

Gastrointestinal Torsion in a Channel Catfish (*Ictalurus punctatus*)

Authors: Pasnik, David J., Khoo, Lester, and Gaunt, Patricia S.

Source: Journal of Wildlife Diseases, 39(1) : 238-240

Published By: Wildlife Disease Association

URL: <https://doi.org/10.7589/0090-3558-39.1.238>

BioOne Complete (complete.BioOne.org) is a full-text database of 200 subscribed and open-access titles in the biological, ecological, and environmental sciences published by nonprofit societies, associations, museums, institutions, and presses.

Your use of this PDF, the BioOne Complete website, and all posted and associated content indicates your acceptance of BioOne's Terms of Use, available at www.bioone.org/terms-of-use.

Usage of BioOne Complete content is strictly limited to personal, educational, and non - commercial use. Commercial inquiries or rights and permissions requests should be directed to the individual publisher as copyright holder.

BioOne sees sustainable scholarly publishing as an inherently collaborative enterprise connecting authors, nonprofit publishers, academic institutions, research libraries, and research funders in the common goal of maximizing access to critical research.

Gastrointestinal Torsion in a Channel Catfish (*Ictalurus punctatus*)

David J. Pasnik,^{1,2,4} Lester Khoo,^{1,3} and Patricia S. Gaunt¹ ¹ Thad Cochran National Warmwater Aquaculture Center, College of Veterinary Medicine, Mississippi State University, Stoneville, Mississippi 38776, USA; ² Current address: Aquatic Medicine Laboratory, Virginia-Maryland College of Veterinary Medicine, Virginia Polytechnic Institute and State University, Blacksburg, Virginia 24061, USA; ³ Current address: University of Pennsylvania, School of Veterinary Medicine, New Bolton Center, 382 West Street Road, Kennett Square, Pennsylvania 19348, USA; ⁴ Corresponding author (email: dpasnik@vt.edu)

ABSTRACT: A case of gastrointestinal torsion with dilatation in a farm-raised channel catfish (*Ictalurus punctatus*) was examined at the Thad Cochran National Warmwater Aquaculture Center (Stoneville, Mississippi, USA). The affected fish was a gravid female broodfish, which displayed pale gills and a markedly distended abdomen. Internal examination revealed that the gastrointestinal tract and ovaries were rotated around each other four times in a counterclockwise direction as viewed in right lateral recumbency. The catfish had a markedly distended gastrointestinal tract, pale liver, hypoplastic spleen, hypoplastic swim bladder, and high volume of ascitic fluid. Blood analysis indicated multiple abnormalities, including severe anemia and metabolic acidosis. The etiology of the torsion was uncertain; however, the presence of a hypoplastic swim bladder most likely allowed for increased movement of the gastrointestinal tract and ovaries. When examining cases of abdominal distention in fish, gastrointestinal torsion can be considered among the differential diagnoses.

Key words: Aquaculture, channel catfish, fish health, *Ictalurus punctatus*, pathology, torsion.

Gastrointestinal torsion is caused by a segment of bowel twisting on its long axis. While it has been widely-reported in mammals (Aiello and Mays, 1998), gastrointestinal torsion is not a well-documented affliction of fish. Morales and Dunker (1999) described a possible torsion in a captive blacktip reef shark (*Carcharhinus melanopterus*). The authors found grossly inflamed mucosa in the valvular intestine and colon. Multiple adhesions were also noted, suggesting peritonitis, and the stomach was detached from the proximal valvular intestine. The proposed etiology included a torsion of the intestine with subsequent ischemia, leading to perforation and ultimate separation of the intestine. In the paper, the authors also cited a personal communication describing intes-

tinal torsion in the bull shark (*Carcharhinus leucas*).

We examined a live 55.8 cm long, 3.5 kg, gravid female channel catfish (*Ictalurus punctatus*) taken from an earthen broodstock pond in western Mississippi. The fish was presented to the Fish Diagnostic Laboratory at the Thad Cochran National Warmwater Aquaculture Center (Stoneville, Mississippi, USA) on 19 April 2000 with a chief complaint of lethargy. The farmer caught the fish while it was resting on the surface of the pond near the bank. Reported water quality parameters were within normal limits (Tucker and Robinson, 1990), and no other fish were reported affected.

External examination revealed pale gills and a severely distended abdomen. Approximately 7 ml of blood was taken from the caudal vessel and the hematocrit was 1%. Normal hematocrit levels of channel catfish in western Mississippi during April are approximately 19% (Leard et al., 1998). The catfish was euthanized with an overdose of tricaine methanesulfonate (MS-222; Western Chemical, Ferndale, Washington, USA). When the abdominal cavity was aseptically opened, it contained approximately 110 ml of cloudy red ascitic fluid, which was collected using a sterile needle and syringe. Approximately 20 cm of the gastrointestinal tract appeared dark red and tensely distended with gas; the corresponding mesenteric vessels were severely congested. The stomach and bowel were twisted around the mesovarium of the gravid ovaries four times in a counterclockwise direction when viewed in right lateral recumbency (Fig. 1). When incised, the intestines contained a small amount of

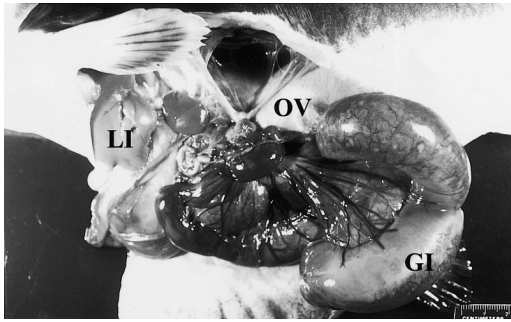


FIGURE 1. Torsion of the gastrointestinal tract (GI) around gravid ovaries (OV) in a catfish. The intestines are severely distended and mesenteric vessels are prominent. In the cranial abdomen, the liver (LI) appears pale. A 2 cm ruler is included for reference.

fetid brown fluid, which included numerous white flecks of sloughed, devitalized intestinal mucosa approximately 1 mm in diameter. No food was observed in the stomach or intestines. The liver was pale with a green hue, and the spleen and swim bladder appeared to be hypoplastic. The inflated swim bladder was 4.3 cm in length and 3.5 cm in its widest width. No other significant lesions were noted.

Samples from brain, posterior kidney, and ascitic fluid were plated on trypticase soy agar (TSA) with 5% defibrinated sheep blood and on Ordal's Cytophaga agar. Plates were incubated at 25 C for 96 hr. Cultures of brain and kidney were negative. However, *Aeromonas sobria* was identified from ascitic fluid according to its biochemical characteristics (Minitex, Becton Dickinson, Microbiology Systems, Cockeysville, Maryland, USA). Motile aeromonads are part of the normal enteric flora of channel catfish (Tucker and Robinson, 1990) and their presence in the peritoneal cavity suggested loss of intestinal integrity. This was further suggested by examination of the ascitic fluid. The fluid was grossly cloudy and red with a packed cell volume of 1% and total protein of 3.7 g/dl. Cytologic preparations revealed many bacilli-containing macrophages. Two major bacterial components were present: $2.7 \times 0.5 \mu\text{m}$ Gram-negative bacilli and $3.8 \times 0.8 \mu\text{m}$ Gram-positive bacilli. The

Gram-negative bacilli were morphologically consistent with the cultured *A. sobria*. The morphology of the Gram-positive bacilli was suggestive of *Clostridium* spp., which are commonly found in earthen catfish ponds. Given these findings, the fluid can be characterized as a septic exudate presumably present due to leakage from the gastrointestinal tract.

Samples of muscle, brain, gill, liver, spleen, anterior kidney, posterior kidney, gastrointestinal tract, and ovary were placed in neutral buffered 10% formalin. The tissues were processed using routine histological techniques, sectioned at $4 \mu\text{m}$, and stained with hematoxylin and eosin, Giemsa, or Gram. Microscopically, the intestinal mucosa was necrotic with marked sloughing of cells into the lumen. The intestinal serosa was severely thickened and edematous, replete with inflammatory cells and bacilli. Mesenteric vessels were markedly congested and contained eosinophilic proteinaceous, fibrillar material (presumptive fibrin thrombi). Also noted was a lymphocyte-depleted spleen, one section of which contained a fibrin tag. There was passive congestion in the vessels of the ovary as well as necrosis of the vessel walls. Small numbers of the Gram-negative bacilli were intermixed with the follicles.

A serum sample from the subject was analyzed (ACE Clinical Chemistry System, Schiapparelli Biosystems, Fairfield, New Jersey, USA) and compared to baseline parameters of commercially-reared channel catfish (Bentinck-Smith et al., 1987; Leard et al., 1998). Abnormalities were detected for the following values (with measured levels versus normal reference ranges in parentheses): sodium (110.0 versus 130.9–147.9 meq/l), potassium (8.4 versus 1.9–5.3 meq/l), chloride (89 versus 115.1–147.9 meq/l), phosphate (17.1 versus 6.1–13.1 mg/dl), glucose (27 versus 40.4–88.6 mg/dl), aspartate aminotransferase (1,010 versus 37.1–152.3 U/l), alkaline phosphatase (7.0 versus 8.8–31.8 U/l), creatinine kinase (8,570 versus N/A), and osmolality (207 versus 277.7–301.9 mOsm/kg). Most

of these abnormalities could be attributed to loss of fluids and electrolytes across the damaged intestinal mucosa and through sequestration in the gut lumen. Starvation and gastrointestinal malabsorption may have exacerbated these changes. The apparently increased anion gap (27) and decreased TCO_2 (2.5 meq/l) were consistent with metabolic acidosis. Calcium, urea-nitrogen, creatinine, total protein, and albumin values were within normal limits.

This is one of the first reports of gastrointestinal torsion in fish and the first in channel catfish. Therefore, the etiology of this condition is not known. Because torsions are most commonly found in animals with cavernous or pendulous body cavities (Aiello et al., 1998), it is possible that a congenital or developmental anomaly allowed sufficient space for movement of the intestine. The predisposing abnormality was most likely the swim bladder, which appeared hypoplastic. Although this irregularity has not been studied in catfish, it is documented among other cultured species, such as sea bream (*Sparus aurata*; Weppe and Bonami, 1981) and striped bass (*Morone saxatilis*; Bennett et al., 1987).

The combination of a small swim bladder and gravid ovaries most likely allowed movement of the gastrointestinal tract around the mesovarium. With subsequent compression of the mesenteric blood vessels, pooling of the blood resulted in congested, edematous, hemorrhagic bowel segments. The resulting hypoxic condition in the intestine induced necrosis of the intestinal mucosa, which decreased the absorptive capabilities of the intestine and allowed effusion of fluid and blood into the bowel lumen (Barker et al., 1993). As the condition progressed, the integrity of the intestinal tract was further compromised; fluid and normal enteric flora invaded and passed through the bowel. Anaerobic bacteria also proliferated in the hypoxic bowel and these are capable of producing toxins and gas (Barker et al., 1993). These toxins can promote cardiovascular failure, and gangrene and distention of the intestine

can ultimately lead to a rupture in the increasingly devitalized, friable intestinal wall. Ultimately, if the catfish had not been euthanized, it probably would have died due to cardiovascular dysfunction, septic shock, peritonitis, or hypoxia (Aiello et al., 1998).

The authors wish to thank T. Santucci, J. Tobia, and S. Gaunt for technical assistance, and P. Hanson, S. Jack, and M. Lawrence for analysis of the manuscript. This research is supported by the Mississippi Agricultural and Forestry Experimental Station (MAFES) and the College of Veterinary Medicine, Mississippi State University. This paper is MAFES publication number J9951.

LITERATURE CITED

- AIELLO, S. E., AND A. MAYS. 1998. Digestive system. In *The Merck veterinary manual*, Aiello, S. E. and A. Mays (eds.). Merck & Co., Inc., Whitehouse Station, New Jersey, pp. 103–348.
- BARKER, I. K., A. A. VAN PREUMEL, AND N. PALMER. 1993. The intestine. In *Pathology of domestic animals*, Vol. 2. Jubb, K. F. V., P. C. Kennedy and N. C. Palmer (eds.). Academic Press, Inc., San Diego, California, pp. 74–141.
- BENNETT, R. O., J. N. KRAEUTER, L. C. WOODS, M. M. LIPSKY, AND E. B. MAY. 1987. Histological evaluation of swim bladder non-inflation in striped bass larvae *Morone saxatilis*. *Diseases of Aquatic Organisms* 3: 91–95.
- BENTINCK-SMITH, J., M. H. BELEAU, P. WATERSTRAT, C. S. TUCKER, F. STILES, P. R. BOWSER, AND L. A. BROWN. 1987. Biochemical reference ranges for commercially reared channel catfish. *The Progressive Fish-Culturist* 49: 108–114.
- LEARD, A. T., B. A. WAGNER, K. L. CAMP, D. J. WISE, AND X. D. GAO. 1998. Seasonal values of selected blood parameters of farm-raised channel catfish (*Ictalurus punctatus*) in the Mississippi delta. *Journal of Veterinary Diagnostic Investigation* 10: 344–349.
- MORALES, P., AND F. DUNKER. 1999. Suspected intestinal torsion in a blacktip reef shark (*Charcharhinus melanopterus*). *Journal of Zoo and Wildlife Medicine* 30: 170–172.
- TUCKER, C. S., AND E. H. ROBINSON. 1990. Channel catfish farming handbook. Van Nostrand Reinhold, New York, New York, 454 pp.
- WEPPE, M., AND J. R. BONAMI. 1981. Non-inflation of the swimbladder in hatchery-reared sea bass and sea bream: A significant problem in marine aquaculture. *Bulletin of the European Association of Fish Pathologists* 3: 59–60.

Received for publication 5 November 2001.