



CLINICAL DISEASE AND LABORATORY ABNORMALITIES IN FREE-RANGING DESERT TORTOISES IN CALIFORNIA (1990–1995)

Authors: Christopher, Mary M., Berry, Kristin H., Henen, Brian T., and Nagy, Kenneth A.

Source: Journal of Wildlife Diseases, 39(1) : 35-56

Published By: Wildlife Disease Association

URL: <https://doi.org/10.7589/0090-3558-39.1.35>

BioOne Complete (complete.BioOne.org) is a full-text database of 200 subscribed and open-access titles in the biological, ecological, and environmental sciences published by nonprofit societies, associations, museums, institutions, and presses.

Your use of this PDF, the BioOne Complete website, and all posted and associated content indicates your acceptance of BioOne's Terms of Use, available at www.bioone.org/terms-of-use.

Usage of BioOne Complete content is strictly limited to personal, educational, and non - commercial use. Commercial inquiries or rights and permissions requests should be directed to the individual publisher as copyright holder.

BioOne sees sustainable scholarly publishing as an inherently collaborative enterprise connecting authors, nonprofit publishers, academic institutions, research libraries, and research funders in the common goal of maximizing access to critical research.

CLINICAL DISEASE AND LABORATORY ABNORMALITIES IN FREE-RANGING DESERT TORTOISES IN CALIFORNIA (1990–1995)

Mary M. Christopher,^{1,5} Kristin H. Berry,² Brian T. Henen,^{3,4} and Kenneth A. Nagy³

¹ Department of Pathology, Microbiology & Immunology, School of Veterinary Medicine, University of California–Davis, Davis, California 95616, USA

² 22835 Calle San Juan de Los Lagos, Moreno Valley, California 92553, USA

³ Department of Organismic Biology, Ecology, and Evolution, and Laboratory of Biomedical and Environmental Sciences, University of California–Los Angeles, Los Angeles, California 90024, USA

⁴ Current address: Department of Zoology, University of the Western Cape, Private Bag X17, Bellville, 7535, South Africa

⁵ Corresponding author (email: mmchristopher@ucdavis.edu)

ABSTRACT: Desert tortoise (*Gopherus agassizii*) populations have experienced precipitous declines resulting from the cumulative impact of habitat loss and human and disease-related mortality. Diagnosis of disease in live, free-ranging tortoises is facilitated by evaluation of clinical signs and laboratory test results but may be complicated by seasonal and environmental effects. The goals of this study were: 1) to describe and monitor clinical and laboratory signs of disease in adult, free-ranging desert tortoises at three sites in the Mojave Desert of California (USA) between October 1990 and October 1995; 2) to evaluate associations between clinical signs and hematologic, biochemical, serologic, and microbiologic test results; 3) to characterize disease patterns by site, season, and sex; and 4) to assess the utility of diagnostic tests in predicting morbidity and mortality. Venous blood samples were obtained four times per year from tortoises of both sexes at the Desert Tortoise Research Natural Area (DTNA), Goffs/Fenner Valley, and Ivanpah Valley. Tortoises were given a physical examination, and clinical abnormalities were graded by type and severity. Of 108 tortoises, 68.5% had clinical signs of upper respiratory tract disease consistent with mycoplasmosis at least once during the study period. In addition, 48.1% developed moderate to severe shell lesions consistent with cutaneous dyskeratosis. Ulcerated or plaque-like oral lesions were noted on single occasions in 23% of tortoises at Goffs and 6% of tortoises at Ivanpah. Tortoises with oral lesions were significantly more likely than tortoises without lesions to have positive nasal cultures for *Mycoplasma agassizii* ($P=0.001$) and to be dehydrated ($P=0.0007$). Nine tortoises had marked azotemia (blood urea nitrogen [BUN] >100 mg/dl) or persistent azotemia (BUN 63–76 mg/dl); four of these died, three of which had necropsy confirmation of urinary tract disease. Laboratory tests had low sensitivity but high specificity in assessing morbidity and mortality; there was marked discrepancy between serologic and culture results for *M. agassizii*. Compared with tortoises at other sites, tortoises at DTNA were more likely to be seropositive for *M. agassizii*. Tortoises at Goffs were significantly more likely to have moderate to severe shell disease, oral lesions, positive nasal cultures for *M. agassizii*, and increased plasma aspartate aminotransferase activity. The severe disease prevalence in Goffs tortoises likely contributed to the population decline that occurred during and subsequent to this study.

Key words: Chelonian, clinical chemistry, cutaneous dyskeratosis, desert tortoise, hematology, Mojave Desert, *Gopherus agassizii*, *Mycoplasma agassizii*, mycoplasmosis, shell disease, upper respiratory tract disease.

INTRODUCTION

Over the past 25 yr, dramatic declines have been observed in many desert tortoise (*Gopherus agassizii*) populations in the Mojave and Colorado deserts of the southwestern United States (US Fish and Wildlife Service, 1994; Berry and Medica, 1995; Berry, 1997). These declines have been attributed to the cumulative impacts of human activities, predation, habitat loss and degradation, and disease (US Fish and Wildlife Service, 1994). In April 1990, de-

sert tortoise populations north and west of the Colorado River were listed as threatened by the US Fish and Wildlife Service. At about the same time, the Bureau of Land Management initiated several research projects in response to developing disease problems in desert tortoises, including mycoplasmosis (upper respiratory tract disease [URTD]; Jacobson et al., 1991; Brown, et al., 1994, 1999; Homer et al., 1998) and shell disease (cutaneous dyskeratosis; Jacobson et al., 1994; Homer et

al., 1998). A "health profile" program was established to determine reference intervals for laboratory data for clinically healthy desert tortoises at various seasons and geographic sites (Christopher et al., 1999; Berry and Christopher, 2001). Baseline data would be useful for identifying abnormal laboratory results, which may help diagnose stress or disease in tortoises (Jacobson et al., 1991, 1994; O'Connor et al., 1994).

In the course of the health profile study, two-thirds of samples were obtained from tortoises that were clinically healthy at the time of sampling, but one-third of samples were from tortoises with clinical signs of disease or abnormal laboratory test results (Christopher et al., 1999). Reference intervals were constructed using laboratory values only from those sampling periods when tortoises had negative serologic and culture results for mycoplasmosis and no or minimal clinical signs of URTD. Tortoises with severe or persistent clinical abnormalities or laboratory abnormalities were not included in the reference population. The purpose of the present study was to characterize the prevalence, severity, and types of clinical signs of disease in these same three populations of free-ranging desert tortoises and to determine their association, if any, with alterations in laboratory data and mortality. In addition, shells were evaluated retrospectively for lesions of cutaneous dyskeratosis. The longitudinal design of the study facilitated monitoring of clinical and laboratory abnormalities over time, including years having below and above average rainfall.

MATERIALS AND METHODS

Sites

Samples were obtained from tortoises at three sites in the Mojave Desert of California (USA): the Desert Tortoise Research Natural Area (DTNA) in the western Mojave Desert (35°10'N, 118°10'W; elevation 869–945 m); Goffs/Fenner Valley (Goffs) in the eastern Mojave Desert, at the boundary with the northern Colorado Desert (34°52'N, 115°10'E; elevation ~700 m); and Ivanpah Valley (Ivanpah), in the

western corner of the northeastern Mojave Desert (35°39'N, 115°15'W; elevation 866–914 m). Long-term (1961–1996), annual, and winter precipitation data from these sites were obtained from the National Oceanic and Atmospheric Administration (1989–1995).

Animals, sampling periods, and physical findings

Study populations and sampling periods were previously described (Christopher et al., 1999). Briefly, 10 adult males and 10 adult females at each site were captured, marked, and fitted with radio transmitters (AVM model SB-2, AVM Instrument Co., Livermore, California, with 48-cm copper antenna, powered by a lithium C-cell) in 1989. Tortoises were identified by a combination of letters (site and sex) and numbers. Tortoises that died or disappeared were replaced, when possible, with tortoises of the same sex and given sequential, new numbers. Samples were collected from tortoises at all sites four times per year: late winter (February–March, just prior to emergence from hibernation), spring (May–June, during a time of peak activity and forage), summer (July–August, a hot, typically dry season), and fall (October, just prior to hibernation). Data were organized by hydrologic year (fall through summer seasons; October 1–September 30). Study years included 1990–91, 1991–92, 1992–93, 1993–94, 1994–95, and a final sample in fall 1995.

Precautions were taken to prevent transmission of pathogens within and among study sites. Each tortoise was handled with a fresh pair of disposable gloves, and items of equipment touching the tortoise were disinfected with a sodium hypochlorite solution (0.175%) or ethanol (70%) immediately after use. Precautions were taken to assure the tortoise did not touch or rest upon the field worker's limbs, clothing, or equipment without protective covering.

Body weight using a top-loading balance and carapace length at the midline (MCL) using alcohol-sterilized calipers were measured each time a tortoise was sampled. In addition, tortoises were given a complete physical examination, using field guidelines described elsewhere (Berry and Christopher, 2001). Briefly, the following features were evaluated: beak and nares, forelegs, breathing, eyes, chin (mental) glands, integument, posture/behavior, oral cavity, shell, evidence of trauma (e.g., bite wounds, abrasions), and presence of ectoparasites. Ticks were sent to Dr. James Oliver (Georgia Southern University, Institute of Arthropodology and Parasitology, Statesboro, Georgia, USA) for identification. Retrospective, blinded examination (by KB) of color transparencies (35 mm

slides) of the carapace and plastron was done to further evaluate shell disease. Full-frame images of the head, carapace, and plastron were taken when the tortoise was first entered in the study and again in the spring of each year. Photographs also were taken of any physical abnormality or lesion, when noted. For each tortoise, the severity of shell lesions was graded as none, mild, moderate, or severe, based on the degree of discoloration, lifting laminae, flaking, and amount of bone exposed on the carapace and plastron (Berry and Christopher, 2001). Distribution of shell lesions was categorized as affecting 0%, <10%, 11–40%, or >40% of the plastron or carapace. An overall grade of none, mild, moderate, or severe shell disease was based on the combined assessment of carapace and plastron. Shell lesions also were classified as active, if current lesions were noted, or chronic, if signs of regression or healing were seen, such as healthy laminae at the seams of scutes.

Scute condition (from 35 mm transparencies) was used to determine the approximate age class of tortoises, based on the following criteria (Berry and Woodman, 1984): 1) very young adult (12–25 yr), full or partial areola on each scute, growth rings surrounding areola over 90% of carapace; 2) young adult (25–50 yr), most areola worn away, growth rings chipping and flaking (normal wear) but distinct and in good condition; 3) middle-aged adult (50–70 yr), many growth rings worn away, flaking, and chipping, maximal scute thickness; 4) old adult (>70 yr), depressions on surfaces of eight or fewer scutes, scutes thinning; 5) very old adult, depressions on most scutes involving entire scute, most growth rings gone, thin laminae.

Serology and microbiology

Beginning in winter 1992, plasma samples from all tortoises were sent to Dr. Mary Brown (University of Florida, Gainesville, Florida, USA) where they were tested for antibodies to *Mycoplasma agassizii* using an enzyme linked immunosorbent assay (ELISA), as previously described (Schumacher et al., 1993). Serologic results were classified as positive or negative; “suspect” results were considered negative unless the tortoise seroconverted to a positive titer (see Brown et al., 1999 for a complete description of serologic results). Nasal flushes were obtained by introducing 0.5 ml of trypticase soy broth (BBL Microbiology Systems, Cockeysville, Maryland, USA) into the anterior nares using a sterile open-end tomcat catheter. After flushing the nasal passages, aspirates were placed in sterile cryovials, frozen at –196 C, and transferred to a veterinary diagnostic lab-

oratory (APL Laboratories, Las Vegas, Nevada, USA) within 24 hr. Cultures for *Pasteurella testudinis* and mixed flora were done using blood agar (trypticase soy agar with 5% sheep red blood cells RBC), chocolate agar (incubated at 35 C in 5% CO₂), and MacConkey agar (incubated at 35 C in ambient atmosphere) plates. One blood agar plate was incubated at 35 C in a 5% CO₂ atmosphere, and another at 25 C in ambient atmosphere. Cultures were examined daily for 7 days. Nasal flush samples also were cultured for *M. agassizii* as previously described (Brown et al., 1994). Nasal flushes were discontinued after fall 1994 due to lack of funding.

Blood samples and analysis

Blood collection, processing, and analytical methods were previously described (Christopher et al., 1999). Briefly, sterile technique was used to obtain 4.0 to 4.7 ml blood from the jugular vein. Aliquots were placed in tubes containing lithium heparin for whole blood analysis and for separation of plasma. Air-dried smears were fixed in methanol and stained with modified Wright's stain. Microhematocrit centrifugation was used to determine packed cell volume (PCV) both in the field and in the laboratory. Frozen plasma (–196 C) and chilled whole blood samples (4 C) were transported to the laboratory within 24 hr for analysis.

A complete blood count included PCV, RBC count, white blood cell (WBC) count, hemoglobin (Hb) concentration, mean cell volume (MCV), mean cell Hb (MCH), mean cell Hb concentration (MCHC), differential WBC count, and qualitative evaluation of blood cell morphology (Raskin, 2000). Clinical chemistry tests included glucose, blood urea nitrogen (BUN), creatinine (beginning in spring 1993), uric acid, total protein, albumin, calcium, phosphorus, total bilirubin, direct bilirubin, triglycerides (beginning in spring 1993), bile acids (beginning in spring 1993), cholesterol, iron (beginning in summer 1993), magnesium (beginning in spring 1994) sodium, potassium, chloride, and total carbon dioxide (TCO₂) concentrations and alkaline phosphatase (ALP), aspartate aminotransferase (AST), and alanine aminotransferase (ALT) activities. Globulins, albumin/globulin ratio, anion gap, osmolality, sodium/potassium ratio, and indirect bilirubin were calculated.

Statistical analysis

Statistical analysis was done using a computer-assisted program (StatView, Abacus Concepts, Inc., Berkeley, California). Cut-off values for each analyte were established by examina-

tion of previously published reference intervals for site, season, and sex (Christopher et al., 1999) and examination of scatterplots of all values. Crude mortality rate (%) at each site was calculated as the number of tortoises found dead divided by the total number of tortoises sampled at that site per hydrologic year. Average annualized mortality rate (%) was the total mortality rate divided by 5 yr.

Tortoises were categorized by sex, site, age class, status at the end of the study (live, dead), year of death, presence and severity of shell disease (none to mild, moderate to severe), amount of *P. testudinis* and mixed flora growth (none to light, moderate to heavy), presence or absence of marked azotemia (BUN > 100 mg/dl), persistent azotemia (increased BUN in two or more consecutive seasons), bite marks, ticks, oral lesions, clinical dehydration, clinical signs of URTD, seropositivity for *M. agassizii*, and culture-positivity for *M. agassizii*. For calculation of sensitivity, specificity, and predictive values, tortoises were categorized as affected (positive, present) or unaffected (negative, absent) based on cut-off values for the following laboratory abnormalities: anemia (decreased PCV, Hb, or RBC count), leukocytosis, heterophilia, heteropenia, lymphocytosis, lymphopenia, basopenia, increased iron concentration (hyperferremia), increased AST activity, hyperglobulinemia, hypertriglyceridemia, hypophosphatemia, hypomagnesemia, any electrolyte abnormality, increased bile acids concentration, hyperbilirubinemia, and azotemia. Some abnormalities affected too few tortoises for statistical analysis. Contingency tables and Chi-square (χ^2) analyses were used to evaluate associations among variables. Quantitative differences in some values (e.g., numbers of positive ELISA tests by site) were determined using Student's *t*-test and analysis of variance (ANOVA). Data were reported as mean \pm SD unless otherwise indicated. Significance was defined as $P < 0.05$. Sensitivity, specificity, and predictive values were calculated for laboratory and clinical variables that were significantly associated (based on χ^2 analysis) with death, seropositivity, culture positivity for *M. agassizii*, or moderate to severe cutaneous dyskeratosis.

RESULTS

A total of 1,071 observations were made, and blood samples obtained, from 108 tortoises. Tortoises were sampled 9.9 ± 6.9 times (median = 8; range = 1–21 samples) over the 5 yr (21 sample) period. These included 295 observations on 40 tortoises (23 males, 17 females) at DTNA;

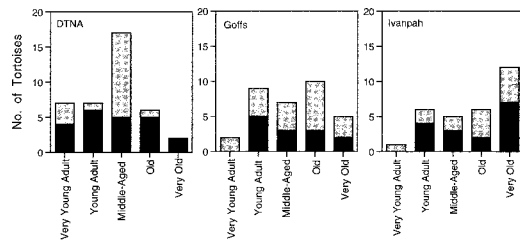


FIGURE 1. Distribution of tortoises by age-size class and sex at three sites in the Mojave desert. Solid bar = males; shaded bar = females.

393 observations on 35 tortoises (13 males, 22 females) at Goffs; and 383 observations on 33 tortoises (18 males, 15 females) at Ivanpah. Sixty-three of the 108 tortoises were sampled one to six times, 21 tortoises were sampled seven to 12 times, 23 tortoises were sampled 13–18 times, and one tortoise was sampled at each of the 21 sampling periods. There was no significant difference in the number of male and female tortoises sampled each season at each site. There was a significant difference ($\chi^2 = 25.24$, $P = 0.0014$) in age distribution of tortoises at the three sites, with the highest percent of very old tortoises (65%) at Ivanpah, and the highest percentage of very young tortoises (70%) at the DTNA (Fig. 1).

The study period included both norms and extremes of annual and winter precipitation amounts (see Christopher et al., 1999 for detailed rainfall data). Annual precipitation was at or above long-term norms in 1990–91, below long-term norms in 1993–94, and above long-term norms in 1991–92, 1992–93, and 1994–95 at all three sites. Winter precipitation was below long-term norms in 1989–90 (the year preceding the study period) and 1993–94 at all three sites.

Mortality

Of 108 tortoises evaluated, 58 (53.7%) were known survivors as of fall 1995 (Table 1). Thirty-two tortoises disappeared and were not relocated for the remainder of the study. Several tortoises were missing for one or more sampling periods but were

TABLE 1. Numbers of tortoises entered into and exiting the study each year.

Site	Fall 1990	1990–91	1991–92	1992–93	1993–94	1994–95	Fall 1995	Total	% at site	Annualized mortality
DTNA										
No. entered	13	3	8	2	3	8	3	40	—	
No. found dead	—	2	0	1 ^a	0	2 ^a	0	5	12.5%	2.5%
No. missing ^b	—	3	2	1	5	3	1	15	37.5%	
GOFFS										
No. entered	16	4	4	3	3	4	1	35	—	
No. found dead	—	0	2	0	6 ^c	0	1 ^a	9	25.7%	5.1%
No. missing	—	1	2	4	1	0	0	8	22.9%	
IVANPAH										
No. entered	15	6	5	1	4	2	0	33	—	
No. found dead	—	2	0	0	0	2	0	4	12.1%	2.4%
No. missing	—	1	3	1	1	1	2	9	27.3%	
ALL SITES										
No. entered	44	13	17	6	10	14	4	108	—	
No. found dead	—	4	2	1	6	4	1	18	16.7%	3.3%
No. missing	—	5	7	6	6	3	3	32	29.6%	

^a One tortoise assumed dead because radiotransmitter was found.

^b Unable to locate at this time and for the remainder of the study.

^c Five tortoises were found dead in July 1994.

found again at a later date, and thus remained in the study. Goffs had about twice the crude and annualized mortality rate of DTNA and Ivanpah. All nine Goffs tortoises that died were female ($\chi^2=7.37$, $P=0.0066$); whereas, females accounted for 40% of deaths at the DTNA and 50% of deaths at Ivanpah (Table 2). Six of nine tortoises at Goffs died in 1993–94. Eight of nine deaths at the DTNA and Ivanpah occurred the year following a dry winter (i.e., in 1990–91 and 1994–95).

At the DTNA, two of five tortoises that died (D40M, I8M) had urolithiasis with azotemia, and clinical signs of URTD (Table 2). Tortoise D40M was one of only two tortoises at the DTNA (along with D25M) with moderate (versus none to mild) shell disease; four of nine Goffs tortoises and three of four Ivanpah tortoises that died also had moderate to severe shell disease. Tortoise D7M had severe peritonitis and multiple bladder wall abscesses, presumably related to previous cystocenteses done as part of a research study (Klaassen, 1991; Peterson, 1994). Eleven of 18 tortoises that died had no clinical or laboratory abnormalities in the season preceding

death, including eight of nine Goffs tortoises. Necropsy results for tortoise G30F listed predation and acute bacterial pneumonia as the cause of death (Homer et al., 1998).

Clinical signs

Three tortoises (D7M, D9M, I9M) had general signs of illness, including poor body condition, lethargy, and weakness. One tortoise died (D7M, described above) and the other two tortoises went missing. Tortoise D9M was dehydrated, had hypoglycemia (glucose 22 mg/dl, reference values 40–169 mg/dl), a low basophil count (26/ μ l; reference values, 62–3,575/ μ l), and lymphopenia (26/ μ l; reference values, 63–2,746/ μ l), and was seropositive for *M. agassizii*. Tortoise I9M also was dehydrated, and subsequently developed marked leukocytosis (40,000 WBC/ μ l; reference values, 1496–10,924/ μ l), heterophilia (20,000 heterophils/ μ l; reference values, 719–7,159/ μ l) and lymphocytosis (16,000 lymphocytes/ μ l; reference values, 63–2,746/ μ l). An additional 16 tortoises (14.8%) were clinically dehydrated, as evidenced by decreased skin elasticity or

TABLE 2. Clinical signs of disease and laboratory abnormalities in 18 tortoises that died.

Tortoise no.	No. observations	Found dead	ELISA	Culture	Necropsy	Clinical and laboratory abnormalities in the season preceding death	Earlier clinical and laboratory abnormalities (in chronological order)
D7M	2	Spring '91	ND ^a	ND	Peritonitis, bladder abscesses ^b	Dehydrated, weak, azotemia (251 mg/dl), hyperosmolality (408 mOsm/kg)	Azotemia (217 mg/dl), azurophilia (1,710/ μ l)
D16F	3	Summer '91	ND	ND	ND	None	None
D30F ^c	2	Winter '93	—	—	ND	None	None
D40M ^d	4	Spring '95	—	—	Urolithiasis ^e	Eyes swollen, mucus in eyes, azotemia (71 mg/dl), 1+ polychromasia, hypomagnesemia (3.0 mg/dl)	Dark brown thick urine, hyperbilirubinemia (0.6 mg/dl), azotemia (25 and 76 mg/dl), increased iron (292 μ g/dl)
D41M ^c	3	Summer '95	—	—	ND	Hypertriglyceridemia (431 mg/dl)	Mucus in right eye, hypomagnesemia (3.0 mg/dl)
G21F	5	Summer '92	ND	ND	ND	None	Bubbles from nares, wet eyelids, dehydration, hyperphosphatemia (9.1 mg/dl), high anion gap (41 mmol/l)
G23F ^d	16	Fall '95	+	+	ND	Right eye crusty	Raspy, clicking breathing, mucus in both eyes, dehydrated, swollen eyelids, dried mucus in eyes, azotemia (46 mg/dl), heterophilia (8,500/ μ l), hyperkalemia (8.6 mmol/l), oral ulcers, foul-smelling oral cavity, hyperkalemia (7.7 mmol/l), metabolic acidosis (total CO ₂ 10 mmol/l)
G27F	13	Summer '94	—	—	ND	None	Mucus in eye, heteropenia (364/ μ l), azotemia (57 mg/dl), high anion gap (37 mmol/l), in poor condition, high AST (170 U/l), hyperchloremia (144 mmol/l), hyperkalemia (8.2 mmol/l)
G30F	1	Winter '92	ND	ND	Pneumonia, predation ^e	None	Not applicable
G31F ^d	9	Summer '94	—	—	ND	None	Oral plaques, high AST (158 U/l), watery eye, high AST (341 U/l), oral ulcer, hyperglycemia (223 mg/dl), ticks
G32F	9	Summer '94	—	+	ND	None	Hyperosmolality (416 mOsm/kg), azotemia (112 mg/dl), hyperphosphatemia (6.9 mg/dl), azotemia (194 mg/dl), hyperchloremia (145 mmol/l), 1+ polychromasia, heterophilia (8,422/ μ l), hyperchloremia (149 mmol/l)
G34F ^d	3	Spring '94	—	—	ND	None	1+ polychromasia, high RBC count
G35F	5	Summer '94	—	—	ND	None	1+ polychromasia, high RBC count, hypertriglyceridemia (782 mg/dl)
G36F ^d	5	Summer '94	—	—	ND	None	High RBC count

TABLE 2. Continued.

Tortoise no.	No. observations	Found dead	ELISA	Culture	Necropsy	Clinical and laboratory abnormalities in the season preceding death	Earlier clinical and laboratory abnormalities (in chronological order)
I8M ^d	17	Winter '95	—	+	Urolithiasis ^e	Azotemia (306 mg/dl), hyperosmolality (421 mOsm/kg)	Heteropenia (109/ μ l), anemia (PCV 10%, hemoglobin 2.7 mg/dl), heteropenia (570/ μ l), lymphopenia (20/ μ l), heterophilia (12,008/ μ l), wheezing raspy breath, hypophosphatemia (0.8 mg/dl), increased creatinine (0.5 mg/dl), azotemia (46 mg/dl), hypophosphatemia (0.5 mg/dl), azotemia (140 mg/dl), hypophosphatemia (0.5 mg/dl)
I12F	3	Summer '91	ND	ND	ND	None	None
I28F ^d	1	Summer '91	ND	ND	ND	Hyperphosphatemia (9.5 mg/dl)	Not applicable
I42M ^d	2	Spring '95	—	—	ND	Hypophosphatemia (0.2 mg/dl)	Ticks

^a ND indicates not done; URTD, upper respiratory tract disease; AST, aspartate aminotransferase; RBC, red blood cell.

^b Presumed secondary to previous cystocentesis.

^c Bite marks noted on shell at all observations.

^d These tortoises also had moderate to marked shell disease.

^e Complete necropsy results reported in Homer et al., 1998.

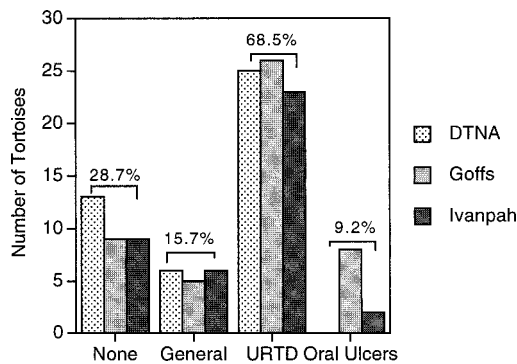


FIGURE 2. Number (for each site) and mean percent of all tortoises showing clinical signs of disease during a 5 yr period. General signs of illness included lethargy, weakness, and dehydration. Some tortoises with signs of upper respiratory tract disease (URT) also had general signs of illness. All tortoises with oral lesions had clinical signs of URTD at some point in the study.

sunken eyes; all but four of these also had clinical signs of URTD.

Seventy-four tortoises (68.5%) had signs of URTD at some point during the 5 yr study period (Fig. 2), including puffy, swollen eyes and eyelids (25.5%), wet or watery eyes (11.6%) or nose (6.0%), cruste-eyed eyes and eyelids (16.2%), mucus or other discharge in the eyes (12.4%) or in the nares (2.2%), and audible respiratory sounds (4.3%). Clinical signs did not differ by site, and many tortoises had more than one sign of URTD. Nine tortoises (three at DTNA, five at Goffs, one at Ivanpah) had abnormal respiratory sounds, including wheezing, rasping, and inspiratory clicks. Weakness, lethargy, or dehydration was noted in 54% (Goffs), 39% (Ivanpah), and 32% (DTNA) of tortoises with clinical signs of URTD. Twenty-two percent of tortoises had clinical signs of disease on one occasion, 30% had signs two or three times, and 19% showed clinical signs four or more times. Clinical signs of URTD were seen more often in 1990–91 and again in 1994–95, compared with other years ($\chi^2=74.05$, $P<0.0001$). Both of these years were normal to wet years that followed a year of below-normal rainfall. Clinical signs were significantly more likely

to be observed at the time of emergence from hibernation in late winter ($\chi^2=15.19$, $P<0.0017$) and were least likely to be seen in summer.

Eight tortoises at Goffs (23% of the Goffs population) and two tortoises at Ivanpah (6% of the Ivanpah population) had oral lesions in 1992–93 (Table 3). The lesions were ulcerated or covered with whitish-yellow plaques and were observed on the top and bottom of the oral cavity, as well as on or along the side of the tongue. Two Goffs tortoises with oral lesions had concurrent signs of URTD; other tortoises with oral lesions had signs of URTD, often severe, at other sampling periods. The oral cavity of two tortoises smelled foul. Tortoises with oral lesions were significantly more likely to have positive nasal cultures for *M. agassizii* ($\chi^2=16.73$, $P<0.0001$); i.e., 70% of tortoises with oral lesions were culture-positive at some time during the study. Four tortoises had multiple positive cultures and 30% were seropositive for *M. agassizii*. Five tortoises (50%) with oral lesions had increased plasma enzyme activity (AST, ALT, and/or ALP), and eight of 10 were dehydrated.

Ticks (one to five per tortoise) were observed on seven Goffs tortoises and eight Ivanpah tortoises in 1993–94 and spring 1995. Ticks were located on the carapace near or under the transmitter ($n=8$), and on the plastron ($n=3$), neck ($n=5$), tail ($n=2$), eyelids ($n=1$), foreleg ($n=1$) or unspecified sites ($n=3$). All ticks were *Ornithodoros* sp. Ticks were significantly more likely to be observed on tortoises that had oral lesions in the previous year ($\chi^2=5.32$, $P=0.021$). Draining chin glands were noted in six male and two female tortoises in summer ($n=3$), fall ($n=2$), and winter ($n=3$). Three tortoises with draining chin glands had concurrent clinical signs of URTD.

Shell lesions

Shell lesions were consistent with those previously described for cutaneous dysker-

TABLE 3. Clinical signs and laboratory abnormalities in 10 tortoises with oral lesions.

Tortoise no.	Season	Serology	Culture	Concurrent abnormalities	Other clinical and laboratory abnormalities in the 5-year period	Outcome
G14M	Winter '93	—	+ ^a	Ocular mucus	Severe upper and lower respiratory signs, ticks, increased AST ^b and ALT ^b , hyperglycemia, azotemia, heteropenia, hyperalbuminemia	Alive
G22F	Winter '93	—	—	Sunken, dull eyes, ocular mucus, weak	Severe upper respiratory signs, increased ALP ^b , hyperbilirubinemia, hyperphosphatemia, hyperkalemia	Missing
G23F	Summer '93	+	+	Foul-smelling oral cavity, hyperkalemia	Severe upper and lower respiratory signs, leukocytosis, heteropenia, azotemia, metabolic acidosis	Dead
G24M	Winter '92	—	+	None	Mild upper respiratory signs, hyperbilirubinemia, polychromasia, basophilia, lymphopenia	Missing
G25M	Winter '93	—	+ ^c	None	Severe upper respiratory signs, polychromasia, increased AST, azotemia, hypoosmolality	Missing
G26F	Spring '93	—	+ ^a	Increased AST	Upper respiratory signs, azotemia, metabolic acidosis, hyperkalemia, increased ALP, hypochloremia	Alive
G29F	Winter '93	+	+ ^a	Hypouricemia	Upper respiratory signs, ticks, polychromasia, hyperbilirubinemia	Alive
G31F	Summer '93	—	—	Hyperglycemia	Mild upper respiratory signs, ticks, increased AST	Dead
I5M	Winter '93	+	—	Foul-smelling oral cavity	Upper respiratory signs, ticks, anemia, heteropenia, lymphopenia, increased ALT, hyperferremia, hypomagnesemia, hypophosphatemia	Alive
I11M	Winter '93	—	+	None	General and upper respiratory signs, ticks, leukocytosis, heteropenia	Alive

^a Tortoise had two positive cultures.^b AST = aspartate aminotransferase; ALT = alanine aminotransferase; ALP = alkaline phosphatase.^c Tortoise had three positive cultures.

atosis (Jacobson et al., 1994; Homer et al., 1998); however, histopathologic confirmation was not done. Distinct white discolored areas also were observed on the shells of many tortoises at all sites, especially during winter and in wet years.

Shell lesions were observed in 88 tortoises (85.4%) and were significantly more severe with increasing tortoise age ($\chi^2=21.40$, $P=0.0003$). Severity of carapace lesions was none ($n=14$), mild ($n=54$), moderate ($n=21$), and severe ($n=1$), with significantly fewer DTNA tortoises having carapace lesions, compared with other sites ($\chi^2=40.24$, $P<0.0001$). Distribution of carapace lesions was 0% ($n=14$), <10% ($n=37$), 11–40% ($n=26$), and >30% ($n=12$). Severity of plastron lesions was none ($n=10$), mild ($n=46$), moderate ($n=35$), or severe ($n=8$), with significantly more Goffs tortoises having moderate to severe plastron disease ($\chi^2=49.12$, $P<0.0001$). Distribution of plastron lesions was 0% ($n=10$), <10% ($n=44$), 11–40% ($n=23$), or >40% ($n=22$). Twenty-seven (77%) Goffs tortoises had moderate to severe plastron lesions, which in 18 tortoises affected >40% of the plastron, significantly more than at other sites (severity $\chi^2=49.12$; distribution $\chi^2=54.18$; $P<0.0001$). Sixty-four percent of carapace lesions and 83% of plastron lesions were active; remaining lesions were chronic or showed evidence of recovery. Overall, for carapace and plastron combined, 28 of 35 (79%) tortoises at Goffs had moderate or severe shell lesions, significantly more ($\chi^2=36.06$, $P<0.0001$) than at Ivanpah (18 of 33, 56%) and DTNA (two of 40, 6%). Hyperglobulinemia ($\chi^2=7.63$, $P=0.0221$), positive *M. agassizii* cultures ($\chi^2=5.98$, $P<0.0001$), and oral lesions ($\chi^2=4.30$, $P=0.0380$), all seen primarily in tortoises at Goffs, were significantly associated with shell disease.

Annual (spring) shell data were compared on a subset of 19 tortoises (five from DTNA, nine from Goffs, five from Ivanpah), which were observed over the entire 5 yr period. There was a significant increase in the number of tortoises with moderate to severe plastron disease over

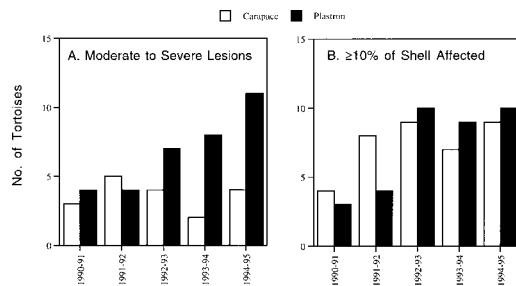


FIGURE 3. Changes over the 5 yr study period in the number of tortoises with (A) moderate to severe shell lesions and (B) shell lesions affecting $\geq 10\%$ of the carapace or plastron.

time ($\chi^2=22.88$, $P=0.0288$, Fig. 3). In addition, the number of tortoises with active carapace lesions increased from six to 13 (32–74%).

Traumatic lesions were observed on 45 (41.7%) tortoises. Old shell or gular trauma or scars were observed on 25 tortoises. Shell chips, cracks, or scratches were observed on 18 tortoises. Eight of 18 shells with bite marks were seen in DTNA tortoises. Other traumatic lesions included missing scales ($n=9$), soft tissue abrasions ($n=8$, five at Ivanpah), missing or damaged nails or feet ($n=6$), and abnormal growths ($n=3$). Traumatic lesions in general were more likely to be seen in tortoises with anemia ($\chi^2=6.66$, $P=0.0098$).

Serology and microbiology

One hundred and seven (of 834) plasma samples from 27 tortoises (25% of all tortoises) were positive for antibodies to *M. agassizii*. Eight tortoises were not tested. Tortoises at DTNA were significantly more likely to be seropositive than tortoises at Goffs ($\chi^2=9.29$, $P=0.0096$, Fig. 4). Seropositive DTNA tortoises also were more likely to have ≥ 2 positive tests (median 3.5, range 1–16), compared with tortoises at Goffs (median 1.5, range 1–2) and Ivanpah (median 1.0, range 1–5). About the same percent of seropositive (78%) and seronegative tortoises (75%) had clinical signs of URTD. Three of four seropositive Goffs tortoises had concurrent clinical signs of URTD compared with 68.8% of

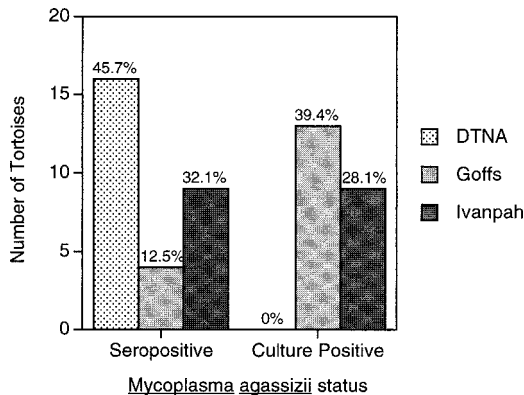


FIGURE 4. Number and percent of tortoises at each site that tested positive for *M. agassizii* by serology or nasal culture on one or more occasions between 1990 and 1995.

seropositive DTNA tortoises and no seropositive tortoises at Ivanpah.

Thirty-six (of 844) nasal cultures from 22 tortoises (20% of all tortoises) were positive for *M. agassizii*. No tortoises at DTNA were culture-positive for *M. agassizii* compared with 39.4% of Goffs tortoises and 28.1% of Ivanpah tortoises (Fig. 4). Eight Goffs tortoises and one Ivanpah tortoise had ≥ 2 positive cultures (range two to six). Male tortoises were significantly more likely to be culture-positive than female tortoises at Goffs ($\chi^2=5.27$, $P=0.0217$). Forty-seven percent of Goffs tortoises with positive mycoplasma cultures were heteropenic (<500 cells/ μ l) in 1990–91. Fifteen of 22 tortoises (68%) with positive nasal cultures for *M. agassizii* were seronegative for *M. agassizii*. The number of positive cultures more than doubled between 1990–91 ($n=5$, 2.7%) and 1993–94 ($n=14$, 39%).

One hundred fifty-five (of 798) nasal cultures from 67 tortoises (62% of all tortoises) had moderate to heavy growth of *P. testudinis*, which was significantly more prevalent ($\chi^2=7.34$, $P=0.0255$) in Ivanpah tortoises (23.7%), than in Goffs (19.4%) or DTNA (14.5%) tortoises. Tortoises at Ivanpah with moderate to heavy *P. testudinis* growth had significantly ($t=2.03$, $P=0.0430$) higher heterophil counts

($4,077 \pm 4,837/\mu$ l versus $3,167 \pm 2,634/\mu$ l) than tortoises from other sites. At all sites, *P. testudinis* isolation was significantly more likely ($\chi^2=0.18$, $P<0.0001$) to occur in spring (37%) and winter (21.7%) and was significantly less likely in 1993–94 (a dry year) compared with other years ($\chi^2=37.91$, $P<0.0001$). Tortoises with moderate to heavy *P. testudinis* growth had significantly higher globulin concentrations (2.45 ± 0.66 g/dl; $t=3.67$, $P<0.0003$) compared with tortoises with little or no *P. testudinis* growth (2.23 ± 0.65 g/dl). Moderate to heavy growth of mixed bacterial flora was found in 389 (of 633) cultures from 94 tortoises, with 59% of heavy growth in winter and spring. Mixed flora growth was less in 1993–94 compared with other years ($\chi^2=121.48$, $P<0.0001$).

Hematology and clinical chemistry

Hematologic abnormalities were observed in 53 (49%) tortoises at least once during the study period (Table 4). A higher number of DTNA tortoises had lymphocytosis in spring 1995 ($\chi^2=13.44$, $P=0.0021$) compared both with spring of other years and with tortoises at other sites. Significantly more ($\chi^2=7.41$, $P=0.0246$) tortoises at the DTNA ($n=10$) and Ivanpah ($n=14$) had leukocytosis or heterophilia compared with tortoises at Goffs ($n=4$). Tortoises I13F and I22M had heterophilia (range, 8,380–13,391 cells/ μ l) on two occasions, 12–14 mo apart. Tortoise I11M had marked heterophilia (34,960/ μ l). Tortoise D33M had heterophilia on three occasions, concurrent with lymphocytosis or monocytosis. Basophilia was less frequently observed ($n=5$) and was more likely to occur in spring. Seven Goffs tortoises had heteropenia. Of tortoises with heteropenia, lymphopenia, or basopenia, 19 of 21 were observed in 1990–91, primarily in winter and spring. Tortoises with hematologic abnormalities were significantly more likely to show clinical signs of URTD ($\chi^2=4.54$, $P=0.033$) compared with tortoises without hematologic abnormalities.

TABLE 4. Hematologic abnormalities in free-ranging desert tortoises between 1990 and 1995.

Analyte	Cut-off values	Range of abnormal values	No. of tortoises				Comments
			DTNA	Goffs	Ivanpah	Total	
PCV ^a (%) or hemoglobin (Hb; g/dl)	PCV <18–21 (male) PCV <15.0 (female) Hb <4.0	PCV 16–19% (male) PCV 8.5% (female) Hb 1.5–3.6	7 ^b	1	2 ^b	10 ^b	Four tortoises had both low PCV and low Hb
RBC ^a ($\times 10^6/\mu\text{l}$)	>1.0	1.4–1.9	1	3	0	4	All Goffs were in spring '93
MCV ^a (fl)	<197.0	97.1–183.2	2	3	0	5	All in fall '91 and '95
MCH ^a (pg)	<40.0	28.8–39.0	1	6	0	7	Most in spring '93
MCHC ^a (%)	<18.0	14.6–17.9	2	3	0	5	All in spring
WBC ^a (μl)	$\geq 12,000$	12,000–40,000	10 ^b	4 ^c	14 ^b	28 ^b	
Heterophils (μl)	$\geq 8,000$	8,000–20,000	7 ^b	2 ^c	10 ^b	19 ^b	
Lymphocytes (μl)	<500	73–420	0	7 ^{c,d}	3	10	All but one in 1990–91
	>5,000	5,078–16,000	9 ^c	0	1	10	All DTNA were in spring '95
	<20 (<30 summer)	0–26	4	2	7 ^b	13	Most in 1990–91
Basophils (μl)	>5,000	5,283–17,760	1	2	2	5	Usually in spring
	<20 (<30 summer)	11–26	2	1	1	4	All in 1990–91
Azurophils (μl)	>1,500	1,570–2,505	4	2 ^b	0	6 ^b	All in winter or fall
Eosinophils (μl)	>1,000	1,739	0	0	1	1	
Monocytes (μl)	>800	847–3,149	2	2	1	5	
Total			52 ^b	38 ^b	42 ^b	115 ^b	

^a PCV = packed cell volume; RBC = red blood cells; MCV = mean cell volume; MCH = mean cell hemoglobin; MCHC = mean cell hemoglobin concentration; WBC = white blood cells.

^b Some tortoises had multiple abnormal values.

^c Significantly different than other sites ($P < 0.03$).

^d Three tortoises also were leukopenic.

Thrombocytes were clumped or considered adequate in all specimens. Parasites of RBCs were not observed in any tortoise. Slight (1+) polychromasia was observed in nine tortoises at the DTNA and 11 tortoises at Goffs in winter or spring. Moderate (2+) to marked (3+) polychromasia was observed in six DTNA tortoises in winter 1995, without anemia. In winter 1993, tortoise D26F had marked, microcytic, hypochromic, regenerative anemia (PCV=8.5%, Hb=1.5 mg/dl, MCV=113.9 fL, MCH=39.0 pg, MCHC=15.9 g/dl, 2+ polychromasia), with leukocytosis (WBC=18,610/ μ l) and heterophilia (17,307/ μ l). This tortoise remained anemic in 1993–94 (Hb=3.2 g/dl), had basophilia (5,283 cells/ μ l) in 1994–95, and was seropositive for *M. agassizii* for 4 consecutive years.

Biochemical abnormalities were observed in 61 (56%) tortoises at least once during the study period (Table 5). Tortoises at Goffs were significantly more likely to have increased AST activity ($\chi^2=9.23$, $P=0.0099$) and electrolyte abnormalities ($\chi^2=12.74$, $P=0.0017$) compared with tortoises at other sites. In addition, three of four tortoises with increased bile acids or bilirubin concentrations were from Goffs. Bile acids concentrations were high in three Goffs tortoises in summer 1994, coincident with the death of five other Goffs tortoises. Tortoises from DTNA were more likely to have low magnesium values ($\chi^2=6.25$, $P=0.0440$) than tortoises at other sites, especially in winter 1995. Hypophosphatemia ($\chi^2=7.39$, $P=0.0066$) and hypomagnesemia ($\chi^2=9.97$, $P=0.0028$) were more likely to occur in male tortoises compared with female tortoises, and neither of these abnormalities were observed in Goffs tortoises.

Six tortoises had marked, persistent azotemia (BUN>100 mg/dl); four of these (D07M, G32F, I08M, I36M) also were hyperosmolar and three of these four were found dead by the next sampling period (Fig. 5). Tortoises D7M and I8M had a necropsy diagnosis of urologic disease, as previously described. The BUN values in

two tortoises (I36M, G32F) with severe azotemia decreased to within the reference interval after three to six sampling periods, respectively; tortoise G32F was found dead about 2 yr later. Concurrent laboratory abnormalities in tortoises with severe azotemia included hypophosphatemia ($n=3$), anemia ($n=3$), hyperchloremia ($n=2$), and heterophilia ($n=2$). Three additional tortoises (I2M, D36M, D40M) had moderate but persistent azotemia (range 63–76 mg/dl) for two to three consecutive seasons beginning in summer or fall 1994 (a dry period) and persisting through hibernation in 1995 (a wet winter). Eleven additional tortoises at Goffs and one at DTNA had mild transient increases in BUN (range 17–77 mg/dl).

Dehydrated tortoises, i.e., those with clinical and biochemical (azotemia or hyperbilirubinemia) evidence of dehydration were considered as a group. Thirty-six tortoises were dehydrated on at least one occasion, including 11 at DTNA, 16 at Goffs, and nine at Ivanpah. Compared with hydrated tortoises, dehydrated tortoises had significantly higher BUN (57.6 ± 9.0 vs. 12.2 ± 0.5 mg/dl), uric acid (5.6 ± 0.3 vs. 4.7 ± 0.1 mg/dl), total bilirubin (0.16 ± 0.02 vs. 0.12 ± 0.01 mg/dl), osmolality (312.4 ± 6.0 vs. 284.8 ± 0.8 mOsm/kg), sodium (150.6 ± 1.9 vs. 143.2 ± 0.4 mmol/l), and chloride (118.8 ± 1.6 vs. 112.4 ± 0.4 mmol/l) concentrations. Dehydration more often affected male tortoises ($\chi^2=10.35$, $P<0.0001$) and primarily occurred in 1990–91 (DTNA, Goffs) and 1994–95 (DTNA, Ivanpah). Dehydrated tortoises had a greater prevalence of oral lesions ($\chi^2=11.40$, $P<0.0007$) and positive nasal cultures for *M. agassizii* ($\chi^2=12.30$, $P<0.0005$), but were not more likely to be seropositive ($\chi^2=0.008$, $P=0.9268$).

Sensitivity, specificity, and predictive values

Significant associations between laboratory and clinical variables were tested for their ability to detect or predict outcome (death, mycoplasmosis, oral lesions, moderate to severe shell disease). Marked or persistent azotemia had low sensitivity but

TABLE 5. Clinical biochemical abnormalities in free-ranging desert tortoises between 1990 and 1995.

Analyte	Cut-off values	Range of abnormal values	No. of tortoises				Comments
			DTNA	Goffis	Ivanpah	Total	
Enzymes							
Alkaline phosphatase (U/l)	>125	135–852	1	2	0	3	All in seasons other than spring All Goffis were in spring
Alanine aminotransferase (U/l)	≥10	14–87	1 ^a	2 ^a	3	6 ^a	
Aspartate aminotransferase (U/l)	>150	170–612	1	7 ^{a,b}	1	9 ^a	
Organics							
Bile acids (μg/ml)	>60	63.0–186.6	1	3	0	4	Goffis were in summer 1994 Goffis were in summer 1992
Bilirubin, total (mg/dl)	>0.4	0.5–0.6	1	3	0	4	
Blood urea nitrogen (mg/dl)	<100	17–77	3 ^a	11	1 ^a	15 ^a	See Figure 5 Females only
Blood urea nitrogen (mg/dl) ^c	>100	108–373	3 ^a	1 ^a	2 ^a	6 ^a	
Cholesterol (mg/dl)	Seasonally dependent	312–543	0	2	1	3	
Globulins (g/dl) ^d	>4.0	4.0–4.7	0	2 ^a	2 ^a	4 ^a	Ivanpah in winter '93
Glucose (mg/dl)	>200	202–293	0	2	5	7	
Total protein (g/dl)	>5.4	5.6–6.3	0	2 ^a	2 ^a	4 ^a	Males only in spring '95
Triglycerides (mg/dl)	>164	255–554	5	0	1	6	
Uric acid (mg/dl)	≤1.3	0–1.0	2	2	0	4	
Minerals							
Iron (μg/dl)	>150	189–292	1	2	2	5	Most in winter '95 Males only
Magnesium (mg/dl)	≤3.0	2.7–3.0	6 ^a	0 ^b	2 ^a	8 ^a	
Phosphorus (mg/dl)	<0.5 to 0.8 mg/dl	0.2–0.7	4	0 ^b	7 ^a	11 ^a	
Electrolytes							
Osmolality (mg/kg) ^e	≥400	400–481	1	1	2 ^a	4 ^a	All in summer '91
Osmolality (mg/kg)	<235	168–234	0	2	1	3	
Anion gap (mmol/l)	>29	32–49	0	4	0	4	
Chloride (mmol/l)	>141	144–150	0	2 ^a	3 ^a	5 ^a	Summer or fall
Potassium (mmol/l)	>7.5	7.6–8.9	0	4 ^a	3 ^a	7 ^a	
Total CO ₂ (mmol/l)	<14	3–11	0	3	1 ^a	4 ^a	
Other ^f			3 ^a	6 ^a	3 ^a	12 ^a	Total
Total			33 ^a	63 ^a	42 ^a	138 ^a	

^a Some tortoises had multiple abnormal values.^b Significantly different from other sites ($P<0.05$).^c Two tortoises with increased blood urea nitrogen also had mild hypercreatinemia (0.5 mg/dl).^d These tortoises also had increased total protein concentration.^e These tortoises also had azotemia.^f Individual tortoises had mild hypo- (1) or hyperalbuminemia (1); mild hypoglobulinemia (1); mild hypoglycemia (2); mild hypochloremia (2); mild hyponatremia (2); mild hyperuricaemia (2); and mild hypocalcemia (1).

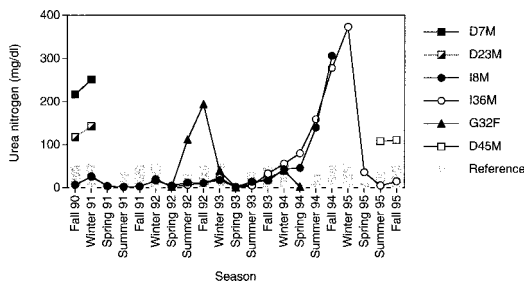


FIGURE 5. Plasma urea nitrogen concentration in six tortoises with severe azotemia (BUN > 100 mg/dl) and three tortoises (D36M, D40M, I02M) with moderate but persistent azotemia (63–76 mg/dl). Open symbols indicate tortoises that were alive at the end of the study; closed symbols indicate tortoises that were found dead; partially open symbols indicate tortoises missing for the remainder of the study.

high specificity for mortality (Table 6). Leukocytosis and heterophilia had low sensitivity but higher specificity for seropositivity. A cut-off value of 10,000 WBC/ μ l resulted in lower specificity (60%), but increased sensitivity to 73%; using a cut-off value of 15,000 cells/ μ l, sensitivity was lower (30%), but specificity increased to 94%. High AST had low sensitivity but high specificity for oral lesions; when tortoises with high AST, ALT, or ALP activity were considered together, sensitivity for oral lesions increased to 60%, with only a slight decrease in specificity (92%); there was no effect on predictive values. Clinical dehydration and weakness had relatively high sensitivity (80%) for identifying tortoises with oral lesions. Positive nasal cultures for *M. agassizii* had relatively high positive predictive values for tortoises with moderate to severe shell disease.

DISCUSSION

Desert tortoise populations in the Mojave Desert have declined precipitously over the last three decades from the cumulative impact of habitat loss and human and disease-related mortality. Diagnosis of disease in live, free-ranging tortoises by evaluation of clinical signs and laboratory test results is complicated by seasonal and environmental effects, particularly because desert tortoises are capable of profound

physiologic adaptations (Nagy and Medica, 1986; Henen et al., 1998). Recent publication of site, season, and sex-specific reference intervals for desert tortoises in the Mojave Desert (Christopher et al., 1999) has made possible evaluation of laboratory data from tortoises with clinical signs of disease. In this study, we evaluated the same three populations of tortoises from which reference values were derived; however, we focused on laboratory data from those tortoises showing clinical and laboratory abnormalities and compared disease patterns by site, season, and year. Because of the low number of tortoises in each group, repeated measures on some tortoises, marked seasonal variation in the concentrations of some analytes, and the tendency for tortoises to have intermittent but multiple abnormalities over time, comparisons between affected and unaffected animals were helpful in identifying associations among clinical and laboratory abnormalities during the 5 yr study period. While important and useful for identifying disease “cues” in a population, these comparisons did not necessarily indicate direct associations between laboratory data and specific disorders. In addition, because of the large number of comparisons made, the probability for type I errors was increased, such that statistical comparisons should be interpreted cautiously.

Three major disease abnormalities were observed in tortoises in this study: URTD, cutaneous dyskeratosis, and urinary tract disease. These same disorders predominated in a pathologic study of 24 dead or dying tortoises from the Mojave and Colorado deserts (Homer et al., 1998). To our knowledge, the oral lesions seen primarily in Goffs tortoises have not previously been described in free-ranging tortoises in the Mojave, Colorado, or Sonoran deserts. The manifestation, prevalence, and apparent impact of these disease conditions differed substantially among sites. Compared with other sites, mortality, especially of female tortoises, was twice as high at Goffs, where there was a combined impact of se-

TABLE 6. Sensitivity, specificity, and predictive value of selected clinical and laboratory abnormalities (all sites combined).

Disease outcome	Laboratory or clinical abnormality	P value	χ^2	Sensitivity (%)	Specificity (%)	PPV ^a (%)	NPV ^b (%)
Death	Marked azotemia (BUN > 100 mg/dl)	0.0454	4.00	17	97	60	79
	Persistent azotemia (two consecutive captures)	0.0268	4.90	22	95	57	80
Mycoplasmosis	Leukocytosis	0.0187	5.53	44	79	46	78
Seropositivity	Heterophilia ^c	0.0088	6.87	19	97	71	75
	Clinical dehydration or weakness	0.0018	9.76	59	76	38	88
Positive nasal culture ^d	Hyperglobulinemia	0.0057	7.64	14	99	75	82
	Clinical dehydration or weakness	0.0005	12.03	80	73	24	97
Oral ulcers ^d	Positive nasal <i>M. agassizii</i>	<0.0001	16.73	70	85	32	97
	High aspartate aminotransferase	0.0001	14.47	40	95	44	94
	Electrolyte abnormalities	0.0104	6.37	50	84	24	94
	Hyperbilirubinemia	<0.0001	21.37	30	99	75	93
Moderate to severe shell lesions ^e	Positive nasal <i>M. agassizii</i>	<0.0001	15.98	40	94	86	62

^a Positive predictive value, i.e., the likelihood that a tortoise with that abnormality will have the outcome indicated.^b Negative predictive value, i.e., the likelihood that a tortoise without that abnormality will not have the outcome indicated.^c Results primarily reflect Ivapah tortoises.^d Results primarily reflect Goff's tortoises.^e Results primarily reflect Goff's and Ivapah tortoises.

vere shell disease, culture-positive URTD, and oral lesions.

Clinical signs of URTD were similar to those described previously for mycoplasmosis (Jacobson et al., 1991; Lederle et al., 1997; Brown et al., 1999). Draining chin glands were not considered a sign of URTD in this study, but may have been abnormal when observed in female tortoises or in winter. Upper respiratory signs can be seen in respiratory diseases other than mycoplasmosis (such as the acute pneumonia in tortoise G30F), however, the persistence of clinical signs over years in association with seropositivity or positive nasal cultures strongly suggested that *M. agassizii* was the most likely cause of most if not all of the respiratory disease in these tortoises.

Upper respiratory tract disease in the DTNA population has evolved from an acute, epidemic disease with high mortality to a chronic disease with variable morbidity, low mortality, and a high seroconversion rate for antibodies to *M. agassizii* (Brown et al., 1999). Nearly one-half of DTNA tortoises had serologic evidence of exposure to *M. agassizii*, a higher prevalence than either of the other two sites and than other desert tortoise populations (Lederle et al., 1997). Tortoises with *M. agassizii* infection may remain seropositive without overt disease (Brown et al., 1994); however, two-thirds of DTNA tortoises had intermittent clinical signs of URTD. Tortoises at DTNA never had positive culture results for *M. agassizii*, possibly because *M. agassizii* may be shed from the nasal epithelium (and thus be less likely to be cultured) by the time antibodies develop and are detected serologically. The youth of the DTNA population was consistent with loss of up to 90% of adult tortoises due to URTD (between 1988 and 1996), and predation and human intervention (between 1979–1988) (Peterson, 1994; Berry, 1997; Brown et al., 1999). Predator attacks continue to be an important cause of morbidity in DTNA tortoises, based on the prevalence of bite wounds.

Increased frequency of clinical signs in 1994–95 may indicate recrudescence of URTD in the DTNA population and impending spread among younger, more susceptible tortoises.

Lymphocytosis, heterophilia, and azurophilia in DTNA tortoises were consistent with immunologic responses to infection. Lymphocytosis occurred concurrent with resurgence in clinical signs of URTD, perhaps exacerbated by drought the previous year. The nasal passages of tortoises with mycoplasmosis contain subepitheloid lymphoid aggregates and heterophilic infiltrates (Jacobson et al., 1991). Mild anemia in a few DTNA tortoises may have been associated with chronic infection. Interestingly, Goffs tortoises rarely had hematologic evidence of inflammation (e.g., heterophilia), compared with Ivanpah and DTNA tortoises.

Poor correlation between *M. agassizii* culture and serology results suggested that Goffs tortoises may be infected with a different strain or isolate of mycoplasma than tortoises at other sites, one perhaps less likely to be detected by the ELISA test. Recent molecular studies of seven *Mycoplasma* isolates from clinically ill desert tortoises revealed differences in 16S ribosomal RNA nucleotide sequences, although serologic crossreactivity occurred (Brown et al., 2001). Discrepancies between serologic and culture results also could indicate genetic or environmental traits that alter tortoise response to disease. Re-evaluating culture and serologic results on surviving Goffs tortoises would be useful for determining whether nasal growth of *M. agassizii* remains high in this population and/or whether more Goffs tortoises are now seroconverting. The higher prevalence of positive cultures in male tortoises is consistent with the increased beak-to-beak contact between fighting males.

The oral lesions in nearly one-fourth of Goffs tortoises and two Ivanpah tortoises were a new disease finding of substantial concern. Oral lesions were significantly as-

sociated with positive *M. agassizii* nasal cultures, and as such may be a unique manifestation or complication of mycoplasmosis. Viral infection is another possible cause, because similar diphtheritic plaques have been described in gopher tortoises and Mediterranean tortoises with pathogenic herpesvirus infections (Jacobson, 2000; Origgi et al., 2001). The clustering of oral lesions and positive *Mycoplasma* cultures in a single dry year, and concurrent dehydration in tortoises with oral lesions suggest that environmental stress also may have played a role. Other causes of oral lesions, such as infection secondary to cactus spine trauma (Homer et al., 1998) could not be excluded.

Cutaneous dyskeratosis, most severe in Goffs tortoises, is characterized by greyish-white, roughened, and flaky areas that most severely affect the plastron. It has been associated with high mortality of desert tortoises on the Chuckwalla Bench Area of California (Jacobson et al., 1994; Berry, 1997). Necropsy results in a subsequent study showed a number of tortoises from different locations in the Mojave and Colorado deserts with cutaneous dyskeratosis as well as shell necrosis (Homer et al., 1998). Jacobson et al. (1994) suggested nutrient deficiency or heavy metal toxicosis as a cause of cutaneous dyskeratosis. The fact that larger, older tortoises in this study had more severe shell lesions supports a chronic, cumulative problem. The white discolored areas seen more often in wet seasons and years were suggestive of fungal colonization, which has been reported previously as causing opportunistic infection secondary to cutaneous dyskeratosis (Homer et al., 1998). Concurrent positive *M. agassizii* cultures, oral lesions, and hyperglobulinemia in Goffs tortoises suggest chronic infection or antigenic stimulation could be a factor in the pathogenesis of cutaneous dyskeratosis. Differences in the soluble plastron scute proteins of desert tortoises with mycoplasmosis, urolithiasis, and inflammation suggest that systemic disease may affect

keratinization (Homer et al., 2001). Of 30 tortoises (from >150) remaining on an adjacent study site in Goffs in 2000, most have moderate to severe shell disease (Berry, 2000).

Tortoises at Goffs were more likely than other tortoises to have laboratory evidence of hepatic disease, including increased bile acids concentration, which are specific for hepatic insufficiency (Divers, 2000a). Two tortoises recently necropsied at Goffs had liver atrophy, a decrease in the size and number of hepatocytes, and in overall hepatic mass (Homer and Berry, pers. comm.), which could result in increased bile acids concentration. In addition, bile acids concentration was very high (670 µg/ml) in a severely dehydrated tortoise (Berry et al., 2002). Hepatic lipidosis, degeneration, and hemosiderosis are commonly observed in tortoises and other reptiles secondary to anorexia, and may have contributed to increased AST, ALT, and ALP activities in tortoises at Goffs. Hyperglobulinemia also is a feature of chronic hepatic disease.

Drought is a natural part of the desert tortoise's environment, but when combined with disease or habitat loss, may contribute to additional disease problems and mortality (Peterson 1996). Clinical signs of URTD, lower leukocyte counts, positive nasal cultures of *M. agassizii*, and mild to moderate azotemia were more commonly seen in 1993–94, a year of below-normal annual and winter precipitation. Heteropenia previously has been associated with drought and starvation (Berry et al., 2002). Tortoises entering hibernation in a drought year may be physiologically compromised, because clinical signs of URTD and heteropenia were noted at the time of emergence from hibernation in 1990–91 and 1994–95, years following a period of drought. Most dehydrated tortoises and most deaths at the DTNA and Ivanpah also occurred in 1990–91 and 1994–95, years following dry winters. Dehydration in tortoises at Goffs

may have increased their susceptibilities to the oral lesions.

Azotemia was the most common laboratory abnormality observed. It is likely that the mild transient azotemia in several tortoises at Goffs was evidence of physiologic extreme rather than disease, because it occurred in multiple tortoises during dry years or seasons. Healthy Goffs tortoises showed marked physiologic alterations in relation to periodic drought and summer precipitation, including sharp changes in electrolyte, osmolality, BUN, and anion gap values (Christopher et al., 1999). Drought causes urine retention to conserve water and urea and can cause BUN values of up to 60 mg/dl in healthy desert tortoises without clinical dehydration (Christopher et al., 1999).

Tortoises with severe azotemia (substantially higher than other tortoises at the site) or persistent azotemia (even through relatively wet seasons) more likely had decreased renal function due to severe dehydration (prerenal azotemia, perhaps due to inability to access water due to disease or other barriers), urolithiasis (postrenal azotemia), or renal disease (renal azotemia). These underlying mechanism of azotemia are closely related, especially in tortoises, and may be difficult to differentiate. A desert tortoise trapped for 11 mo in its burrow had a BUN of 259 mg/dl and an osmolality of 395 mOsm/kg (Christopher, 1999). Severely dehydrated tortoises had BUN values (range 88.7–640 mg/dl), similar to those seen here (Berry et al., 2002). Clinically dehydrated tortoises in this and other studies often have other laboratory abnormalities, including anemia (rather than polycythemia), heteropenia, hyperbilirubinemia, hyperosmolality, hypernatremia, hyperchloremia, hypocalcemia, and hypophosphatemia (Jacobson et al., 1991; O'Connor et al., 1994; Christopher, 1999; Berry et al., 2002).

Urolithiasis causes azotemia due to the inability of the kidney to sufficiently excrete urea, and is more likely to develop in dehydrated tortoises (Berry et al., 2002).

The two tortoises with urolithiasis in this study had BUN values ranging from 71–306 in the season preceding death. Interestingly, both of these tortoises had multiple incidences of mild but worsening azotemia (25–140 mg/dl) in earlier seasons, likely indicating early development of uroliths. Uroliths may develop from prolonged retention of urine and excessive crystal formation, primarily in dehydrated tortoises, which have thick, sludged urine, as seen in tortoise D40M. Uroliths may contribute to renal failure by obstructing urination, but do not necessarily cause death. Several tortoises with moderate to marked azotemia in this study also had inflammation, including heterophilia, azurophilia, or lymphocytosis, which has been observed in tortoises with bacterial or protozoal infections of the kidneys (Jackson 1991; Homer et al., 1998; Divers, 2000b).

High BUN concentration was a good indicator of decreased renal function, but did not always predict mortality. In tortoise I36M, an extremely high BUN value quickly normalized with the onset of winter rains, possibly coinciding with available drinking water or with the passage of small uroliths. However, because four of nine tortoises with severe or persistent azotemia died, and because three of these four had necropsy evidence of urolithiasis or bladder infection, underlying disease should be strongly considered in the differential diagnosis of tortoises with severe or persistent azotemia.

Hypophosphatemia has been described previously in ill tortoises (Jacobson et al., 1991; Christopher, 1999), and is likely due to decreased food intake. There was no correlation between hypophosphatemia and disease in this study. Low phosphorus values were usually observed in winter following a drought year, consistent with changes in healthy tortoises (Christopher et al., 1999). Abnormalities in plasma magnesium, triglyceride, and iron concentrations were seasonal and also may have been diet related, but the low number of

measurements available limited conclusions.

Tortoises at Ivanpah had disease type and severity intermediate between that of DTNA and Goffs, including intermediate severity of cutaneous dyskeratosis. Like Goffs tortoises, a few Ivanpah tortoises had oral lesions and positive nasal mycoplasma cultures. Like DTNA tortoises, Ivanpah tortoises often were seropositive and had inflammatory leukograms. Inflammation (heterophilia and hyperglobulinemia) and clinical signs of URTD were more likely to be seen in Ivanpah tortoises with heavy *P. testudinis* growth. Although the role of *P. testudinis* in URTD is not fully understood, it may be synergistic with mycoplasmosis or contribute to secondary infection in tortoises infected with *Mycoplasma* (Jacobson et al., 1991). Although *P. testudinis* can be isolated from the nasal cavity of healthy tortoises, certain isolates have been recovered solely from tortoises with URTD (Snipes et al., 1995). Unlike *Mycoplasma*, *Pasteurella* growth was less severe in the drought year.

In summary, URTD, cutaneous dyskeratosis, and oral lesions comprised the major disease conditions observed in three populations of free-ranging Mojave Desert tortoises. Azotemia was the most common laboratory abnormality, and, when severe or persistent, it was often associated with underlying urolithiasis or bladder infection. With few exceptions, routine hematologic and biochemical laboratory tests had poor sensitivity and low predictive values in detecting or monitoring disease. Predictive values are affected by the prevalence of disease, however, and because of the low numbers of tortoises with specific diseases, caution must be exercised in interpreting these results. The severe problems associated with positive *Mycoplasma* cultures, oral lesions, dehydration, and moderate to severe shell disease in the tortoises at Goffs were of particular concern because of their potential for cumulative impact on the population. A population of Goffs tortoises ~2 km from our study site,

considered the "gold standard" for a healthy population since 1979, has suffered recent 92–96% decreases in tortoise density between 1994 and 2000 (Berry and Medica 1995; Berry 2000). In light of these findings, disease and laboratory abnormalities identified in the present study may be important clues to the demise of the neighboring Goffs population. Further investigation into different strains of *Mycoplasma* organisms, histopathology of oral lesions, and research into the pathogenesis of shell disease, hepatic disease, and urologic disease are critical for better understanding these problems.

ACKNOWLEDGMENTS

This work was funded by the Department of the Interior, Bureau of Land Management Contract Nos. B950-C1-0060 (Christopher), YA-651-CT0-340079 (Nagy), and CA950-CT0-47 (APL Laboratories) and National Biological Service Contract No. 14-48-0006-95-003. Federal and state permits were issued to and administered by K. Berry. The hard work and dedication of the following individuals made this work possible: C. C. Peterson, I. A. Girard, J. Parinayakosol, B. S. Wilson, I. R. Wallis, A. Ancel, M. A. Wilson, and C. Tran. The authors also wish to thank M. Brown, E. R. Jacobson, V. Dickinson, J. Conway-Klaassen, and J. Klaassen for their contributions to this work.

LITERATURE CITED

- BERRY, K. H. 1997. Demographic consequences of disease in two desert tortoise populations in California, USA. *In* Proceedings: Conservation, restoration, and management of tortoises and turtles, An international conference, J. Van Abbema (ed.). Wildlife Conservation Society Turtle Recovery Program and the New York Turtle and Tortoise Society, pp. 91–99.
- . 2000. Preliminary report on the spring survey of desert tortoises at the Goffs permanent study plot and special project on the effects of roads. US Geological Survey, Western Ecological Research Center, 11 pp.
- , AND M. M. CHRISTOPHER. 2001. Guidelines for the field evaluation of desert tortoise health and disease. *Journal of Wildlife Diseases* 37: 427–450.
- , AND P. MEDICA. 1995. Desert tortoises in the Mojave and Colorado deserts. *In* Our living resources: A report to the nation on the distribution, abundance, and health of U.S. plants, animals, and ecosystems, E. T. LaRoe, G. S. Farris,

- C. E. PUCKETT, P. D. DORAN, AND M. J. MAC (eds.). US Department of the Interior, National Biological Service, Washington, D. C. pp. 135–137.
- , AND A. P. WOODMAN. 1984. Preliminary investigations of shell wear in determining adult age groups in desert tortoises. Appendix 4. In *The status of the desert tortoise (Gopherus agassizii) in the United States*. K. H. Berry (ed.). Report to US Fish and Wildlife Service from the Desert Tortoise Council on Order No. 11310–0083–81. A4-1 to A4-54.
- , E. K. SPANGENBERG, B. L. HOMER, AND E. R. JACOBSON. In press. Deaths of desert tortoises following periods of drought and research manipulation. *Chelonian Conservation and Biology*.
- BROWN, M. B., I. M. SCHUMACHER, P. A. KLEIN, K. HARRIS, T. CORRELL, AND E. R. JACOBSON. 1994. *Mycoplasma agassizii* causes upper respiratory tract disease in the desert tortoise. *Infection and Immunity* 62: 4580–4586.
- , K. H. BERRY, I. M. SCHUMACHER, K. A. NAGY, M. M. CHRISTOPHER, AND P. A. KLEIN. 1999. Seroepidemiology of upper respiratory tract disease in the desert tortoise in the western Mojave desert of California. *Journal of Wildlife Diseases* 35: 716–727.
- , D. R. BROWN, P. A. KLEIN, G. S. MC- LAUGHLIN, I. M. SCHUMACHER, E. R. JACOBSON, H. P. ADAMS, AND J. G. TULLY. 2001. *Mycoplasma agassizii* sp. nov., isolated from the upper respiratory tract of the desert tortoises (*Gopherus agassizii*) and the gopher tortoise (*Gopherus polyphemus*). *International Journal of Systematic and Evolutionary Microbiology* 51: 413–418.
- CHRISTOPHER, M. M. 1999. Physical and biochemical abnormalities associated with prolonged entrapment in a desert tortoise. *Journal of Wildlife Diseases* 35: 361–366.
- , K. H. BERRY, I. R. WALLIS, K. A. NAGY, B. T. HENEN, AND C. C. PETERSON. 1999. Reference intervals and physiologic alterations in hematologic and biochemical values of free-ranging desert tortoises in the Mojave desert. *Journal of Wildlife Diseases* 35: 212–238.
- DIVERS, S. J. 2000a. Reptilian liver and gastrointestinal testing. In *Laboratory medicine—avian and exotic pets*, A. Fudge (ed.). W. B. Saunders, Philadelphia, pp. 205–209.
- . 2000b. Reptilian renal and reproductive disease diagnosis. In *Laboratory medicine—avian and exotic pets*, A. Fudge (ed.). W. B. Saunders, Philadelphia, pp. 217–222.
- HENEN, B. T., C. C. PETERSON, I. R. WALLIS, K. H. BERRY, AND K. A. NAGY. 1998. Effects of climatic variation on field metabolism and water relations of desert tortoises. *Oecologia* 117: 365–373.
- HOMER, B. L., K. H. BERRY, M. B. BROWN, AND E. R. JACOBSON. 1998. Pathology of spontaneously occurring diseases in free-ranging California desert tortoises (*Gopherus agassizii*). *Journal of Wildlife Diseases* 34: 508–523.
- , C. LI, K. H. BERRY, N. D. DENSLOW, E. R. JACOBSON, R. H. SAWYER, AND J. E. WILLIAMS. 2001. Soluble scute proteins of healthy and ill desert tortoises (*Gopherus agassizii*). *American Journal of Veterinary Research* 62: 104–110.
- JACKSON, O. F. 1991. Reptiles, Part One. Chelonians. In *Manual of exotic pets*, P. H. Beynon and J. E. Cooper (eds.). British Small Animal Veterinary Association, Cheltenham, Gloucestershire, UK, pp. 221–243.
- JACOBSON, E. R. 2000. Reptilian viral diagnostics. In *Laboratory medicine—avian and exotic pets*, A. Fudge (ed.). W. B. Saunders, Philadelphia, pp. 229–235.
- , T. J. WRONSKI, J. SCHUMACHER, C. REGGIARDO, AND K. H. BERRY. 1994. Cutaneous dyskeratosis in free-ranging desert tortoises, *Gopherus agassizii*, in the Colorado desert of southern California. *Journal of Zoo and Wildlife Medicine* 25: 68–81.
- , J. M. GASKIN, M. B. BROWN, R. K. HARRIS, C. H. GARDINER, J. L. LAPOINTE, H. P. ADAMS, AND C. REGGIARDO. 1991. Chronic upper respiratory tract disease of free-ranging desert tortoises (*Xerobates agassizii*). *Journal of Wildlife Disease* 27: 296–316.
- KLAASSEN, J. 1991. Necropsy report for male tortoise D7M. Report from APL Veterinary Laboratories, Las Vegas, Nevada, to U.S. Department of the Interior, Bureau of Land Management, Riverside, California, 5 pp.
- LEDERLE, P. E., K. R. RAUTENSTRAUCH, D. L. RAKESTRAW, K. K. ZANDER, AND J. L. BOONE. 1997. Upper respiratory tract disease and mycoplasmosis in desert tortoises from Nevada. *Journal of Wildlife Diseases* 33: 759–765.
- NAGY, K. A., AND P. A. MEDICA. 1986. Physiological ecology of desert tortoises in southern Nevada. *Herpetologica* 42: 73–92.
- NATIONAL OCEANIC AND ATMOSPHERIC ADMINISTRATION. 1989–1995. Climatological data for California, Vol. 93–99, National Climatic Data Center, Asheville, North Carolina.
- O'CONNOR, M. P., J. S. GRUMBLES, R. H. GEORGE, L. C. ZIMMERMAN, AND J. R. SPOTILA. 1994. Potential hematological and biochemical indicators of stress in free-ranging desert tortoises and captive tortoises exposed to a hydric stress gradient. *Herpetological Monographs* 8: 5–26.
- ORIGGI, F., P. KLEIN, C. ROMERO, AND E. JACOBSON. 2001. Transmission study with a tortoise herpesvirus (THV) in Greek tortoises. *Proceedings, Desert Tortoise Council Symposium*, Tucson, Arizona, pp. 31–33.
- PETERSON, C. C. 1994. Different rates and causes of high mortality in two populations of the threatened desert tortoise *Gopherus agassizii*. *Biological Conservation* 70: 101–108.

- . 1996. Anhomeostasis: Seasonal water and solute relations in two populations of the desert tortoise (*Gopherus agassizii*) during chronic drought. *Physiological Zoology* 69: 1324–1358.
- RASKIN, R. E. 2000. Reptilian complete blood count. In *Laboratory medicine—avian and exotic pets*, A. Fudge (ed.). W. B. Saunders, Philadelphia, pp. 193–197.
- SCHUMACHER, I. M., M. B. BROWN, E. R. JACOBSON, B. R. COLLINS, AND P. A. KLEIN. 1993. Detection of antibodies to a pathogenic mycoplasma in desert tortoises (*Gopherus agassizii*) with upper respiratory tract disease. *Journal of Clinical Microbiology* 31: 1454–1460.
- SNIPES, K. P., R. W. KASTEN, J. M. CALAGOAN, AND J. T. BOOTHBY. 1995. Molecular characterization of *Pasteurella testudinis* isolated from desert tortoises (*Gopherus agassizii*) with and without upper respiratory tract disease. *Journal of Wildlife Diseases* 31: 22–29.
- US FISH AND WILDLIFE SERVICE. 1990. Endangered and threatened wildlife and plants; Determination of threatened status for the Mojave population of the desert tortoise. *Federal Register* 44(63):12178–12191.
- US FISH AND WILDLIFE SERVICE. 1994. Desert tortoise (Mojave population) recovery plan. U.S. Fish and Wildlife Service, Portland, Oregon, 73 pp.

Received for publication 25 October 2001.