

Natural Infection of *Cryptosporidium muris* (Apicomplexa: Cryptosporiidae) in Siberian Chipmunks

Authors: Hůrková, Lada, Hajdušek, Ondřej, and Modrý, David

Source: Journal of Wildlife Diseases, 39(2) : 441-444

Published By: Wildlife Disease Association

URL: <https://doi.org/10.7589/0090-3558-39.2.441>

BioOne Complete (complete.bioone.org) is a full-text database of 200 subscribed and open-access titles in the biological, ecological, and environmental sciences published by nonprofit societies, associations, museums, institutions, and presses.

Your use of this PDF, the BioOne Complete website, and all posted and associated content indicates your acceptance of BioOne's Terms of Use, available at www.bioone.org/terms-of-use.

Usage of BioOne Complete content is strictly limited to personal, educational, and non - commercial use. Commercial inquiries or rights and permissions requests should be directed to the individual publisher as copyright holder.

BioOne sees sustainable scholarly publishing as an inherently collaborative enterprise connecting authors, nonprofit publishers, academic institutions, research libraries, and research funders in the common goal of maximizing access to critical research.

Natural Infection of *Cryptosporidium muris* (Apicomplexa: Cryptosporiidae) in Siberian Chipmunks

Lada Hůrková,^{1,3} Ondřej Hajdušek,² and David Modrý^{1,2,1} Department of Parasitology, University of Veterinary and Pharmaceutical Sciences, Palackého 1-3, 612 42 Brno, Czech Republic; ² Institute of Parasitology, Academy of Sciences of the Czech Republic, Branišovská 31, 370 05 České Budějovice, Czech Republic; ³ Corresponding author (email: lhurkova@vfu.cz)

ABSTRACT: Coprologic examination of nine Siberian chipmunks (*Eutamias sibiricus*) imported from Southeast Asia revealed infection with *Cryptosporidium* sp. Experimental inoculation of BALB/c mice proved their susceptibility to the infection. Infected mice shed oocysts 14–35 days postinfection. Oocyst morphology was similar to that reported for *C. muris* in previous studies, oocysts were 8.1 (7.0–9.0)×5.9 (5.0–6.5) μm. Clinical signs were absent in naturally infected chipmunks and experimental mice. Histologic examinations of mice revealed numerous developmental stages of *C. muris* in the glandular stomach. Analysis of partial small subunit rRNA gene sequences confirmed identity of these isolates as *C. muris*. Our results represent the first report of *C. muris* in members of the family Sciuridae.

Key words: BALB/c mice, *Cryptosporidium muris*, *Eutamias sibiricus*, Sciuridae, Siberian chipmunk, SSU rRNA gene.

The genus *Cryptosporidium* (Protista: Apicomplexa) includes several species of protozoan parasites of vertebrates. *Cryptosporidium* species have been isolated from fish, amphibians, reptiles, birds, and mammals including humans. These parasites most commonly attack the digestive tract, though other organ systems may be affected, especially in birds. Although most species predominantly infect the intestine, there is a distinct group of gastric cryptosporidia consisting of *C. muris* in rodents (Tyzzer, 1907, 1910), *C. serpentis* in reptiles (Levine, 1980), *C. (muris) andersoni* in ruminants (Lindsay et al., 2000), *C. galli* in birds (Pavlásek, 1999; Morgan et al., 2001). *Cryptosporidium muris* was described by Tyzzer in 1907 in gastric glands of mice and was later found in other rodents (Iseki, 1986; Pavlásek and Lávicka, 1995; Chalmers et al., 1997; Torres et al., 2000) and a rock hyrax (*Procapra capensis*) (Anderson, 1991). All natural rodent hosts

of *C. muris* belong to the families Muridae and Cricetidae. Thus, this report represents the first record of this pathogen in a member of the family Sciuridae.

Siberian chipmunks (*Eutamias sibiricus*) were obtained from a group imported to the Czech Republic from Southeast Asia by a pet-trader in November 1999. The animals were housed separately in standard plastic cages and were fed commercial rodent food, fruits, and water ad libitum. Fecal samples were collected daily for 2 wk for routine parasitologic examination. Individual samples were concentrated by centrifugation-flotation in modified Sheather's sugar solution (specific gravity 1.30). Samples containing oocysts were mixed with 2.5% aqueous (w/v) potassium dichromate (K₂Cr₂O₇) solution and stored at 4 C. Cryptosporidian oocysts were examined and photographed using Nomarski interference-contrast microscopy using a Provis AX 70 microscope. Measurements were made using a calibrated ocular micrometer and are reported in micrometers as means of 30 oocysts followed by the ranges in parentheses. Oocysts used for transmission studies were concentrated by flotation and the potassium dichromate was removed by repeated centrifugation at 2,000×G for 10 min. Six 4 wk old BALB/c mice (AnLab, Czech Republic) were inoculated by stomach tube with 10⁴ oocysts each. Animals were examined coprologically on day 7, postinfection (DPI) and then daily from DPI 10–42. A single mouse was euthanized and necropsied DPI 7, 14, 21, 28, 35, and 42. Gastric mucosal scrapings and fecal contents were examined for *C. muris* oocysts. Samples of liver, gall bladder, esophagus, stomach

(glandular and non-glandular part), intestines (upper, middle, and lower portions), caecum, colon, kidney, and lungs were collected for histologic examination, fixed in 10% neutral formalin, embedded in paraffin, sectioned, and stained with haematoxylin and eosin.

Oocysts derived from experimental mice were used for DNA isolation. Total DNA was isolated according to Spano et al. (1997) from 3×10^5 purified oocysts. For identification, DNA was amplified using primers CPB-DIAGF: 5'-AAGCTCGTAGTTGGATTTCTG-3', and CPB-DIAGR: 5'-TAAGGTGCTGAAGGAGTAAGG-3' (Johnson et al., 1995). Polymerase chain reaction (PCR) with annealing to the approximately 440 base pair (bp) small subunit (SSU) rRNA gene region was set under conditions according to Johnson et al. (1995), with initial denaturation at 94 C for 5 min, followed by 40 cycles consisting of 94 C for 30 sec, 55 C for 30 sec, and 72 C for 1 min. The program was concluded by final extension at 72 C for 10 min. Positive (*C. parvum*) and negative controls were done. The amplified fragment was cloned (TOPO TA Cloning, Invitrogen, Beckman Coulter, USA) and sequenced using a CEQ 2000 automatic sequencer (Beckman Coulter). The sequence has been deposited in the GeneBank™ database (GenBank, National Center for Biotechnology Information, www.ncbi.nlm.nih.gov/Genbank/, accession number AY029361). Nucleotide sequences obtained from GeneBank were aligned using ClustalW 1.8 (Thompson et al., 1997). Distance-based analysis was performed using PAUP 4.0b8 (Swofford, 1996) under a Kimura-two-parameter sequence evolution model of our isolate and closely related species. The amplified 432 bp internal SSU rRNA gene fragment corresponds to position 602–1,034 of the entire *C. muris* SSU rRNA gene (AF093498). The resulting 390 bp long fragment (without primers) was compared with sequences available in 2001.

Coprologic examination of Siberian

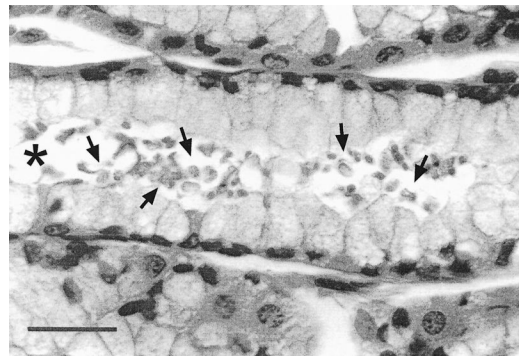


FIGURE 1. Histologic section through gastric mucosa of mice examined at 21 DPI. Note numerous developmental stages of *C. muris* (some marked by arrows) in the lumen (asterisk). Bar=20 μ m.

chipmunks revealed fully sporulated *C. muris*-like oocysts in six animals, unsporulated eimerian oocysts in all animals, and eggs of unidentified nematodes (Strongylida, Oxyurida). Based on morphology and measurements, the eimerian oocysts were *Eimeria asiatici* (Levine and Ivens, 1965). Oocysts of *Cryptosporidium* were morphologically and morphometrically identical to those of *C. muris*. Oocysts were ellipsoidal, $8.1 (7.0-9.0) \times 5.9 (5.0-6.5) \mu$ m, with a shape index (length:width ratio) 1.36 (1.17–1.70). The oocyst wall was thinner than 1μ m, composed of a single colorless layer, a micropyle was absent but oocyst residuum was present, appearing as a cluster of more or less equal granules. Inoculated mice shed oocysts from DPI 14–35, with a peak on DPI 22 and 23. Histologic examination of experimentally infected mice revealed numerous developmental stages in glandular cells of the stomach DPI 14, 21, 28, and 35. Detection of the stages in histologic sections corresponded with the presence of oocysts in feces. Observed histopathologic changes consist of moderate hypertrophy of the stomach wall with dilated gastric glands filled with numerous developmental stages of *Cryptosporidium* (Fig. 1). The glandular cells were flattened, atrophic, and degenerated but inflammatory cells were not seen. Clinical signs were not observed in any infected animal. The prepatent period

of the infection (14 DPI) in experimentally infected mice corresponds roughly with that reported by previous authors. In contrast, patent periods observed by previous researchers varied greatly. Iseki et al. (1989) described oocyst excretion from DPI 6–80, Rhee et al. (1991, 1995) from DPI 6–75, and Taylor et al. (1999) from DPI 10–89. It is possible that observed variability in the prepatent and patent period depends both on the strain of *Cryptosporidium* and the experimental animal used. Results of histologic examination as well as the absence of clinical signs in chipmunks and experimentally infected mice correspond with previous reports (Iseki et al., 1989; Aydın and Özkul, 1996; Taylor et al., 1999).

The SSU rRNA sequence was identical with *C. muris* sequences AF093498 and AF248761. The most related species, *C. andersoni* (AF093496) and *C. serpentis* (AF093499) differ in 6 and 15 bp, respectively. *Cryptosporidium parvum* bovine isolate (AF108864) differs from our isolate by 48 bp, which correlates with the observations of Morgan et al. (2000). This DNA region is useful for identification of the species (Pieniazek et al., 1999), although sequencing of internal transcribed spacer region of the rRNA gene or other genes could provide a more exact identification (Morgan et al., 2000).

Coccidians parasitizing members of the genus *Eutamias* are poorly studied. Recently, Matsui et al. (2000) reported *C. parvum* in these sciurids in China. The present study is the first record of *C. muris* not only in *Eutamias*, but also in members of the family Sciuridae. However, the possibility exists that the described infection was acquired during the transportation through various pet-trader facilities. Occurrence of *C. muris* in free-ranging populations of *E. sibiricus* needs further confirmation.

We thank M. Kadlecová and J. Kvicerová for their help and care of experimental animals and R. Frýzelka for providing imported chipmunks. We are indebted also

to Olympus C&S for their generous technical support. This study was supported by Grant FRVŠ 1260-2001, and, in part, by the Ministry of Education of Czech Republic CEZ: AJ06/98:F1-123100003 and J16/98: 161700001.

LITERATURE CITED

- AYDIN, Y., AND I. A. ÖZKUL. 1996. Infectivity of *Cryptosporidium muris* directly isolated from the murine stomach for various laboratory animals. *Veterinary Parasitology* 66: 257–262.
- CHALMERS, R. M., A. P. STURDEE, S. A. BULL, A. MILLER, AND S. E. WRIGHT. 1997. The prevalence of *Cryptosporidium parvum* and *C. muris* in *Mus domesticus*, *Apodemus sylvaticus* and *Clethrionomys glareolus* in an agricultural system. *Parasitology Research* 83: 478–482.
- ISEKI, M. 1986. Two species of *Cryptosporidium* naturally infecting house rats, *Rattus norvegicus*. *Japanese Journal of Parasitology* 35: 521–526.
- , T. MAEKAWA, K. MORIYA, S. UNI, AND S. TAKADA. 1989. Infectivity of *Cryptosporidium muris* (strain RN 66) in various laboratory animals. *Parasitology Research* 75: 218–222.
- JOHNSON, D. W., N. J. PIENIAZEK, D. W. GRIFFIN, L. MISENER, AND J. ROSE. 1995. Development of a PCR protocol for sensitive detection of cryptosporidium oocysts in water samples. *Applied and Environmental Microbiology* 61: 3849–3855.
- LEVINE, N. D. 1980. Some corrections of coccidian (Apicomplexa: Protozoa) nomenclature. *Journal of Parasitology* 66: 830–834.
- , AND V. IVENS. 1965. The coccidian parasites (Protozoa, Sporozoa) of rodents. *Illinois Biological Monographs* 33. University of Illinois Press, Urbana, Illinois, 365 pp.
- LINDSAY, D. S., S. J. UPTON, D. S. OWENS, U. M. MORGAN, J. R. MEAD, AND B. L. BLAGBURN. 2000. *Cryptosporidium andersoni* n. sp. (Apicomplexa: Cryptosporiidae) from cattle, *Bos taurus*. *Journal of Eukaryotic Microbiology* 47: 91–95.
- MATSUI, T., T. FUJINO, J. KAJIMA, AND M. TSUJI. 2000. Infectivity to experimental rodents of *Cryptosporidium parvum* oocysts from Siberian chipmunks (*Tamias sibiricus*) originated in the People's Republic of China. *Journal of Veterinary Medical Science* 62: 487–489.
- MORGAN, U. M., L. XIAO, P. T. MONIS, I. SULAIMAN, I. PAVLASEK, B. BLAGBURN, M. OLSON, S. J. UPTON, N. V. KHRAMTSOV, A. LAL, A. ELLIOT, AND R. C. A. THOMPSON. 2000. Molecular and phylogenetic analysis of *Cryptosporidium muris* from various hosts. *Parasitology* 120: 457–464.
- , P. T. MONIS, L. XIAO, J. LIMOR, I. SULAIMAN, S. RAIDAL, P. O'DONOGHUE, R. GASSER, A. MURRAY, R. FAYER, B. L. BLAGBURN, A. A. LAL,

- AND R. C. THOMPSON. 2001. Molecular and phylogenetic characterisation of *Cryptosporidium* from birds. *International Journal for Parasitology* 31: 289–296.
- PAVLÁSEK, I. 1999. *Cryptosporidia*: Biology, diagnosis, host spectrum, specificity, and the environment. *Remedia—Klinická Mikrobiologie* 3: 290–301 [In Czech.]
- , AND M. LÁVIČKA. 1995. The first finding of a spontaneous gastric cryptosporidiosis infection in hamsters (*Phodopus roborovskii* Satumin, 1903). *Veterinární Medicína (Praha)* 40: 261–263 [In Czech.]
- PIENIAZEK, N. J., F. J. BORNAY-LLINARES, S. B. SLEMENDA, A. J. DA SILVA, I. N. S. MOURA, M. J. ARROWOON, O. DITRICH, AND D. G. ADDISS. 1999. New *Cryptosporidium* genotypes in HIV-infected persons. *Emerging Infectious Diseases* 5: 444–449.
- RHEE, J. K., Y. S. SEU, AND B. K. PARK. 1991. Isolation and identification of *Cryptosporidium muris* from various animals in Korea: II. Identification of *Cryptosporidium muris* from mice. *Korean Journal of Parasitology* 29: 149–159.
- , S. Y. YOOK, AND B. K. PARK. 1995. Oocyst production and immunogenicity of *Cryptosporidium muris* (strain MCR) in mice. *The Korean Journal of Parasitology* 33: 377–382.
- SPANO, F., L. PUTIGNANI, J. McLAUCHLIN, D. P. CASEMORE, AND A. CRISANTI. 1997. PCR-RFLP analysis of the *Cryptosporidium* oocyst wall protein (COWP) gene discriminates between *C. wairi* and *C. parvum*, and between *C. parvum* isolates of human and animal origin. *FEMS Microbiology Letters* 150: 209–217.
- SWOFORD, D. L. 1996. PAUP: Phylogenetic analysis using parsimony (and other methods), version 4.0. Sinauer Associates, Sunderland, Massachusetts.
- TAYLOR, M. A., R. N. MARSHALL, J. A. GREEN, AND J. CATCHPOLE. 1999. The pathogenesis of experimental infections of *Cryptosporidium muris* (strain RN 66) in outbred nude mice. *Veterinary Parasitology* 86: 41–48.
- THOMPSON, J. D., T. J. GIBSON, F. PLEWNIAK, F. JEANMOUGIN, AND D. G. HIGGINS. 1997. The ClustalX windows interface: Flexible strategies for multiple sequence alignment aided by quality analysis tools. *Nucleic Acids Research* 24: 4879–4882.
- TORRES, J., M. GRACENEA, M. S. GOMEZ, A. ARRIZABALAGA, AND O. GONZALEZ-MORENO. 2000. The occurrence of *Cryptosporidium parvum* and *C. muris* in wild rodents and insectivores in Spain. *Veterinary Parasitology* 92: 253–260.
- TYZZER, E. E. 1907. A protozoan found in the peptic glands of the common mouse. *Proceedings of the Society for Experimental Biology and Medicine* 5: 12–13.
- . 1910. An extracellular coccidium, *Cryptosporidium muris* (gen. et sp. nov.), of the gastric glands of the common mouse. *Journal for Medical Research* 23: 487–509.

Received for publication 18 October 2002.