

TOXOPLASMA GONDII INFECTIONS IN CAPTIVE BLACK-FOOTED FERRETS (MUSTELA NIGRIPES), 1992–1998: CLINICAL SIGNS, SEROLOGY, PATHOLOGY, AND PREVENTION

Authors: Burns, Roy, Williams, Elizabeth S., O'Toole, Donal, and Dubey, J. P.

Source: Journal of Wildlife Diseases, 39(4) : 787-797

Published By: Wildlife Disease Association

URL: <https://doi.org/10.7589/0090-3558-39.4.787>

BioOne Complete (complete.BioOne.org) is a full-text database of 200 subscribed and open-access titles in the biological, ecological, and environmental sciences published by nonprofit societies, associations, museums, institutions, and presses.

Your use of this PDF, the BioOne Complete website, and all posted and associated content indicates your acceptance of BioOne's Terms of Use, available at www.bioone.org/terms-of-use.

Usage of BioOne Complete content is strictly limited to personal, educational, and non - commercial use. Commercial inquiries or rights and permissions requests should be directed to the individual publisher as copyright holder.

BioOne sees sustainable scholarly publishing as an inherently collaborative enterprise connecting authors, nonprofit publishers, academic institutions, research libraries, and research funders in the common goal of maximizing access to critical research.

TOXOPLASMA GONDII INFECTIONS IN CAPTIVE BLACK-FOOTED FERRETS (*MUSTELA NIGRIPES*), 1992–1998: CLINICAL SIGNS, SEROLOGY, PATHOLOGY, AND PREVENTION

Roy Burns,^{1,4} Elizabeth S. Williams,² Donal O'Toole,² and J. P. Dubey³

¹Louisville Zoological Garden, P.O. Box 37250, Louisville, Kentucky 40233, USA

²Department of Veterinary Sciences, University of Wyoming, Laramie, Wyoming 82070, USA

³USDA, ARS, ANRI, Animal Parasitic Disease Laboratory, BARC-East, Bldg. 1001, 10300 Baltimore Avenue, Beltsville, Maryland 20705-2350, USA

⁴Corresponding author (email: roy.burns@loukymetro.org)

ABSTRACT: An epizootic of toxoplasmosis occurred among 22 adult and 30 kit black-footed ferrets (*Mustela nigripes*) maintained under quarantine conditions at the Louisville Zoological Garden (Louisville, Kentucky, USA) in June, 1992. Black-footed ferrets appear to be highly susceptible to acute and chronic toxoplasmosis. Clinical signs were observed in 19 adults and six kits and included anorexia, lethargy, corneal edema, and ataxia. Two adults and six kits died with acute disease. High antibody titers to *Toxoplasma gondii* were detected by latex agglutination and modified agglutination assay in 10 black-footed ferrets. One adult and six kits that died with acute clinical signs were necropsied and *T. gondii*-like organisms were found microscopically in multiple organs. Diagnosis of toxoplasmosis was confirmed by immunohistochemical staining with anti-*T. gondii* antibodies and by ultrastructural examination. Although the source of *T. gondii* for black-footed ferrets was not identified, frozen uncooked rabbit was the most likely source. Chronic toxoplasmosis resulted in the death of an additional 13 black-footed ferrets that were adults during the epizootic. Affected animals developed chronic progressive posterior weakness and posterior ataxia 6–69 mo after the epizootic began. Meningoencephalitis or meningoencephalomyelitis associated with chronic toxoplasmosis were identified at necropsy in all 13 ferrets. Precautions to prevent introduction of pathogens into the colony were insufficient to exclude *T. gondii*. Although toxoplasmosis may cause significant mortality in mustelids, the high mortality of black-footed ferrets in this epizootic was of concern due to their endangered status. This is the first detailed report of toxoplasmosis in black-footed ferrets.

Key words: Black-footed ferrets, endangered species, *Mustela nigripes*, *Toxoplasma gondii*, toxoplasmosis.

INTRODUCTION

The protozoan *Toxoplasma gondii* infects many species of homeothermic animals, resulting in varied disease (Dubey and Beattie, 1988). Infection occurs in many free-ranging and captive wild species (Dreesen, 1990). Of species in the family Mustelidae, *T. gondii* has been reported in domestic ferret (Coutelen, 1932; Bigalke et al., 1966; Thornton and Cook, 1986; Fox, 1998), steppe polecat (*Mustela putorius eversmanni*; Beyer and Shevkunova, 1986), and mink (*M. vison*; Hulland, 1956; Pridham and Belcher, 1958; Pridham, 1961; Dietz et al., 1993; Frank, 2001). Serologic evidence of *T. gondii* infection was reported in North American river otter (*Lontra canadensis*; Tociłdowski et al., 1997), marten (*Martes americana*; Tizard et al., 1976), and fisher (*Martes pennanti*; Tizard et al., 1976).

The successful captive propagation and reintroduction program for the endangered black-footed ferret (*Mustela nigripes*) involves various wildlife agencies, universities, and zoos (Williams et al., 1991). Concern about disease has influenced management of this species and design of facilities from inception of the program (Hutchins et al., 1996). Herein, we report an epizootic of toxoplasmosis in the Louisville Zoological Garden (LZG; Louisville, Kentucky, USA) colony of black-footed ferrets, including clinical signs, pathology, and serology. We speculate on the most likely source of infection. Brief details of the episode were reported previously (Williams and Thorne, 1996).

History of the colony and the epizootic

Toxoplasmosis occurred in black-footed ferrets at the LZG Conservation Center.

The epizootic of toxoplasmosis began in June 1992. During the epizootic, the black-footed ferret population consisted of 22 adults and 30 kits.

The LZG established a captive-breeding colony in 1991 as an expansion of the Black-footed Ferret Species Survival Plan (BFFSSP) captive-breeding program that began with 18 wild caught black-footed ferrets. The population's mean inbreeding coefficient in 1992 was 0.056, with a living descendant founder genome equivalent of 4.178 black-footed ferrets (BFFSSP Stud-book Report, 1992).

Black-footed ferrets were maintained under quarantine conditions using facilities and management practices designed to prevent introduction of disease. These included continuous positive pressure air-flow ventilation and a shower-in policy for staff (Burns, 1991). Necropsies were performed on most black-footed ferrets dying in the colony. Coccidiosis was the only recognized infectious disease present in the colony prior to the toxoplasmosis epizootic.

The black-footed ferret diet consisted of a mixture of 1.5 kg raw rabbit (ground muscle and bones; Kentucky Specialty Meats, Inc., Princeton, Kentucky), 600 g dry pelleted mink food (National Gro-fur Dark Pellets, Milk Specialists Co., New Holstein, Wisconsin, USA), 25 g dried beef liver biodigest (Biodigest, Bioproducts, Inc., Louisville, Kentucky), 300 international units vitamin E (Vitamin E TPGS, Eastman Chemical Products, Inc., Kingsport, Tennessee, USA), and 1.4 l water. Whole hamsters were offered twice a week from a closed colony established at the Conservation Center in 1990 (Sasco, Inc., Charles River Labs, Wilmington, Massachusetts, USA). Kits were offered a gruel mixture of the black-footed ferret diet and kitten milk replacer (KMR, PetAg, Inc., Hampshire, Illinois, USA) beginning at 3–4 wk of age.

Rabbit meat was purchased from a United States Department of Agriculture-inspected supplier to the restaurant trade.

Most of the supplier's rabbit was raised indoors but outdoor enclosures were used on occasion. Rabbit was delivered frozen, eviscerated, skinned, and quartered. On occasion, rabbits arrived whole or with a small amount of organ meat. Rabbit usually was stored frozen at -14 to -17 C at the LZG for a week prior to being fed raw. According to the manufacturers, the dry pelleted mink food and dried beef liver biodigest were processed to 82 C and 87 C, respectively. The diet mixture was refrigerated (4 C) for use over a 3 day period after which it was discarded. Drops of a multiple vitamin supplement (Poly Vi-Sol, Bristol-Meyers, Evansville, Indiana, USA) were added to each black-footed ferret's diet twice a week. No illness was diagnosed in the hamster colony at the LZG.

MATERIALS AND METHODS

Behavioral observations, husbandry records, and physical examinations were used to evaluate clinical signs. Physical examinations were performed by manual restraint using a small cage or by chemical restraint using a combination of diazepam (0.1–0.2 mg total dose) and ketamine (15–26 mg/kg) intramuscularly. Eyes were evaluated by direct ophthalmoscopy and digital pressure. Black-footed ferret kits present during the epizootic were young (age range 10–48 days). Observation of kits present during the epizootic was limited due to husbandry practices intended to minimize disturbance of kits and their dams.

Blood was collected from sick and clinically healthy black-footed ferrets multiple times throughout the outbreak via jugular venipuncture and chemical restraint. Complete blood counts (CBC) were performed either at the LZG using a white blood cell manual determination method (Unopette Microcollection System, Becton Dickinson and Co., Franklin Lakes, New Jersey, USA) or at Roche Bioveterinary Labs (Columbus, Ohio, USA). Complete blood counts were performed on blood collected 1 and 5 wk after the first black-footed ferret exhibited clinical signs.

Serum chemistry assays were performed at Roche Bioveterinary Labs. Chemistry assays were performed on serum collected 3 and 5 wk after the first black-footed ferret exhibited clinical signs.

Serum chemistry and CBC results were interpreted using mean and standard deviation values for normal adult black-footed ferrets

provided by the BFFSSP (Burns, unpubl. data). Values were considered abnormal if they were greater than two standard deviations from the mean.

The latex agglutination test (LAT) for antibodies against *T. gondii* was performed at the Wyoming State Veterinary Laboratory (University of Wyoming, Laramie, Wyoming, USA; Toxotest-MT, Eiken Chemical Company, LTD, Tokyo, Japan). Tests were performed on sera collected from eight adult black-footed ferrets with clinical signs and one adult black-footed ferret without clinical signs 2 and 5 wk after the first black-footed ferret exhibited clinical signs.

The modified agglutination test (MAT) (Dubey and Desmonts, 1987) was performed at the Beltsville Agricultural Research Center (USDA, ARS, Beltsville, Maryland, USA). This test was performed on the same serum samples as the LAT and in addition, samples from the same individuals collected 29 wk after the first black-footed ferret exhibited clinical signs. Both LAT and MAT were performed to confirm seroconversion in a species not previously tested using these methods.

Rectal swabs for bacterial culture were collected from four black-footed ferrets during physical examinations (Minitip culturette collection and transport system, Becton-Dickinson, Cockeysville, Maryland). Food samples were collected in sterile containers and cultured for *Salmonella* spp., *Shigella* spp., *Campylobacter* spp., and *Yersinia* spp. (Roche Bioveterinary Labs and the University of Kentucky Livestock Disease Diagnostic Center, Lexington, Kentucky).

Necropsy examinations of black-footed ferrets were performed at the LZG or the Wyoming State Veterinary Laboratory. Sections of heart, lungs, trachea, esophagus, thyroid, lymph nodes, spleen, eyes, liver, stomach, pancreas, small intestine, large intestine, skeletal muscle, bone and bone marrow, tongue, adrenal gland, kidneys, urinary bladder, gonad, brain, spinal cord, and skin were fixed in 10% neutral buffered formalin, processed routinely for paraffin embedding, sectioned at 5–6 μm , and stained for histopathology with hematoxylin and eosin (HE).

Immunohistochemical (IHC) detection of *T. gondii* tachyzoites and tissue cysts in formalin-fixed tissues was performed using an avidin-biotin complex (ABC) technique. Blocks of tissue from eight ferrets with acute clinical signs (kits and adults) and four adult ferrets with chronic signs were selected on the basis of detectable protozoa in HE stained sections. Five μm sections of formalin-fixed tissues were mounted on adhesive-treated slides and heated for 1 hr at

56 C. Endogenous peroxidase activity was blocked by incubation with 3% hydrogen peroxide in methanol for 10 min. Sections were partly-digested using a 0.05% protease solution at 37 C for 15 min. *Toxoplasma gondii* bradyzoites and tachyzoites were detected using a 1:320 dilution of hyperimmune serum from a rabbit and a commercial ABC kit used according to manufacturer's instructions (Vector Laboratories, Burlingame, California, USA; Lindsay and Dubey, 1989). Formalin-fixed sections of liver from a mouse experimentally-infected with *T. gondii* served as a positive control. Negative controls consisted of sections treated as above, except that primary antibody was replaced by phosphate-buffered saline.

Ultrastructural examination was performed on formalin-fixed pieces of tissue from an adult that died of necrotizing hepatitis and splenitis. Samples of liver and kidney containing 1 mm white foci were diced to 1 mm³ blocks and transferred to 2.5% glutaraldehyde in sodium cacodylate buffer. Samples were post-fixed in a 1% solution of osmium tetroxide, dehydrated in ascending concentrations of ethyl alcohol, embedded in an epoxy resin, and cut using glass knives. Selected blocks containing protozoa were cut with a diamond knife. Ultrathin sections were examined using a Philips 410 electron microscope. Ultrastructural criteria helpful in distinguishing *T. gondii* from other tissue cyst-forming Apicomplexan protozoa, including *Neospora caninum*, were described previously (Dubey, 1993).

Four hamsters from the Louisville Zoo feed hamster colony were anesthetized, bled via cardiocentesis, and euthanized for necropsy 6 wk after first ferret demonstrated acute toxoplasmosis. Sections of heart, lungs, spleen, liver, kidney, and brain were processed for histopathology as described above and microscopic examination was performed at the University of Kentucky Livestock Disease Diagnostic Center. Serology (LAT, MAT) on hamster sera was performed as described above.

RESULTS

Acute toxoplasmosis

Clinical signs associated with acute toxoplasmosis began 16 June 1992 when an adult female black-footed ferret was lethargic and partially anorexic. Within 1 wk, 19 of 22 adult black-footed ferrets in the colony were lethargic with partial or complete anorexia. Other clinical signs in adult black-footed ferrets were corneal edema, glaucoma, ataxia, and death (Table 1). The

TABLE 1. Clinical signs and significant lesions observed in 22 adult and 30 kit black-footed ferrets present in the colony during an epizootic of toxoplasmosis.

Clinical status		Clinical signs		Lesions	
Acute toxoplasmosis	1st mo	Lethargy	19 adults	Hepatitis, acute or subacute	1 adult, 4 kits
		Partial anorexia	19 adults	Hepatic necrosis	2 kits
		Corneal edema	4 adults	Hepatomegaly	1 adult
		Ataxia	3 adults	Myocarditis, severe, subacute	4 kits
		Death	2 adults, 6 kits	Pericardial fluid, increased	1 kit
		Glaucoma	1 adult	Meningoencephalitis, nonsuppurative	1 adult, 2 kits
				Pulmonary congestion	1 adult, 2 kits
				Pneumonia, interstitial	2 kits
				Pneumonitis, necrotizing	1 adult
				Abdominal fluid, increased	2 kits
				Splenitis, necrotizing	1 adult
				Pancreatitis, acute nonhemorrhagic	1 kit
				Peritonitis, nonsuppurative	1 kit
				Necrosis, thymus	1 kit
				Myositis	1 kit
				Colitis	1 kit
	Chronic toxoplasmosis	6-69 mo	Weakness, posterior	10 adults	Meningoencephalitis
		Depression	5 adults	Meningomyelitis	2 adults
		Disorientation	5 adults	Encephalitis	1 adult
		Urinary incontinence	5 adults	Cataract	9 adults
		Behavioral blindness	5 adults	Retinal atrophy	1 adult
		Death	5 adults	Corneal edema	1 adult
		Head tilt	3 adults	Hepatitis, subacute	1 adult
		Circling	1 adult	Hepatitis, chronic	1 adult
				Myocarditis	1 adult
				Pneumonia, granulomatous	1 adult
				Thymus, atrophy	1 adult
				Peritonitis, chronic	1 adult

TABLE 2. Latex agglutination and modified agglutination antibodies in nine black-footed during an epizootic of toxoplasmosis.

Studbook number	Clinical signs (Y/N)	Latex agglutination		Modified agglutination		
		6/30/92	7/22/92	6/30/92	7/22/92	1/7/93
155	Y	1:256	>1:2,048	NT ^a	≥1:5,000	NT ^a
157	Y	1:256	>1:2,048	≥1:5,000	≥1:5,000	NT ^a
213	Y	NT ^a	>1:2,048	NT ^a	≥1:5,000	1:256,000
242	Y	1:64	>1:2,048	≥1:5,000	1:5,000	1:128,000
243	Y	1:128	>1:2,048	≥1:5,000	≥1:5,000	1:128,000
237	Y	NT ^a	>1:2,048	≥1:5,000	≥1:5,000	1:1,024,000
140	Y	1:256	>1:2,048	≥1:5,000	≥1:5,000	1:128,000
439	Y	1:128	>1:2,048	≥1:5,000	≥1:5,000	1:128,000
238	N	NT ^a	mt1:2,048	NT ^a	≥1:5,000	1:256,000

^a Not tested.

duration of anorexia in adults ranged from 2–16 days. Of 30 kits present during the epizootic, death associated with *T. gondii* in tissues occurred in six kits aged 35–47 days (20% kit mortality). No clinical signs other than death were observed in these black-footed ferret kits. An additional 10 kits died of starvation or maternal trauma with no *Toxoplasma* organisms found in multiple tissue sections.

Treatment of clinically affected adult black-footed ferrets during the epizootic included amoxicillin trihydrate (Amoxidrop, Smith, Kline, Beecham Animal Health, West Chester, Pennsylvania, USA) 11–22 mg/kg orally twice a day for 7 days followed by trimethoprim-sulfamethoxazole (Sulfatrim Pediatric Suspension, Barre-National, Inc., Baltimore, Maryland) 19–30 mg/kg orally twice a day for 5–14 days, followed by sulfadimethoxine (Albon, 5% oral suspension, Smith, Kline, Beecham Animal Health, West Chester, Pennsylvania) 25–30 mg/kg orally once a day for 6–10 days. Some clinically affected black-footed ferrets were given supportive care with vitamin A and D injections (Injacom 100, Hoffman-LaRoche, Inc., Nutley, New Jersey) 0.1 ml IM, vitamin B complex (The Butler Company, Columbus, Ohio) 0.25 ml, and lactated Ringer's solution subcutaneously.

Seven of eight clinically ill adult black-footed ferrets bled during week three of

the epizootic were anemic (low packed cell volume, red blood cell count, and/or hemoglobin concentration); three had leukocytosis, and two had leukopenia. Four clinically ill adult black-footed ferrets bled during week five of the epizootic had hyperproteinemia and hyperglobulinemia; three had elevated aspartate aminotransferase activity and lactate dehydrogenase activity, and two had elevated alanine aminotransferase (ALT) activity.

Rectal cultures collected from clinically ill adult black-footed ferrets during the epizootic were negative for *Salmonella* spp., *Shigella* spp., *Campylobacter* spp., and *Yersinia* spp.

Latex agglutination and MAT serology results are shown in Table 2. Seroconversion (≥ four-fold rise in titers in the LAT or MAT, or both) occurred in all nine black-footed ferrets tested, including one asymptomatic animal. An eight-fold or more rise in titer was found by LAT in six black-footed ferrets over a 2 wk period.

Two adults and 16 kits died during the initial epizootic. In one adult and six kits, organisms consistent with *T. gondii* were detected histologically. *Toxoplasma* organisms were identified by histopathology and by IHC staining in spleen (Fig. 1), myocardium, liver (Fig. 2), lungs, brain, and colonic tunica muscularis. Gross and microscopic findings in black-footed ferrets in which *Toxoplasma* organisms were iden-

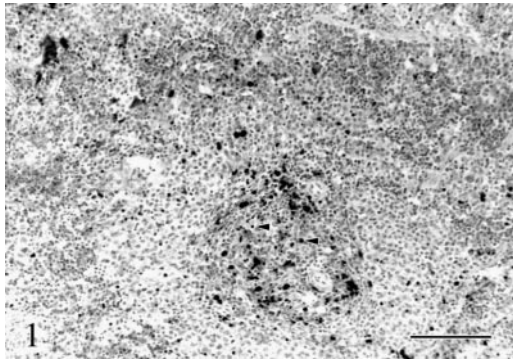


FIGURE 1. Multiple aggregates of *T. gondii* tachyzoites (solid arrowheads) are in periarteriolar sheath and adjacent red pulp in the spleen of a black-footed ferret with acute toxoplasmosis. Immunohistochemistry for *T. gondii* with hematoxylin counterstain. Bar=100 μ m.

tified at necropsy are listed (Table 1). The 2.0×4.4 μ m curved unicellular protozoa had ultrastructural features typical of the subphylum Apicomplexa, including presence of apical rings, conoid, pellicle, subpellicular microtubules, rhoptries, and micronemes (Fig. 3). Organisms were intracytoplasmic in parasitophorous vacuoles, and multiplied asexually by endodyogeny. The morphologic features of gland-like rhoptries were consistent with *T. gondii* (five or fewer per tachyzoite; restriction to cytosol anterior to nucleus; honeycomb-like internal structure) (Fig. 4). Early tissue cysts in hepatocytes contained ≥ 35 bradyzoites and had a 0.4 μ m cyst wall (Fig. 5).

Hamsters were negative for antibodies against *Toxoplasma* by LAT and MAT. Lesions or organisms suggestive of toxoplasmosis were absent in tissues from four hamsters.

Cultures of mink pellets, whole rabbit, and prepared diet were negative for enteric pathogens.

Chronic toxoplasmosis

Clinical signs associated with chronic toxoplasmosis were observed subsequently in 13 adult black-footed ferrets (Table 1). Ten had previously exhibited acute clinical signs (lethargy and/or anorexia) yet ap-

peared to recover completely. Clinical signs associated with chronic toxoplasmosis developed 6–69 mo after the epizootic began. Clinical signs of chronic toxoplasmosis lasted 1–29 mo and ended in death or euthanasia.

The most common presenting clinical signs in chronically affected ferrets suggested involvement of the central nervous system. Animals developed mild to moderate progressive posterior weakness (10/13; 77%), disorientation (5/13; 38%), depression (5/13, 38%), head tilt (3/13; 23%), and circling (1/13; 8%).

Seven other adult black-footed ferrets present during the epizootic had no clinical signs associated with chronic toxoplasmosis and were part of a release program 27–33 mo after the epizootic began. Five previously exhibited acute clinical signs (lethargy, anorexia) but appeared to recover completely. The fate of these black-footed ferrets after leaving the LZG colony is unknown.

Treatment of chronically infected black-footed ferrets with trimethoprim-sulfamethoxazole 30 mg/kg orally twice a day, rifampin (Rifadin, Merrell Dow Pharmaceuticals, Richmond Hill, Ontario, Canada) 26 mg/kg orally twice a day, or clindamycin hydrochloride (Antirobe Aquadrops, Upjohn Veterinary Products, Kalamazoo, Michigan, USA) 25 mg/kg orally twice a day, did not improve clinical signs.

Gross and microscopic findings in chronically infected black-footed ferrets are listed in Table 1. Chronic toxoplasmosis was identified in 10 animals. The principal abnormality was moderate to severe multifocal necrotizing nonsuppurative or granulomatous meningoencephalomyelitis (Fig. 6). Tissue cysts with numerous bradyzoites that stained strongly positive by IHC for *Toxoplasma* antigen were identified in central nervous tissues of nine black-footed ferrets. Lesions in tissues other than the central nervous system and eyes were interpreted as age-related or incidental.

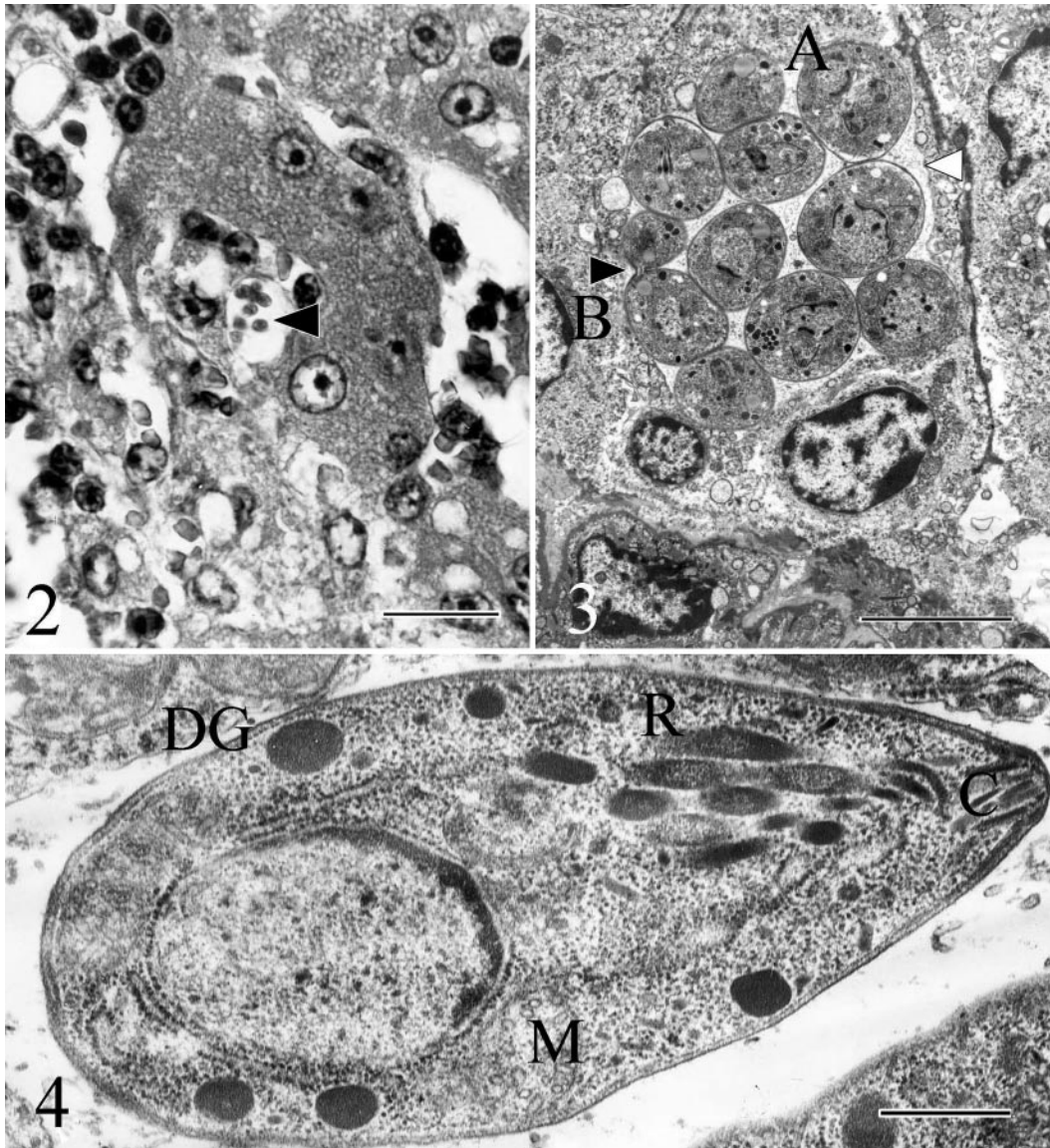


FIGURE 2. Intracellular tachyzoites of *T. gondii* in hepatocyte (solid arrowhead) of a black-footed ferret with acute toxoplasmosis. HE. Bar=10 μ m.

FIGURE 3. Electron micrograph of an infected hepatocyte similar to that in Figure 2. Tachyzoites in various stages of endodyogeny in parasitophorous vacuole (white arrowhead). A: early endodyogeny with formation of two apical complexes; B: late endodyogeny, with incipient separation of two organisms (solid arrowhead). Bar=5 μ m.

FIGURE 4. Electron micrograph of *T. gondii* tachyzoite from the liver of a black-footed ferret with acute toxoplasmosis. This is a longitudinal section, illustrating conoid (C), rhoptries (R), mitochondrion (M), dense granule (DG), and subterminal nucleus. Bar=500 nm.

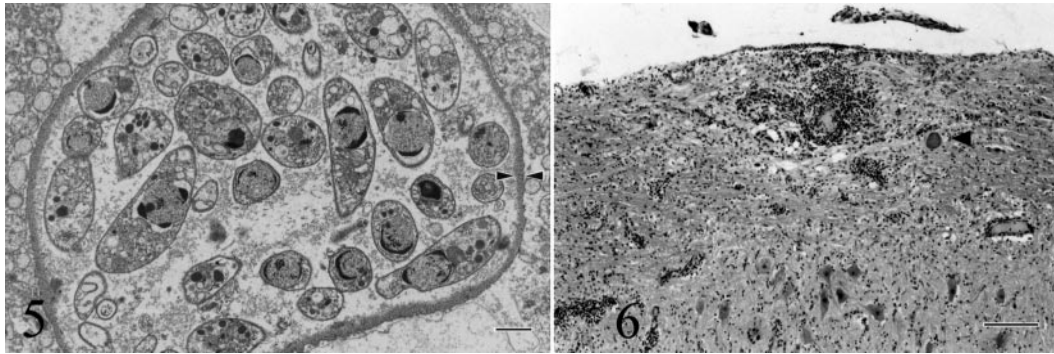


FIGURE 5. Electron micrograph of formation of an early cyst in hepatocyte in a ferret dying of toxoplasmosis. Note cyst wall (between arrowheads). HE. Bar=1 μ m.

FIGURE 6. Nonsuppurative leukomyelitis with intralosomal *T. gondii* cyst (solid arrowhead) from the lumbar spinal cord of a black-footed ferret with chronic toxoplasmosis. HE. Bar=100 μ m.

DISCUSSION

Illness and death in this group of black-footed ferrets was due to toxoplasmosis. The diagnosis was established by suggestive clinical signs and confirmed by histopathology, immunohistochemistry, electron microscopy, and serology.

The most likely source of infection was uncooked rabbit meat, because most other ingredients in the diet underwent heat processing at temperatures over 70 C, which should kill *Toxoplasma* (Dubey and Beattie, 1988). *Toxoplasma gondii* is killed by salting, curing, or heat used for processed meat (Dubey, 1994). Most *Toxoplasma* cysts are destroyed when meat is frozen and thawed (Frenkel, 1990a). In establishing a freeze-death curve for inactivation of *T. gondii* cysts in pork, tissue cysts were generally killed by freezing at -12.4 C but there were unexplained instances where tissue cysts in pork were infective after exposures to colder temperatures (Koluta et al., 1991). In another report, *T. gondii* in pork was killed by freezing at -12 C for 3 days (Dubey, 1988). Raw rabbit fed in the black-footed ferret's diet at the time of the outbreak was stored frozen at -17 to -14 C for an undetermined amount of time. Toxoplasmosis occurs in domestic rabbits (Leland et al., 1992). We suspect *T. gondii* organisms survived in frozen rabbit meat but unfortu-

nately, we were unable to test the suspect batch of rabbit meat for the parasite.

Hamsters were an unlikely source of the organism. Four hamsters were sacrificed and were negative for evidence of exposure to *Toxoplasma* by LAT, MAT, and histology. There was no history of illness in the closed hamster colony for over 1 yr prior to the ferret epizootic. However, we examined only four hamsters and subclinical infection of other hamsters could not be excluded.

Clinical signs (lethargy, anorexia, ataxia, disorientation, incontinence, circling, chronic infection, and death) and lesions (nonsuppurative encephalitis, myocarditis, pulmonary congestion, hepatic necrosis, splenitis, and *Toxoplasma* organisms in organs) observed in this epizootic in black-footed ferrets were similar to those described in epizootics of toxoplasmosis in mink (Pridham and Belcher, 1958; Pridham, 1961; Frank, 2001). However, unlike previous reports, all black-footed ferrets present in the LZG colony at the time of the epizootic eventually died of chronic toxoplasmosis. Most ferrets that succumbed to chronic toxoplasmosis had clinical signs and lesions attributable to persistent infection of the central nervous system and eyes. Reactivation of chronic toxoplasmosis involving the central nervous system is a feature of immunosup-

pressed human patients (Frenkel, 1990a, b). We were unable to identify factor(s) in this group of ferrets to account for reactivation of chronic toxoplasmosis.

In most species, toxoplasmosis develops in young animals that have an immature immune response as well as in older animals with impaired immune responses, and in animals that evolved without exposure to toxoplasmosis (Frenkel, 1990a; Dubey, 1994). The historic range of the black-footed ferret includes regions in which serologic evidence of *Toxoplasma* occurs (Hall and Kelson, 1959; Dubey, 1985; Williams et al., 1992; Smith and Frenkel, 1995). The historic range covered 12 states in the US and extended into Canada (Hall and Kelson, 1959).

Clinical toxoplasmosis in free ranging and captive mustelids is uncommon (Lainson, 1957; Siim and Sorensen-Biering, 1963). However, there are several reports of clinical signs and death due to toxoplasmosis in farmed mustelids (Pridham and Belcher, 1958; Pridham, 1961; Thornton and Cook, 1986; Dietz et al., 1993; Frank, 2001). Clinical signs and high mortality experienced by this colony of black-footed ferrets suggest that the species is highly susceptible to toxoplasmosis.

Inadequate immune response may explain the high mortality experienced in this colony. Cellular and humoral components are required for adequate immune responses to infection with *Toxoplasma* (Frenkel, 1974, 1990a). In humans, chronic toxoplasmosis occurs because the bradyzoite/tissue cyst stage evades the immune response and persists for months to years, resulting in latent chronic infection (Frenkel, 1990b). Sporadically, lesions develop due to rupture of tissue cysts. Lesions are generally self-limited because protective immunity is adequate (Frenkel, 1990b). A study of one component of the black-footed ferrets immune system identified an inability to produce interleukin-6, which may increase vulnerability to infectious agents that require a strong hu-

mor immune response or neutrophil mobilization (Kennedy-Stoskopf et al., 1997).

Some of the abnormal clinical pathology seen in black-footed ferrets during the epizootic are similar to those described in cats with clinical feline toxoplasmosis due to extraintestinal infection (Lappin, 1995). These include anemia, leukophilia, leukopenia, hyperproteinemia, and elevated ALT.

Two of the drugs used to treat black-footed ferrets (clindamycin, trimethoprim-sulfamethoxazole) have resolved some clinical signs in cats with toxoplasmosis (Lappin, 1995). However, treatment of acute and chronically infected black-footed ferrets did not improve clinical signs or prevent development of chronic toxoplasmosis.

Infection of kits was likely due to exposure of kits to *Toxoplasma* in the gruel fed at weaning which contained uncooked rabbit meat. Gruel was first fed at 22 and 24 days of age to six black-footed ferret kits that died of toxoplasmosis. These kits died 10–26 days after the first gruel feeding. This is consistent with an incubation period of 5–18 days in common-source epizootics of human toxoplasmosis (Frenkel, 1990b).

The epizootic did not result in subsequent vertical transmission. Nine females survived the epizootic. Of these, eight bred in 1993 and three were bred in 1994 producing 25 and nine kits respectively. Twenty-one of the 1993 kits and two of the 1994 kits died. Age at death ranged from 0–20 days of age. None had evidence of *Toxoplasma* infection at necropsy. A report of congenital *Toxoplasma*-like disease in domestic ferrets speculated that domestic ferrets, once infected, transmit congenital toxoplasmosis over several gestations without recrudescence (Thornton and Cook, 1986). Congenital toxoplasmosis was not identified in the LZG colony of black-footed ferrets.

Other than adult black-footed ferrets affected during the epizootic, no other black-footed ferrets have shown clinical

signs or lesions associated with toxoplasmosis since 1992. Management changes instituted after the outbreak included maintaining freezer temperatures at -20 C or less, prolonging freezing time for rabbit meat to 1 mo, storing other dietary ingredients at -20 C for 1 wk, and removing remaining organ tissues from rabbit meat prior to use. In October 2000, the diet was changed to a more nutritionally balanced horse meat-based diet (Toronto Zoo Carnivore Mix Diet, Milliken Wholesale Meat, Scarborough, Ontario) in response to recommendations by the BFFSSP.

ACKNOWLEDGMENTS

The authors thank V. Crossett, G. Graves, and J. Luyster for technical and husbandry expertise, V. Welch for histopathology and immunohistochemical staining, C. Hearne for electron microscopy preparations, S. Vaughn for help in necropsy and treatment, and R. Tramountin and C. B. Hong of the University of Kentucky Livestock Disease Diagnostic Center for morphologic examinations of hamsters and some black-footed ferret kits.

LITERATURE CITED

- BEYER, T. V., AND E. A. SHEVKUNOVA. 1986. A review of toxoplasmosis in the U.S.S.R. *Veterinary Parasitology* 19: 225–243.
- BIGALKE, R. D., R. C. TUSTIN, J. L. DU PLESSIS, P. A. BASSON, AND R. M. MCCULLY. 1966. The isolation of *Toxoplasma gondii* from ferrets in South Africa. *Journal of the South African Veterinary Medical Association* 37: 243–247.
- BLACK-FOOTED FERRET SURVIVAL PLAN STUDBOOK REPORT. 1992. Unpublished report.
- BURNS, R. B. 1991. Black-footed ferret (*Mustela nigripes*) captive breeding program at the Louisville Zoo. In Proceedings of the American Association of Zoo Veterinarians annual meeting, R. E. Junge (ed.). Calgary, Alberta, Canada, pp. 85–89.
- COUTELEN, F. 1932. Existence of a spontaneous and generalized toxoplasma in the ferret: A new toxoplasma *Toxoplasma laidlawi* n. sp. parasite of *Mustela (putorius) putorius* var. *furo*. *Comptes Rendus de Societe Biologique*, Paris 111: 284–287.
- DIETZ, H. H., P. HENRIKSEN, M. LEBECH, AND S. A. HENRIKSEN. 1993. Experimental infection with *Toxoplasma gondii* in farmed mink (*Mustela vison*). *Veterinary Parasitology* 47: 1–7.
- DREESEN, D. W. 1990. *Toxoplasma gondii* infections in wildlife. *Journal of the American Veterinary Medical Association* 196: 274–276.
- DUBEY, J. P. 1985. Serologic prevalence of toxoplasmosis in cattle, sheep, goats, pigs, bison, and elk in Montana. *Journal of the American Veterinary Medical Association* 186: 969–970.
- . 1988. Long-term persistence of *Toxoplasma gondii* in tissues of pigs inoculated with *T. gondii* oocysts and effect of freezing on viability of tissue cysts in pork. *American Journal of Veterinary Research* 49: 910–913.
- . 1993. *Toxoplasma*, *Neospora*, *Sarcocystis* and other tissue cyst forming coccidia. In *Parasitic protozoa*, Vol. 6. J. P. Krier (ed.). Academic Press, New York, New York, pp. 1–158.
- . 1994. Toxoplasmosis. *Journal of the American Veterinary Medical Association* 205: 1593–1598.
- , AND C. P. BEATTIE. 1988. Toxoplasmosis in animals and man. CRC Press, Boca Raton, Florida, 220 pp.
- , AND G. DESMONTS. 1987. Serological responses of equids fed *Toxoplasma gondii* oocysts. *Equine Veterinary Journal* 19: 337–339.
- FOX, J. G. 1998. Biology and diseases of the ferret. Lea & Febiger, Philadelphia, Pennsylvania, 475 pp.
- FRANK, R. K. 2001. An outbreak of toxoplasmosis in farmed mink (*Mustela vison* S.). *Journal of Veterinary Diagnostic Investigation* 13: 245–249.
- FRENKEL, J. K. 1974. Pathology and pathogenesis of congenital toxoplasmosis. *Bulletin of the New York Academy of Medicine* 50: 182–191.
- . 1990a. Transmission of toxoplasmosis and the role of immunity in limiting transmission and illness. *Journal of the American Veterinary Medical Association* 196: 233–240.
- . 1990b. Toxoplasmosis in human beings. *Journal of the American Veterinary Medical Association* 196: 240–248.
- HALL, E. R., AND K. R. KELSON. 1959. The mammals of North America, Vol. 2. Ronald Press, New York, New York, p. 914.
- HULLAND, T. J. 1956. Toxoplasmosis in Canada. *Journal of the American Veterinary Medical Association* 128: 74–79.
- HUTCHINS, M., R. J. WIESE, AND J. BOWDOIN. 1996. Black-footed ferret recovery program analysis and action plan. American Zoo and Aquarium Association, Baltimore, Maryland, 137 pp.
- KENNEDY-STOSKOPF, S., A. E. HORSMAN, AND R. B. BURNS. 1997. Absence of interleukin-6 (IL-6) expression in the black-footed ferret (*Mustela nigripes*). In *The 7th congress of the International Society of Developmental and Comparative Immunology*, L. W. Clem and G. W. Warr (eds.). The College of William and Mary, Williamsburg, Virginia, p. 127.
- KOLUTA, A. W., J. P. DUBEY, A. K. SHARAR, C. D. ANDREWS, S. K. SHEN, AND D. S. LINDSAY.

1991. Effect of freezing on infectivity of *Toxoplasma gondii* tissue cysts in pork. *Journal of Food Protection* 54: 687–690.
- LAINSON, R. 1957. The demonstration of *Toxoplasma* in animals, with particular reference to members of the Mustelidae. *Transactions of the Royal Society of Tropical Medicine and Hygiene* 51: 111–117.
- LAPPIN, M. E. 1995. CVT update: Feline toxoplasmosis. In *Current veterinary therapy XII*, R. W. Kirk (ed.). W. B. Saunders Company, Philadelphia, Pennsylvania, pp. 309–314.
- LELAND, M. M., G. V. HUBBARD, AND J. P. DUBEY. 1992. Clinical toxoplasmosis in domestic rabbits. *Laboratory Animal Science* 42: 318–319.
- LINDSAY, D. S., AND J. P. DUBEY. 1989. Immunohistochemical diagnosis of *Neospora caninum* in tissue sections. *American Journal of Veterinary Research* 50: 1981–1983.
- PRIDHAM, T. J. 1961. An outbreak of toxoplasmosis in mink. *Canadian Journal of Public Health* 52: 389–393.
- , AND J. BELCHER. 1958. Toxoplasmosis in mink. *Canadian Journal of Comparative Medicine* 22: 99–106.
- SIIM, J. C., AND U. SORENSEN-BIERING. 1963. Toxoplasmosis in domestic animals. *Advances in Veterinary Science and Comparative Medicine* 8: 335–429.
- SMITH, D. D., AND J. K. FRENKEL. 1995. Prevalence of antibodies to *Toxoplasma gondii* in wild mammals of Missouri and east central Kansas: Biology and ecologic considerations of transmission. *Journal of Wildlife Diseases* 31: 15–21.
- THORNTON, R. N., AND T. G. COOK. 1986. A congenital *Toxoplasma*-like disease in ferrets (*Mustela putorius furo*). *New Zealand Veterinary Journal* 34: 31–33.
- TIZARD, I. R., J. B. BILLET, AND R. O. RAMSDEN. 1976. The prevalence of antibodies against *Toxoplasma gondii* in some Ontario mammals. *Journal of Wildlife Diseases* 12: 322–325.
- TODDOWSKI, M. E., M. R. LAPPIN, P. W. SUMNER, AND M. K. STOSKOPF. 1997. Serologic survey of toxoplasmosis in river otters. *Journal of Wildlife Diseases* 33: 649–652.
- WILLIAMS, E. S., AND E. T. THORNE. 1996. Infectious and parasitic diseases of captive carnivores, with special emphasis on the black-footed ferret (*Mustela nigripes*). *Revue Scientifique et Technique* 15: 91–114.
- , ———, D. R. KWAITKOWSKI, S. L. ANDERSON, AND K. LUTZ. 1991. Reproductive biology and management of captive black-footed ferrets (*Mustela nigripes*). *Zoo Biology* 10: 383–389.
- , J. CAVENDER, C. LYNN, K. MILLS, C. NUNAMAKER, A. BOERGER-FIELDS, B. LUCE, AND S. ANDERSON. 1992. Survey of coyotes and badgers for diseases in Shirley Basin, Wyoming in 1991. In *Black-footed ferret reintroduction in Shirley Basin, Wyoming, 1991*, B. Oakleaf, B. Luce, E. Thorne and S. Torbit (eds.). Wyoming Game and Fish Department, Cheyenne, Wyoming, 240 pp.

Received for publication 26 September 2002.