

Congenital Hypotrichosis in a White-Tailed Deer Fawn from South Dakota

Authors: Zimmerman, Teresa J., Jenks, Jonathan A., Holler, Larry D., Jacques, Christopher N., and Morlock, Wilbert W.

Source: Journal of Wildlife Diseases, 40(1) : 145-149

Published By: Wildlife Disease Association

URL: <https://doi.org/10.7589/0090-3558-40.1.145>

BioOne Complete (complete.BioOne.org) is a full-text database of 200 subscribed and open-access titles in the biological, ecological, and environmental sciences published by nonprofit societies, associations, museums, institutions, and presses.

Your use of this PDF, the BioOne Complete website, and all posted and associated content indicates your acceptance of BioOne's Terms of Use, available at www.bioone.org/terms-of-use.

Usage of BioOne Complete content is strictly limited to personal, educational, and non - commercial use. Commercial inquiries or rights and permissions requests should be directed to the individual publisher as copyright holder.

BioOne sees sustainable scholarly publishing as an inherently collaborative enterprise connecting authors, nonprofit publishers, academic institutions, research libraries, and research funders in the common goal of maximizing access to critical research.

Congenital Hypotrichosis in a White-Tailed Deer Fawn from South Dakota

Teresa J. Zimmerman,^{1,4} Jonathan A. Jenks,¹ Larry D. Holler,² Christopher N. Jacques,¹ and Wilbert W. Morlock³ ¹Department of Wildlife and Fisheries Sciences, South Dakota State University, Box 2140B, Brookings, South Dakota 57007, USA; ²Department of Veterinary Science, South Dakota State University, ADR 106, Brookings, South Dakota, 57007, USA; ³Wildlife Division, South Dakota Department of Game, Fish, and Parks, 400 West Kemp, Watertown, South Dakota, 57201 USA; and ⁴Corresponding author (email: zimmermanteresa@hotmail.com)

ABSTRACT: On 1 October 2001, a 4-mo-old male white-tailed deer (*Odocoileus virginianus*) fawn was collected in Day County, South Dakota (USA), by South Dakota Department of Game, Fish and Parks personnel. The fawn had sparse hair development on the ventral thorax, the lateral caudal and caudal aspects of the rear legs, the muzzle, around the eyes, and inside the ears. Remaining skin surfaces were devoid of hair. Histologic examination revealed normal hair follicle density although follicles were empty or contained keratin debris and fragments of hair shaft. The epidermis of the fawn was mildly thickened and melanin pigment was prominent within deep layers of the epidermis. Based on histologic examination, the deer was diagnosed with congenital hypotrichosis. Although this condition has been reported in domestic species and humans, this specimen represents the first documented case of congenital hypotrichosis in a cervid.

Key words: Congenital hypotrichosis, hypotrichosis, *Odocoileus virginianus*, white-tailed deer.

Hypotrichosis, of genetic or nongenetic origin, has been reported in domestic species, humans, and a rhesus monkey (*Macaca mulatta*; Ratterree and Baskin, 1992). Hypotrichosis in cattle is visually expressed by partial or complete absence of hair and may be associated with prognathia (Meyer et al., 1992), dental anomalies, or malformations of hooves and horns (Thomsett, 1961).

A 4-mo-old male white-tailed deer, *Odocoileus virginianus*, with profound alopecia was observed in Day County, South Dakota (USA; 45°12'25.2"N, 97°20'20.4"W) on 1 October 2001. Because of the unusual condition of the fawn, it was harvested by South Dakota Department of Game, Fish and Parks personnel and transported to the Animal Disease Research and Di-

agnostics Laboratory, South Dakota State University (Brookings, South Dakota) for examination.

At necropsy, the ventral thorax had normal-appearing, white-haired skin. A rim of coarse guard hair was observed along the caudal aspect of the rear legs and extended over the top line. Sparse hair development was present on the muzzle, around the eyes, and inside the ears. Remaining skin surfaces were devoid of hair, appeared thin, and were uniformly dark brown to tan (Fig. 1). Teeth, hooves, and condition of the fawn appeared normal. Weight of the fawn was average for age, 30 kg. The rumen contained foamy green gray roughage and scant amounts of whole corn. Minimal subcutaneous, pericardial, and perirenal adipose tissue was present. Endocrine and pituitary glands appeared normal during gross examination.

Examination of skin sections from grossly affected regions revealed morphologic changes that primarily affected adnexal structures. Hair-follicle density appeared to be normal in these sections. Follicles were usually ectatic and appeared to extend into the superficial to middermis (Fig. 2a). Follicles were empty or contained keratin debris and fragments of hair shaft. Discernible hair bulbs were not usually associated with these follicles. Occasional clusters of pale eosinophilic spindle cells were loosely associated with clusters of follicular squamous cells that appeared at the level where normal hair bulbs would have been found (Fig. 2c). Apocrine sweat glands were usually ectatic and often the only adnexal structures in the mid to deep dermis. Apocrine gland

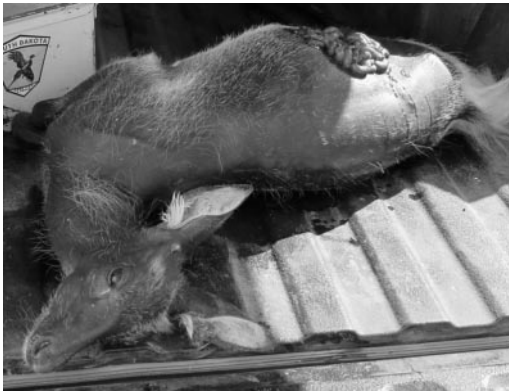

FIGURE 1. White-tailed deer fawn with congenital hypotrichosis collected from eastern South Dakota in October 2001.

ductules were empty or contained sloughed cells admixed with amphophilic to palely basophilic, globular to fibular material. In some sections, widely scattered hair follicles with normal hair-root bulbs extended into the deep dermis. These hair follicles appeared in various stages of hair development. Arrector pili muscles were usually readily evident and appeared to insert near the base of the dilated follicles. Variable sebaceous gland hypertrophy and hyperplasia was present in all sections examined.

The epidermis of the fawn was mildly thickened (orthokeratotic hyperkeratosis and mild acanthosis). Melanin pigment was prominent within deep layers of the epidermis of the hairless fawn (Fig. 2b) compared with an age-matched normal

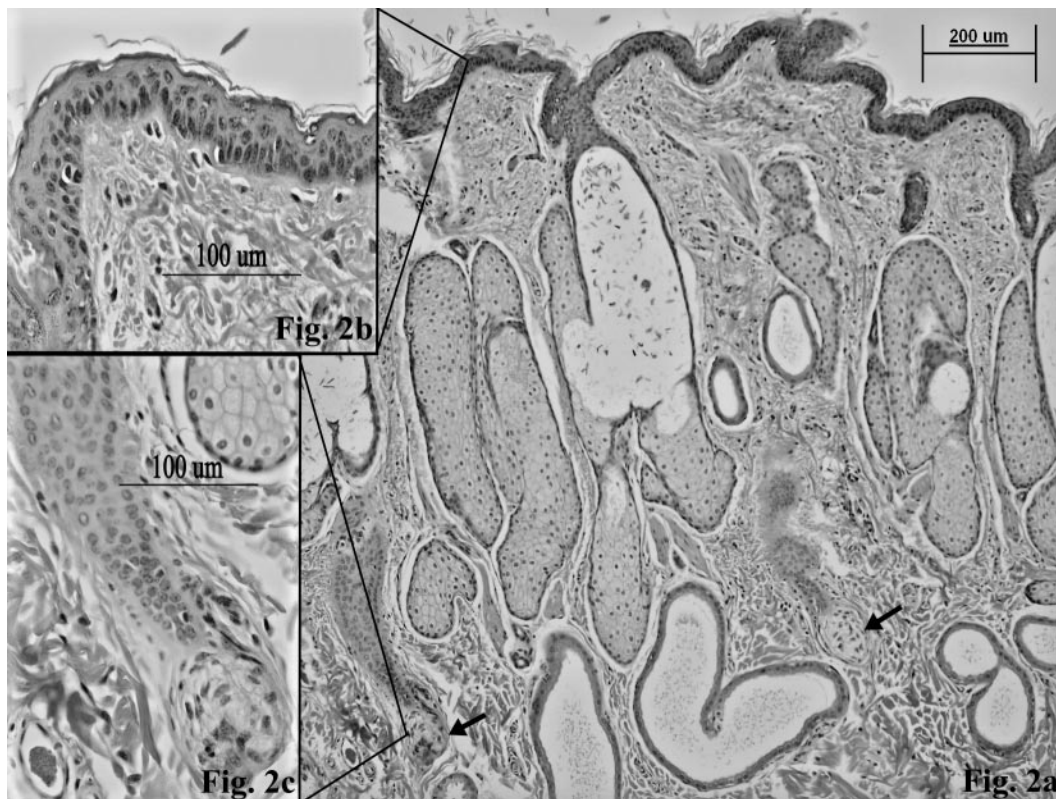


FIGURE 2. Skin section from scapular region of hypotrichosis fawn. (a) Note ectatic follicles, hyperplastic and hypertrophic sebaceous glands, ectatic apocrine glands, and abnormal hair bulbs (see arrows). H&E, 100X. (b) Note melanin pigment in deep layers of epidermis. H&E, 400X. (c) Abnormal hair follicle development from hypotrichosis fawn. Note cluster of spindloid cells associated with follicle squamous cells. H&E, 400X.

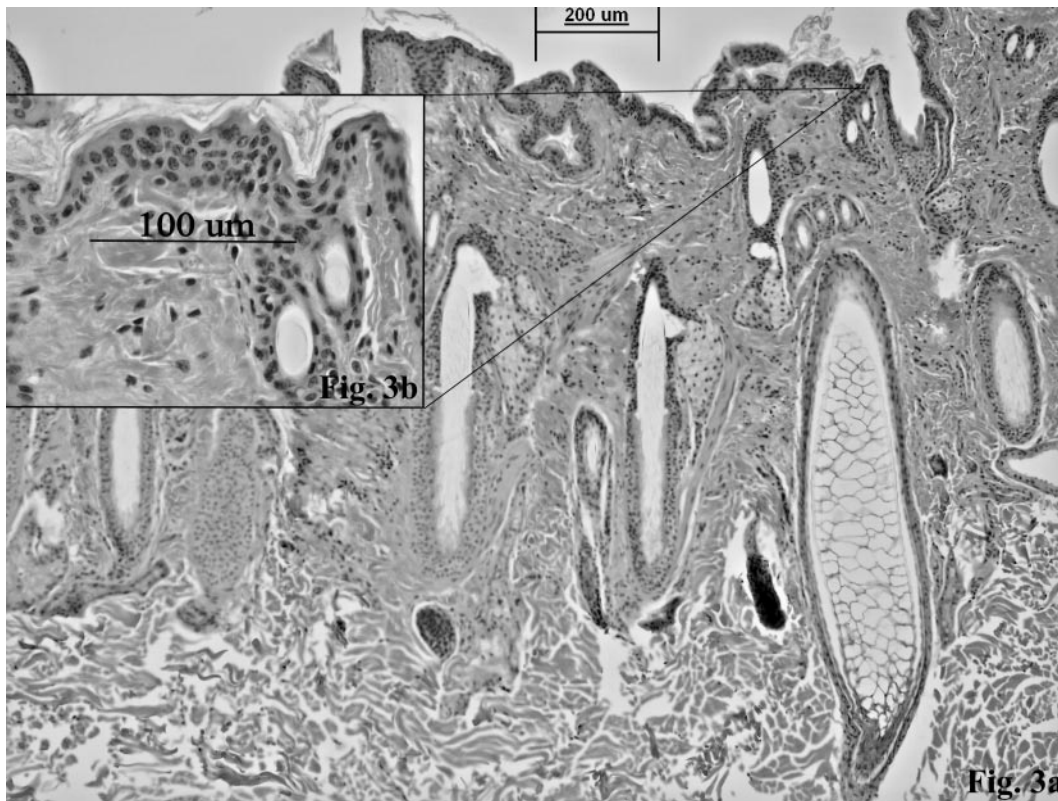


FIGURE 3. Skin section from scapular region of a normal fawn. (a) H&E, 100 \times . (b) Epidermis and secondary hair follicles from a normal fawn; note lack of visible melanin pigment (see Fig. 2b for comparison). H&E, 400 \times .

fawn (Fig. 3b). Epidermal or dermal inflammation was not present in sections examined. Dermal collagen was occasionally fragmented but otherwise normal. Additional sections of skin stained with Gomori's methenamine silver (GMS) for fungal hyphae were negative. No histologic evidence of ectoparasitism was observed in skin sections examined. No gross or histologic lesions were observed in skeletal muscle, lung, liver, kidney, spleen, heart, cerebrum, cerebellum, brain stem, rumen, abomasum, small intestine, and large intestine. Thyroid and adrenal glands were grossly normal but were not examined histologically.

Ectoparasites were not found by skin scrapings of the epidermis and superficial to middermis. Samples were submitted in oil, cover slipped, and examined under

10 \times magnification. No ectoparasites were observed in multiple hematoxylin and eosin sections examined. Immunohistochemistry on submitted skin samples, kidneys, and lungs was negative for antigens compatible with bovine viral diarrhea virus (BVDV). Based on histologic examination and absence of ectoparasites, the fawn was diagnosed with congenital hypotrichosis.

Hypotrichosis, of nongenetic origin, has been linked to factors such as iodine deficiency, adeno-hypophyseal hypoplasia, and intrauterine infection with BVDV (Hanna and Ogilvie, 1989). Miller et al. (1988) indicated that iodine deficiency during pregnancy may result in birth of hairless young; however, obvious goiter, or enlarged thyroid, was observed in these cases. Consequently, iodine deficiency was not a probable cause of nongenetic hypo-

trichosis in this fawn due to the lack of obvious goiter. Evidence of BVDV was not demonstrated in the white-tailed fawn, as submitted skin, lung, and kidney samples were negative for BVDV antigens.

Hutt (1963) described six forms of genetic hypotrichosis in cattle: lethal hairlessness, semihairlessness, hypotrichosis with anodontia, hypotrichosis with missing incisors, streaked hairlessness, and viable hypotrichosis. Lethal hairlessness is typified by calves that die within minutes of birth; although Becker et al. (1963) described a similar viable condition. Calves affected by semihairlessness are viable at birth and are born with a sparse coat of fine, short hair (Hutt, 1963). In addition to some degree of hairlessness, cattle affected by either hypotrichosis with anodontia or hypotrichosis with missing incisors exhibit dental anomalies. Cattle affected with streaked hairlessness show patterns of hairless, vertical streaks over hip joints and sometimes along the side of the body (Hutt, 1963).

Viable hypotrichosis is a condition characterized by viable young, born completely to semi-hairless, with normal teeth. Existing pelage may be found on the legs, tail switch, eyelids, ventral areas, thorax, prepuce, around the mammary glands, and the inner surfaces of the ears (Hutt, 1963; Bracho et al., 1984). When present, hair is brittle, thin, undulated, and sometimes curly. Skin is reported to be thin, pliable, smooth, and shiny (Popova-Wassina, 1931; Bracho et al., 1984). Secondary effects of hairlessness associated with hypotrichosis include sunburn and wrinkled skin (Becker et al., 1963).

Histologic description of viable congenital hypotrichosis is characterized by poorly differentiated empty hair follicles with occasional plugs of keratin (Becker et al., 1963). Other histologic examinations have demonstrated a decrease in follicle density, skin thickness, hair diameter, and size and number of sweat and sebaceous glands (Bracho et al., 1984; Hanna and Ogilvie, 1989). Becker et al. (1963) reported that

sweat glands were dilated and cystic while others observed normal sweat glands (Mackie and McIntyre, 1992). Other findings in sheep include an absence of fibers in follicles, keratotic follicles, hypertrophy and hyperplasia of sebaceous glands and epidermis, and epidermal hyperkeratosis (Mackie and McIntyre, 1992).

This white-tailed deer fawn represents the first case of congenital hypotrichosis observed in a cervid. Diagnosis as hypotrichosis was made based on results of histopathology, negative immunohistochemistry for BVDV, and skin scrapings. With the degree of hairlessness associated with the fawn, it is unlikely that it would have survived exposure to inclement weather, which is likely related to the paucity of reports of this condition in wild animals. Nevertheless, presence of congenital hypotrichosis does represent a mortality factor potentially affecting white-tailed deer in North America.

The authors thank the South Dakota Department of Game, Fish and Parks for the collection of the deer; the Animal Disease Research and Diagnostics Laboratory, South Dakota State University, for diagnosis and preparation of skin samples; and M. B. Hildreth for assistance with figures. We thank the South Dakota Department of Game, Fish and Parks and South Dakota State University for support for this project.

LITERATURE CITED

- BECKER, R. B., C. F. SIMPSON, AND C. J. WILCOX. 1963. Hairless Guernsey cattle: Hypotrichosis—A non-lethal character. *Journal of Heredity* 54: 3–7.
- BRACHO, G. A., K. BEEMAN, J. L. JOHNSON, AND H. W. LEIPOLD. 1984. Further studies of congenital hypotrichosis in Hereford cattle. *Zentralblatt für Veterinärmedizin. Reihe A* 31: 72–80.
- HANNA, P. E., AND T. H. OGILVIE. 1989. Congenital hypotrichosis in an Ayrshire calf. *Canadian Veterinary Journal* 30: 249–250.
- HUTT, F. B. 1963. A note on six kinds of genetic hypotrichosis in cattle. *Journal of Heredity* 54: 186–187.
- MACKIE, J. T., AND B. MCINTYRE. 1992. Congenital hypotrichosis in Poll Dorset sheep. *Australian Veterinary Journal* 69: 146–147.
- MEYER, W., K. NEURAND, AND K. MULLER. 1992.

- Integumental structure in a Friesian calf with congenital hypo- or atrichosis combined with prognathia inferior. *Veterinary Dermatology* 3: 43–46.
- MILLER, J. K., N. RAMSEY, AND F. C. MADSEN. 1988. The trace elements. *In* The ruminant animal: Digestive physiology and nutrition, D. C. Church (ed.). Waveland Press, Inc., Prospect Heights, Illinois, pp. 342–400.
- POPOVA-WASSINA, E. T. 1931. A naked lamb. *Journal of Heredity* 22: 91–92.
- RATTERREE, M. S., AND G. B. BASKIN. 1992. Congenital hypotrichosis in a rhesus monkey. *Laboratory Animal Science* 42: 410–412.
- THOMSETT, L. R. 1961. Congenital hypotrichia in the dog. *Veterinary Record* 73: 915–917.

Received for publication 30 October 2002.