

EVALUATION OF IVERMECTIN FOR TREATMENT OF HAIR LOSS SYNDROME IN BLACK-TAILED DEER

Authors: Foreyt, William J., Hall, Briggs, and Bender, Louis

Source: Journal of Wildlife Diseases, 40(3) : 434-443

Published By: Wildlife Disease Association

URL: <https://doi.org/10.7589/0090-3558-40.3.434>

BioOne Complete (complete.BioOne.org) is a full-text database of 200 subscribed and open-access titles in the biological, ecological, and environmental sciences published by nonprofit societies, associations, museums, institutions, and presses.

Your use of this PDF, the BioOne Complete website, and all posted and associated content indicates your acceptance of BioOne's Terms of Use, available at www.bioone.org/terms-of-use.

Usage of BioOne Complete content is strictly limited to personal, educational, and non - commercial use. Commercial inquiries or rights and permissions requests should be directed to the individual publisher as copyright holder.

BioOne sees sustainable scholarly publishing as an inherently collaborative enterprise connecting authors, nonprofit publishers, academic institutions, research libraries, and research funders in the common goal of maximizing access to critical research.

EVALUATION OF IVERMECTIN FOR TREATMENT OF HAIR LOSS SYNDROME IN BLACK-TAILED DEER

William J. Foreyt,^{1,3} Briggs Hall,² and Louis Bender²

¹ Department of Veterinary Microbiology and Pathology, Washington State University, Pullman, Washington 99164-7040, USA

² Washington Department of Fish and Wildlife, Olympia, Washington 98504, USA

³ Corresponding author (email: wforeyt@vetmed.wsu.edu)

ABSTRACT: Since 1997, numerous Columbian black-tailed deer (*Odocoileus hemionus columbianus*) in western Washington (USA) have developed a hair loss syndrome that often preceded emaciation, debilitation, pneumonia, and death. To study this syndrome, eight affected free-ranging Columbian black-tailed deer fawns were captured from western Washington in February 1999 to determine the effect of ivermectin treatment. Fecal examinations indicated that the internal parasites were *Dictyocaulus viviparus*, *Parelaphostrongylus* sp., *Trichuris* sp., *Moniezia* sp., *Eimeria* spp., and gastrointestinal strongyles. Biting lice (*Tricholipeurus parallelus*) were observed on all deer, with up to 5 lice/cm² on the index areas counted. Three deer were treated with ivermectin subcutaneously at doses between 0.2 and 1.3 mg/kg of body weight monthly for four consecutive months, and five control deer received no anthelmintic treatment. Complete blood counts, parasite evaluations, weight gains, and hair loss evaluations were used to assess effectiveness of treatment. Two untreated deer died during the experiment compared with no deaths among the three treated deer. Treated deer gained significantly more weight ($P < 0.05$) than the untreated deer (22.4 vs. 12.6 kg, respectively) that survived the experiment, had significantly fewer parasite eggs and larvae ($P < 0.05$) in feces and significantly fewer nematodes ($P < 0.05$) at necropsy, and regrew their hair at a faster rate than untreated deer. Lice and all nematode eggs and larval stages in feces were eliminated or greatly reduced following treatment. On the basis of these data, excessive louse populations, gastrointestinal nematodes, and the lungworms *Parelaphostrongylus* sp. and *D. viviparus*, might be important predisposing factors for this hair loss condition and death of affected animals.

Key words: Black-tailed deer, hair loss syndrome, ivermectin, *Odocoileus hemionus columbianus*, pediculosis.

INTRODUCTION

Since spring 1997, wildlife biologists and other observers noticed a peculiar hair loss syndrome (also called hair slip syndrome) in Columbian black-tailed deer (*Odocoileus hemionus columbianus*) throughout much of western Washington, USA (Fig. 1). Affected deer developed yellowish to whitish discoloration of hair over the thorax, flanks, rump, and neck, and they licked their hair excessively. Progressive hair loss, emaciation, weakness, debilitation, and death occurred in numerous deer throughout the area. Deer were usually affected in late fall and winter, and fawns were most likely to die, whereas affected adult deer often recovered. Necropsies were performed on some of the dead deer, and a common necropsy finding was verminous pneumonia. Viruses or pathogenic bacteria were not isolated. Examination of

fecal samples from numerous dead and affected deer indicated infection with numerous parasites, including lungworms (*Dictyocaulus viviparus*, *Parelaphostrongylus* sp.) and other internal nematodes, tapeworms, and coccidia. Lice populations on most affected deer were high, with some estimates of approximately 50,000 biting lice (*Tricholipeurus parallelus*) per deer. Mites were not detected in numerous skin scrapings, in histologic preparations, or from skin digested in dilute potassium hydroxide solution, except for detection of *Demodex* sp. in one animal. The purpose of this experiment was to determine the effects of ivermectin to treat hair loss syndrome in captive black-tailed deer fawns by treating some of the deer with ivermectin and comparing blood values, weights, parasites, and lesions between treated and untreated deer.



FIGURE 1. Columbian black-tailed deer at the beginning of the experiment showing varying degrees of hair loss.

MATERIALS AND METHODS

Eight approximately 8-mo-old black-tailed deer fawns were captured between 18 and 24 February 1999 on Indian Island (48°4'N, 122°4'W) and McNeil Island (47°12'N, 122°49'W) in western Washington (Table 1). Deer were immobilized with approximately 1.3 mg of carfentanil and 20 mg of xylazine with a remote dart delivery system. Reversal of carfentanil was with 150 mg of naltrexone. Deer were transported to Washington State University (Pullman, Washington) and maintained together in a 2-ha pen. Alfalfa hay, an alfalfa-grain pelleted ration especially formulated for wild ruminants, mineralized salt, and fresh water were available at all times. Monthly for the next 6 mo, deer were captured in a drive net and restrained physically for approximately 10 min. One exception was during the fifth month, when four of the six deer were immobilized with carfentanil and xylazine. Reversal of the carfentanil was accomplished with 150 mg of naltrexone. Three of the deer were selected randomly and treated subcutaneously with iver-

mectin at a dose of approximately 1.1–1.3 mg/kg each month for the first 2 mo of the experiment and 0.2–0.3 mg/kg monthly for the third and fourth months; none of the deer were treated for the final 2 mo of the experiment. The five untreated deer received no anthelmintic treatments throughout the experiment (Table 1). While deer were restrained, 20 ml of blood was collected from the jugular vein, fecal samples for internal parasite evaluation were collected from the rectum, and deer were weighed to the nearest 0.45 kg. Lice numbers were determined in two index areas by counting all lice in a 58-cm² grid placed on the right shoulder and in a triangular area on the right side of the face from the eye to the tip of the nose and back to the end of the maxilla. Complete blood counts were performed on samples collected in potassium ethylenediaminetetraacetic acid tubes. Hematologic analysis was performed on an automated analyzer (Serono Baker 9010, ABX Diagnostics, Irvine, California, USA). Differential cell counts were performed manually from blood films stained with Wright-Giemsa stain. Fecal samples were evaluated for the presence of parasites by the sugar flotation method (specific gravity 1.27) and modified Baermann method as described by Foreyt (2001).

Surviving deer were euthanatized at the end of the experiment with pentobarbital given intravenously. Necropsies were performed on all deer that died or were euthanatized by personnel in the Washington Animal Disease Diagnostic Laboratory (Pullman, Washington). Representative samples of major tissues for histopathologic evaluation were preserved in 10% buffered formalin, sectioned at 5 μ m, and stained with hematoxylin and eosin. Selected lymph nodes were stained with Ziehl-Neelsen acid-fast stain. Brain, abomasum, small intestine, large intestine, and muscle masses were evaluated for parasites by established methods (Nettles, 1981; Pybus and Samuel, 1984a). For

TABLE 1. Characteristics of the 8-mo-old black-tailed deer used in the ivermectin treatment experiment.

Animal no.	Sex	Collection date (1999)	Location	Hair loss (%)	Initial weight (kg)	Treatment group
Y13	F	18 February	McNeil Island	15	22.3	Untreated
Y14	M	18 February	McNeil Island	60	17.3	Untreated
Y18	F	18 February	McNeil Island	10	15.9	Untreated
OR 45	M	24 February	Indian Island	70	29.5	Untreated
OR 50	F	18 February	Indian Island	60	19.1	Untreated
OR 41	M	24 February	Indian Island	70	25.0	Treated
OR 44	M	18 February	Indian Island	80	25.0	Treated
OR 49	M	18 February	Indian Island	50	22.7	Treated

recovery of lungworms, special attention was given to the lungs and the musculature of the back, loins, and hind legs. External parasites were preserved in 70% alcohol. Identifications of external parasites were verified by K. C. Kim (Frost Entomological Museum, Department of Entomology, Pennsylvania State University, University Park, Pennsylvania, USA). Representative specimens of all parasites have been deposited in the US National Parasite Collection (Beltsville, Maryland, USA) as US National Museum Helminthological Collection numbers 090068–090076.

Deer weights, lice numbers, and blood values were compared for treated and untreated deer by a repeated measures analysis of variance (Littell et al., 1996). Data were transformed where necessary to better satisfy homogeneity of variance and normality assumptions. Parasite recovery data from the abomasum and gastrointestinal tract were compared for treated and untreated deer by a two-sample *t*-test on log-transformed data.

RESULTS

Three treated deer and three untreated deer survived the 6-mo experiment. Two untreated deer died during the experiment. One male (Y14) from McNeil Island died on experimental day 31. This deer was emaciated and weak at capture, lost 4.5 kg during the first 31 days, had major hair loss, and did not improve in appearance. One female (OR50) from Indian Island died on experimental day 60. This deer was extremely weak before death. At necropsy, both deer were moderately to severely emaciated with lack of subcutaneous and mesenteric adipose tissue. Multifocal areas of hair loss, which ranged from 1 cm diameter to 4×1 cm, were scattered on the dorsal portions of all limbs. Fifteen adult *D. viviparus* were recovered from the lungs of deer OR50, and seven *Moniezia* sp. were present in the small intestine of deer Y14. Both deer had more than 1,000 biting lice (*T. parallelus*) and fewer than 10 keds (*Lipoptena* sp.) on the entire hide, fewer than 10 nasal botfly larvae (*Cephenemyia* sp.) in the retropharyngeal pouches, and gastrointestinal nematodes, including 141 and 127 *Oesophagostomum venulosum* in the large intestine and 88 and 110 *Haemonchus contortus* in

the abomasum of deer Y14 and OR50, respectively. Deer Y14 also had fewer than 10 sucking lice identified as *Solenopotes ferrisi*. Nematodes were not observed grossly on the surface of the brain or in the muscles examined.

Histologically, one deer (OR50) had adult nematodes (*D. viviparus*) in bronchioles, and both deer had granulomas, which were 150 to 300 μm in diameter scattered throughout the lung tissue. Granulomas consisted of histiocytes, plasma cells, and eosinophils that surrounded nematode eggs and larvae of *Parelaphostrongylus* sp. Numbers of *Parelaphostrongylus* sp. in lung sections were 3–4 larvae/cm² of tissue. Some granulomas also contained large, multinucleate giant cells and small aggregates of necrotic cellular debris. *Sarcocystis* sp. was present in several muscles, including tongue, skeletal muscle, and heart. Acid-fast organisms were not detected in lymph nodes. Sections of skin had mild hyperkeratosis and perivascular lymphocytic dermatitis with some eosinophils and mast cells. One section of skin contained unidentifiable basophilic fragments that were compatible with mite fragments. Other tissues had minor histologic changes and were considered normal.

At the initiation of the experiment, all deer had hair loss ranging from 10% to 80% (Table 1 and Fig. 1). Hair regrowth was seen clearly in the three treated deer within 30 to 60 days of treatment, whereas two untreated deer with moderate to severe hair loss did not begin to regrow hair until early summer, which was approximately 3 mo later than the treated deer.

Changes in deer weights are illustrated in Figure 2. Mean weights of treated and untreated deer were not significantly different ($P>0.05$) on day 0 (24.2 ± 0.76 vs. 21.7 ± 2.26 kg) and on days 30, 60, 90, and 120. Weights and weight gains for treated deer were significantly more ($P<0.05$) than untreated deer on experimental days 150 and 180 (mean final weights = 46.7 ± 1.69 vs. 35.1 ± 6.08 kg;

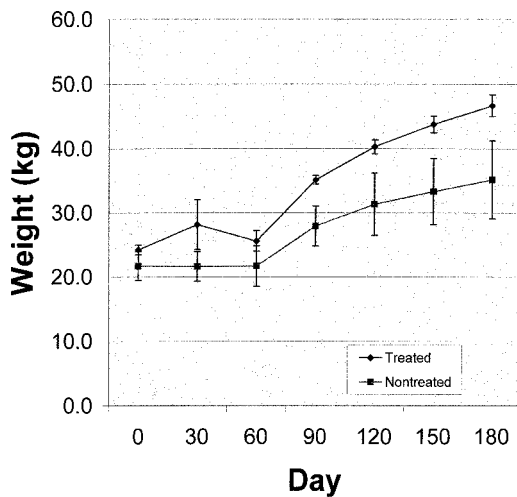


FIGURE 2. Mean weights of black-tailed deer treated with ivermectin ($n=3$) and of untreated deer ($n=3-5$). Untreated deer died on days 31 and 60. Bars indicate standard error.

mean final weight gains = 22.4 ± 1.89 vs. 12.6 ± 5.49 kg) of the experiment (Fig. 2). No significant differences in the following blood values were detected between groups ($P>0.05$) throughout the experiment: hemoglobin, packed cell volume, total red blood cells, mean corpuscular volume, mean corpuscular hemoglobin concentration, mean corpuscular hemoglobin, platelets, neutrophils, lymphocytes, monocytes, eosinophils, basophils, total protein, and fibrinogen.

Lice numbers found per month are il-

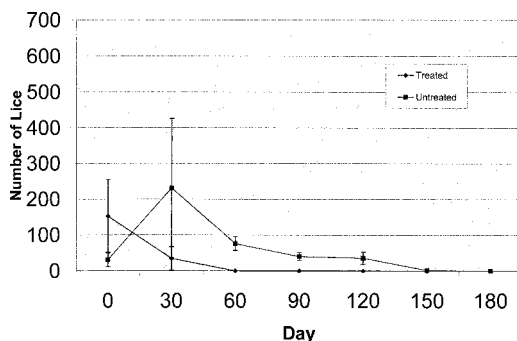


FIGURE 3. Mean numbers of *Tricholipeurus parallelus* from two index areas on black-tailed deer treated with ivermectin ($n=3$) and on untreated deer ($n=3-5$). Untreated deer died on days 31 and 60. Bars indicate standard error.

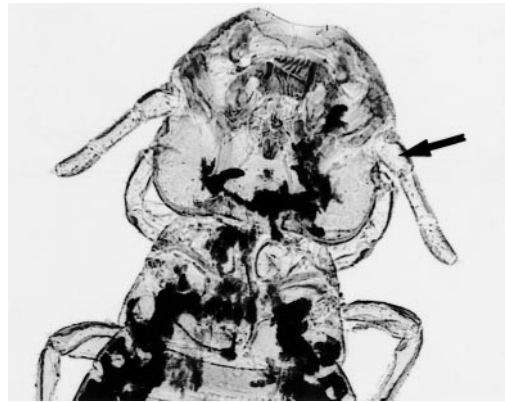


FIGURE 4. *Tricholipeurus parallelus* showing the first antennal segment, which is less than half the total antennal length.

lustrated in Figure 3. All eight deer had *T. parallelus* (Figs. 4, 5) at initiation of the experiment, but more lice were present in the treated group (mean of 152 vs. 31). In the treated animals, lice were eliminated within 30 days ($n=1$) or 60 days ($n=2$) of initial treatment. In the untreated group, numbers of lice increased in all deer during the first 30 days and then decreased gradually for the next 4 mo (Fig. 3). There were few lice on deer during the last 2 mo of the experiment (midsummer), and at the last evaluation in August, no lice were observed on any deer.

Parasite eggs and larvae detected in monthly fecal examinations are listed in Table 2. Genera of parasite eggs and oocysts detected in feces included *Eimeria*,




FIGURE 5. Abdominal segments of *Tricholipeurus* have a transverse row of setae on each segment.

TABLE 2. Summary of mean numbers of parasite eggs, larvae, and oocysts (per gram of feces) from fecal evaluation of treated (T) and untreated (U) black-tailed deer after 0, 30, 60, 90, 120, 150, and 180 days posttreatment.

	Mean no. of parasites																	
	0		30		60		90		120		150		180		Mean ^a			
	T ^b	U ^c	T ^b	U ^c	T ^b	U ^c	T ^b	U ^b	T ^b	U ^b	T ^b	U ^b	T ^b	U ^b	T	U		
Nematodes																		
<i>Capillaria</i> sp. (eggs/g feces)	0	1	0	4	0	4	0	6	0	7	0	7	0	0	0	0	5	
<i>Dictyocaulus</i> sp. (larvae/g feces)	0	37	0	9	0	82	0	7	0	15	0	8	1	3	0	21		
<i>Nematodirus</i> sp. (eggs/g feces)	3	2	0	7	0	0	0	0	0	0	0	0	0	0	0	1		
<i>Paralaphostromylus</i> sp. (larvae/g feces)	60	34	0	32	0	23	0	22	0	29	0	13	0	6	0	21		
<i>Strongyles</i> (eggs/g feces)	103	75	0	98	0	171	0	96	0	97	0	25	0	21	0	85		
<i>Trichuris</i> sp. (eggs/g feces)	3	1	0	3	0	5	0	7	0	5	0	3	0	3	0	4		
Cestodes																		
<i>Moniezia</i> sp. (eggs/g feces)	77	29	121	67	0	0	0	45	0	37	0	0	0	0	20	25		
Protozoa																		
<i>Eimeria</i> spp. (oocysts/g feces)	0	39	0	1	0	48	0	0	0	1	0	22	0	55	0	21		

^a Mean for days 30–180 (first administration of anthelmintic given to treated deer on day 0).^b n=3.^c n=5.^d n=4.

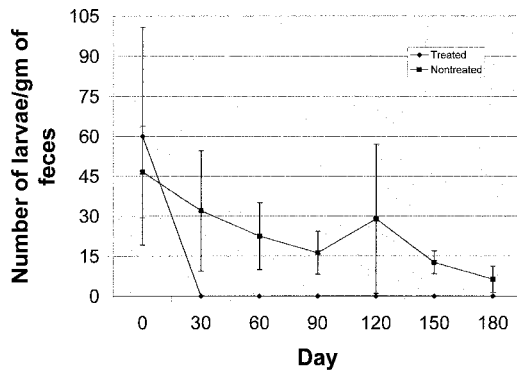


FIGURE 6. Mean numbers of *Parelaphostrongylus* sp. larvae (per gram of feces) in black-tailed deer treated with ivermectin ($n=3$) and in untreated deer ($n=3-5$). Untreated deer died on days 31 and 60. Bars indicate standard error.

Capillaria, *Moniezia*, *Nematodirus*, *Trichuris*, and gastrointestinal strongyles (*Haemonchus* and *Oesophagostomum*). In treated animals, *Nematodirus*, *Trichuris*, and strongyle eggs were not detected after the initial treatment, whereas untreated deer consistently had numerous eggs in feces. Larvae of two genera of lungworms were detected in feces. Larvae of *Dictyocaulus* sp. were detected throughout the experiment in the three untreated deer but were not detected at any time in the treated deer (Table 2). Larvae of *Parelaphostrongylus* sp. were initially detected in

two of three treated deer and two of three untreated deer that survived. After treatment, larvae were no longer detected in the treated deer throughout the experiment but were routinely detected in all three untreated deer that survived (Fig. 6). Significantly more larvae ($P<0.05$) were detected in untreated deer from day 30 to day 150 of the experiment.

Internal parasites recovered at necropsy are listed in Table 3. In the untreated deer, one specimen of *D. viviparus* was recovered from each of the three deer. Lungworms were not recovered from the treated deer. Histologically, eggs and larvae of *Parelaphostrongylus* sp. were detected in lungs of all three untreated deer but were not detected in any of the treated deer. Numbers of *Parelaphostrongylus* sp. in lung sections were 1–4 larvae/cm² of tissue. A total of 33 gastrointestinal nematodes were recovered from the three treated deer compared with 338 nematodes from the untreated deer (Table 3). Ivermectin treatment resulted in significantly fewer ($P<0.05$) parasites in treated deer when compared with untreated deer. At necropsy, all surviving deer had normal hair coats and were in good physical condition with adequate subcutaneous and mesenteric adipose tissue. External para-

TABLE 3. Numbers of parasites recovered at necropsy from three treated and three untreated deer that survived the 6-mo experiment.

Deer No.	No. of parasites recovered					
	Abomasum, <i>Haemonchus</i> <i>contortus</i>	Small intestine, <i>Nematodirus</i> <i>odocoilei</i>	Large intestine		Lungs, <i>Dictyocaulus</i> <i>viviparus</i>	Skin, lice and keds
			<i>Oesophagostomum</i> <i>venulosum</i>	<i>Trichuris</i> sp.		
Untreated						
Y13	44	0	3	135	1	0
Y18	21	0	23	22	1	0
OR 45	66	0	21	0	1	0
Mean	44	0	10	52	1	0
Treated						
OR41	22	0	1	0	0	0
OR45	8	2	0	0	0	0
OR49	0	0	0	0	0	0
Mean	10	<1	<1	0	0	0

sites were not recovered from any of the deer at necropsy.

DISCUSSION

The hair loss syndrome in black-tailed deer in western Washington is an important disease because of the high local mortality associated with deer less than 1 yr of age (B. Hall, unpubl. obs.) and the negative public reaction to clinically affected deer. This is a recently recognized disease syndrome that apparently was not observed before 1997 and has now been found throughout much of western Washington (B. Hall, unpubl. data). In this experiment, with a limited number of deer, we demonstrated that treatment with ivermectin effectively eliminated a majority of the internal nematodes and lice, which likely resulted in the improved hair growth and weight gains observed. We used dosages of ivermectin that are higher than the 0.2 mg/kg of body weight recommended for cattle and sheep, but the increased levels of drug did not appear to be toxic and were highly effective. Treated deer were not treated for the last 60 days of the experiment, and it is likely that the few gastrointestinal parasites that were present in treated deer at necropsy were the result of reinfection from pasture contamination from the untreated deer.

Adult *Parelaphostrongylus* spp. were not recovered from brain or muscle tissues at necropsy. Therefore, accurate identification of this parasite could not be determined because specific identification of this group of parasites can only be accomplished with adult male parasites recovered from brain or muscle or, potentially, with the use of recently developed molecular genetics techniques (Gajadhar et al., 2000). The *Parelaphostrongylus* spp. group of lungworms pass dorsal-spined first-stage larvae in feces that are essentially indistinguishable from one another. However, *P. tenuis* is the only adult worm in this group that lives on the surface of the brain, and it has never been reported from western North America (Lankester,

2001). *Parelaphostrongylus andersoni* and *P. odocoilei* are called muscieworms because adult parasites live primarily in major muscle masses of the back and legs, whereas eggs and larvae often accumulate in the lungs. It is possible that both parasites or other genera of lungworms that pass dorsal-spined larvae could be present in black-tailed deer, but *P. odocoilei* is the parasite most likely present. Previous reports indicated that *P. odocoilei* is present in black-tailed deer in California (Hobmaier and Hobmaier, 1934; Brunetti, 1969) and on Vancouver Island, British Columbia, Canada (Pybus et al., 1984). Verminous pneumonia can result from infections with *P. odocoilei* because larvae accumulate in lung tissue and evoke an intense granulomatous inflammation with subsequent necrosis and calcification (Pybus and Samuel, 1984b). On the basis of necropsies of deer with hair loss syndrome from western Washington, verminous pneumonia is the most common finding in dead deer (W. Foreyt, unpubl. data). In Washington, *P. odocoilei* has only been recovered from a debilitated pneumonic mountain goat (*Oreamnos americana*), from which 65 adult parasites were recovered (Pybus et al., 1984). To our knowledge, *P. andersoni* has not been reported in Washington.

Samuel and Gray (1988) indicated that ivermectin at 0.2–0.4 mg/kg of body weight suppressed larval production or killed larvae in white-tailed deer (*Odocoileus virginianus*) infected with *P. andersoni*, but larval shedding began again 10 to 55 days after treatment. In this experiment, larval shedding did not occur during the 60 days following the last ivermectin treatment. Our data indicate that at the doses we used in the four treatments, adult worms and larvae of *Parelaphostrongylus* sp. were likely killed because larvae were not recovered from feces after treatment, and eggs or larvae were not observed in the histologic sections of lungs from the treated animals at necropsy. However, eggs and larvae were detected in

histologic sections of lung from all three untreated deer. Another possibility is that the larval stages were killed and the adult worms stopped producing larvae for an extended period or permanently. On the basis of more than 200 routine fecal parasite analyses during the last 5 yr, the lungworms *Parelaphostrongylus* sp. and *D. viviparus* are relatively common in black-tailed deer from western Washington (W. Foreyt, unpubl. data). Brown (1961) indicated that *D. viviparus* was detected at necropsy in 27% of 338 black-tailed deer in Washington, but that author did not conduct fecal analyses to determine the presence of *Parelaphostrongylus* sp. larvae. Larvae of *Dictyocaulus* and *Parelaphostrongylus* can be differentiated easily on the basis of morphology (Foreyt, 2001). Unfortunately, there are no data to indicate whether *Parelaphostongylus* sp. is a relatively new parasite in black-tailed deer or whether the prevalence has increased concurrently with hair loss syndrome. The only nematodes that Brown (1961) detected in 338 black-tailed deer from western Washington were *D. viviparus*, *O. venulosum*, *Setaria* sp., *Trichuris* sp., and *Onchocerca cervipedis*. Biting lice identified as *Cervicola virginiana* were also reported (Brown, 1961). *Tricholipeurus parallelus* has also been identified as *Trichodectes odocoilei*, *Cervicola odocoilei*, and *Damalinia parallelus* (Walker and Becklund, 1970). It is possible that *C. virginiana* might be synonymous with the *T. parallelus* identified in this study, but specimens from the earlier study were not available for examination. Brown (1961) indicated that lice were most common during winter and spring, and degree of infestation was apparently related to body condition, with the healthiest animals having the fewest lice. Lice numbers in our experiment declined almost immediately in the treated deer but also declined at a much slower rate in the untreated deer. Lice numbers in large animals are highest in winter or the coolest months and often disappear during the summer or warmest months.

Solar radiation, immune responses by the host, and other factors could be responsible for declines in lice numbers (Murray, 1963; James, 1999). Large numbers of lice on mammals might also reflect compromised immune systems or nutritional deficiencies (Durden, 2001). During this experiment, the deer were fed a high-quality diet, which might have ameliorated some of the nutritional effects of hair loss syndrome, but differences in body weights and hair coats between treated and untreated deer during the experiment were obvious.

Although numerous methods of counting lice have been used by researchers (Clayton and Drown, 2001; Durden, 2001), we used two consistent index areas throughout the experiment because they were easily accessible while the deer were restrained and because lice appeared to be scattered over the entire body. Cowan (1946) reported biting lice (*T. parallelus* and *T. virginianus*) from 2,940 black-tailed deer on Vancouver Island, which is less than 100 km from the source of the deer in this experiment. He indicated that when lice were scarce, they were primarily found on the abdomen and the neck, but in heavy infestations, lice were evenly distributed over all parts of the body with long hair. Our initial observations indicated that the lice were present over most of the body in relatively high numbers. Therefore, for comparison between groups, we chose two representative areas that could be counted quickly with minimal discomfort to the deer.

Weight gains were significantly greater in treated than untreated deer (Fig. 1). Because of random assignment to groups, the treated group contained three males and the untreated group contained two males and three females. Male black-tailed deer gain approximately 3% to 10% more weight than females during the first 1.5 yr (Brown, 1961; Anderson, 1981), which might account for some of the extra weight gain in the treated animals. However, the weight gain in the treated group was 78%

greater than the untreated group, which indicated that most of the weight gain likely resulted from treatment, rather than a gender bias. Blood values for both treated and untreated deer were generally within normal limits (Fowler, 1986). Although some deer were obviously weak and lacked body fat, deer were not anemic. Because of a lack of differences between treated and untreated deer, it was concluded that treatment had minimal effect on blood parameters.

It is likely that marginal nutrition from reduced availability of digestible energy and potential mineral deficiencies in winter contribute to hair loss syndrome by resulting in a negative energy balance because of increased energy costs of thermoregulation (Parker et al., 1999). Removal of internal and external parasites with ivermectin might increase survival of deer affected by hair loss syndrome by improving their hair coats; preventing loss of energy; and reducing the effects of hypothermia, exhaustion, and pneumonia.

ACKNOWLEDGMENTS

We acknowledge US Bangor Naval Base biologist T. James and Indian Island environmental officer B. Kalina for their expertise and assistance in capturing affected deer for this study. The expert laboratory assistance of J. Lagerquist is appreciated. We also acknowledge the numerous veterinary students at Washington State University who enthusiastically participated in the deer captures and data collections. Appreciation is extended to J. Alldredge who provided statistical analysis of the data and to K. C. Kim for verifying the identification of external parasites. This study was partially funded by the US Navy, The Washington Department of Fish and Wildlife, the Northwest Washington Chapter of Safari Club International, and the College of Veterinary Medicine at Washington State University.

LITERATURE CITED

- ANDERSON, A. E. 1981. Morphological and physiological characteristics. *In* Mule and black-tailed deer of North America, O. C. Wallmo (ed.). University of Nebraska Press, Lincoln, Nebraska, pp. 27–98.
- BROWN, E. R. 1961. The black-tailed deer of western Washington. *Biological bulletin* 13, Washington State Game Department, Olympia, Washington, 124 pp.
- BRUNETTI, O. A. 1969. Redescription of *Parelaphostromylus* (Boev and Schuls, 1950) in California deer, with studies on its life history and pathology. *California Fish and Game* 55: 307–316.
- CLAYTON, D. H., AND D. M. DROWN. 2001. Critical evaluation of five methods for quantifying chewing lice (Insecta: Phthiraptera). *Journal of Parasitology* 87: 1291–1300.
- COWAN, I. MCT. 1946. Parasites, diseases, injuries, and anomalies of the Columbian black-tailed deer, *Odocoileus hemionus columbianus* (Richardson), in British Columbia. *Canadian Journal of Research, Series D* 24: 71–103.
- DURDEN, L. A. 2001. Lice (Phthiraptera). *In* Parasitic diseases of wild mammals, 2nd Edition, W. M. Samuel, M. J. Pybus, and A. A. Kocan (eds.). Iowa State University Press, Ames, Iowa, pp. 3–17.
- FOREYT, W. J. 2001. Veterinary parasitology reference manual, 5th Edition. Iowa State University Press, Ames, Iowa, 235 pp.
- FOWLER, M. E. 1986. Zoo and wild animal medicine, 2nd Edition. W. B. Saunders Company, Philadelphia, Pennsylvania, 1,126 pp.
- GAJADHAR, A., T. STEEVES-GURNSEY, J. KENDALL, M. LANKESTER, AND M. STEEN. 2000. Differentiation of dorsal spined elaphostromyline larvae by polymerase chain reaction amplification of ITS-2 of rDNA. *Journal of Wildlife Diseases* 36: 713–722.
- HOBMAIER, A., AND M. HOBMAIER. 1934. *Elaphostromylus odocoilei* n. sp., a new lungworm in black-tail deer (*Odocoileus columbianus*). Description and life history. *Proceedings of the Society for Experimental Biology and Medicine* 31: 509–514.
- JAMES, P. J. 1999. Do sheep regulate the size of their mallophagan louse populations? *International Journal for Parasitology* 29: 869–875.
- LANKESTER, M. W. 2001. Extrapulmonary lungworms of cervids. *In* Parasitic diseases of wild mammals, 2nd Edition, W. M. Samuel, M. J. Pybus, and A. A. Kocan (eds.). Iowa State University Press, Ames, Iowa, pp. 228–278.
- LITTELL, R. C., G. A. MILLEKEN, G. A. STROUP, AND R. D. WOLFINGER. 1996. SAS system for mixed models. SAS Institute, Cary, North Carolina, 663 pp.
- MURRAY, M. D. 1963. Influence of temperature on the reproduction of *Damalimia equi* (Denny). *Australian Journal of Zoology* 11: 183–189.
- NETTLES, V. 1981. Necropsy procedures. *In* Diseases and parasites of white-tailed deer, W. R. Davidson (ed.). Tall Timbers Research Station Miscellaneous Publication 7, Tallahassee, Florida, pp. 6–14.
- PARKER, K. L., M. P. GILLINGHAM, T. A. HANLEY, AND C. T. ROBBINS. 1999. Energy and protein

- balance of free-ranging black-tailed deer in a natural forest environment. *Wildlife Monographs* 143: 1–48.
- PYBUS, M. J., AND W. M. SAMUEL. 1984a. *Parelaphostrongylus andersoni* (Nematoda: Protostrongylidae) and *P. odocoilei* in two cervid definitive hosts. *Journal of Parasitology* 70: 507–515.
- , AND ———. 1984b. Lesions caused by *Parelaphostrongylus odocoilei* (Nematoda: Metastrongyloidea) in two cervid hosts. *Veterinary Pathology* 21: 425–431.
- , W. J. FOREYT, AND W. M. SAMUEL. 1984. Natural infections of *Parelaphostrongylus odocoilei* (Nematoda: Protostrongylidae) in several hosts and locations. *Proceedings of the Helminthological Society of Washington* 51: 338–340.
- SAMUEL, W. M., AND J. B. GRAY. 1988. Efficacy of ivermectin against *Parelaphostrongylus andersoni* (Nematoda, Metastrongyloidea) in white-tailed deer (*Odocoileus virginianus*). *Journal of Wildlife Diseases* 24: 491–495.
- WALKER, M. L., AND W. W. BECKLUND. 1970. Checklist of the internal and external parasites of deer, *Odocoileus hemionus* and *Odocoileus virginianus*, in the United States and Canada. Special publication 1. Index catalogue of medical and veterinary zoology. US Department of Agriculture, Agricultural Research Service, US Government Printing Office, Washington, DC, 45 pp.

Received for publication 3 November 2003.