

## **ESTABLISHING A FOOD-CHAIN LINK BETWEEN AQUATIC PLANT MATERIAL AND AVIAN VACUOLAR MYELINOPATHY IN MALLARDS (ANAS PLATYRHYNCHOS)**

Authors: Birrenkott, Anna H., Wilde, Susan B., Hains, John J., Fischer, John R., Murphy, Thomas M., et al.

Source: Journal of Wildlife Diseases, 40(3) : 485-492

Published By: Wildlife Disease Association

URL: <https://doi.org/10.7589/0090-3558-40.3.485>

---

BioOne Complete ([complete.BioOne.org](https://complete.BioOne.org)) is a full-text database of 200 subscribed and open-access titles in the biological, ecological, and environmental sciences published by nonprofit societies, associations, museums, institutions, and presses.

Your use of this PDF, the BioOne Complete website, and all posted and associated content indicates your acceptance of BioOne's Terms of Use, available at [www.bioone.org/terms-of-use](https://www.bioone.org/terms-of-use).

Usage of BioOne Complete content is strictly limited to personal, educational, and non - commercial use. Commercial inquiries or rights and permissions requests should be directed to the individual publisher as copyright holder.

---

BioOne sees sustainable scholarly publishing as an inherently collaborative enterprise connecting authors, nonprofit publishers, academic institutions, research libraries, and research funders in the common goal of maximizing access to critical research.

## ESTABLISHING A FOOD-CHAIN LINK BETWEEN AQUATIC PLANT MATERIAL AND AVIAN VACUOLAR MYELINOPATHY IN MALLARDS (*ANAS PLATYRHYNCHOS*)

Anna H. Birrenkott,<sup>1</sup> Susan B. Wilde,<sup>2</sup> John J. Hains,<sup>3</sup> John R. Fischer,<sup>4</sup> Thomas M. Murphy,<sup>5</sup> Charlotte P. Hope,<sup>5</sup> Pamela G. Parnell,<sup>6</sup> and William W. Bowerman<sup>1,7</sup>

<sup>1</sup> Department of Forestry and Natural Resources, Graduate Program in Environmental Toxicology, Clemson University, Clemson, South Carolina 29634, USA

<sup>2</sup> Baruch Institute, University of South Carolina, and South Carolina Department of Natural Resources, Marine Resources Division, Charleston, South Carolina 29412, USA

<sup>3</sup> United States Army Corps of Engineers, Engineer Research and Development Center, Environmental Laboratory, Vicksburg, Mississippi 39183, USA and Department of Biological Sciences, Long Hall, Clemson University, Clemson, South Carolina 29634, USA

<sup>4</sup> Southeastern Cooperative Wildlife Disease Study, College of Veterinary Medicine, University of Georgia, Athens, Georgia 30602, USA

<sup>5</sup> South Carolina Department of Natural Resources, 585 Donnelly Drive #2, Green Pond, South Carolina 29446, USA

<sup>6</sup> Clemson Veterinary Diagnostic Center, Clemson University, Columbia, South Carolina 29224-2406, USA

<sup>7</sup> Corresponding author (email: wbowerm@clemson.edu)

**ABSTRACT:** Avian vacuolar myelinopathy (AVM) is a neurologic disease primarily affecting bald eagles (*Haliaeetus leucocephalus*) and American coots (*Fulica americana*). The disease was first characterized in bald eagles in Arkansas in 1994 and then in American coots in 1996. To date, AVM has been confirmed in six additional avian species. Attempts to identify the etiology of AVM have been unsuccessful to date. The objective of this study was to evaluate dermal and oral routes of exposure of birds to hydrilla (*Hydrilla verticillata*) and associated materials to evaluate their ability to induce AVM. Mallards (*Anas platyrhynchos*) were used in all trials; bobwhite quail (*Colinus virginianus*) also were used in one fresh hydrilla material exposure trial. Five trials were conducted, including two fresh hydrilla material exposure trials, two cyanobacteria exposure trials, and a frozen hydrilla material exposure trial. The cyanobacteria exposure trials and frozen hydrilla material trial involved gavaging mallards with either *Pseudanabaena catenata* (live culture), *Hapalosiphon fontinalis*, or frozen hydrilla material with both cyanobacteria species present. With the exception of one fresh hydrilla exposure trial, results were negative or inconclusive. In the 2002 hydrilla material exposure trial, six of nine treated ducks had histologic lesions of AVM. This established the first cause-effect link between aquatic vegetation and AVM and provided evidence supporting an aquatic source for the causal agent.

**Key words:** Avian vacuolar myelinopathy, bald eagle, brain lesion, Cyanobacteria, hydrilla, mallard.

### INTRODUCTION

Avian vacuolar myelinopathy (AVM) is a disease of the central nervous system characterized by microscopic vacuolization of white matter of the brain and spinal cord. Avian vacuolar myelinopathy primarily affects bald eagles (*Haliaeetus leucocephalus*) and American coots (*Fulica americana*). The disease can be sublethal or lethal, although partial or complete clinical recovery may occur in coots with intervention and rehabilitation (Larsen et al., 2002). Clinically, affected birds are ataxic; they typically lack the ability to fly or display reluctance in flight, a staggering gait, and swim in circles (Thomas et al., 1998).

However, lesions may persist even with resolution of clinical signs (Larsen et al., 2002). It is also possible for birds to have characteristic brain lesions upon histopathologic analysis but not exhibit clinical manifestations of the disease (Fischer et al., 2003). Peak occurrence of AVM is early winter, but AVM has been diagnosed from October to April (Rocke et al., 2002).

Occurrence of AVM has been confined to the southeastern United States. It has been diagnosed at 10 reservoirs in North Carolina, South Carolina, Georgia, and Arkansas (USA; Rocke et al., 2002). Avian vacuolar myelinopathy has been diagnosed in various species of birds, primarily raptors and waterfowl. At Woodlake, North

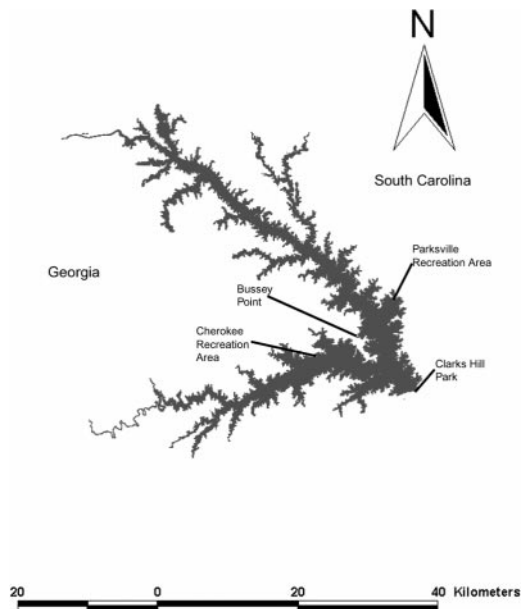


FIGURE 1. Map of J. Strom Thurmond Lake on the border of South Carolina and Georgia (USA) showing collection sites for hydrilla material used in the trials.

Carolina, affected waterfowl species in addition to coots included mallards (*Anas platyrhynchos*), ring-necked ducks (*Aythya collaris*), and buffleheads (*Bucephala albeola*; Augspurger et al., 2003). Additional species diagnosed with AVM from J. Strom Thurmond Lake (JSTL), on the border of South Carolina and Georgia (Fig. 1), included Canada geese (*Branta canadensis*) and great horned owls (*Bubo virginianus*; Fischer et al., 2002). Only one species in the order Charadriiformes, a killdeer (*Charadrius vociferous*) from JSTL, has been diagnosed with AVM (Fischer et al., 2002).

Attempts to determine the cause of AVM have been unsuccessful to date. Substances known to cause intramyelinic lesions in domestic animals and humans, including triethyltin, the rodenticide bromethalin, and the antituberculosis drug isonicotinic acid hydrazide, have not been identified in AVM-affected birds (Thomas et al., 1998). In addition to these agents, two plant species, *Stypandra imbricata* and *Heliochrysum argyrosphaerum*, can

cause intramyelinic lesions; however, these plants do not naturally occur in North America (Fischer et al., 2002). No consistent toxic level of individual pollutants has been found in AVM-affected bald eagles (Thomas et al., 1998). Site-specificity and rapid onset of the disease using sentinel mallards was reported (Rocke et al., 2002). Raptors acquire the disease from ingesting AVM-affected waterfowl tissue (Fischer et al., 2003). We hypothesized that waterfowl contract AVM from ingestion of some factor associated with aquatic plant material.

Two prominent cyanobacteria species were found on hydrilla (*Hydrilla verticillata*) collected from JSTL during an AVM epornitic in November 2001: *Pseudanabaena catenata* and an unknown species within the order Stigonematales (Wilde, unpubl. data). Epiphytic algae communities associated with hydrilla leaves were characterized from monoecious and dioecious hydrilla collections from JSTL. The epiphytic assemblage was comprised primarily of Bacillariophyceae (diatoms), Chlorophyta (green algae), and Cyanophyta (cyanobacteria). During October–November 2001, however, >90% of the leaf surface was covered by a single species of colonial cyanobacteria, the unknown Stigonematalan species (Wilde, unpubl. data). Another filamentous cyanophyte, *P. catenata*, was also abundant during this time period (surface area coverage up to 40%; Wilde, unpubl. data). Thus, the material utilized in this study was a complex of aquatic biota associated with hydrilla and will be referred to throughout this paper as “hydrilla material” or “hydrilla and associated material.”

Stigonematalan species may produce potentially harmful natural products; however, none of these products has been associated with animal morbidity or lesions. *Hapalosiphon fontinalis*, a closely related species within the Stigonematales order, produces cytotoxic compounds including hapalindoles and antibacterial and antimycotic indole alkaloids (Moore et al., 1987). Cultures of *P. catenata* produced as

yet uncharacterized neurotoxins, and bioassays with mice elicited violent tremors (Gorham et al., 1982). The presence of the unknown Stigonematalan species and *P. catenata* was documented at all locations that have had cases of AVM (Wilde, unpubl. data). Therefore, we hypothesized that one or both cyanobacterial species could cause AVM.

The objective of this study was to evaluate dermal and oral routes of exposure of birds to hydrilla and associated materials to establish cause-effect linkages by fulfilling Koch's postulates as applied to toxicology (Evans, 1976).

## MATERIALS AND METHODS

### Animal care

Mallard ducks were leg-banded for identification and wing-clipped. Bobwhite quail (*Colinus virginianus*) were leg-banded. Due to the circumstances of captivity, signs of AVM observed in the field, such as a reluctance to fly and swimming in circles, could not be observed. Birds were sacrificed if they showed neurologic signs associated with AVM. A pre-charged CO<sub>2</sub> chamber was used to sacrifice birds, whether necessitated by clinical signs or at completion of the experiment. Birds were sacrificed individually, and brain extraction occurred immediately after death. Brains were weighed and placed in 10% buffered formalin. All procedures were approved by the Clemson University Animal Research Committee (Animal Use Protocols 20005, 20026, and 2003000005).

### Hydrilla material exposure trial 2001

Mallards and bobwhite quail were used to examine effects of exposure to hydrilla and associated material from JSTL (33°42'N, 82°20'W), an impoundment where AVM has been diagnosed in bald eagles since 1998 and in waterfowl beginning in 2001.

Six adult, pen-raised, male mallards (Ducks and Ducks, Inc., Lake City, Arkansas, USA) and six adult, male, northern bobwhite quail (M & M Game Bird Farm, Toccoa, Georgia, USA) were obtained for these studies. Hydrilla and associated material were collected from JSTL once per week during November 2001 from two regions where AVM mortalities had occurred: Parksville and Cherokee Park Recreation Area (Fig. 1). Vegetation was collected at a water depth ranging from 0.6 to 1.6 m.

Aquatic material was placed in covered plastic containers and transported to the Clemson Institute of Environmental Toxicology (CIET; Clemson University, Clemson, South Carolina, USA). The hydrilla and associated material was then placed in a large plastic wading pool and left outdoors uncovered.

Commercial feed (Purina® Flight Conditioner, St. Louis, Missouri, USA) was provided ad libitum to ducks and quail, and deionized water was provided for drinking and in swimming tanks. Six ducks were divided into three groups of two ducks each. The control group was not exposed to hydrilla. The treatment groups were fed hydrilla material ad libitum from Parksville Recreation Area or Cherokee Park Recreation Area. Hydrilla and associated material were placed in the swim tanks of mallards for 4 wk; hydrilla material was consistently consumed and comprised approximately 50% of the duck's diet. The hydrilla material was freshened or replaced twice daily.

Six quail were divided into a control group and two treatment groups of two birds each. The control group was not exposed to hydrilla material. For the treatment groups, 20 g of hydrilla material was placed in bathing troughs that were filled with deionized water for 5 wk. The hydrilla material in the troughs was discarded and replenished twice per week. Quail were never observed consuming the material but were observed in dermal contact with it for an estimated 1 hr/day. Birds were observed daily for behavioral changes during two 1-hr periods, at which time pens were cleaned and water and feed were replenished.

### Gavage trials

Algal cultures were obtained either from hydrilla collected in JSTL or from laboratory cultures. Cultures were maintained in 100 ml flasks with liquid BG 11 medium at 20 C with 12 hr light and 12 hr dark cycles. *Pseudanabaena catenata* was cultured from hydrilla collected from JSTL in December 2001. *Haplo-siphon fontinalis* isolated from hydrilla from JSTL could not be cultured in large quantities, so frozen hydrilla and associated material from JSTL containing an unidentified Stigonematalan species and *P. catenata* was homogenized and used for gavage. A freeze-dried culture of *H. fontinalis* was provided by Dr. Thomas Hemscheidt (University of Hawaii, Honolulu, Hawaii). This culture of *H. fontinalis* was isolated from terrestrial soil samples from the Marshall Islands (9°00'N, 168°00'E) and was used for our studies because local isolates could not be obtained. Trials were performed first using the culture of *P. catenata*, then with the

hydrilla and epiphytic cyanobacterial mixture, and finally with the freeze-dried cells of *H. fontinalis*.

For each trial, 12 adult male mallard ducks (Whistling Wings, Hanover, Illinois, USA) were purchased and preconditioned for 1 wk and treated for 2 wk. Ducks were housed three per pen by treatment group. Control ducks were dosed with 5 ml of deionized water via oral gavage three times per week. Treatment groups were gavaged with 2 ml of algae preparation followed by 3 ml of deionized water, either once (Group 1), twice (Group 2), or three times (Group 3) per week. In the *H. fontinalis* trial, the freeze-dried cells were reconstituted with deionized water prior to dosing. Each dose consisted of 0.2 g *H. fontinalis* in 2 ml of deionized water. Ducks were observed daily for behavioral changes during two 1-hr periods, at which time pens were cleaned and water and duck feed were replenished.

#### Hydrilla material exposure trial 2002

A second exposure trial was conducted from 17 October to 3 December 2002 using hydrilla and associated material collected from three locations in JSTL: Bussey Point, Cherokee Park Recreation Area, and Clarks Hill Park (Fig. 1). These sites were chosen because of occurrence of AVM-related bird deaths and presence of extensive hydrilla and epiphytic Stigonematalan species in plant collections conducted during September 2002. Hydrilla and associated material were collected once per week for 7 wk from JSTL using a rake from a depth of up to 1.5 m. Hydrilla was selected for heavy coverage of the unknown Stigonematalan species on the leaves (cyanobacterial colonies covering and estimated 50–90% of leaf surface). Upon collection, the relative abundance of the Stigonematalan species was estimated, and the vegetation was stored in plastic containers and transported to CIET. The relative abundance of the unknown Stigonematalan species on hydrilla at each location was confirmed microscopically. The vegetative material was stored in wading pools, and deionized water was added to prevent desiccation.

Treatment and control groups of three birds each were given access to feed twice per day for a total of 2 hr. Three treatment groups received hydrilla and associated material from one of the three JSTL collection locations and the control ducks received no hydrilla material. The hydrilla and associated material given to the treatment ducks was placed in 40 l plastic containers filled with deionized water. Hydrilla was available to each treatment group ad libi-

tum and was freshened and/or replaced three times per day. We estimated that the hydrilla material comprised 60–70% of the ducks' diet. Although the relative abundance of the unknown Stigonematalan species present on hydrilla from each of the three locations in JSTL was recorded, the feeding regime was not manipulated in an attempt to expose ducks to similar amounts of cyanobacteria. Ducks were observed for behavioral changes daily during two 1-hr periods, at which time pens were cleaned, water was replenished, and duck feed was offered or taken away in accordance with the feeding regime.

#### Tissue collection and processing

One half of the brain, portions of the spinal cord, and sciatic nerve were fixed in 10% buffered formalin, embedded in paraffin, sectioned at 5  $\mu$ m, stained with hematoxylin and eosin, and examined by light microscopy (Southeastern Cooperative Wildlife Disease Study [SCWDS], the University of Georgia, Athens, Georgia). For electron microscopy, samples of formalin-fixed optic lobe were placed in 2% glutaraldehyde, 2% paraformaldehyde, and 0.2% picric acid in a 0.1 M cacodylate buffer (pH 7.2). Following fixation, the samples were postfixed in 1% osmium tetroxide, dehydrated in a series of alcohols, stained en bloc with uranyl acetate, and embedded in epoxy resins. Sections 1- $\mu$ m thick were stained with toluidine blue and examined by light microscopy to select areas with vacuolar lesions of white matter. Ultrathin sections of these areas were stained with uranyl acetate and lead citrate and examined with a JEOL Model JEM-1210 transmission electron microscope (JEOL USA, Inc., Peabody, Massachusetts, USA).

In the 2001 hydrilla exposure trial, liver, kidney, spleen, heart, and gonad were collected. In all gavage trials, liver and kidney were collected. These tissues were packaged individually in aluminum foil and then placed in plastic bags (Whirlpaks<sup>®</sup>, Nasco, Fort Atkins, Wisconsin, USA), labeled, and frozen at  $-20^{\circ}$  C.

In the 2002 hydrilla material exposure trial, additional tissues were collected and fixed in phosphate-buffered saline with 4% paraformaldehyde and examined microscopically (Clemson Veterinary Diagnostic Center, Columbia, South Carolina, USA). These included heart, air sac, gizzard, cecum, ileum, proventriculus, spleen, duodenum, pancreas, esophagus, crop, gonad, adrenal gland, and lung. These tissues were routinely processed through an automated system, embedded in paraffin, sectioned at 4  $\mu$ m, and stained with hematoxylin and eosin.

TABLE 1. Experiment, treatment, number of birds, and presence or absence of avian vacuolar myelinopathy (AVM) 2001–02.

Experiment	Treatment	Number of ducks	Number of quail	AVM-positive		AVM-negative	
				Ducks	Quail	Ducks	Quail
Hydrilla exposure trial 2001	Control <sup>a</sup>	2	2				
	Replicate 1	2	2	Inconclusive <sup>b</sup>	0	Inconclusive	6
Cyanobacteria gavage trial <i>Pseudanabaena catenata</i>	Control <sup>a</sup>	3	0	0	NA <sup>c</sup>	3	NA
	Group 1	3	0	0	NA	3	NA
	Group 2	3	0	0	NA	3	NA
	Group 3	3	0	0	NA	3	NA
Hydrilla gavage trial ( <i>P. catenata</i> + unknown Stigonematalan species)	Control	3	0	0	NA	3	NA
	Group 1	3	0	0	NA	3	NA
	Group 2	3	0	0	NA	3	NA
	Group 3	3	0	0	—	3	—
Cyanobacteria gavage trial ( <i>Hapalosiphon fontinalis</i> )	Control <sup>a</sup>	2	0	0	NA	2	NA
	Group 1	3	0	0	NA	3	NA
	Group 2	3	0	0	NA	3	NA
	Group 3	3	0	0	NA	3	NA
Hydrilla exposure trial 2002	Control <sup>a</sup>	3	0	0	NA	3	NA
	Group 1	3	0	1	NA	2	NA
	Group 2	3	0	2	NA	1	NA
	Group 3	3	0	3	NA	0	NA

<sup>a</sup> Control brains from all trials were unequivocally negative for AVM.

<sup>b</sup> Microscopic examination of brain yielded equivocal evidence of AVM in two of four treated ducks.

<sup>c</sup> Not applicable.

## RESULTS

### Hydrilla material exposure trial 2001

No clinical manifestation of AVM was observed during this study. Microscopic examination of brain yielded equivocal results in two of four ducks in the treatment group. Suspected AVM lesions could not be confirmed due to artifactual changes consistent with postmortem decomposition and physical damage to the specimens. Lesions were not apparent in the brains in any of the quail (Table 1).

### Gavage trials

No clinical signs were observed in any of the ducks during the course of the gavage trials. Microscopic lesions of AVM were not apparent in brain tissue of any of the ducks (Table 1).

### Hydrilla material exposure trial 2002

Seventeen days after the trial began, one duck in the treatment group receiving material from Clarks Hill was ataxic. No

other ducks were observed with neurologic signs during the remainder of the study. Of the nine treatment ducks, six had histologic lesions in the brain consistent with AVM: three of three from the group receiving material from Clarks Hill; two of three from the group receiving material from Cherokee Park; and one of three from group receiving material from Bussey Point. No significant lesions were observed in any other tissues from treated ducks. Histologic lesions were not apparent in control ducks (Table 1). There was a significant difference ( $P=0.09$ , Fisher's exact test) in occurrence of lesions between treated and control groups.

## DISCUSSION

The results of this study confirm that AVM lesions develop in some ducks following ingestion of aquatic vegetation and associated materials collected from a lake during an AVM outbreak. This, in combination with the results of Fischer et al.

(2003), completes the food chain linkage of AVM from aquatic vegetation to waterfowl to raptors.

Much research still needs to be done to elucidate the exact cause and consequences of AVM. This study confirmed that an undetermined factor associated with hydrilla is responsible for AVM; the next step is to determine what that factor is. The factor may be a cellular constituent of an aquatic organism or possibly a toxic metabolite of the aquatic organism. If a toxic metabolite, it may be synthesized only under certain environmental or growth conditions. Elucidation of the factor will require intensive biochemical investigation. Further, it is not known whether mammals are susceptible to contracting AVM. Both avenues of research will have major implications for natural resources management.

Avian vacuolar myelinopathy was reproduced in treatment animals in one of five trials. In the 2001 hydrilla material exposure trial, the quail were exposed by dermal routes, but there was no evidence of AVM. Some possible explanations are that the route of exposure to material causing AVM is not dermal, the hydrilla material the quail were exposed to did not contain the etiologic agent, the hydrilla material contained the etiologic agent but lacked sufficient quantities to cause the disease, or the hydrilla material contained the etiologic agent but the frequency and/or duration of exposure was not sufficient to cause the disease. Lesions in two treatment ducks in this trial were equivocal for AVM, but artifactual changes in the brain precluded diagnosis.

No animals from the gavage trials had AVM-like brain lesions. These results do not necessarily rule out the hypothesis that a cyanobacterial toxin is responsible for AVM; the etiologic agent may have been present but not toxic, the preparation may not have contained the agent in sufficient quantities to produce the disease, or the frequency and/or duration of exposure was not sufficient to cause the disease.

The 2002 hydrilla material exposure tri-

al resulted in histologic lesions in six of nine ducks, confirming that the etiologic agent was present in sufficient quantities in the hydrilla material fed to the birds and they were exposed for a sufficient frequency and duration. Because animals were housed in groups of three, it was impossible to know the quantity of hydrilla material consumed by each individual, and therefore a dose-response relationship could not be established.

A cyanobacterial toxin, possibly from the undescribed *Stigonematalan* species, may be the factor associated with aquatic vegetation responsible for causing AVM. This statement is based on the abundance of the unknown *Stigonematelan* species on hydrilla leaves in JSTL coinciding with AVM occurrence. Future studies that include separately dosing treatment animals with hydrilla containing the epiphytic unknown *Stigonematales* colonies and "clean" hydrilla—that is, hydrilla devoid of the suspect *Stigonematalan* species—will be important for determination of whether a metabolite or metabolites produced by this cyanobacteria are actually responsible for the disease. However, it is also possible that an unobserved organism or toxin not associated with the cyanobacteria occurred in some association with JSTL hydrilla, and that this unidentified organism is responsible for AVM.

Cyanobacterial toxins as the cause of wildlife mortality or disease can be difficult to recognize. Although it is poorly understood what factors cause cyanobacteria to produce toxins, toxin production may be regulated by genetics and influenced by environmental changes. In a bloom of cyanobacteria that consists of one species, it is possible to have strains that are toxic and strains that are nontoxic, and cyanobacteria can produce more than one toxin simultaneously. Algal toxins are generally released during cell senescence, lysis, or death (Sivonen and Jones, 2000).

Certain aspects of diet and breeding behavior may make bald eagles susceptible to AVM. Eagles prey on fish; however,

when wintering coots arrive, they become a dominant component of the bald eagle's diet at JSTL. Eagles cue in on struggling prey, such as weak, flightless, AVM-affected coots; these moribund coots are presumably toxic to eagles when ingested. The pathway of AVM transmission to raptors is by ingestion of affected coots or waterfowl (Fischer et al., 2003). South Carolina has a nonmigratory bald eagle population with a winter breeding season coinciding with AVM outbreaks. Nesting eagles are dedicated to a territory for 7–8 mo/year because of breeding activities; therefore, if AVM occurs in the territory, the eagles are likely to be exposed. Offspring may also be at risk because they return to their natal sites each breeding season. Eagles that nest in other locations but use affected river drainages to forage for prey are also at risk.

The primary component of the winter diet of American coots is aquatic vegetation. When available, coots feed heavily on hydrilla (Esler, 1989). Unlike some other waterfowl, coots can dive under the surface of the water to feed on submersed vegetation. Coots exhibit a generalist foraging strategy: they are terrestrial granivores in the fall and shift to aquatic herbivory in the winter with migration (Yee, 2001). Hydrilla grows to the water surface by August and is senescent in early spring. This makes the vegetation readily accessible to coots.

The spread of nuisance aquatic plants, including hydrilla, and related water use problems have greatly impacted the JSTL area. Hydrilla was first discovered in JSTL in 1995; extent of coverage was 22 ha. Despite aggressive herbicide applications in 1996 and 1997, by October 2000 hydrilla covered 5.5% (1,580 ha) of JSTL, and by October 2002 approximately 7.2% (2,070 ha) of the reservoir was impacted by hydrilla. Since 1998, herbicides have only been applied to public recreation areas and around private docks. Annual herbicide applications have been to less than 32 surface ha (Dean, pers. comm.).

Occurrence of AVM may be underestimated due to lack of observation of clinical signs in affected birds and recovery of carcasses. It may be difficult to observe clinical signs in eagles and coots and, in the field, coots may have histologic lesions in the brain without showing clinical signs (Fischer et al., 2002). This is consistent with absence of clinical signs in the majority of AVM-affected ducks in the 2002 hydrilla material exposure trial. Modifications in behavior due to sublethal effects of toxicity could make affected birds more susceptible to predation (Brewer et al., 1996). Because eagles and coots are mobile, they may die away from reservoir shorelines in inaccessible areas where they are not discovered. Also, carcasses may be scavenged. If natural resource managers and the public are not aware of the disease and its manifestations, it may go unnoticed or unreported.

Since 1994, AVM has been diagnosed in 10 reservoirs in Arkansas, Georgia, North Carolina, and South Carolina, and these reservoirs have some common features. All locations where AVM has been documented are man-made. All but one reservoir contains extensive aquatic vegetation dominated by an exotic aquatic macrophyte species. Four of these lakes are dominated by hydrilla, two have large stands of egeria (*Egeria densa*), and three lakes contain Eurasian watermilfoil (*Myriophyllum spicatum*).

Results from the 2001 hydrilla material exposure trial were inconclusive because of problems in processing brains from treatment ducks, and thus the inability to accurately make a positive diagnosis of AVM. Modifications to the experimental design from the 2001 to 2002 hydrilla material exposure trials included a longer trial duration (from 4 to 7 wk), less exposure to commercial duck feed (from ad libitum to 1 hr twice daily), and increased exposure to hydrilla material (from hydrilla material fed twice per day to hydrilla material replaced three times per day).

The search for the etiology of AVM be-



gan with deaths of eagles in Arkansas at DeGray Lake and continues today. No consistent significant level of any individual pollutant has been found (Thomas et al., 1998). A total of 90 bald eagles have been diagnosed with AVM; the number of coots deaths is unknown but is estimated to be in the thousands (Rocke et al., 2002). At JSTL, 27 bald eagles have been confirmed with or suspected of having AVM since 1998 (Birrenkott, 2003). This represents a loss of five of 10 bald eagle breeding territories at JSTL, which translates into a considerable decrease in the eagle population along the Savannah River Basin. Although these experiments have established a cause-effect linkage between eating aquatic vegetation and the development of AVM in waterfowl, much more work is necessary to determine the exact etiologic agent that causes AVM.

#### ACKNOWLEDGMENTS

Funding was provided by the College of Agriculture, Forestry, and Life Sciences, Clemson University, and through Public Service Activities. We thank Army Corps of Engineers personnel, including A. Dean, R. Waters, D. Williamson, and S. Willard; M. Hall for assistance with necropsy; S. Ellis for assistance with histology; A. Johnson, members of the Wildlife Toxicology Laboratory, K. Bryant, and B. Williams; SCWDS staff, especially L. Lewis-Weis; Clemson Veterinary Diagnostic Center; Godley-Snell Research Center staff; and T. Hemscheidt and J. Komarek.

#### LITERATURE CITED

- AUGSPURGER, T. A., J. R. FISCHER, N. J. THOMAS, L. SILEO, R. E. BRANNIAN, K. J. G. MILLER, AND T. E. ROCKE. 2003. Vacuolar myelinopathy in waterfowl from a North Carolina impoundment. *Journal of Wildlife Diseases* 39: 412–417.
- BIRRENKOTT, A. H. 2003. Investigating the cause of avian vacuolar myelinopathy and the consequences to the South Carolina bald eagle (*Haliaeetus leucocephalus*) population. Masters Thesis, Clemson University, Clemson, South Carolina, 50 pp.
- BREWER, R. A., L. L. CARLOCK, M. J. HOOPER, L. W. BREWER, G. P. COBB, AND R. J. KENDALL. 1996. Toxicity, survivability, and activity patterns of northern bobwhite quail dosed with the insecticide terbufos. *Environmental Toxicology and Chemistry* 15: 723–753.
- ESLER, D. 1989. An assessment of American coot herbivory of hydrilla. *Journal of Wildlife Management* 53: 1147–1149.
- EVANS, A. S. 1976. Causation and disease: The Henle-Koch postulates revised. *Yale Journal of Biological Medicine* 49: 175–195.
- FISCHER, J. R., L. A. LEWIS, T. AUGSPURGER, AND T. E. ROCKE. 2002. Avian vacuolar myelinopathy: A newly recognized fatal neurological disease of eagles, waterfowl, and other birds. *Transactions of the North American Wildlife and Natural Resources Conference* 67: 51–61.
- \_\_\_\_\_, \_\_\_\_\_, AND C. M. TATE. 2003. Experimental vacuolar myelinopathy in red-tailed hawks. *Journal of Wildlife Diseases* 39: 400–406.
- GORHAM, P. R., S. MCNICHOLAS, AND E. A. DALE ALLEN. 1982. Problems encountered in searching for new strains of toxic planktonic Cyanobacteria. *South African Journal of Science* 78: 357–362.
- LARSEN, R. S., F. B. NUTTER, T. AUGSPURGER, T. E. ROCKE, L. TOMLINSON, N. J. THOMAS, AND M. K. STOSKOPF. 2002. Clinical features of avian vacuolar myelinopathy in American coots. *Journal of American Veterinary Medicine Association* 221: 80–85.
- MOORE, R. E., C. CHEUK, X. G. YANG, G. M. L. PATTERSON, R. BONJOUKLIAN, T. A. SMITKA, J. S. MYNDERSE, R. S. FOSTER, N. D. JONES, J. K. SWARTZENDRUBER, AND J. B. DEETER. 1987. Hapalindoles, antibacterial and antimycotic alkaloids from the cyanophyte *Hapalosiphon fontinalis*. *Journal of the American Chemical Society* 52: 1036–1043.
- ROCKE, T. E., N. J. THOMAS, T. AUGSPURGER, AND K. MILLER. 2002. Epizootiologic studies of avian vacuolar myelinopathy in waterbirds. *Journal of Wildlife Diseases* 38: 678–684.
- SIVONEN, K., AND G. JONES. 1999. Cyanobacterial toxins in water. In *Toxic cyanobacteria in water: A guide to their public health consequences, monitoring and management*, I. Chorus and J. Bartram (eds.). Spon Press, London, UK, pp. 41–111.
- THOMAS, N. J., C. U. METEYER, AND L. SILEO. 1998. Epizootic vacuolar myelinopathy of the central nervous system of bald eagles (*Haliaeetus leucocephalus*) and American coots (*Fulica americana*). *Veterinary Pathology* 35: 479–487.
- YEE, C. G. 2001. Diet composition and changes in body components of American coots wintering in southwestern Arkansas. Masters Thesis, Texas A&M University—Kingsville, Kingsville, Texas, 80 pp.

Received for publication 10 October 2003.