

## **Malignant Mesenchymal Tumors in Two White-tailed Jack Rabbits (*Lepus townsendii*)**

Authors: Jardine, Claire, Wobeser, Gary A., and Simko, Elemir

Source: Journal of Wildlife Diseases, 40(4) : 754-758

Published By: Wildlife Disease Association

URL: <https://doi.org/10.7589/0090-3558-40.4.754>

---

The BioOne Digital Library (<https://bioone.org/>) provides worldwide distribution for more than 580 journals and eBooks from BioOne's community of over 150 nonprofit societies, research institutions, and university presses in the biological, ecological, and environmental sciences. The BioOne Digital Library encompasses the flagship aggregation BioOne Complete (<https://bioone.org/subscribe>), the BioOne Complete Archive (<https://bioone.org/archive>), and the BioOne eBooks program offerings ESA eBook Collection (<https://bioone.org/esa-ebooks>) and CSIRO Publishing BioSelect Collection (<https://bioone.org/csiro-ebooks>).

Your use of this PDF, the BioOne Digital Library, and all posted and associated content indicates your acceptance of BioOne's Terms of Use, available at [www.bioone.org/terms-of-use](http://www.bioone.org/terms-of-use).

Usage of BioOne Digital Library content is strictly limited to personal, educational, and non-commercial use. Commercial inquiries or rights and permissions requests should be directed to the individual publisher as copyright holder.

---

BioOne is an innovative nonprofit that sees sustainable scholarly publishing as an inherently collaborative enterprise connecting authors, nonprofit publishers, academic institutions, research libraries, and research funders in the common goal of maximizing access to critical research.

## Malignant Mesenchymal Tumors in Two White-tailed Jack Rabbits (*Lepus townsendii*)

Claire Jardine,<sup>1,2</sup> Gary A. Wobeser,<sup>1</sup> and Elemir Simko<sup>1</sup> <sup>1</sup> Department of Veterinary Pathology, Western College of Veterinary Medicine, University of Saskatchewan, 52 Campus Drive, Saskatoon, Saskatchewan, Canada, S7N 5B4; <sup>2</sup> Corresponding author (email: claire.jardine@usask.ca)

**ABSTRACT:** Two white-tailed jack rabbits (*Lepus townsendii*) with proliferative lesions in their internal organs were submitted to the Canadian Cooperative Wildlife Health Centre (Saskatoon, Saskatchewan, Canada) for necropsy because of concern that dogs that had contact with the hares might have been exposed to an infectious disease. In both hares, the primary diagnosis was neoplasia. One hare had metastatic leiomyosarcoma and uterine fibroma, the other had metastatic mesenchymal tumors involving the liver and mesentery. These cases represent the only reports of malignant mesenchymal tumors in white-tailed jack rabbits that we have found in the literature.

**Key words:** Leiomyosarcoma, *Lepus townsendii*, mesenchymal tumor, neoplasia, uterine fibroma, white-tailed jack rabbit.

Between 1997 and 2002, only two white-tailed jack rabbits (*Lepus townsendii*) were submitted to the Canadian Cooperative Wildlife Health Centre at the Western College of Veterinary Medicine (University of Saskatchewan, Saskatoon, Saskatchewan, Canada). In both instances, the person submitting the hare was concerned about the possibility of infectious diseases.

In March 2000, a farmer from Delisle (Saskatchewan, Canada, 51°55'N, 107°08'W) shot a male white-tailed jack rabbit that had been caught by his dog. He noticed lesions in the internal organs, contacted his veterinarian, and submitted the abdominal and thoracic viscera for necropsy the following day. The farmer was concerned because his dog had eaten portions of the hare and had become ill. Tularemia was listed as a possible differential diagnosis on the history.

At necropsy, approximately 30% of the liver contained multifocal to coalescing green-yellow necrotic foci that were surrounded by firm, white tissue. The gall

bladder was moderately distended. There were also multifocal, white, homogenous, nodular masses up to 3 cm in diameter in the mesentery. The lungs were diffusely congested. No gross lesions were seen in the kidney, lymph node, intestine, stomach, heart, and testes. Affected tissue samples were submitted for aerobic and anaerobic culture and samples from all tissues examined were fixed in 10% neutral buffered formalin and submitted for standard histologic processing.

No significant bacteria were cultured from the liver or mesentery, and samples cultured on cysteine heart agar and in *Yersinia* enrichment broth followed by subculture onto blood agar and McKonkey agar were negative for *Francisella* and *Yersinia* species, respectively.

Histologically the liver was affected by multifocal to coalescing infiltrative and obliterative neoplasia that invaded and replaced hepatocellular parenchyma and, in some areas, surrounded and invaded vascular walls. Haphazardly arranged in densely cellular bundles, neoplastic fusiform to angular cells had large vesicular nuclei with prominent nucleoli and sparse cytoplasm with indistinct cellular borders. These cells produced eosinophilic intercellular fibrillar matrix. There were approximately three mitotic figures per microscopic high-power field of view (40×). In the central areas of the neoplastic foci, there were multifocal to coalescing areas of necrosis (Fig. 1). The remaining hepatic parenchyma not affected by the neoplastic process had multifocal periportal mild to moderate lymphoplasmacytic inflammatory infiltration. The mesenteric masses consisted of similar neoplastic cells with abundant necrosis and hemorrhage. They were

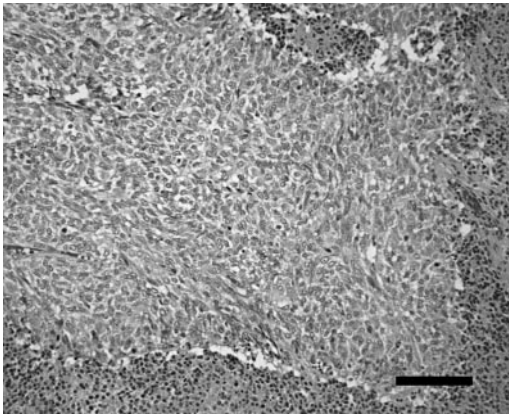


FIGURE 1. Mesenchymal neoplasia in the liver of a white-tailed jack rabbit showing fusiform cells haphazardly arranged in densely cellular bundles. The tissue surrounding the tumor is necrotic. Bar=100  $\mu$ m.

suspected to be remnants of the mesenteric lymph nodes completely obliterated by the aggressively invasive malignant neoplasia. The lungs and kidney were diffusely congested. No microscopic lesions were present in the intestine, stomach, heart, lymph node, and testis.

Formalin-fixed, paraffin-embedded histologic sections of these anaplastic tumors were submitted for immunohistochemical examination using standard methods for avidin biotin complex-immunoperoxidase staining (Haines and Chelack, 1991). The masses were positive for vimentin intermediate filaments using mouse antivimentin clone V9 antibody (Sigma Chemicals, St. Louis, Missouri, USA) (1:10,000 dilution) and negative for keratin intermediate filaments using rabbit antipancytokeratin antibody (Dako Corporation, Carpinteria, California, USA) (1:10,000 dilution). Smooth-muscle-specific actin and desmin were both negative using mouse anti-smooth-muscle actin antibody (1:50 dilution) (NovoCastra Lab Ltd., UK), and anti-rabbit desmin antibody (1:800 dilution) (Dako), respectively. Positive immunohistochemical staining of normal intestinal and biliary epithelia was present with antipancytokeratin, and positive immunohistochemical staining of normal intestinal

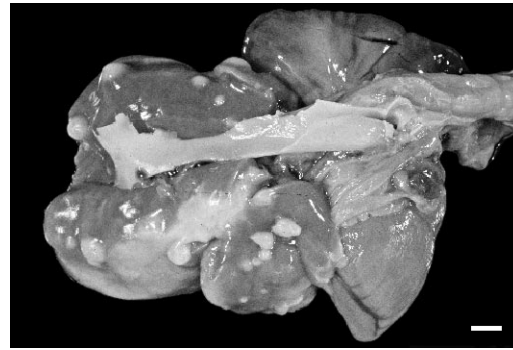


FIGURE 2. Metastatic leiomyosarcoma in the lungs of a white-tailed jack rabbit showing multiple, white nodules scattered throughout the lung parenchyma. Bar=1 cm.

smooth muscle was present with anti-smooth-muscle actin antibodies and anti-desmin antibodies (internal positive controls). Based on microscopic and immunohistochemical characteristics, the tumors were diagnosed as metastatic mesenchymal tumors.

A farmer from Borden (Saskatchewan, Canada; 52°24'N, 107°14'W) submitted a white-tailed jack rabbit for necropsy in February 2002. The farmer thought that the rabbit was acting strangely because it had run into a grain bin and died while being chased by a dog. The farmer was concerned for his dog, which had contact with the rabbit.

The 4-kg adult female white-tailed jack rabbit was in adequate body condition. The thoracic cavity contained approximately 300 ml of blood. The lungs contained multiple, firm, round, white, homogenous nodules ranging from 0.1 cm to 1 cm in diameter that were easily shelled out from the surrounding pulmonary parenchyma (Fig. 2). The right cranial lung lobe was replaced by a firm, red, 3-cm by 2-cm mass containing a necrotic center. There were three other similar, approximately 1-cm-diameter, masses scattered throughout the lung. In addition, there was a 1.5-cm diameter gray-to-red mass that extended from the wall of the right uterine horn (Fig. 3). The right uterine horn was distended and contained a small

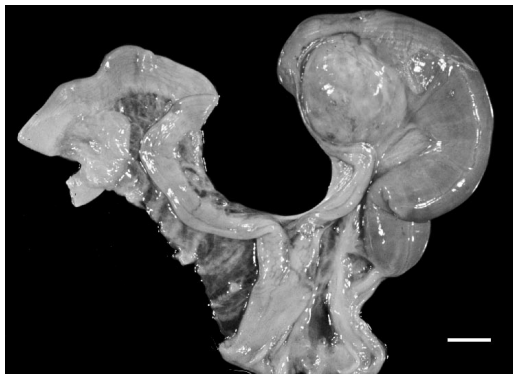


FIGURE 3. Uterine fibroma in a white-tailed jack rabbit. Bar=1 cm.

amount of green/black fluid and, what was presumed to be, the remnants of placental tissues. Samples from the uterus and lungs were submitted for aerobic and anaerobic culture and samples from these tissues and intestine, stomach, liver, kidney, brain, and muscle were submitted for standard histologic processing.

No significant bacteria were cultured from the lungs. Histologic examination of the lung revealed multiple neoplastic metastases consisting of variably sized, densely cellular, expansile, well-demarcated, spindle-cell tumors scattered throughout the parenchyma. The densely packed, spindle shaped, neoplastic cells were arranged in haphazard streams and intersecting bundles (Fig. 4). Cell borders were indistinct and the cytoplasm was eosinophilic and vacuolated. Nuclei were large, centrally located, and cigar shaped. There were occasional multinucleate cells and rare mitotic figures. The neoplastic mass replacing the entire right cranial lung lobe had multifocal necrosis and hemorrhage.

Fixed tissues from the lung mass were submitted for immunohistochemical examination using the same markers described for the first case. The tumor cells were positive for vimentin intermediate filaments and negative for keratin intermediate filaments, indicative of a mesenchymal cell tumor, and stained positively for smooth-muscle-specific actin and desmin, a pattern of expression consistent with

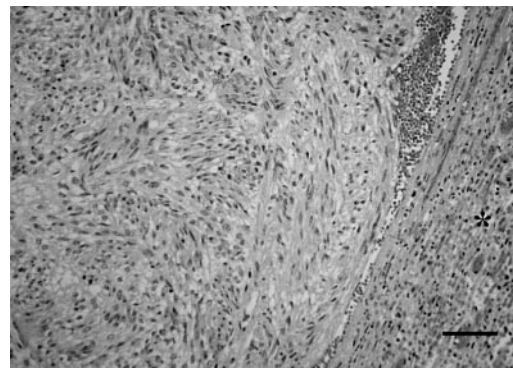


FIGURE 4. Metastatic leiomyosarcoma in the lungs of a white-tailed jack rabbit showing densely packed, fusiform neoplastic cells with cigar-shaped nuclei. The tumor is compressing adjacent lung parenchyma (\*). Bar=100  $\mu$ m.

smooth-muscle origin (Cullen et al., 2002). Accordingly, neoplasia in the lungs was diagnosed as metastatic leiomyosarcoma based on gross, microscopic, and immunohistochemical features.

A mixed bacterial population consisting of *Escherichia coli*, *Enterobacter* spp., and Gram-negative anaerobic rods were isolated from the uterus. There was mild, chronic, active endometritis characterized by congestion/hyperemia and diffuse mild inflammatory infiltration consisting of lymphocytes, plasma cells, hemosiderin-laden macrophages, and heterophils (migrating to the uterine lumen). The expansile well-demarcated spindle cell mass in the wall of the right uterine horn was affected by large areas of coagulation necrosis with multifocal mineralization and peripheral hemorrhage and infiltration by foamy macrophages, often containing ceroid intracytoplasmic pigment. Well-differentiated spindle cells produced abundant intercellular collagenous matrix that was positively stained with Masson's trichrome technique. Immunohistochemical staining of the uterine mass was negative for smooth-muscle actin and desmin. Accordingly, the uterine mass was diagnosed as a fibroma, unrelated to the pulmonary masses. No microscopic lesions were present in the



stomach, intestines, brain, kidney, liver, heart, and skeletal muscle

Prior to histologic examination of the tissues of the second case, we hypothesized that the uterine mass was the primary tumor site with metastasis to the lungs. However, based on histologic, histochemical, and immunohistochemical differences between neoplasms in the uterus and lungs, we are confident that this is not the case. There are two different neoplastic processes occurring in this hare, a benign fibroma in the uterus and a metastatic leiomyosarcoma in the lungs. Although we were not able to definitively determine the primary site of the leiomyosarcoma, based on the tissues we examined, we hypothesize that the large tumor obliterating the right pulmonary lobe may be the primary site. Although rare, leiomyosarcomas are the most common primary pulmonary sarcomas in humans (Etienne-Mastroianni et al., 2002), and Newman and West (2001) reported a primary pulmonary leiomyosarcoma with pulmonary metastasis and no other related lesions in a rock dove (*Columba livia*).

Malignant sarcomas, including a hemangioendothelioma (Pletcher and Murphy, 1984) have been diagnosed in wild rabbits but, to the best of our knowledge, this is the first report of malignant mesenchymal tumors in wild hares. The only tumors described in *Lepus* spp. have been viral-induced tumors, including poxvirus fibromas on three African hares (*Lepus capensis*) (Karstad et al., 1977), and Beard and Rous (1935) reported that *Lepus californicus* was susceptible to experimental infection with papillomatosis.

The cause of these tumors is unknown. Viruses are an important cause of tumors found in wild lagomorphs (Beard and Rous, 1935; Karstad et al., 1977), but we did not investigate this possibility in these two cases. Other possible tumor etiologies include increased hormone levels or chemical agents. Zook and Hertz (1987) experimentally induced malignant sarcomas (deciduomas) in domestic rabbits

using estrogen progestin treatments, and chemical agents such as polychlorinated biphenyls have been suggested as potential causal agents for neoplasia in marine mammals (Lair et al., 1998).

Neoplasia in wildlife is not considered to be common. Fowler (1987) suggested that the relatively short lifespan of wild mammals compared with their captive counterparts, in combination with the few necropsies done on wild animals, may help explain this rarity. Indeed, only two white-tailed jack rabbits have been submitted to our lab for necropsy between 1997 and 2002 and, in both, the carcasses or portions were submitted only out of concern that dogs, which had had contact with the hares, may have contracted an infectious disease. In both cases, the animals were diagnosed with neoplasia. We suspect that hunters seeing gross lesions consistent with infectious disease (or neoplasia) often discard the carcass without obtaining a definitive diagnosis.

We thank Ian Shirley for technical assistance with photography. Specimens from these cases are on file in the Department of Veterinary Pathology, Western College of Veterinary Medicine, accession numbers D008439 and D024905.

#### LITERATURE CITED

- BEARD, J. W., AND P. ROUS. 1935. Effectiveness of the Shope papilloma virus in various American rabbits. *Proceedings of the Society for Experimental Biology and Medicine* 33: 191–193.
- CULLEN, J. J., R. PAGE, AND W. MISDORP. 2002. An overview of cancer pathogenesis, diagnosis, and management. *In* Tumors in domestic animals, 4th edition, D. J. Meuten (ed.). Iowa State Press, Iowa, pp. 3–44.
- ETIENNE-MASTROIANNI, B., L. FALCHERO, L. CHALABREYSSE, R. LOIRE, D. RANCHERE, P. SOUQUET, AND J. CORDIER. 2002. Primary sarcomas of the lung a clinicopathologic study of 12 cases. *Lung Cancer* 38: 283–289.
- FOWLER, M. E. 1987. Zoo animals and wildlife. *In* Veterinary cancer medicine, 2nd edition, G. H. Theilen and B. R. Madwell (eds.). Lea and Febiger, Philadelphia, Pennsylvania, pp. 649–662.
- HAINES, D. M., AND B. J. CHELAK. 1991. Technical considerations for developing enzyme immunohistochemical staining procedures on formalin-

- fixed paraffin-embedded tissues for diagnostic pathology. *Journal of Veterinary Diagnostic Investigations* 3: 101–112.
- KARSTAD, L., J. THORSEN, G. DAVIES, AND J. S. KAMINJOLO. 1977. Poxvirus fibromas on African hares. *Journal of Wildlife Diseases* 13: 245–247.
- LAIR, S., S. DEGUISE, AND D. MARTINEAU. 1998. Uterine adenocarcinoma with abdominal carcinomatosis in a beluga whale. *Journal of Wildlife Diseases* 34: 373–376.
- NEWMAN, S. J., AND K. WEST. 2001. Pulmonary leiomyosarcoma in a white carneau pigeon (*Columba livia*). *Journal of Avian Medicine and Surgery* 15: 293–296.
- PLETCHER, J. M., AND C. MURPHY. 1984. Spontaneous malignant hemangioendothelioma in two rabbits. *Veterinary Pathology* 21: 542–544.
- ZOOK, B. C., AND R. HERTZ. 1987. Malignant neoplasms of decidual origin (deciduomas) induced by estrogen-progestin releasing intravaginal devices in rabbits. *American Journal of Pathology* 128: 315–327.

*Received for publication 19 August 2003.*