

Zinc Toxicosis in a Free-flying Trumpeter Swan (*Cygnus buccinator*)

Authors: Carpenter, James W., Andrews, Gordon A., and Beyer, W. Nelson

Source: Journal of Wildlife Diseases, 40(4) : 769-774

Published By: Wildlife Disease Association

URL: <https://doi.org/10.7589/0090-3558-40.4.769>

The BioOne Digital Library (<https://bioone.org/>) provides worldwide distribution for more than 580 journals and eBooks from BioOne's community of over 150 nonprofit societies, research institutions, and university presses in the biological, ecological, and environmental sciences. The BioOne Digital Library encompasses the flagship aggregation BioOne Complete (<https://bioone.org/subscribe>), the BioOne Complete Archive (<https://bioone.org/archive>), and the BioOne eBooks program offerings ESA eBook Collection (<https://bioone.org/esa-ebooks>) and CSIRO Publishing BioSelect Collection (<https://bioone.org/csiro-ebooks>).

Your use of this PDF, the BioOne Digital Library, and all posted and associated content indicates your acceptance of BioOne's Terms of Use, available at www.bioone.org/terms-of-use.

Usage of BioOne Digital Library content is strictly limited to personal, educational, and non-commercial use. Commercial inquiries or rights and permissions requests should be directed to the individual publisher as copyright holder.

BioOne is an innovative nonprofit that sees sustainable scholarly publishing as an inherently collaborative enterprise connecting authors, nonprofit publishers, academic institutions, research libraries, and research funders in the common goal of maximizing access to critical research.

Zinc Toxicosis in a Free-flying Trumpeter Swan (*Cygnus buccinator*)

James W. Carpenter,^{1,4} Gordon A. Andrews,² and W. Nelson Beyer³ ¹ Department of Clinical Sciences, College of Veterinary Medicine, Kansas State University, Manhattan, Kansas 66506-5601, USA; ² Department of Diagnostic Medicine/Pathobiology, College of Veterinary Medicine, Kansas State University, Manhattan, Kansas 66506-5601, USA; ³ USGS, Patuxent Wildlife Research Center, 11510 American Holly Drive, Laurel, Maryland 20708-4019, USA; ⁴ Corresponding author (email: carpentr@vet.k-state.edu)

ABSTRACT: A trumpeter swan (*Cygnus buccinator*) was observed near a mill pond in Picher, Oklahoma, USA. It became weakened and emaciated after about 1 mo, was captured with little resistance, and taken into captivity for medical care. Serum chemistry results were consistent with hepatic, renal, and muscular damage. Serum zinc concentration was elevated at 11.2 parts per million (ppm). The swan was treated for suspected heavy-metal poisoning, but died overnight. Gross postmortem findings were emaciation and pectoral muscle atrophy. Histopathologic lesions in the pancreas included mild diffuse disruption of acinar architecture, severe diffuse depletion or absence of zymogen granules, occasional apoptotic bodies in acinar epithelial cells, and mild interstitial and capsular fibrosis. Zinc concentration in pancreas was 3,200 ppm wet weight, and was similar to that reported in the pancreases of waterfowl known to be killed by zinc toxicity. Zinc concentrations in liver (154 ppm) and kidneys (145 ppm) also were elevated. Acute tubular necrosis of the collecting tubules of the kidneys was also possibly due to zinc toxicity. To the authors' knowledge, this is the first confirmed case of zinc poisoning in a trumpeter swan associated with mining wastes.

Key words: Amyloidosis, Anseriformes, *Cygnus buccinator*, mortality, trumpeter swan, zinc toxicity.

Ottawa County in northeastern Oklahoma (USA) is within the Tri-State Mining District, which extends into southwest Missouri and southeast Kansas, where mining for lead and zinc occurred from about 1850 through 1970 (Gibson, 1972). Today, the area remains contaminated with lead, zinc, and other metals, and now makes up the Tar Creek superfund site. Concentrations of up to 35,000 parts per million (ppm) of zinc and 8,700 ppm of lead have been found in surface crusts on sediments in the Tar Creek Basin (Parkhurst et al., 1988). In 1983, the US Environmental Protection Agency added the Tar Creek

Superfund Site to its National Priorities List. Recently, the gross and microscopic lesions of zinc toxicity in three Canada geese (*Branta canadensis*) and a mallard (*Anas platyrhynchos*) due to environmental exposure to zinc in this area were described by Sileo et al. (2004). In the present article, we give the clinical, clinical pathologic, gross necropsy findings, and microscopic lesions of zinc toxicity due to environmental exposure to zinc in a trumpeter swan (*Cygnus buccinator*) collected in the Tri-State Mining District.

The swan was observed swimming on a mill pond about 5 km east of Picher, Ottawa County, Oklahoma (36°59.231'N, 94°45.363'W) on February 9, 2003. By March 6, it had moved to a nearby winter wheat field, where it was observed to be inactive. Because it failed to flee or respond normally when approached, personnel of the US Fish and Wildlife Service were consulted and arrangements made to have the swan taken into captivity and rehabilitated. When approached closely, the swan flapped its wings but could not walk. It was captured by hand with little resistance. Based on banding records, the swan was a 3-yr-old, hand-reared female that had been hatched in captivity at Delta, Iowa, USA, in the spring of 2000 as part of a restoration program headed by the Iowa Department of Natural Resources. It had been released in good health from Cerro Gordo County, Iowa, USA, on 31 May 2002. Following capture on 6 March 2003 in Oklahoma, the swan was provided food and water and held overnight. The following morning it was placed in a well-ventilated, commercial, large dog carrier and transported to the Veterinary Medical Teaching Hospital, College of Veterinary

Medicine, Kansas State University, Manhattan, Kansas, USA, for evaluation and treatment.

On physical examination, the bird was alert but lethargic, weak, and could walk only a few steps before collapsing. The head was moderately drooping, there was ankylosis of the cranial cervical vertebrae, and the wings were held in a normal position over the back. No neurologic deficits were detected on preliminary evaluation. The bird weighed 7.3 kg and was very thin. The bird's head and neck feathers were stained orange, presumably from iron oxides found in local streams contaminated with mine waters. Blood was obtained via medial metatarsal venipuncture for a complete blood count, determination of serum biochemical values, and analyses for concentrations of lead, zinc, copper, and cadmium. Analysis of heavy metals in blood was performed by atomic absorption spectroscopy (Veterinary Diagnostic Laboratory, Department of Diagnostic Medicine/Pathobiology, College of Veterinary Medicine, Manhattan, Kansas, USA). Mineral to metal opacity was present in the ventriculus, although individual particles were not well visualized on full-body radiographs. There was also a chronic healed malunion in the cranial cervical spine (C5-C6). No other radiographic abnormalities were detected.

Complete blood count results included a packed cell volume of 42% (reference range, 35–53%), total protein of 3.6 g/dl (reference range, 3.3–4.9 g/dl), and a leukocyte count of $45.7 \times 10^3/\mu\text{l}$ (reference range, $8.6\text{--}22.4 \times 10^3/\mu\text{l}$) (International Species Inventory System, 2002). The leukocyte differential consisted of 70% segmented heterophils (reference mean, 71%), 25% immature heterophils, 1% lymphocytes (reference mean, 22%), 5% monocytes (reference mean, 5%), and no eosinophils (reference mean, 3%), or basophils (reference mean, 2%).

Serum chemical values that were outside the normal range included glucose, 52 mg/dl (14 mmol/l) (reference range, 173–237

mg/dl; 11 ± 2 mmol/l); urea nitrogen, 24 mg/dl (9 mmol/l) (reference range, 1–3 mg/dl; 0.6–1.4 mmol/l); albumin, <1.0 g/dl (reference range, 1.3–1.9 g/dl); alanine aminotransferase (AST), 593 IU/l (reference range, 10–40 IU/l); creatine kinase, 4,555 IU/l (reference range, 0–872 IU/l); and uric acid, 23.6 mg/dl (1404 $\mu\text{mol/l}$) (reference range, 3.0–8.6 mg/dl; 178–512 $\mu\text{mol/l}$).

Results of antemortem analysis of blood for heavy metals were zinc, 11.2 ppm; lead, 1.0 ppm; copper, 0.17 ppm; and cadmium, <0.05 ppm (below detection limits). Because of these findings, heavy-metal toxicity was suspected and the bird was administered fluids (lactated Ringers solution and dextrose with vitamin B complex), calcium disodium versenate (CaEDTA; 35 mg/kg intramuscularly), and fed herbivore slurry via gavage. In spite of this, it died 5 hr posttreatment.

On postmortem examination, the bird was moderately emaciated with mild pectoral muscle atrophy. There was minimal subcutaneous and no intracoelomic adipose tissue. The spleen was mildly enlarged. The gizzard was moderately distended with gravel, but no metal fragments were detected. The gizzard lining was not eroded. No other gross lesions were observed in any other tissues or organ systems. Samples of fresh pancreas, liver, kidney, heart blood, and gizzard contents were placed in chemically clean jars and frozen for heavy-metal analyses by ion coupled plasma-atomic emission spectroscopy (Animal Health Diagnostic Laboratory, College of Veterinary Medicine, Michigan State University, East Lansing, Michigan, USA). Samples of liver, spleen, and intestinal tract were submitted for bacterial culture. No attempt was made to culture anaerobic bacteria. Tissues for histopathologic examination were placed in 10% buffered formalin, routinely processed, embedded in paraffin, sectioned at 4 μm , and stained with hematoxylin and eosin (HE). Selected tissue slides also were stained with Masson's trichrome stain

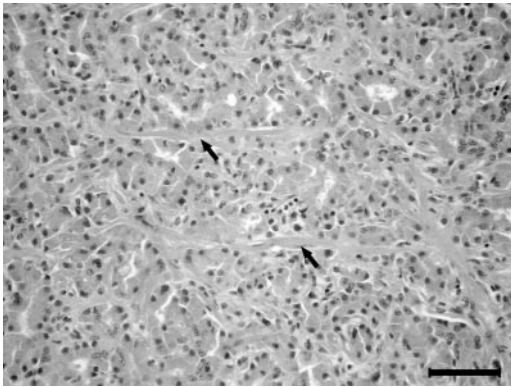


FIGURE 1. Photomicrograph of the pancreas from a trumpeter swan with chronic zinc toxicosis, amyloidosis, and enterotoxemia. Note diffuse acinar cell zymogen granule depletion, disruption of normal acinar architecture, and interstitial fibrosis (arrows) in the parenchyma, lesions characteristic of zinc toxicosis. Hematoxylin and eosin. Bar=50 μ m.

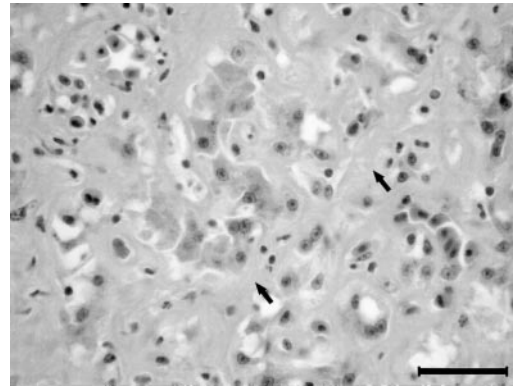


FIGURE 3. Photomicrograph of the liver from a trumpeter swan with chronic zinc toxicosis, amyloidosis, and enterotoxemia. The space of Disse is filled and expanded by amyloid (arrows), resulting in compression of sinusoids and atrophy and loss of hepatocytes. Hematoxylin and eosin. Bar=30 μ m.

for collagen, Congo red stain for amyloid, and Gram stain to characterize bacteria.

Histologic lesions in the pancreas included mild, diffuse disruption of normal acinar architecture with mild to moderate interstitial fibrosis characterized by small to moderate amounts of collagen and fibroblasts arranged in a trabecular pattern (Fig. 1). The exocrine pancreatic acinar cells exhibited diffuse and severe depletion or absence of zymogen granules, and

occasional acinar epithelial cells contained apoptotic bodies (Fig. 2). There was moderate, diffuse fibrosis of the capsule of the pancreas.

Moderate to severe chronic diffuse amyloidosis, accompanied by hepatocellular atrophy and loss, was present in the liver (Fig. 3). The liver also contained random, multifocal areas of acute hepatocellular necrosis with heterophilic inflammation (Fig. 4). Multifocal mucosal necrosis and ulceration with large numbers of intra-

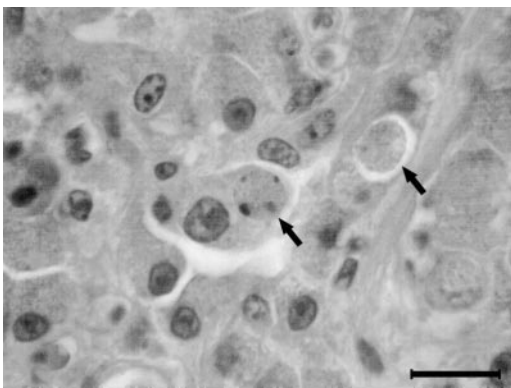


FIGURE 2. Photomicrograph of the pancreas from a trumpeter swan with chronic zinc toxicosis, amyloidosis, and enterotoxemia. Apoptotic bodies (arrows), characteristic of zinc toxicosis, are present in acinar epithelial cells. Hematoxylin and eosin. Bar=10 μ m.

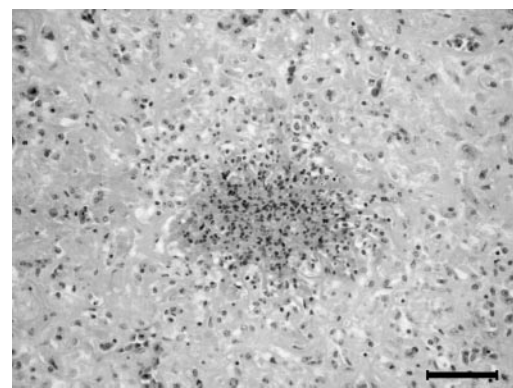


FIGURE 4. Photomicrograph of the liver from a trumpeter swan with chronic zinc toxicosis, amyloidosis, and enterotoxemia. The parenchyma contains random foci of acute necrosis infiltrated by degenerate heterophils. Hematoxylin and eosin. Bar=50 μ m.




FIGURE 5. Photomicrograph of the cecum from a trumpeter swan with chronic zinc toxicosis, amyloidosis, and enterotoxemia. The mucosa contains a focal area of acute necrosis resulting in ulceration covered by fibrin, necrotic cell debris, and large numbers of bacilli and sporulated bacilli (inset). Hematoxylin and eosin. Bar=200 µm.

sional Gram-positive sporulating bacilli were present in the small intestines, colon, and cecae (Fig. 5). Multifocal necrosis and heterophilic inflammation were present in the tunica muscularis and mild, diffuse serositis was present in the cecae. Other findings included acute tubular nephrosis of collecting tubules, multifocal to coalescing amyloidosis with lymphoid depletion in spleen, pulmonary congestion, and mild multifocal myodegeneration and necrosis in pectoral muscle. No histologic lesions were observed in any other tissues.

Nonhemolytic *Escherichia coli* was isolated from the spleen. *Enterobacter agglomerans* and nonhemolytic *E. coli* were cultured from the intestines. No bacteria were isolated from the liver.

Results of postmortem analyses for heavy metals for zinc, lead, copper, and cadmium are summarized in Table 1. Concentrations of iron, cadmium, chromium, and mercury were within normal limits or not significantly elevated. The final post-mortem diagnoses were chronic zinc toxicity; hepatic and splenic amyloidosis; necrotizing and ulcerative enteritis, colitis, and typhilitis; and clostridial enterotoxemia.

The zinc concentration in the swan's pancreas was 3,200 mg/kg. Levengood et al. (1999) reported that, when farm-raised mallards (*Anas platyrhynchos*) were lethally poisoned with zinc shot, the mean concentration of zinc in the pancreas increased from about 88 mg/kg to about 2,200 mg/kg wet weight. Likewise, Gasaway and Buss (1972) found that concentrations of zinc in the pancreases of mallards fed lethal concentrations of zinc increased from 89 mg/kg to between 1,300 mg/kg and 2,700 mg/kg of zinc wet weight. The swan's liver and kidneys contained 154 ppm and 145 ppm of zinc, respectively, and were both elevated above normal ranges of 30–100 ppm zinc in the liver and 20–40 ppm zinc in the kidneys reported from a population of more than 75 trumpeter swans (Puls, 1994). Copper concentration was 1.05 mg/kg in the swan's liver and 4.61 mg/kg in the kidneys, compared with a normal range for trumpeter swans of 6–100 mg/kg in livers and 3.0–7.0 mg/kg in kidneys (Puls, 1994). Levengood et al. (1999) reported that zinc decreased hepatic copper concentrations and increased

TABLE 1. Concentrations of metals (expressed as parts per million wet weight) in tissues and serum of a female trumpeter swan captured from a mill pond in Ottawa County, Oklahoma, in the Tri-State Mining District.

Metal	Tissue				
	Pancreas	Liver	Kidney	Ventriculus contents	Blood serum
Zinc	3,200	154	145	54	11.2
Lead	0.50	0.78	3.23	7.61	1.0
Copper	5.10	1.05	4.61	2.30	0.17
Cadmium	<0.1	<0.1	0.23	0.29	<0.05

renal copper concentrations in zinc-poisoned mallards.

The leukocytosis was likely in response to an inflammatory process, most notably concurrent bacterial infection. High numbers of immature heterophils were indicative of the animal's attempt to respond to the infection. Although a number of the serum biochemical values were abnormal, the most notable included hypoglycemia (52 mg/dl), which may have been a response to septicemia or hepatic dysfunction; elevated AST (593 U/l), likely resulting from liver and muscle disease; elevated creatine kinase (4,555 U/l), which resulted from muscle damage; and elevated uric acid (23.6 mg/dl), which is associated with renal disease, dehydration, tissue damage, and starvation.

The limited gross lesions in the swan were consistent with those associated with experimental zinc toxicity in birds (Levengood et al., 1999, 2000). Histopathologic lesions in the pancreas were identical to those reported in experimental and naturally occurring zinc toxicosis in other bird species (Kazacos and Van Vleet, 1989; Droual et al., 1991; Levengood et al., 1999; Sileo et al., 2004). In an experimental time-course study of lesion development in the pancreas of ducklings, cytoplasmic exocytic and autophagic vacuoles were present at day 3, with increasing severity of vacuolar change and apoptotic body formation at days 5 to 7. At 10 days, the predominant changes were acinar cell atrophy and interstitial fibrosis with apoptotic bodies in acinar epithelial cells in various stages of degeneration. These changes and occasional apoptotic bodies were observed to days 12 to 17 (Kazacos and Van Vleet, 1989). The pancreatic changes in the swan, therefore, were considered to be at least 10–17 days old based on the experimental model in the ducklings. Necrohemorrhagic enteritis, colitis, and typhilitis are frequent findings in experimental zinc toxicosis in ducklings (Levengood et al., 1999, 2000). The swan had similar necrotizing lesions of the small

intestine, colon, and cecae, but with numerous Gram-positive bacilli with sporulating forms typical of *Clostridium* sp. on the necrotic mucosal surface. Whether the necrotizing lesions of the intestinal tract were a result of clostridial infection or the clostridia colonized an intestinal mucosa damaged by zinc toxicity is conjectural. The random foci of acute hepatocellular necrosis with heterophilic inflammation are evidence of enterotoxemia. The combination of intestinal and hepatic lesions in the swan was strikingly similar to those caused by *Clostridium colinum* in quail (*Colinus virginianus*) (Berkhoff and Campbell, 1973).

Liver lesions reported in experimental zinc toxicity include granulomas, hemosiderosis, and hepatocellular atrophy to apoptosis (Levengood et al., 1999). Hepatocellular atrophy was present in the swan liver but was a result of severe diffuse amyloid deposition. Minimal hemosiderosis was present in the liver. Splenic lesions reported are hemosiderosis with lymphoid depletion and/or lympholysis (Levengood et al., 1999). Severe lymphoid depletion was present in the spleen of the swan but was a result of replacement of lymphoid follicles by amyloid. Renal tubular necrosis of the collecting tubules also is associated with zinc toxicity (Levengood et al., 1999).

In humans, mortality following severe zinc intoxication, even with treatment, is high (Bennett et al., 1997). Removal of the source of zinc and supportive therapy are important for successful treatment. Although 80–90% of ingested foreign bodies pass spontaneously, surgical intervention is warranted in cases of perforation, severe hemorrhage, or complete bowel obstruction, or for removal of a toxic substance from the bowel (Bennett et al., 1997). Chelation therapy for zinc toxicosis is controversial. Bennett et al. (1997) reports preoperative chelation of zinc with Ca-EDTA may be needed to reduce the mortality, whereas Talcott (2001) states that chelation is contraindicated because chelating agents may increase gastrointestinal

absorption of zinc and are potentially nephrotoxic.

Although enterotoxemia, chronic debility, and stress were possibly the ultimate cause of death in this swan, the underlying cause was zinc toxicosis.

We thank J. D'Agostino, J. Pickerell, and F. Oehme, College of Veterinary Medicine, Kansas State University, for clinical and toxicologic assistance with this case; and L. Sileo, National Wildlife Health Center, USGS, Madison, Wisconsin, USA, for providing additional toxicologic analyses. We also acknowledge J. Dalgarn of the Bureau of Indian Affairs (Miami, Oklahoma, USA), J. Sparkman, Executive Director of the Picher Housing Authority, and J. Miesner and M. McNulty of the US Fish and Wildlife Service (Manhattan, Kansas, USA) for monitoring the swan in the wild and transporting it to the College of Veterinary Medicine, Kansas State University.

LITERATURE CITED

- BENNETT, D. R., C. J. BAIRD, K. M. CHAN, P. F. CROOKES, C. G. BREMMER, M. M. GOTTIEB, AND W. Y. NARITOKU. 1997. Zinc toxicity following massive coin ingestion. *The American Journal of Forensic Medicine and Pathology* 18: 148–153.
- BERKHOFF, G. A., AND S. G. CAMPBELL. 1974. Etiology and pathogenesis of ulcerative enteritis ("quail disease"). *The experimental disease. Avian Disease* 18: 205–212.
- DROUAL, R., C. U. METEYER, AND F. D. GALEY. 1991. Zinc toxicosis due to ingestion of a penny in a gray-headed chachalaca (*Ortalis cinereiceps*). *Avian Diseases* 35: 1007–1011.
- GASAWAY, W. C., AND I. O. BUSS. 1972. Zinc toxicity in the mallard duck. *Journal of Wildlife Management* 36: 1107–1117.
- GIBSON, A. M. 1972. *Wilderness bonanza: The Tri-State District of Missouri, Kansas, and Oklahoma*. University of Oklahoma Press, Norman, Oklahoma, 362 pp.
- INTERNATIONAL SPECIES INFORMATION SYSTEM. 2002. Physiological data reference values. International Species Inventory System, Apple Valley, Wisconsin.
- KAZACOS, E. A., AND J. F. VAN VLEET. 1989. Sequential changes of the pancreas in zinc toxicosis in ducklings. *American Journal of Pathology* 134: 581–595.
- LEAVENGOOD, J. M., G. C. SANDERSON, W. L. ANDERSON, G. L. FOLEY, P. W. BROWN, AND J. W. SEETS. 2000. Influence of diet on the hematology and serum biochemistry of zinc-intoxicated mallards. *Journal of Wildlife Diseases* 36: 111–123.
- _____, _____, _____, L. M. SWOKRON, P. W. BROWN, AND J. W. SEETS. 1999. Acute toxicity of ingested zinc shot to game-farm mallards. *Illinois Natural History Survey Bulletin* 36: 1–36.
- PARKHURST, D. L., M. DOUGHTEN, AND P. P. HEARN. 1988. Chemical analyses of stream sediment in the Tar Creek Basin of the Picher mining areas, northeast Oklahoma: US Geological Survey Open-File Report 88-469.
- PULS, R. 1994. Mineral levels in animal health: Diagnostic data, 2nd ed. Sherpa International, Clearbrook, British Columbia, Canada, p. 349.
- SILEO, L., W. N. BEYER, AND R. MATEO. 2004. Pancreatitis in wild zinc-poisoned waterfowl. *Avian Pathology* 32: 655–660.
- TALCOTT, P. A. 2001. Zinc poisoning. In *Small animal toxicology*, M. E. Peterson and P. A. Talcott (eds.). W. B. Saunders, Philadelphia, Pennsylvania, pp. 756–761.

Received for publication 20 August 2003.