

Sarcocystis neurona-associated Meningoencephalitis and Description of Intramuscular Sarcocysts in a Fisher (*Martes pennanti*)

Authors: Gerhold, Richard W., Howerth, Elizabeth W., and Lindsay, David S.

Source: Journal of Wildlife Diseases, 41(1) : 224-230

Published By: Wildlife Disease Association

URL: <https://doi.org/10.7589/0090-3558-41.1.224>

BioOne Complete (complete.BioOne.org) is a full-text database of 200 subscribed and open-access titles in the biological, ecological, and environmental sciences published by nonprofit societies, associations, museums, institutions, and presses.

Your use of this PDF, the BioOne Complete website, and all posted and associated content indicates your acceptance of BioOne's Terms of Use, available at www.bioone.org/terms-of-use.

Usage of BioOne Complete content is strictly limited to personal, educational, and non - commercial use. Commercial inquiries or rights and permissions requests should be directed to the individual publisher as copyright holder.

BioOne sees sustainable scholarly publishing as an inherently collaborative enterprise connecting authors, nonprofit publishers, academic institutions, research libraries, and research funders in the common goal of maximizing access to critical research.

***Sarcocystis neurona*-associated Meningoencephalitis and Description of Intramuscular Sarcocysts in a Fisher (*Martes pennanti*)**

Richard W. Gerhold,^{1,4} Elizabeth W. Howerth,² and David S. Lindsay³ ¹ Southeastern Cooperative Wildlife Disease Study, College of Veterinary Medicine, The University of Georgia, Athens, Georgia 30602, USA; ² Department of Pathology, College of Veterinary Medicine, The University of Georgia, Athens, Georgia 30602, USA; ³ Center for Molecular Medicine and Infectious Diseases, Department of Biomedical Sciences and Pathobiology, Virginia-Maryland College of Veterinary Medicine, Virginia Tech, 1410 Prices Fork Road, Blacksburg, Virginia 24061, USA; and ⁴ Corresponding author (email: rgerhold@vet.uga.edu).

ABSTRACT: A free-ranging juvenile fisher (*Martes pennanti*) with ataxia, lethargy, stupor, and intermittent, whole-body tremors was examined postmortem. Microscopically, the fisher had protozoal meningoencephalitis caused by *Sarcocystis neurona*, which was confirmed by immunohistochemistry, polymerase chain reaction (PCR) and restriction fragment length polymorphism testing, and genetic sequencing. Sarcocysts found in the skeletal muscle of the fisher were negative for *S. neurona* by PCR, but were morphologically similar to previous light and electron microscopy descriptions of *S. neurona*. This is the first report of clinical neural *S. neurona* infection in a fisher.

Key words: Fisher, *Martes pennanti*, meningoencephalitis, mustelid, *Sarcocystis neurona*.

Clinical encephalitis caused by *Sarcocystis neurona* or *S. neurona*-like parasites has been reported in free-ranging mammals including the raccoon (*Procyon lotor*), mink (*Mustela vison*), striped skunk (*Mephitis mephitis*), sea otter (*Enhydra lutris*), and Pacific harbor seal (*Phoca vitulina*) (Dubey and Hamir, 2000; Lindsay et al., 2000, 2001; Dubey et al., 2001b, 2002; Miller et al., 2001a and b). In some cases, concurrent viral or bacterial diseases were associated with the protozoal infections, whereas in other cases the protozoal parasites were cited as the primary cause of morbidity. Dual *S. neurona* and *Toxoplasma gondii* infections have been documented in clinically affected mammals including a Pacific harbor seal and a northern sea otter (Lindsay et al., 2001; Miller et al., 2001b). We report a case of acute meningoencephalitis caused by *S. neurona* and describe intramuscular sarcocysts of a

possibly unrecognized *Sarcocystis* sp. in a free-ranging fisher (*Martes pennanti*).

On 13 July 2002, a male fisher was observed near a farmhouse in Garrett County (39°21'N, 79°23'W), Maryland, USA. The fisher had no fear of humans and was attacked by a dog. The fisher was live-trapped by the landowner and submitted to the Maryland Department of Natural Resources. On submission, the fisher was alert with ataxia of the pelvic limbs. The fisher eventually became lethargic, had whole-body tremors, and developed hind-quarter paralysis. The fisher was euthanized by gunshot to the neck, refrigerated, and submitted to the Southeastern Cooperative Wildlife Disease Study (SCWDS), College of Veterinary Medicine, the University of Georgia, Athens, Georgia, USA, for diagnostic examination.

At postmortem examination, portions of the brain, skin, trachea, lung, heart, kidney, testis, liver, spleen, esophagus, stomach, pancreas, small intestine, large intestine, skeletal muscle, and urinary bladder were collected and frozen at –20 C. Portions of the brain, skin, trachea, lung, skeletal muscle, heart, kidney, adrenal gland, testis, liver, spleen, esophagus, stomach, pancreas, small intestine, large intestine, thyroid gland, and urinary bladder were fixed in 10% buffered formalin, embedded in paraffin, sectioned at 3 µm, and stained with hematoxylin and eosin for light microscopy.

A portion of frozen brain was submitted to the Maryland Department of Health, Baltimore, Maryland, USA, for fluorescent

antibody (FA) testing for rabies virus. Additionally, fresh and paraffin embedded brain samples were submitted to the Athens Diagnostic Laboratory (University of Georgia, Athens, Georgia, USA) for FA and immunohistochemistry (IHC) testing for canine distemper virus (CDV), *T. gondii*, and *Neospora caninum*.

Unstained sections of brain tissue, as well as frozen brain and muscle samples, were submitted to the Center for Molecular Medicine and Infectious Diseases, Department of Biomedical Sciences and Pathobiology, Virginia-Maryland College of Veterinary Medicine, Virginia Tech, Blacksburg, Virginia, USA, for *S. neurona*, *T. gondii*, and *N. caninum* IHC testing, and *S. neurona*, *T. gondii*, and *N. caninum* DNA amplification by polymerase chain reaction (PCR). Rabbit anti-*T. gondii* sera was a gift from J. P. Dubey. Rabbit anti-*S. neurona* (a mixture of SN6 and SNSO-1 strains) and rabbit anti-*N. caninum* (Nc-1 strain) antisera were made at Virginia Tech. Immunohistochemistry using the avidin-biotin technique (Peroxidase Rabbit IgG Vectastain® ABC Kit; Vector Laboratories, Inc., Burlingame, California, USA) was performed with a 1:500 dilution of each parasite antisera and was done as described by Lindsay and Dubey (1989) with the exception that slides were incubated in Antigen Retrieval Citra (Biogenex, San Ramon, California, USA) for 20 min before blocking with goat serum. Bound antibodies were visualized using diaminobenzidine reagent (Sigma Company, St. Louis, Missouri, USA). DNA amplification was performed using species specific primer pairs JNB 33/JNB 54 for *S. neurona*, B1 sense/B1 antisense for *T. gondii*, and Np6/Np21 for *N. caninum* as previously described (Hyman et al., 1995; Yamage et al., 1996; Tanhauser et al., 1999), and the highly conserved, mammalian, 16S RNA gene (Hyman et al., 1995) was used as a control for DNA isolation. The DNA was extracted from 0.5 g of brain tissue using a commercial DNA extraction kit (DNA Maxi Kit, Qiagen, Valencia, Califor-

nia, USA). The purified DNA was diluted 1:100 and a 20- μ l aliquot was mixed with 200 μ l of InstaGene Matrix (Bio Rad, Hercules, California, USA). The samples were then incubated in a 56 C water bath for 30 min, and the PCR reaction was performed as previously described (Lindsay et al., 2000). The PCR products were run on a 0.5% agarose gel, and water was used as a negative control. For identification of *S. neurona*, the 1100-bp PCR product was digested separately with the restriction enzymes *Hinf* I or *Dra* I (Promega, Madison, Wisconsin, USA) and analyzed by electrophoresis on a 1% agarose gel with appropriate size markers. Merozoite (*S. neurona* SN6 or SN138 strain) or tachyzoite DNA (RH strain *T. gondii*; NC-1 strain *N. caninum*) was used as a positive control. Genetic sequencing was performed on the PCR products amplified from brain using *S. neurona* primers JNB 33/JNB 54. Analysis of the DNA was performed using Seqman program (DNASTar Applications, London, United Kingdom).

Brain and skeletal muscle specimens containing merozoites and schizonts and sarcocysts, respectively, were removed from paraffin blocks for electromicroscopy. Paraffin was extracted with 100% xylene, and tissues placed in 100% ethanol, post-fixed in 1% osmium tetroxide, stained with 0.5% uranyl acetate, rinsed with deionized water, and infiltrated with an Epon-Araldite mixture. Semithin 1- μ m sections were stained with toluidine blue and used to determine tissue orientation by light microscopy. Ultrathin sections were stained with 5% methanolic uranyl acetate and Reynold's lead citrate and examined using a JEM-1210 transmission electron microscope (JEOL USA, Peabody, Massachusetts, USA).

The fisher was estimated to be between 5 mo and 7 mo of age based on deciduous tooth replacement as well as baculum weight (Douglas and Strickland, 1987). Body weight was 2.2 kg, and the carcass was in fair physical condition. The mucous membranes, subcutis, skeletal muscle, and

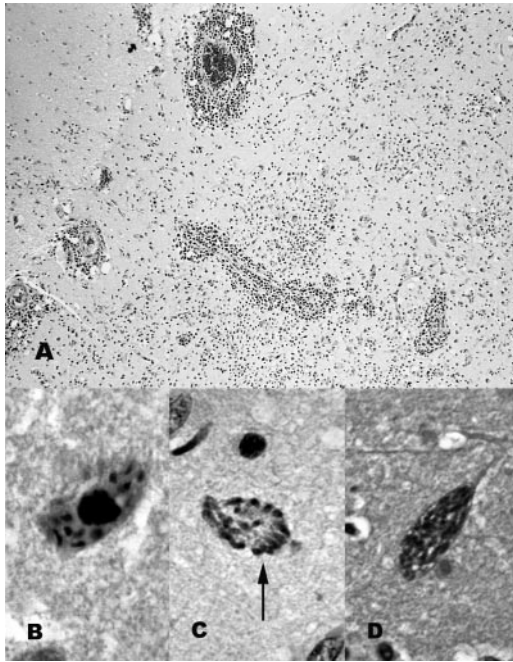


FIGURE 1. Brain from fisher with *Sarcocystis neurona* encephalitis. A: Cerebral gray matter with marked perivascular cuffing and parenchymal inflammation. 100X. Hematoxylin and eosin. B: Multiple merozoites in cytoplasm of neuron. 1,000X. Hematoxylin and eosin. C: Schizont. 1,000X. Hematoxylin and eosin. D: Schizont immunopositive for *Sarcocystis* by immunohistochemistry. 1,000X, DAB.

liver were markedly pale. On the dorsal thorax, there were three areas of subcutaneous hemorrhage and one area of skeletal muscle hemorrhage, each approximately 1 cm in diameter. The right dorsal aspect of the right anterior lung lobe contained a focal area of hemorrhage approximately 3×2 cm. A focal area of marked myocardial pallor, approximately 1 cm in diameter, was at the base of the heart. A diffuse, dark, meningeal exudate was present over a 3-cm diameter area of the dorsocranial aspect of the cerebral hemispheres.

Microscopically, the brain had multifocally extensive areas of necrosis and inflammation in the cerebrum, cerebellum, brainstem, and leptomeninges (Fig. 1A). The lesions were most severe in the thickened, inflamed leptomeninges and the gray matter of the cerebrum, especially the

hippocampus. The affected meninges and the subjacent tissue were infiltrated by a marked number of lymphocytes and plasma cells admixed with fewer macrophages and neutrophils. The cerebral and cerebellar gray matter contained multifocal areas of inflammation and necrosis that varied from glial nodules to areas of necrosis infiltrated with macrophages and fewer lymphocytes, plasma cells, and neutrophils; moderate to marked perivascular lymphoplasmacytic cuffing was present. White matter throughout the brain was less affected and contained scattered areas of mild to moderate, mononuclear inflammatory cells and perivascular lymphoplasmacytic cuffing. The cytoplasm of several neurons contained oval schizonts arranged in a rosette or irregular pattern (Fig. 1C). Multiple oval to elongated, basophilic, protozoal zoites approximately 3–5 μ m in diameter were free in the neutrophil and within neurons (Fig. 1B). Many were associated with inflammation and necrosis. Organisms in the brain were immunopositive for *S. neurona* (Fig. 1D) and immunonegative for *T. gondii* and *N. caninum*. Immunohistochemistry for CDV and FA testing for rabies virus, CDV, *T. gondii*, and *N. caninum* on brain were negative. Ultrastructurally, in brain, neurons contained schizonts with numerous merozoites developing internally (Fig. 2A, B). Schizonts were located in the host-cell cytoplasm; developing merozoites contained micronemes but not rhoptries. Mature intracellular and extracellular merozoites containing micronemes, but without rhoptries, were also observed.

In sections of skeletal muscle, there were multiple, mature sarcocysts that were not associated with inflammation. By light microscopy, the sarcocysts were up to 200 μ m in length and 30 μ m wide. The sarcocyst wall was 1–3 μ m thick and had minute villar protrusions (Fig. 3A). One sarcocyst in skeletal muscle was examined ultrastructurally (Fig. 3B, C). The wall of the sarcocyst parasitophorous vacuolar membrane consisted of numerous, sloping villar

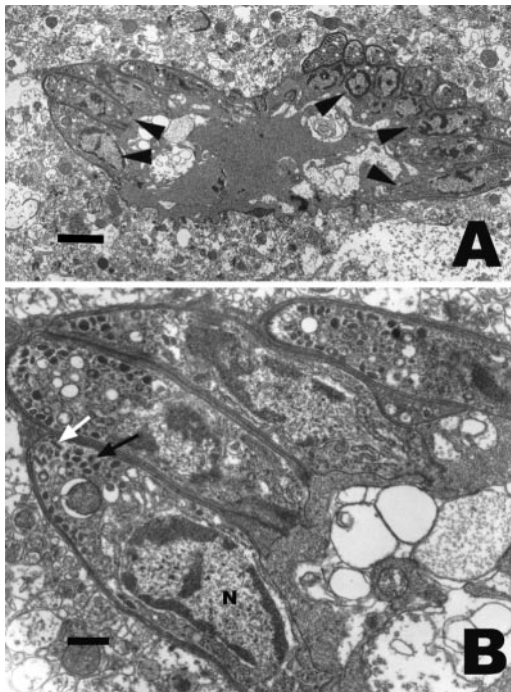


FIGURE 2. Transmission electron micrographs of a schizont in neuron from brain. A: The schizont is surrounded by a plasmalemma and inner schizont membrane and is in the host cell cytoplasm. Note internally budding merozoites near the schizont's surface (arrowheads). Bar=2 μ m. B: Higher magnification of budding merozoites near schizont surface. Note developing conoid (white arrow), numerous micronemes (black arrow) in conoidal end, and posterior nucleus (N). Bar=0.5 μ m.

protrusions, up to 2.2 μ m in length and 0.4 μ m wide, and was lined by an electron-dense layer that was interrupted, giving the villar protrusions a hob-nail appearance. The villar protrusions had roughly parallel walls with pointed tips and were slanted. They contained up to seven microtubules, as observed on cross section, which extended from the tip to the granular layer. The granular layer was about 0.5 μ m thick and relatively electron dense. The sarcocysts contained numerous light-staining metrocytes and dark-staining bradyzoites. Metrocytes were primarily situated at the periphery of the sarcocyst with bradyzoites located centrally. Longitudinally cut bradyzoites were 1.1–1.9 μ m by 3.9–5.5 μ m ($n=4$) and contained organ-

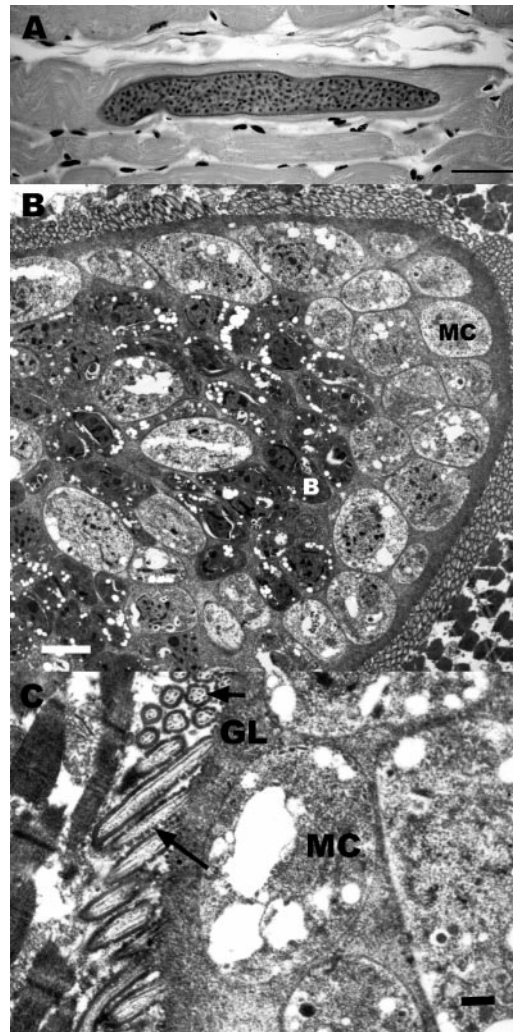


FIGURE 3. A: Sarcocyst in skeletal muscle of fisher. Hematoxylin and eosin. Bar=40 μ m. B: Transmission electron micrograph of sarcocyst from skeletal muscle. Electron-lucent metrocytes (MC) form a peripheral layer. Electron-dense bradyzoites (B) are found more centrally and contain organelles typical of *Sarcocystis* sp. Bar=2 μ m. C: Transmission electron micrograph of sarcocyst from skeletal muscle. Slanting villar protrusions are lined by an electron-dense layer that is interrupted giving the protrusions a hob-nail appearance (long arrow). On cross section, up to seven microtubules (short arrow) are present in the protrusions. The granular layer (GL) is relatively electron dense. Electron-lucent metrocytes (MC) are found at the periphery. Bar=0.5 μ m.

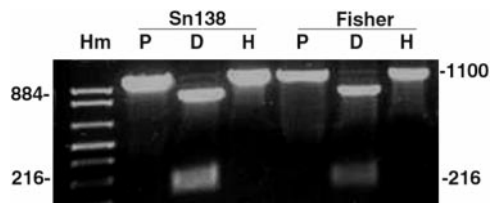


FIGURE 4. Results of PCR using primer pairs JNB33/JNB54 and restriction enzyme digestion with *Dra*I and *Hinf*I of merozoite DNA from *Sarcocystis neurona* strain 138 merozoites (Sn138) or DNA from brain of the Fisher (Fisher). Hm = high molecular mass marker; P = PCR product; D = results of *Dra*I digestion; H = results of *Hinf*I digestion.

elles typical of *Sarcocystis* spp. bradyzoites (Dubey et al., 1989), including numerous micronemes primarily in the conoidal end, a posterior nucleus, a few dense granules, and amylopectin granules throughout. Merozoites were round to ovoid, of varying size, but larger than the bradyzoites and contained a few amylopectin granules.

An approximately 1,100 base pair (bp) PCR product was amplified using the *S. neurona* primers from DNA extracted from brain but not the muscle (Fig. 4). This PCR product from the fisher isolate was cut into 884-bp and 216-bp segments by *Dra*I but was not digested with *Hinf*I, which is typical of *S. neurona* (Lindsay et al., 2000). The sequence of the PCR product was 99% identical to the SN6 strain of *S. neurona*, and the sequence has been deposited in the Genbank® database (National Center for Biotechnology Information, Bethesda, Maryland, USA, www.ncbi.nlm.nih.gov/Genbank, accession number AY466104). *Toxoplasma gondii* also was detected by PCR from brain and skeletal muscle specimens.

Although two species of protozoal parasites, *S. neurona* and *T. gondii*, were detected from brain tissue by PCR, the neurologic deficits and meningoencephalitis observed in the fisher appear to be due to infection with *S. neurona*. The microscopic features of schizonts and merozoites in neurons are consistent with *S. neurona* infection, and these organisms were immunohistochemically positive for *Sarcocystis*

spp. but not for *T. gondii*. Ultrastructurally, the organism in the brain was consistent with a *Sarcocystis* sp. Schizonts were located in the cytoplasm without a parasitophorous vacuole, and similar to other *Sarcocystis* sp. and distinct from other coccidians, the merozoites lacked rhoptries (Dubey et al., 1989). Lack of microscopic, FA, and IHC evidence of *T. gondii* in the brain indicates that it was not a factor in the encephalitis and was, probably, a latent infection.

DNA extracted from the skeletal muscle containing sarcocysts was negative for *S. neurona* by PCR; however, the ultrastructural feature of the sarcocysts in this fisher were very similar to those reported for *S. neurona* in other species, particularly the length of the villi and the interrupted, electron-dense layer lining the parasitophorous vacuolar membrane (Dubey et al., 2001a; Dubey et al., 2001b; Stanek et al., 2002). Thus, failure to amplify *S. neurona* DNA from these sarcocysts may have been related to technical difficulties, or this organism may be an unrecognized *Sarcocystis* sp. that is morphologically similar to *S. neurona*.

The source of the *Sarcocystis* infection in this fisher is unknown. The main diet of fishers throughout their range in North America consists mainly of porcupines (*Erethizon dorsatum*), snowshoe hare (*Lepus americanus*), deer species (*Odocoileus* spp.), passerine birds, and vegetation, but fishers are also opportunistic feeders (Marten, 1994). In North America, the Virginia opossum (*Didelphis virginiana*) serves as the definitive host for *S. neurona* (Fenger et al., 1997; Dubey and Lindsay, 1998), and free-ranging mammals, including the Southern sea otter, striped skunk, raccoon, and the nine-banded armadillo (*Dasypus novemcinctus*), are aberrant, intermediate hosts of *S. neurona* (Dubey and Hamir, 2000; Cheadle et al., 2001; Dubey et al., 2001b). The natural, intermediate host is still unknown, and the potential for other intermediate hosts should be investigated.

A number of *Sarcocystis*-like and *T.*

gondii protozoal infections in carnivores have been associated with current or pre-existing immunosuppressive diseases, especially CDV (Reed and Turek, 1985; Stoffregen and Dubey, 1991). It has been documented previously that other mustelid species, especially black-footed ferrets (*Mustela nigripes*), are susceptible to morbilliviruses, such as CDV (Williams et al., 1988). We found no evidence of a preexisting viral disease that may have predisposed this fisher to infection with *S. neurona*.

This investigation was supported by Cooperative Agreement 2001-96130032-CA, Veterinary Services, APHIS, USDA and sponsorship of SCWDS by the fish and wildlife agencies of Alabama, Arkansas, Florida, Georgia, Kentucky, Kansas, Louisiana, Maryland, Mississippi, Missouri, North Carolina, Puerto Rico, South Carolina, Tennessee, Virginia, and West Virginia. Support from the states to SCWDS was provided by the Federal Aid to Wildlife Restoration Act (50 Stat. 917). We thank Clarissa Harris of the Maryland Department of Natural Resources for the submission of the specimen; K. Carlson, Virginia Tech, for conducting PCR and RFLP assays; M. Ard, University of Georgia, for assistance with the electronic magnification; and M. Yabsley, D. Mead, and C. Tate, University of Georgia, for assistance with manuscript preparation.

LITERATURE CITED

- CHEADLE, M. A., S. M. TANHAUSER, J. B. DAME, D. C. SELLON, M. HINES, P. E. GINN, R. J. MACK-
EY, AND E. C. GREINER. 2001. The nine-banded
armadillo (*Dasypus novemcinctus*) is an inter-
mediate host for *Sarcocystis neurona*. *International Journal of Parasitology* 31: 330–335.
- DOUGLAS, C. W., AND M. A. STRICKLAND. 1987.
Fisher. In *Wild furbearer management and con-
servation in North America*, M. J. Novack, E.
Baker, M. E. Obbard, and B. Malloch (eds.). On-
tario Trappers Association, North Bay, Ontario,
Canada, pp. 511–529.
- DUBEY, J. P., AND A. N. HAMIR. 2000. Immunohis-
tochemical confirmation of *Sarcocystis neurona*
infections in raccoon, mink, cat, skunk, and pony.
Journal of Parasitology 86: 1150–1152.
- , AND D. S. LINDSAY. 1998. Isolation in im-
munodeficient mice of *Sarcocystis neurona* from
opossum (*Didelphis virginiana*) feces, and its dif-
ferentiation from *Sarcocystis falcatula*. *International Journal of Parasitology* 28: 1823–1828.
- , C. A. SPEER, AND R. FAYER. 1989. *Sarco-
cystosis of animals and man*. CRC Press Inc.,
Boca Raton, Florida, 215 pp.
- , D. S. LINDSAY, D. FRITZ, AND C. A. SPEER.
2001a. Structure of *Sarcocystis neurona* sarco-
cysts. *Journal of Parasitology* 87: 1323–1327.
- , A. C. ROSYPAL, B. M. ROSENTHAL, N. J.
THOMAS, D. S. LINDSAY, J. F. STANEK, S. M.
REED, AND J. A. SAVILLE. 2001b. *Sarcocystis
neurona* infections in sea otters (*Enhydra lutris*):
Evidence for natural infections with sarcocystosis
and transmission of infection to opossums (*Di-
delphis virginiana*). *Journal of Parasitology* 87:
1387–1393.
- , A. N. HAMIR, AND M. J. TOPPER. 2002. *Sar-
cocystis mephitis* n. sp. (Protozoa: Sarcocysti-
dae), *Sarcocystis neurona*-like and *Toxoplasma*-
like infections in striped skunks (*Mephitis me-
phitis*). *Journal of Parasitology* 88: 113–117.
- FENGER, C. K., D. E. GRANDSTROM, A. A. GAJAD-
HAR, N. M. WILLIAMS, S. A. MCCRILLIS, S.
STAMPER, J. L. LANDGEMEIER, AND J. P. DUBEY.
1997. Experimental induction of equine proto-
zoal myeloencephalitis in horses using *Sarcocys-
tis* sp. sporocysts from the opossum (*Didelphis
virginiana*). *Veterinary Parasitology* 68: 199–213.
- HYMAN, J. A., L. K. JOHNSON, M. M. TSAI, AND T. J.
O'LEARY. 1995. Specificity of polymerase chain
reaction identification of *Toxoplasma gondii* in-
fection in paraffin-embedded animal tissues.
Journal of Veterinary Diagnostic Investigation 7:
275–278.
- LINDSAY, D. S., AND J. P. DUBEY. 1989. Immuno-
histochemical diagnosis of *Neospora caninum* in
tissue sections. *American Journal of Veterinary
Research* 50: 1981–1983.
- , N. J. THOMAS, AND J. P. DUBEY. 2000. Bi-
ological characterization of *Sarcocystis neurona*
isolated from a southern sea otter (*Enhydra lu-
tris nereis*). *International Journal of Parasitology*
30: 617–624.
- , ———, A. C. ROSYPAL, AND J. P. DUBEY.
2001. Dual *Sarcocystis neurona* and *Toxoplasma
gondii* infection in a northern sea otter from
Washington state, USA. *Veterinary Parasitology*
97: 319–327.
- MARTIN, S. K. 1994. Feeding ecology of American
martens and fishers. In *Martens, sables, and fish-
ers biology and conservation*, S. W. Buskirk, A.
S. Harestad, M. G. Raphael, and R. A. Powell
(eds.). Cornell University Press, Ithaca, New
York, pp. 297–315.
- MILLER, M. A., P. R. CROSBIE, K. SVERLOW, K. HAN-
NI, B. C. BARR, N. KOCK, M. J. MURRAY, L. J.
LOWENSTEIN, AND P. A. CONRAD. 2001a. Iso-
lation and characterization of *Sarcocystis* from

- brain tissue of a free-living southern sea otter (*Enhydra lutris nereis*) with fatal meningoencephalitis. *Parasitology Research* 87: 252–257.
- , K. SVERLOW, P. R. CROSBIE, B. C. BARR, L. J. LOWENSTEIN, F. M. GULLAND, A. PACKHAM, AND P. A. CONRAD. 2001b. Isolation and characterization of two parasitic protozoa from a Pacific harbor seal (*Phoca vitulina richardsi*) with meningoencephalomyelitis. *Journal of Parasitology* 87: 816–822.
- REED, W. M., AND J. J. TUREK. 1985. Concurrent distemper and disseminated toxoplasmosis in a red fox. *Journal of the American Veterinary Medical Association* 187: 1264–1265.
- STANEK, J. F., J. P. DUBEY, M. J. OGLESBEE, S. M. REED, D. S. LINDSAY, L. A. CAPITINI, C. J. MJOKU, K. L. VITTITOW, AND W. J. A. SAVILLE. 2002. Life cycle of *Sarcocystis neurona* in its natural intermediate host, the raccoon, *Procyon lotor*. *Journal of Parasitology* 88: 1151–1158.
- STOFFREGEN, D. A., AND J. P. DUBEY. 1991. A *Sarcocystis*-like protozoan and concurrent canine distemper virus infection associated with encephalitis in a raccoon (*Procyon lotor*). *Journal of Wildlife Diseases* 27: 688–692.
- TANHAUSER, S. M., C. A. YOWELL, T. J. CUTLER, E. C. GREINER, R. J. MACKAY, AND J. B. DAME. 1999. Multiple DNA markers differentiate *Sarcocystis neurona* and *Sarcocystis falciparum*. *Journal of Parasitology* 85: 221–228.
- WILLIAMS, E. S., E. T. THORNE, M. J. G. APPEL, AND D. W. BELITSKY. 1988. Canine distemper in black-footed ferrets (*Mustela nigripes*) from Wyoming. *Journal of Wildlife Diseases* 24: 385–398.
- YAMAGE, M., O. FLECHER, AND B. GOTTSTEIN. 1996. *Neospora caninum*-specific oligonucleotide primers for the detection of brain “cyst” DNA of experimentally infected nude mice by the polymerase chain reaction (PCR). *Journal of Parasitology* 82: 272–279.

Received for publication 11 January 2004.