

## **Fatal West Nile Virus Infection in a White-tailed Deer (*Odocoileus virginianus*)**

Authors: Miller, Debra L., Radi, Zaher A., Baldwin, Charles, and Ingram, Dallas

Source: Journal of Wildlife Diseases, 41(1) : 246-249

Published By: Wildlife Disease Association

URL: <https://doi.org/10.7589/0090-3558-41.1.246>

---

BioOne Complete ([complete.BioOne.org](https://complete.BioOne.org)) is a full-text database of 200 subscribed and open-access titles in the biological, ecological, and environmental sciences published by nonprofit societies, associations, museums, institutions, and presses.

Your use of this PDF, the BioOne Complete website, and all posted and associated content indicates your acceptance of BioOne's Terms of Use, available at [www.bioone.org/terms-of-use](https://www.bioone.org/terms-of-use).

Usage of BioOne Complete content is strictly limited to personal, educational, and non - commercial use. Commercial inquiries or rights and permissions requests should be directed to the individual publisher as copyright holder.

---

BioOne sees sustainable scholarly publishing as an inherently collaborative enterprise connecting authors, nonprofit publishers, academic institutions, research libraries, and research funders in the common goal of maximizing access to critical research.

## Fatal West Nile Virus Infection in a White-tailed Deer (*Odocoileus virginianus*)

Debra L. Miller,<sup>1,2</sup> Zaher A. Radi,<sup>1</sup> Charles Baldwin,<sup>1</sup> and Dallas Ingram<sup>1</sup> <sup>1</sup> The University of Georgia, College of Veterinary Medicine, Veterinary Diagnostic and Investigational Laboratory, 43 Brighton Road, Tifton, Georgia 31793-1389, USA; <sup>2</sup> Corresponding author (email: dmiller@tifton.uga.edu)

**ABSTRACT:** A 3-yr-old male white-tailed deer (*Odocoileus virginianus*) with a history of ataxia and tremors was submitted to the Tifton Veterinary Diagnostic and Investigational Laboratory (The University of Georgia, Tifton, Georgia, USA) for necropsy. Gross findings were unremarkable. Histologically, the brain had multifocal lymphoplasmacytic perivascular inflammation, scattered gliosis, and rare satellitosis. Mild hemorrhage and congestion in the retropharyngeal lymph nodes and mild lymphoid depletion in the tonsil were present. A reverse transcription–polymerase chain reaction test performed on brain yielded a positive result for West Nile virus. This represents the first report of fatal West Nile virus infection in a white-tailed deer.

**Key words:** Case report, flavivirus, *Odocoileus virginianus*, reverse transcription–polymerase chain reaction, West Nile virus, white-tailed deer.

Since its recognition in 1999, West Nile virus (WNV) has been reported in numerous species but with great variability in morbidity and mortality. Avian species (especially Corvidae) and horses have been severely affected. Recently, surveillance and clinical testing have identified the virus in free-ranging wild mammals (Farajollahi et al., 2003; Kiupel et al., 2003). Farajollahi et al. (2003) found three (6%) of 51 black bears (*Ursus americanus*) surveyed in New Jersey (USA) seropositive for WNV, but clinical disease was not identified. Kiupel et al. (2003) identified clinical disease associated with WNV infection in three eastern fox squirrels (*Sciurus niger*) in Michigan (USA) and reported the lesions as similar to those reported in crows. Neither of the reports suggested that WNV posed a significant threat to either of these species.

A 73-kg, approximately 3-yr-old male white-tailed deer (*Odocoileus virginianus*) from Bainbridge, Georgia (Decatur Coun-

ty, USA; 30°53'N, 84°35'W), was submitted to the University of Georgia Tifton Veterinary Diagnostic and Investigational Laboratory (Tifton, Georgia, USA) for necropsy. The animal had been orphaned, raised to weaning by a rehabilitator, and released to the wild. Despite being free-ranging, the deer remained within the vicinity and was observed on a daily basis.

Based on observations by the land owner, the deer had 2–3 days of apparent anorexia and 1 day of ataxia and tremors subsequent to death. At necropsy, the animal was in good flesh, had no external evidence of trauma, and no significant gross findings were noted. Tissues collected included eye, thyroid, retropharyngeal lymph node, lung, heart, brain, spinal cord, kidney, liver, spleen, pancreas, adrenal gland, tonsil, trachea, rumen, reticulum, omasum, abomasum, intestines, and reproductive tract and feces also were collected. Fresh tissue samples were submitted for infectious disease testing (Table 1). Protocols for virus isolation and reverse transcription–polymerase chain reaction (RT-PCR) for WNV, eastern equine encephalitis (EEE) virus, and St. Louis encephalitis virus were as outlined by Miller et al. (2003). Additionally, sections of all collected tissues were placed in 10% buffered formalin, processed, and embedded in paraffin, sliced 5 µm thick, hematoxylin and eosin–stained slide mounts were made, and these were viewed by light microscopy. Finally, a fecal specimen was submitted for negative-stain electron microscopic examination for viruses and for floatation for evidence of parasites.

Light microscopic examination of the brain revealed multifocal mild to moderate numbers of lymphocytes, plasma cells, and

TABLE 1. Tissues collected and tests conducted on tissues from a white-tailed deer from Decatur County, Georgia, USA.

Test conducted	Tissues tested
Virus isolation (Miller et al., 2003)	Lymph node, lung, kidney, liver, spleen, intestines
Reverse transcription–polymerase chain reaction for West Nile virus, eastern equine encephalitis virus, St. Louis encephalitis virus (Miller et al., 2003)	Brain
Fluorescent antibody for epizootic hemorrhagic disease virus (Miller et al., 2003)	Lymph node, lung, tonsil
Bacterial culture	Lymph node, lung, brain, kidney, liver, spleen, intestines
Immunohistochemistry for chronic wasting disease (University of Georgia–Athens Diagnostic Laboratory, Athens, Georgia, USA; Spraker et al., 2002)	Obex of brain

macrophages in perivascular infiltrates randomly scattered throughout the brain stem (Fig. 1). Scattered gliosis and rare satellitosis were noted. Mild hemorrhage and congestion were noted in the lymph

node. Mild lymphoid depletion was found in the tonsil. The heart and skeletal muscle had rare scattered protozoal cysts. The spleen was congested. No other significant microscopic findings were noted.

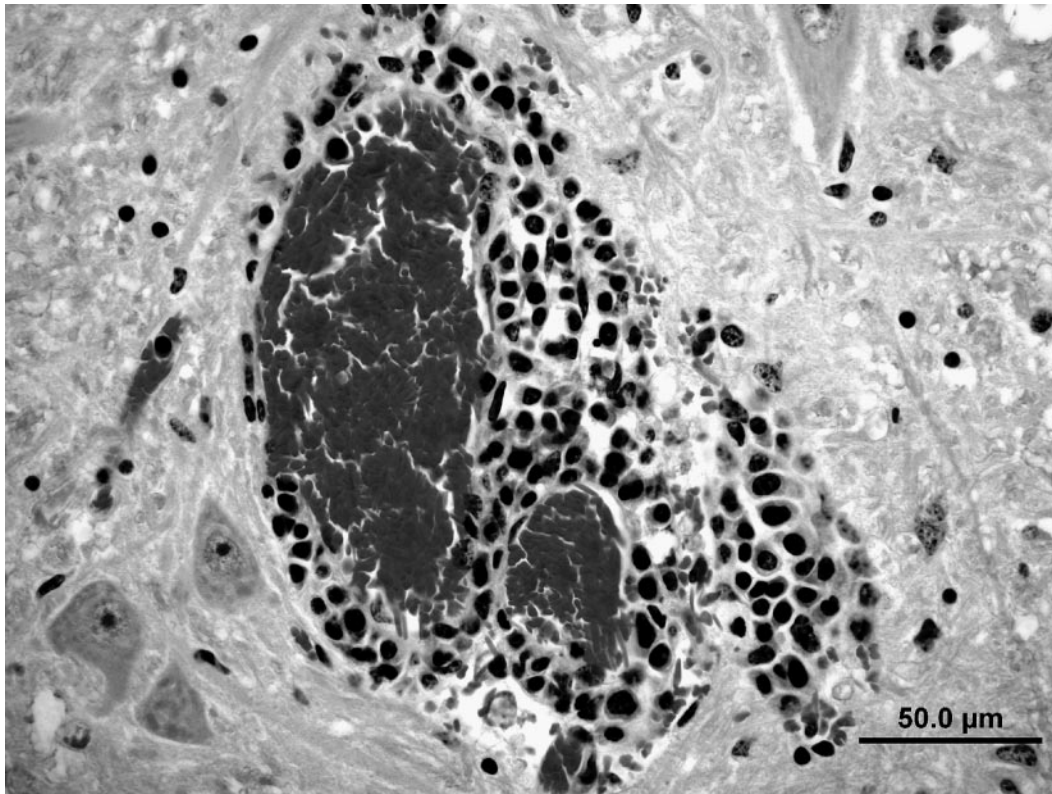


FIGURE 1. Mononuclear perivascular infiltrates in the brain stem of a 3-yr-old male white-tailed deer that was positive by reverse transcription–polymerase chain reaction for West Nile virus. Hematoxylin and eosin stain.

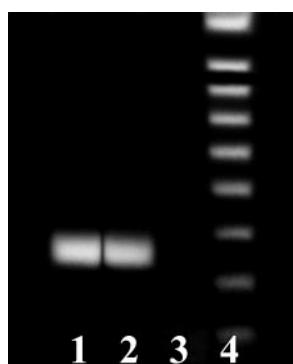


FIGURE 2. Agarose gel (1.5%) showing nested reverse transcription–polymerase chain reaction amplification of the 248-base pair (bp) RNA product for West Nile virus from brain of a white-tailed deer (lane 1). Lane 2 is the positive control, lane 3 is the negative control, and lane 4 is the 100-bp DNA ladder.

Results of the virus isolation attempt from fresh tissue were negative; however, the RT-PCR tests performed on the brain tissue yielded positive results for WNV (Fig. 2). The negative isolation result may have been due to low quantity of virus present in the tissue, location of the specimen collected for isolation, or inactivation of virus after death. Results of tests on tissues for epizootic hemorrhagic disease, chronic wasting disease, and significant bacterial organisms were negative. Results of RT-PCR were negative for EEE and St. Louis encephalitis viruses. Results of electron microscopic examination of feces were negative for viruses. Fecal floatation did not yield evidence of marked parasitism.

To date, WNV has been reported in numerous species (primarily avian species but also reptiles, amphibians, and mammals), but with great variability in morbidity and mortality (McLean et al., 2002). Clinically affected individuals either die directly from WNV infection or succumb to secondary invaders (Miller et al., 2003). Ludwig et al. (2002) conducted a serologic survey for evidence of WNV infection in multiple species of captive and some free-ranging animals in New York (USA). No species of Cervidae were seropositive;

however, white-tailed deer were not tested. Recently, seven of 689 white-tailed deer in New Jersey were found to be seropositive for WNV, with no evidence of clinical disease (Farajollahi et al., 2004). The deer in our study died with no evidence of opportunistic or underlying disease that would suggest that WNV simply served as a predisposing factor. Thus, we conclude that the cause of death in this white-tailed deer was WNV. The prevalence of WNV infection in white-tailed deer remains unknown. Increased occurrence of clinical WNV infection in a variety of species may be due to emergence of new strains of the virus (McLean et al., 2002). The strain of WNV in this deer was not determined, but to our knowledge, this represents the first reported case of fatal WNV in a white-tailed deer. Given that WNV is a vector-borne pathogen, infection in deer has no direct human health implications, except to indicate that the virus is present in the area. Likewise, WNV is not likely a major threat to white-tailed deer populations, although clinical disease and occasional mortality due to WNV is possible. Further, we surmise that, as with horses, white-tailed deer most likely are dead-end hosts.

The authors wish to thank the staff of the Tifton Veterinary Diagnostic and Investigational Laboratory for assistance in specimen analysis.

#### LITERATURE CITED

- FARAJOLLAHI, A., A. N. PANELLA, P. CARR, W. CRANS, K. BURGUESS, AND N. KOMAR. 2003. Serologic evidence of West Nile virus infection in black bears (*Ursus americanus*) from New Jersey. *Journal of Wildlife Diseases* 39: 894–896.
- , R. GATES, W. CRANS, AND N. KOMAR. 2004. Serologic evidence of West Nile virus and St. Louis Encephalitis virus infections in white-tailed deer (*Odocoileus virginianus*) from New Jersey, 2001. *Vector Borne and Zoonotic Diseases* 4: 379–383.
- KIUPEL, M., H. A. SIMMONS, S. D. FITZGERALD, A. WISE, J. G. SIKARSKIE, T. M. COOLEY, S. R. HOLLAMBY, AND R. MAES. 2003. West Nile virus infection in eastern fox squirrels (*Sciurus niger*). *Veterinary Pathology* 40: 703–707.
- LUDWIG G. V., P. P. CALLE, J. A. MANGIAFICO, B. L.

- RAPHAEL, D. K. DANNER, J. A. HILE, T. L. CLIPPINGER, F. J. SMITH, R. A. COOK, AND T. MCNAMARA. 2002. An outbreak of West Nile virus in a New York City captive wildlife population. *American Journal of Tropical Medicine and Hygiene* 67: 67–75.
- MCLEAN, R. G., S. R. UBICO, D. BOURNE, AND N. KOMAR. 2002. West Nile virus in livestock and wildlife. *Current Topics in Microbiological Immunology* 267: 271–308.
- MILLER, D. L., M. J. MAUEL, C. BALDWIN, G. BURTLE, D. INGRAM, M. E. HINES II, AND K. S. FRAZIER. 2003. West Nile virus in farmed alligators. *Emerging Infectious Diseases* 9: 794–799.
- SPRAKER, T. R., R. R. ZINK, B. A. CUMMINGS, M. A. WILD, M. W. MILLER, AND K. I. O'ROURKE. 2002. Comparison of histological lesions and immunohistochemical staining of proteinase-resistant prion protein in a naturally occurring spongiform encephalopathy of free-ranging mule deer (*Odocoileus hemionus*) with those of chronic wasting disease of captive mule deer. *Veterinary Pathology* 39: 110–119.

*Received for publication 28 January 2004.*