

Papillomatosis in a European Bison

I. Literák,^{1,6} Y. Tomita,² T. Ogawa,² H. Shirasawa,² B. Šmíd,³ L. Novotný,⁴ and M. Adamec⁵

¹ Department of Biology and Wildlife Diseases, Faculty of Veterinary Hygiene and Ecology, University of Veterinary and Pharmaceutical Sciences, Palackého 1-3, 612 42 Brno, Czech Republic; ² Department of Molecular Virology, Graduate School of Medicine, Chiba University, 1-8-1 Inohana, Chuou-ku, Chiba 260-8670, Japan; ³ Veterinary Research Institute, Hudcova 70, 621 32 Brno, Czech Republic; ⁴ Department of Pathology, Faculty of Veterinary Medicine, University of Veterinary and Pharmaceutical Sciences, Palackého 1-3, 612 42 Brno, Czech Republic; ⁵ State Nature Conservancy of the Slovak Republic, Center for Nature and Landscape Protection, Lazovná 10, 974 01 Banská Bystrica, Slovakia; ⁶ Corresponding author (email: literaki@vfu.cz)

ABSTRACT: Five European bison (*Bison bonasus*) from three European zoos were shipped to the Bukovské Vrchy Hills (Slovakia) in June 2004 and kept together in an acclimatization enclosure. The European bison were released into the wild in December 2004. At that time, papillomas were found at the medial canthus of the left eye of a 12-yr-old female bison. Cutaneous papillomatosis was confirmed histologically. Negative stain transmission electron microscopic examination revealed papillomavirus in the papillomas, and papillomavirus DNA also was detected using the polymerase chain reaction with FAP59 and FAP64 primers. The amplified 413 bp DNA sequence was identical to that of BAPV2 bovine papillomavirus. This paper is the first report of papillomatosis in European bison.

Key words: *Bison bonasus*, cattle, Italy, lesions, skin, Slovakia.

Attempts are being made in various European countries to reintroduce the European bison *Bison bonasus* (Linnaeus, 1758) (Pucek et al., 2004). In 2004 Slovakia began reintroducing bison to the Bukovské Vrchy Hills area along the borders with Poland and Ukraine (Adamec, 2004). A group of five bison from three European zoological gardens was shipped to the Bukovské Vrchy Hills (49°07'N, 22°21'E) and placed into a quarantine-cum-acclimatization enclosure in June 2004. They were a 12-yr-old and a 2-yr-old female from the Bussolegno Zoo (Italy), a 2-yr-old male from the Amsterdam Zoo (The Netherlands), and a 9-month-old male and a female from the Goldau Zoo (Switzerland). The bison were fitted with transmitters for telemetric tracking and released into the wild in December 2004.

Clinical examination of the bison re-

vealed papillomatous lesions at the left eye of the oldest female before they were released. Papillomatosis has not been reported in European bison, and the aim of this report was to describe the papillomatous lesions found and characteristics of the papillomavirus causing the lesions.

During a standard clinical examination, clusters of papillomas (approximately 70) as well as individual papillomas several millimeters in size were found on an area of about 9 cm² outside the medial canthus of the left eye of a 12-yr-old bison female (Fig. 1). The papillomas were dry, rough, and lightly colored. The bison affected was immobilized with detomidine hydrochloride (20 µg/kg IM; Domosedan, Pfizer, Czech Republic) and ketamine hydrochloride (2 mg/kg IM; Narkamon, Spofa, Czech Republic), and some of the papillomas were scraped off. Part of the material collected was placed in a test tube and frozen at -18 C, and part was fixed in 70% ethanol. No papillomatous lesions were found on any of the other four bison in the group to be released. A month after release, the bison were located by means of the telemetric devices and checked through binoculars for papillomatous lesions. The location and size of papillomas of the affected bison were the same as when samples were collected; no papillomatous lesions were found on any of the other four bison and one wild bison that had joined the group.

Veterinary records of the bison with papillomas contain no mention of papillomatosis. The staff of the Bussolegno Zoo claimed that no papillomatous lesions

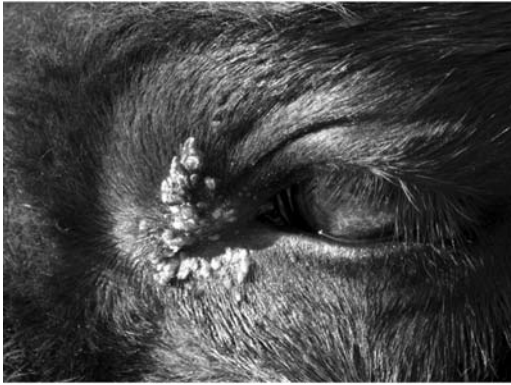

FIGURE 1. Papillomas at the medial canthus of the left eye of a European bison.

were found on this or any other bison, or even any other animal in the zoo. The bison enclosure of the Bussolegno Zoo adjoins the domestic cattle enclosure, but no papillomatous lesions were found there either. Nor did physical examination of the bison on their arrival at the Bukovské Vrchy Hills reveal any skin lesions. The keeper taking care of the bison during their stay at the acclimatization game preserve first noticed the papillomas at the eye of the one bison when it had been in the preserve for some (unspecified) time.

For a histopathologic examination, specimens were processed by a standard paraffin technique, and 5- μm thick sections were stained with hematoxylin and eosin and examined by light microscopy. Frozen tissue was prepared for transmission electron microscopy by a negative staining technique. Small pieces of tissue (approximately 0.5 mm³) were lysed in several drops of distilled water, and a grid coated with a formvar film and carbon was placed onto the surface of the lysate. After 15 sec, the grid was removed, and residual water was drawn off with a strip of filter paper. The preparation was treated with one drop of 2% aqueous ammonium molybdate for several seconds, and after drawing off the excess stain, it was viewed in a Philips EM 208 electron microscope (Philips, The Netherlands).

For polymerase chain reaction (PCR) and DNA sequence analysis, a papilloma was divided into two pieces and then homogenized in mortars refrigerated with liquid nitrogen. The DNA was extracted using the High Pure PCR template preparation kit (Roche Diagnostics, France). Five microliters of purified DNA from each sample was used for analyses by PCR in a final reaction volume of 50 μl . The PCR was carried out using a primer set, FAP59/FAP64, designed by Forslund et al. (1999) using conditions described previously (Ogawa et al., 2004). The PCR products were analyzed by electrophoresis on a 2% agarose gel. The nucleotide sequence of one PCR product was determined by the direct sequencing method. Similarity searches of the sequence were performed by the NCBI WWW-Blast server on the GenBank DNA database, and by CLUSTALW version 1.82.

Microscopically, the papillomas were characterized by hyperplasia of epidermal basal cells, moderate acanthosis, hyperkeratosis and parakeratosis (Fig. 2A), and few basophilic intranuclear inclusion bodies in the stratum granulosum (Fig. 2B). Negative stain transmission electron microscopy demonstrated typical papillomavirus virions approximately 52–55 nm in diameter with capsids composed of capsomeres arranged in icosahedral symmetry in the lesions (Fig. 2C). The PCR with FAP59/FAP64 primer set amplified a 478 bp-long DNA fragment from the DNA extracted from the papillomatous material. As shown in Figure 3, the nucleotide sequence of 413 bp of an amplicon was identical with that of BAPV2 bovine papillomavirus (GenBank Accession number AY300818).

The authors found no mention of papillomatous lesions in European bison in the literature, and the recent overview of classified papillomaviruses (Villiers et al., 2004) does not list any European bison papillomavirus. In this case, papillomatosis was caused by a papillomavirus that had

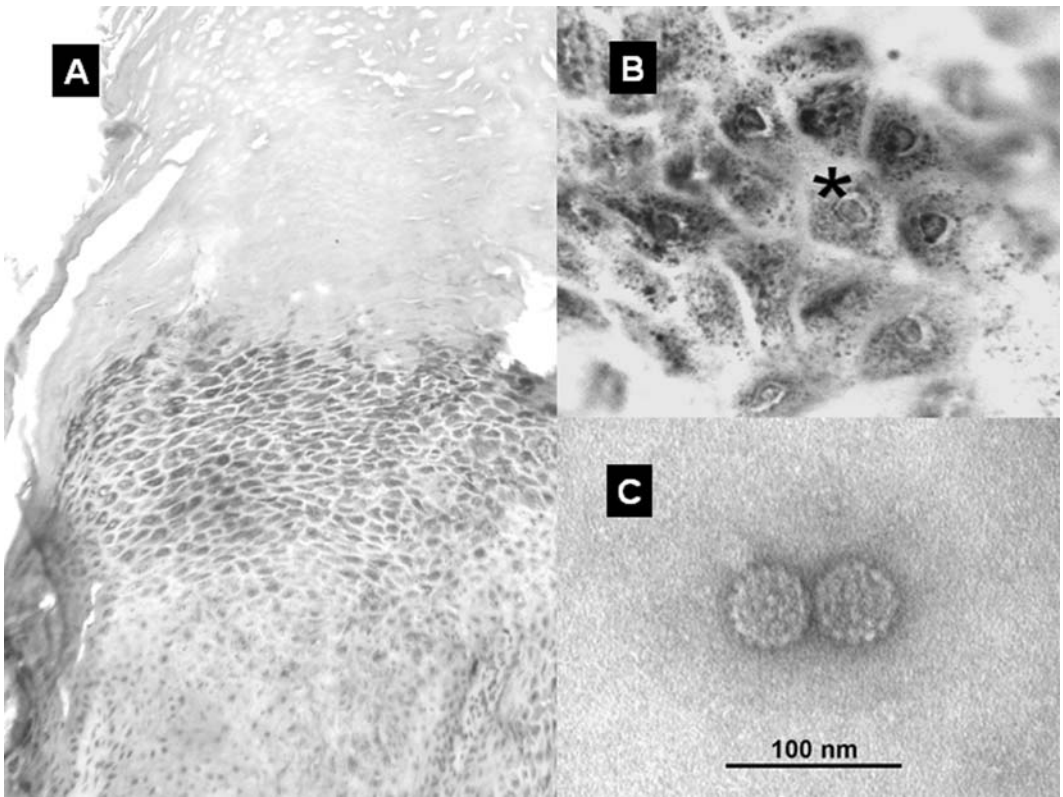


FIGURE 2. Skin; European bison. (A) Histologic section of cutaneous papilloma showing marked hyperkeratosis and acanthosis. Stained with hematoxylin and eosin. (B) Histologic section of stratum granulosum at higher magnification showing basophilic intranuclear inclusion in a degenerated keratinocyte (asterisk). Stained with hematoxylin and eosin. (C) Negative stain transmission electron microscopic preparation of papillomavirus virions with capsids composed of capsomers in icosahedral symmetry. Stained with ammonium molybdate.

the same molecular and biological characteristics as the recently described papillomavirus, BAPV2, which was isolated from cattle in Japan and, based on its genotype, described as a putative new bovine papillomavirus type (Ogawa et al., 2004). This papillomavirus also was isolated from papillomatous lesions on the teats of dairy cows and from smears taken from teats with no papillomatous lesions.

The European bison is related to cattle, both species belonging to the Bovidae family, which may explain nonspecific infection with a bovine papillomavirus in the European bison. Cattle have not been reared at the site of the acclimatization enclosure in the Bukovské Vrchy Hills, and

the bison probably was infected in the Bussolegno Zoo, where bison and domestic cattle were kept next to each other, and cattle-to-bison transfer of infection is feasible. Both domestic cattle and bison in the zoo may be colonized by a papillomavirus without exhibiting any clinical manifestation of the disease.

Clinical manifestation of the latent infection may have been provoked by stress due to transport over a distance of hundreds of kilometers in a trailer from the Bussolegno Zoo to the Bukovské Vrchy Hills and the new rearing methods in the acclimatization enclosure. In addition, the affected female bison was the oldest member of the group and perhaps the

```

EB      AATATTCCCAAAGTTAGTGGCAATCAATATAGGGTGTTTAGAGTGACACTTCCAGACCCA 60
BAPV2  ----TTCCCAAAGTTAGTGGCAATCAATATAGGGTGTTTAGAGTGACACTTCCAGACCCA 56
      *****

EB      AATCAATTTGCCCTTCCTGACAAACAATTCATAATCCCAGCAAGGAGAAGCTTGTTTGG 120
BAPV2  AATCAATTTGCCCTTCCTGACAAACAATTCATAATCCCAGCAAGGAGAAGCTTGTTTGG 116
      *****

EB      TCCATAATGGGCCTACAGGTAAGTAGAGGGCAGCCTTTAGGAGCACCTGTCACAGGCCAT 180
BAPV2  TCCATAATGGGCCTACAGGTAAGTAGAGGGCAGCCTTTAGGAGCACCTGTCACAGGCCAT 176
      *****

EB      AATTTATTTAATGTTTGGACAGATGCAGAAAATGTCACAAGTAAACGTGCAACACAAGGG 240
BAPV2  AATTTATTTAATGTTTGGACAGATGCAGAAAATGTCACAAGTAAACGTGCAACACAAGGG 236
      *****

EB      TCAGATGACAGGAAGCAACTAGGGTTTGATGTCAAACAGAGTCAAATACTTCTAGTGGGC 300
BAPV2  TCAGATGACAGGAAGCAACTAGGGTTTGATGTCAAACAGAGTCAAATACTTCTAGTGGGC 296
      *****

EB      TGTACACCAGCCACAGGTGAATACTGGGGCAAAGCTGCAGAATGTCCTGAAAAGCGGCCT 360
BAPV2  TGTACACCAGCCACAGGTGAATACTGGGGCAAAGCTGCAGAATGTCCTGAAAAGCGGCCT 356
      *****

EB      GCTCCTGGAGGCTGCCACCTATAGAGCTGAAGAACAAGCCTATAGAGGATGGCGAC 417
BAPV2  GCTCCTGGAGGCTGCCACCTATAGAGCTGAAGAACAAGCCTATAGAGGATGGCGAC 413
      *****
    
```

SeqA Name	Len (nt)	SeqB Name	Len (nt)	Score
1 EB	417	2 BAPV2	413	100

FIGURE 3. DNA sequence of 413 bp amplicon derived from a European bison (EB) virus compared to the consensus sequence of BAPV2 (GenBank Accession number AY300818). Asterisks indicate identical bases.

least able to accommodate changes in husbandry.

Papillomas were found on the head of this bison similar to cattle where papillomas are commonly found on the head, neck, and shoulders, and occasionally on the back and abdomen (Aiello, 1998). The extent and duration of papillomatous lesions depend on the type of virus, area affected, and degree of susceptibility. Warts appear ~2 mo after exposure and may last ≥1 yr. A form of persistent cutaneous papillomatosis with smaller numbers of papillomas may occur in herds of older cattle.

Proliferation of basal epidermal cells with solitary intranuclear inclusions in the epidermis was suggestive of viral etiology for the papillomatous growths. Based on

histopathologic features, Hamada et al. (1990) subdivided viral cutaneous papillomas in horses into three phases: growing, developing, and regressing. Morphology of the papillomas in this case corresponds with the growing phase, as only a few intranuclear inclusions are found in keratinocytes during this phase.

The European bison introduced to the Bukovské Vrchy Hills most likely brought the papillomavirus with them. However, during several months of their stay together, no symptoms of papillomatosis were found in the rest of the bison. How the infection will manifest itself among the European bison population in the Bukovské Vrchy Hills in the future remains open.

This study was partially funded by the

grant MSM6215712402 from the Ministry of Education, Youth, and Sports of the Czech Republic.

LITERATURE CITED

- ADAMEC, M. 2004. Strategy for conservation of the European bison in Slovakia. *In* Proceedings: European Bison Conservation—An International Conference, M. Krasínska and K. Daleszczyk (eds.). Mammal Research Institute, Polish Academy of Sciences, Białowieża, Poland, pp. 9–12.
- AIELLO, S. E. (ed.). 1998. The Merck veterinary manual, 8th Edition. Merck and Co., Whitehouse Station, New Jersey, 2305 pp.
- FORSLUND, O., A. ANTONSSON, P. NORDIN, B. STEINQUIST, AND B. G. HANSSON. 1999. A broad range of human papillomavirus types detected with a general PCR method suitable for analysis of cutaneous tumours and normal skin. *Journal of General Virology* 80: 2437–2443.
- HAMADA, M., T. OYAMADA, H. YOSHIKAWA, T. YOSHIKAWA, AND C. ITAKURA. 1990. Histopathological development of equine cutaneous papillomas. *Journal of Comparative Pathology* 102: 393–403.
- OGAWA, T., Y. TOMITA, M. OKADA, K. SHINOZAKI, H. KUBONOYA, I. KAIHO, AND H. SHIRASAWA. 2004. Broad-spectrum detection of papillomaviruses in bovine teat papillomas and healthy teat skin. *Journal of General Virology* 85: 2191–2197.
- PUCEK, Z., I. P. BELOUSOVA, M. KRASINSKA, Z. A. KRASINSKI, AND W. OLECH. 2004. European bison. Status survey and conservation action plan. IUCN/SSC Bison Specialist Group. IUCN, Gland, Switzerland, Cambridge, UK, 54 pp.
- DE VILLIERS, E.-M., C. FAUGUET, T. R. BROKER, H. U. BERNARD, AND H. ZUR HAUSEN. 2004. Classification of papillomaviruses. *Virology* 324: 17–27.

Received for publication 6 March 2005.