

PSEUDORABIES VIRUS IN EUROPEAN WILD BOAR FROM CENTRAL ITALY

Authors: Lari, Andrea, Lorenzi, Davide, Nigrelli, Daniele, Brocchi, Emiliana, Faccini, Silvia, et al.

Source: Journal of Wildlife Diseases, 42(2) : 319-324

Published By: Wildlife Disease Association

URL: <https://doi.org/10.7589/0090-3558-42.2.319>

BioOne Complete (complete.BioOne.org) is a full-text database of 200 subscribed and open-access titles in the biological, ecological, and environmental sciences published by nonprofit societies, associations, museums, institutions, and presses.

Your use of this PDF, the BioOne Complete website, and all posted and associated content indicates your acceptance of BioOne's Terms of Use, available at www.bioone.org/terms-of-use.

Usage of BioOne Complete content is strictly limited to personal, educational, and non - commercial use. Commercial inquiries or rights and permissions requests should be directed to the individual publisher as copyright holder.

BioOne sees sustainable scholarly publishing as an inherently collaborative enterprise connecting authors, nonprofit publishers, academic institutions, research libraries, and research funders in the common goal of maximizing access to critical research.

PSEUDORABIES VIRUS IN EUROPEAN WILD BOAR FROM CENTRAL ITALY

Andrea Lari,¹ Davide Lorenzi,¹ Daniele Nigrelli,² Emiliana Brocchi,³ Silvia Faccini,² and Alessandro Poli^{1,4}

¹ Dipartimento di Patologia Animale, Profilassi ed Igiene degli Alimenti, Università degli Studi di Pisa—Viale delle Piagge, 2 I-56124 Pisa, Italy

² Istituto Zooprofilattico Sperimentale (IZS) della Lombardia e dell'Emilia Romagna, Str. Circonvallazione Sud 21/a, I-46100, Motova, Italy

³ IZS della Lombardia e dell'Emilia Romagna, Via Bianchi, 9, I-25124, Brescia, Italy

⁴ Corresponding author (email: apoli@vet.unipi.it)

ABSTRACT: Tissue and blood samples were collected from 152 wild boars (*Sus scrofa*) from the Maremma area (Grosseto district, Central Italy) between November 2002 and January 2003. The presence of pseudorabies virus (PRV) antibodies, antigen, and DNA were confirmed by an enzyme-linked immunosorbent assay (ELISA), immunohistochemistry, and polymerase chain reaction (PCR), respectively. Of 152 animals, 62 (41%) were positive for viral antigen in tonsillar tissue. Of the 80 serum samples that were suitable for testing, 41 (51%) were positive for PRV antibodies. Positive immunohistochemistry results were confirmed by PCR. A significantly higher prevalence of PRV antigen and seroprevalence was detected in older animals. No differences were detected between males and females or for animals coming from different areas sampled. Results confirm that PRV is endemic in this wild boar population with a high prevalence of infection. The results of immunohistochemistry investigations demonstrated that a large number of wild boars harbor PRV in tonsillar tissues and should be considered as an important reservoir of PRV.

Key words: Aujeszky's disease, pseudorabies virus, serosurvey, *Sus scrofa*, tonsil, viral antigen immunohistochemistry.

INTRODUCTION

Wild boars (*Sus scrofa*) are widely distributed throughout Italy. The Maremma area, in the southwestern part of Tuscany, central Italy (2°33'28"N–11°08'25'E) is characterized by wooded areas with a high-density wild boar population. Pseudorabies virus (PRV; *Suid herpesvirus 1*, *Varicellovirus*, *Herpesviridae*) is an Alphaherpesvirus that causes pseudorabies or Aujeszky's disease. This disease is characterized by high mortality in neonatal piglets, weight loss, poor feed conversion in growers, and abortion in sows (Kluge et al., 1999) and has great economic impact on the swine industry. For this reason several European Union countries have implemented eradication programs. The virus has been reported from wild boar populations in both Europe and North America (Pirtle et al., 1989; Cordioli et al., 1993; Oslage et al., 1994; Muller et al., 1998), and this poses a serious threat to PRV eradication programs or maintaining PRV-free domes-

tic swine. Although there are numerous reports about PRV antibodies in wild swine, the virus has been only rarely isolated from this species (Nettles and Erickson, 1984; Capua et al., 1997a; Romero et al., 1997). Swine surviving acute PRV infection remain latently infected for life (Davies and Beran, 1980). During latency, PRV DNA, RNA, and latency-associated transcripts can be detected in the neurons of CNS ganglia, suggesting that these cells are the primary sites of latent PRV infection (Brown et al., 1995). However, under certain stressing factors, latent virus may become reactivated in tonsils and other nonneuronal tissues (Wittman et al., 1983); this can result in additional shedding and potential transmission to susceptible animals (Howarth, 1969).

Preliminary investigation demonstrated a high seroprevalence to PRV in the wild boar population in the Maremma area (Guberti et al., 2002). The purpose of our study was to further study the distribution of PRV infection in wild boars living in

this area and to better understand the potential transmission of PRV between wild boar and domestic swine by detection of viral antigen in tonsillar tissues.

MATERIALS AND METHODS

One hundred fifty-two wild boars, shot during the hunting season in Maremma, southern part of Tuscany (Italy), were examined from November 2002 to January 2003. Portions of tonsils, lymph nodes (mandibular, pulmonary, and inguinal), lung, spleen, liver, kidney, testicle, skin, and serum samples were collected from each animal. Seventy-three animals were male and 79 females; 54 were <1 yr of age.

Representative portions of sampled tissues were fixed in 10% buffered formalin, pH 7.4 and routinely embedded in paraffin. Five-micrometer-thick sections were stained with hematoxylin and eosin (HE) for histologic evaluation and specific stains for fungi (periodic acid Schiff [PAS] and periodic acid silver methenamine [PASM]) and acid-fast bacteria (Ziehl-Neelsen). Additional sections were used for immunohistochemistry (IHC) to localize PRV antigen. Two anti-PRV MAbs (2H6 and 2E12), previously used to develop a competitive ELISA, were used as primary monoclonal antibodies (MAbs) (Grieco et al., 1997). The 2H6 MAb was directed against viral envelop glycoprotein (G) C (G I), whereas MAb 2E12 was specific for viral GE (G II).

Five-micrometer-thick sections on poly-L-lysine-coated slides were deparaffinized in xylene and rehydrated in alcohol. Endogenous peroxidase activity was blocked by incubating the slides for 5 min at 37 C in Endo/Blocker (Biomed) solution diluted in methanol 1:5. After blocking nonspecific staining with normal horse serum, the sections were individually incubated with the primary anti-PRV mouse monoclonal antibodies (2H6 or 2E12) diluted 1:200 in Tris buffer solution (TBS) for 1 hr at 37 C in a moist chamber. Sections were extensively washed in PBS and then incubated with a biotinylated affinity purified horse pan-specific secondary antibody (Vector Laboratories, Inc., Burlingame, California, USA). Sections were again washed before incubation for 10 min with the streptavidin-biotinylated horseradish peroxidase complex (Biospa, Milan, Italy), and the reaction was developed with the use of Nova Red (Vector Laboratories Inc., Burlingame, California, USA) for 10 min. Finally, the sections were counterstained with hematoxylin, dehydrated, and mounted. Positive controls were included in each staining

and consisted of sections of tonsils from a positive swine. Negative controls were obtained both by omitting the primary antibody and by using murine-unrelated primary monoclonal antibody.

Presence of specific anti-PRV antibodies was determined with the use of a commercial ELISA kit (Ceditest® PRV-gB, Strip Kit, Cedi-Diagnostics B.V., Lelystad, The Netherlands).

To confirm immunohistochemistry results, 10 tonsil samples from wild boars shot in an area with a high percentage of IHC-positive subjects were both formalin fixed and frozen at -20 C for polymerase chain reaction (PCR). Frozen samples were homogenized in 20% W/V saline buffer, and DNA was extracted from 150 µl of suspension with GenElute Mammalian Genomic DNA Kit (Sigma Aldrich, Milan, Italy), according to the manufacturer's instructions. Five microliters of DNA samples were used to perform a nested PCR using primer sets and a technique previously described by Bascuñana et al. (1997).

Potential relationships between the presence of PRV antigen or antibodies with age, gender, location of examined wild boars, and histologic changes were determined using chi-square test (Statistical package SPSS Advanced Statistics 7.5, SPSS Inc., Chicago, Illinois, USA).

During the study period, four domestic dogs living in the examined area were accidentally fed wild boar meat and died spontaneously, showing an acute neurologic syndrome, hypersalivation, vomiting, pruritus, depression, and coma. Tissue samples from these animals were collected and submitted for histopathologic examination and PRV immunohistochemistry.

RESULTS

Alteration of lymphoid tissue was detected in a high proportion of wild boars examined; 38% of subjects showed hyperplasia and 30% depletion of lymphoid tissue, both in spleen and lymph nodes. Almost all examined animals (84%), had inflammatory changes in tonsils. The extent of inflammation was classified as light, moderate, or severe in 42%, 35%, and 7% of animals, respectively. In contrast, interstitial pneumonia was detected only in 15% of examined subjects. Except for severe tonsillitis ($P=0.091$), all these histopathologic changes were found

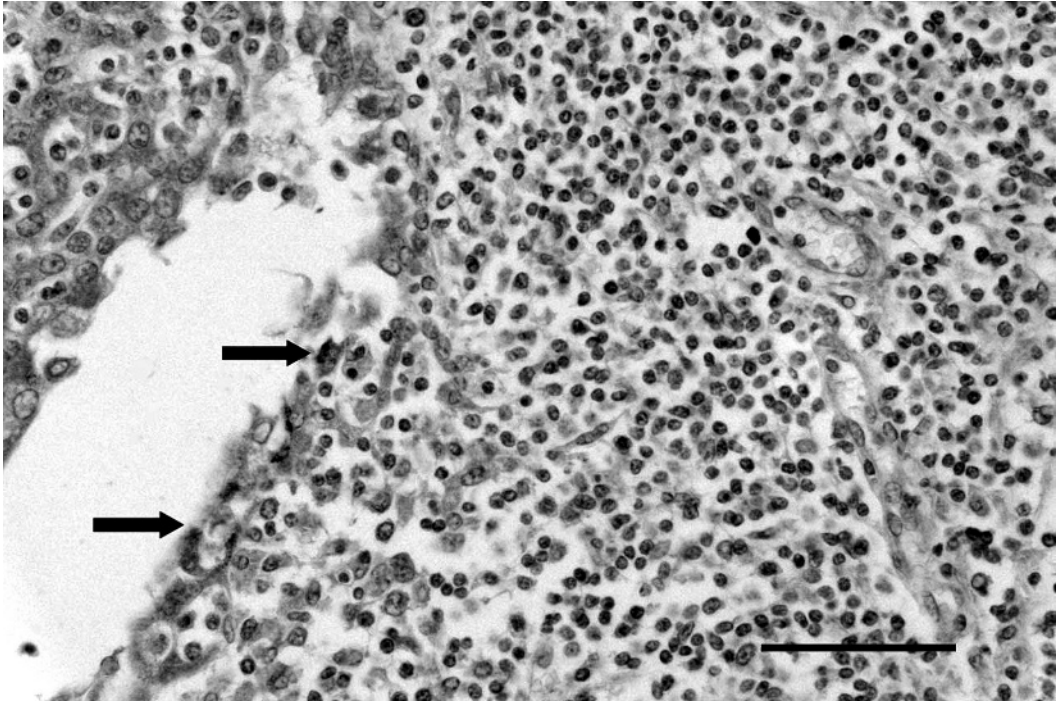


FIGURE 1. Tonsil from a wild boar. Intense immunohistochemical staining for pseudorabies virus (PRV) antigen in the epithelial cells lining the crypts (arrows), scattered lymphoid cells are positively stained. Anti-PRV immunoperoxidase histochemistry, Nova red chromogen, and hematoxylin counterstaining. Bar = 150 μ m.

to be statistically dependent ($P \leq 0.05$) on the presence of PRV antigen.

Both MAbs against PRV (2H6 and 2E12) reacted intensively in positive-control tissues, and equivalent staining was observed when they were used on positive tissues from wild boars. A granular reddish to brownish staining was observed in the cytoplasm of epithelial cells at the bottom of necrotic crypts; lymphoid cells were sometimes stained in follicular centers at the periphery of the lesions (Fig. 1). Nonspecific background staining did not interfere with the interpretation, and staining was never observed in negative-control tissue. Tonsils from 62 animals (41%) were positive for the presence of PRV-antigen; however, viral antigen was rarely detected in lymph nodes from these same animals. Forty-one of 80 serum samples tested (51%) were positive for anti-PRV antibodies. Only 8 of

54 (15%) animals <1 yr old were positive for PRV antigen and only four of 25 (16%) serum samples from these animals were positive for PRV antibodies. In contrast, of 98 wild boars >1 yr of age, 54 were positive for viral antigen (55%) and 37 of 55 (67%) were seropositive. No significant differences between the prevalence of PRV antibody or antigen were detected between males and females or for animals sampled from different areas.

Of the 10 wild boars sampled for molecular biological studies, five tested PCR positive for PRV (Fig. 2). These five PCR-positive wild boars included three animals that tested positive on both ELISA and IHC; one animal that tested positive only by IHC, and one animal that tested positive only by ELISA. Five animals tested negative on PCR and included one IHC and ELISA positive animal, two animals that tested ELISA

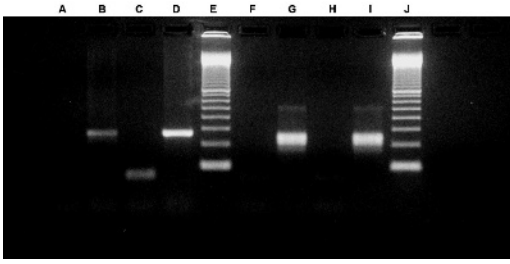


FIGURE 2. Agarose gel electrophoresis of PCR and nested PCR amplification for pseudorabies virus (PRV). Lanes A–D correspond to PCR amplification of a PRV-negative sample field (A), a PRV-positive field sample (B), and negative and positive reaction controls (C and D). Lanes from F to I correspond to nested PCR amplification of a PRV-negative field sample (F), a PRV positive–PRV positive field sample (G), and negative and positive reaction controls (H and I). Lanes E and J, molecular weight marker, 100 bp ladder.

positive, and two animals that tested negative on both IHC and ELISA.

The most significant histopathologic lesion in dogs was a nonsuppurative en-

cephalitis located in the brain stem, mainly near the floor of the fourth ventricle. Cytoplasm of both scattered neurons, and their dendritic and axonal processes, and glial cells stained intensely for PRV by IHC (Fig. 3). The PRV antigen distribution coincided with the location of histopathologic lesions.

DISCUSSION

Immunohistochemistry on paraffin-embedded sections of tonsil proved to be useful for detecting PRV antigens. These results confirmed previous studies using this technique (Grieco et al., 1997) and results were validated by PCR. A high prevalence of antibodies to PRV was detected in this wild boar population. In Italy, prevalence of PRV antibodies in wild boar populations is variable, usually ranging from 20 to 30% (Oggiano et al., 1991; Cordioli et al., 1993). However, in high-

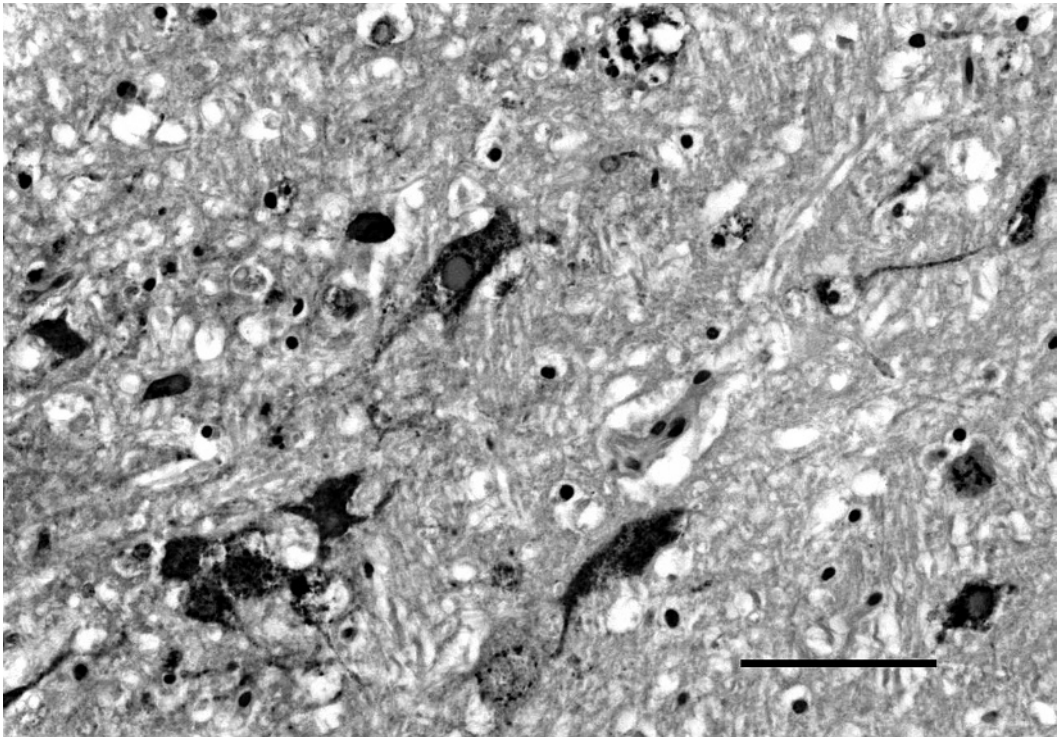


FIGURE 3. Brain stem from a dog. Diffuse pseudorabies virus positivity in neurons; dendritic and axonal processes are intensely stained. Anti-PRV immunoperoxidase histochemistry, Nova red chromogen, and hematoxylin counterstaining. Bar = 100 μ m.

density areas in the United States, antibody prevalence can exceed 50% (Hahn et al., 1997). Furthermore, in this study, seroprevalence increases with age confirming that PRV infection is endemic in the wild boar population in this area (Guberti et al., 2002); this is consistent with other parts of Italy and other European countries (Oggiano et al., 1991; Muller et al., 1998).

The potential impacts of PRV infections on wild boar populations are not known. Infections in wild boar appear to be subclinical, and even during reported outbreaks, mortality ranging from 14% in juveniles to 7.5% in adults has been reported (Gortazar et al., 2002).

Results from IHC demonstrated that a large number of examined animals had viral antigen in tonsil samples, especially adult (≥ 1 yr) wild boars. Although PRV has a predilection for respiratory and nervous tissues, the virus has been isolated from tonsils several months after PRV infection, and PRV DNA has been detected by PCR in the tonsils of experimentally infected pigs 12–16 weeks after inoculation (Galeota et al., 1991). In experimentally infected wild boars PRV was recovered from the tonsils after throat swabs became negative, suggesting the possibility of a carrier state (Tozzini et al., 1982). All these observations confirm the importance that tonsils may have in the pathogenesis of PRV infection in wild boar. Our study suggests that in wild boar this organ may be infected for a long period and could have an important role in viral transmission. The presence of a high percentage of inflammatory alterations in this organ (84% of examined subjects), may indicate a stressed condition that may explain the high percentage of subjects positive for PRV antigen. The absence of systemic changes in these animals could be related to a low pathogenicity of the virus associated with these herds. However, even if the presence of more severe tonsillar changes were significantly correlated to PRV infection, it will be important

to demonstrate the causative role of the virus by its isolation.

Studies on the transmission biology of PRV infection in wild boar indicate that the virus can move from subject to subject by different mechanisms. The shedding of the virus from the respiratory tract occurs during the first 2 wk of acute infection (Hahn et al., 1997) and sexual transmission also has been demonstrated by virus isolation from genital swabs (Romero et al., 1997), and by the demonstration of latent PRV in sacral ganglia of feral swine (Romero et al., 2003). Furthermore, it has been hypothesized that PRV can be transmitted through scavenging the carcass of piglets that die of acute infection (Hahn et al., 1997). Our study confirms the presence of PRV in tissues of infected young and adult animals and this may have relevance to endangered species of wild carnivores such as wild cats (*Felis silvestris*), lynx (*Lynx lynx*), bears (*Ursus arctos*), and particularly wolves (*Canis lupus*), as in some areas of Italy, wild boars represent approximately 50% of the diet of this species (Meriggi et al., 1991). This potential has been indirectly confirmed by the four cases of PRV infection in dogs that were fed PRV-infected meat and had contact with infected wild boar. Additional cases of PRV infection in domestic carnivores due to consumption of PRV-infected meat have previously been reported in other areas in Italy (Capua et al., 1997b).

In conclusion, our data confirm that PRV infection is endemic in the wild boar population in Italy and that this species should be considered an important reservoir of Aujeszky's disease. The existence of a large wild boar population in which PRV infection is endemic should be taken into account during the development and the implementing of eradication programs.

ACKNOWLEDGMENTS

This project was supported by the "Dipartimento Agricoltura e Foreste—Regione Toscana," Florence, Italy.

LITERATURE CITED

- BASCUÑANA, R. C., L. BIÖRNEROT, A. BALLAGI-PORDÁNY, J.-Å. ROBERTSSON, AND S. BELÁK. 1997. Detection of pseudorabies virus genomic sequences in apparently uninfected "single reactor" pigs. *Veterinary Microbiology* 55: 37–47.
- BROWN, T. T., K. O. KWANG, AND F. J. FULLER. 1995. Detection of pseudorabies viral DNA in tonsillar epithelial cells of latently infected pigs. *American Journal of Veterinary Research* 56: 587–594.
- CAPUA, I., C. CASACCIA, G. CALZETTA, AND V. CAPORALE. 1997a. Characterization of Aujeszky disease viruses isolated from domestic animals and from a wild boar (*Sus scrofa*) in Italy between 1972 and 1995. *Veterinary Microbiology* 51: 143–149.
- , R. FICO, M. BANKS, M. TAMBA, AND G. CALZETTA. 1997b. Isolation and characterization of an Aujeszky's disease virus naturally infecting a wild boar (*Sus scrofa*). *Veterinary Microbiology* 55: 141–146.
- CORDIOLI, P., S. CALLEGARI, A. BERLINZANI, E. FONI, P. CANDOTTI, AND G. BARIGAZZI. 1993. Indagine sierologica su cinghiali dell'Appennino Parmense. *Atti Società Italiana delle Scienze Veterinarie* 47: 1065–1068.
- DAVIES, E. B., AND G. W. BERAN. 1980. Spontaneous shedding of pseudorabies virus from clinically recovered postparturient sow. *Journal of American Veterinary Medical Association* 176: 1345–1347.
- GALEOTA-WHEELER, J., AND F. A. OSORIO. 1991. Investigation of sites of pseudorabies virus latency, using polymerase chain reaction. *American Journal of Veterinary Research* 52: 1799–1803.
- GORTAZAR, C., J. VINCENTE, Y. FIERRO, L. LEON, M. J. CUBERO, AND M. GONZALES. 2002. Natural Aujeszky's disease in a Spanish wild boar population. *Annals of the New York Academy of Sciences* 969: 210–212.
- GRIECO, V., D. GELMETTI, G. FINAZZI, E. BROCCHI, AND M. FINAZZI. 1997. Immunohistologic diagnosis of pseudorabies (Aujeszky's disease) using monoclonal antibodies. *Journal of Veterinary Diagnostic Investigation* 9: 326–328.
- GUBERTI, V., G. FERRARI, M. FENATI, M. A. DE MARCO, AND T. PASQUALI. 2002. Pseudorabies in wild boar. Proceedings of the 4th meeting of the European Association of Zoo and Wildlife Veterinarians (EAZWV), Heidelberg, Germany, 8–12 May.
- HAHN, E. C., G. R. PAGE, P. S. HAHN, K. D. GILLIS, C. ROMERO, J. A. ANNELLI, AND E. P. J. GIBBS. 1997. Mechanisms of transmission of Aujeszky's disease virus originating from feral swine in the USA. *Veterinary Microbiology* 55: 123–130.
- HOWARTH, J. A. 1969. A serologic study of pseudorabies in swine. *Journal of the American Veterinary Medical Association* 154: 1583–1589.
- KLUGE, J. P., W. BERAN, H. T. HILL, AND K. B. PLATT. 1999. Pseudorabies (Aujeszky's disease). In *Diseases of swine*, 8th Edition, B. E. Straw, S. D'Allaire, W. L. Mengeling and D. J. Taylor (eds.). Iowa State University Press, Ames, Iowa, pp. 233–246.
- MERICGI, A., P. ROSA, A. BRONGI, AND A. MATTEUCCI. 1991. Habitat use and diet of the wolf in Northern Italy. *Acta Theriologica* 36: 141–151.
- MULLER, T., J. TEUFFERT, K. ZIEDLER, C. POSSARDT, M. KRAMER, C. STAUBACH, AND F. J. CONRATHS. 1998. Pseudorabies in the European wild boar from eastern Germany. *Journal of Wildlife Diseases* 34: 251–258.
- NETTLES, V. F., AND G. A. ERICKSON. 1984. Pseudorabies in wild swine. In *Proceedings of the 88th Annual Meeting of the United States Animal Health Association*, Fort Worth, Texas, 21–26 October, pp. 505–506.
- OGGIANO, A., C. PATA, A. LADDOMADA, AND A. CACCIA. 1991. Epidemiological survey of Aujeszky's disease in wild boars in Sardinia. *Atti Società Italiana delle Scienze Veterinarie*, 1157–1161.
- OSLAGE, U., J. DAHLE, T. MULLER, M. KRAMER, D. BIEREIR, AND B. LIESS. 1994. Antibody prevalence of hog cholera, Aujeszky's disease and the porcine reproductive and respiratory syndrome virus in wild boar in the Federal States Sachsen Anhalt and Brandenburg (Germany). *Deutsche Tierärztliche Wochenschrift* 101: 33–38.
- PIRTLE, E. C., J. M. SACKS, V. F. NETTLES, AND E. A. ROLLOR. 1989. Prevalence and transmission of pseudorabies virus in an isolated population of feral swine. *Journal of Wildlife Diseases* 25: 605–607.
- ROMERO, C. H., P. N. MEADE, J. SANTAGATA, K. GIBBS, G. LOLLIS, E. C. HAHN, AND E. P. J. GIBBS. 1997. Genital infection and transmission of pseudorabies virus in feral swine in Florida, USA. *Veterinary Microbiology* 55: 131–139.
- , ———, B. L. HOMER, J. E. SHULTZ, AND G. LOLLIS. 2003. Potential sites of virus latency associated with indigenous pseudorabies virus in feral swine. *Journal of Wildlife Diseases* 39: 567–575.
- TOZZINI, F., A. POLI, AND G. DELLA CROCE. 1982. Experimental infection of European wild swine (*Sus scrofa*) with pseudorabies virus. *Journal of Wildlife Diseases* 18: 425–428.
- WITTMANN, G., V. OHLINGER, AND H. J. RZIHA. 1983. Occurrence and reactivation of latent Aujeszky's disease virus following challenge in previously vaccinated pigs. *Archives of Virology* 75: 29–41.

Received for publication 3 May 2005.