



MALIGNANT CATARRHAL FEVER IN FREE-RANGING CERVIDS ASSOCIATED WITH OVHV-2 AND CPHV-2 DNA

Authors: Vikøren, Turid, Li, Hong, Lillehaug, Atle, Monceyron Jonassen, Christine, Böckerman, Inger, et al.

Source: Journal of Wildlife Diseases, 42(4) : 797-807

Published By: Wildlife Disease Association

URL: <https://doi.org/10.7589/0090-3558-42.4.797>

BioOne Complete (complete.BioOne.org) is a full-text database of 200 subscribed and open-access titles in the biological, ecological, and environmental sciences published by nonprofit societies, associations, museums, institutions, and presses.

Your use of this PDF, the BioOne Complete website, and all posted and associated content indicates your acceptance of BioOne's Terms of Use, available at www.bioone.org/terms-of-use.

Usage of BioOne Complete content is strictly limited to personal, educational, and non - commercial use. Commercial inquiries or rights and permissions requests should be directed to the individual publisher as copyright holder.

BioOne sees sustainable scholarly publishing as an inherently collaborative enterprise connecting authors, nonprofit publishers, academic institutions, research libraries, and research funders in the common goal of maximizing access to critical research.

MALIGNANT CATARRHAL FEVER IN FREE-RANGING CERVIDS ASSOCIATED WITH OVHV-2 AND CPHV-2 DNA

Turid Vikøren,^{1,5} Hong Li,² Atle Lillehaug,¹ Christine Monceyron Jonassen,³ Inger Böckerman,⁴ and Kjell Handeland¹

¹ Section for Wildlife Diseases, National Veterinary Institute, PO Box 8156 Dep., N-0033 Oslo, Norway

² Animal Disease Research Unit, USDA-ARS, and the Department of Veterinary Microbiology and Pathology, Washington State University, Pullman, Washington 99164, USA

³ Section for Virology and Serology, National Veterinary Institute, PO Box 8156 Dep., N-0033 Oslo, Norway

⁴ Section for Immunoprophylaxis, National Veterinary Institute, PO Box 8156 Dep., N-0033 Oslo, Norway

⁵ Corresponding author (e-mail: turid.vikoren@vetinst.no)

ABSTRACT: Pathologic lesions were summarized in 18 free-ranging cervids (15 moose [*Alces alces*], two roe deer [*Capreolus capreolus*], and one red deer [*Cervus elaphus*]) diagnosed with malignant catarrhal fever (MCF) after examination at the National Veterinary Institute, Oslo 1982–2005. Eye lesions (conjunctivitis, corneal opacity, fibrin clots in the anterior eye chamber) were the most frequent gross finding. Erosive-ulcerative mucosal lesions in the nose and mouth were also commonly found. Histopathology revealed a nonpurulent vasculitis and perivasculitis in the central nervous system (CNS) typical of MCF in 16 of the cases. The diagnosis in the remaining two animals was based upon histologic eye lesions consistent with MCF (CNS not available for examination). Polymerase chain reaction was run on samples from 15 individuals for evidence of MCF-virus DNA, and ovine herpesvirus-2 (OvHV-2) DNA was detected in five moose, one roe deer, and one red deer, and caprine herpesvirus-2 (CpHV-2) DNA was detected in two moose and one roe deer. Sera from 1,000 free-ranging cervids were tested for specific antibodies to MCF-associated viruses (MCFV) by competitive inhibition enzyme-linked immunosorbent assay. The seroprevalences were: red deer 5%, reindeer (*Rangifer tarandus*) 4%, roe deer 2%, and moose 0.4% ($n=250$ for all four species). The results indicate that sheep and goat MCFV may cause serious disease in wild moose, roe deer, and red deer. The seropositive cervids most likely represent individuals infected with either OvHV-2 or CpHV-2, but may also reflect infections with other related MCFV.

Key words: Cervids, CpHV-2, malignant catarrhal fever, moose, OvHV-2, red deer, roe deer.

INTRODUCTION

Malignant catarrhal fever (MCF) is a pansystemic often fatal viral disease primarily affecting both domestic and wild ruminants. The disease is characterized by lymphoproliferation, vasculitis, and erosive-ulcerative lesions in the mucosa and skin (Plowright, 1990; Barker et al., 1993; Heuschele and Reid, 2001). Malignant catarrhal fever is caused by several viruses within a group of closely related ruminant rhadinoviruses (*Gammaherpesvirinae*). This group currently contains nine members, four of which have been found to cause clinical disease (MCF) (Li et al., 2003a). The MCF-associated viruses (MCFV) occur endemically in latently infected carrier species that spread infection to MCFV-susceptible species. In-

cluded in this group are the well-known alcelaphine herpesvirus 1 (AlHV-1) (Plowright et al., 1960) and ovine herpesvirus 2 (OvHV-2) (Baxter et al., 1993), endemic in wildebeest (*Connochaetes* spp.) and domestic sheep, respectively, and two further viruses identified in later years, caprine herpesvirus 2 (CpHV-2) endemic in domestic goats (Li et al., 2001a), and a virus of unknown origin causing MCF in white-tailed deer (*Odocoileus virginianus*) (MCFV-WTD) (Li et al., 2000; Kleiboeker et al., 2002). Alcelaphine herpesvirus 1 is known to cause the classic “African” form of MCF, and OvHV-2 causes the sheep-associated MCF that occurs worldwide in a range of ruminants (Plowright, 1990; Heuschele and Reid, 2001), whereas CpHV-2 has been found to cause disease in sika deer (*Cervus nippon*) (Crawford et

al., 2002; Keel et al., 2003) and white-tailed deer (Li et al., 2003b).

Malignant catarrhal fever has been reported in many species within *Cervidae* (Heuschele and Reid, 2001) including all of the four cervid species that are prevalent in natural populations in Norway: red deer (*Cervus elaphus*) (Reid et al., 1979), moose (*Alces alces*) (Andersson 1953; Altmann et al., 1973; Williams et al., 1984; Warsame and Steen 1989; Hänichen et al., 1998), roe deer (*Capreolus capreolus*) (Hänichen and Mannl 1984), and reindeer (*Rangifer tarandus*) (Altmann et al., 1973; Li et al., 1999). However, with the exception of Warsame and Steen (1989), reporting MCF in two free-ranging moose from Sweden, all reports comprise captive animals held in zoos, wildlife parks, or deer farms. In Norway, MCF is well known as a sporadic disease in domestic cattle, and the first case of MCF in cervids was diagnosed at the National Veterinary Institute (NVI) in a free-ranging moose in 1976. Since then, we have diagnosed another 15 cases in moose and in later years a few cases in free-ranging red deer and roe deer. The diagnoses were based upon pathologic findings that included the demonstration of the typical vasculitis and perivasculitis in the central nervous system (CNS) (Barker et al., 1993). We have also experienced two MCF outbreaks in semi-domesticated reindeer stalled in a sheep house for research purposes.

Our objectives were 1) to summarize pathologic lesions seen in free-ranging Norwegian cervids with the diagnosis MCF, 2) by means of polymerase chain reaction (PCR) to identify causative MCFV in tissues from these cases, and 3) to determine the prevalence of antibodies against MCFV in Norwegian cervids sampled during hunting.

MATERIALS AND METHODS

The study included 18 free-ranging cervids (15 moose, two roe deer, and one red deer), which received a histologic based MCF di-

agnosis after examination at the NVI, Oslo, during 1982–2005. The total number of material (carcass, head, or brain) from cervids submitted to NVI 1982–2005 was 765 (400 moose, 340 roe deer, and 25 red deer). Detailed information about individual MCF cases and the materials received for examination are shown in Table 1 and Figure 1. The materials comprised four complete carcasses; most frequently only the head was submitted, and the CNS was available for examination from all animals with the exception of two moose (Table 1: M3 and M9).

Fresh tissue specimens were fixed in 10% neutral buffered formalin and, along with field-fixed specimens, embedded in paraffin, sectioned at 5 μ m, and stained with hematoxylin and eosin (H&E) for histologic examination (Culling et al., 1985). Standard bacteriologic examination on calf blood agar plates was carried out on the following samples: liver from six moose and one roe deer, lungs from four moose and two roe deer, and brain from two moose. The plates were incubated aerobically at 37 C and examined after 24–48 hr.

Polymerase chain reaction was run on paraffin-embedded, formalin-fixed tissues from 11 of the animals at the Animal Disease Research Unit, USDA-ARS (Table 2). Thirty-one formalin-fixed, paraffin-embedded tissue blocks were examined by both OvHV-2-specific PCR and CpHV-2-specific PCR. The DNA from all tissue that was OvHV-2 PCR negative was subjected to amplification by PCR with degenerate primer targeting a portion of herpesviral DNA polymerase gene.

The detailed procedure for DNA extraction from the formalin-fixed, paraffin-embedded tissues has been described previously (Crawford et al., 1999). Briefly, five 8- μ m-thick sections were cut from each tissue block (a new disposable microtome blade was used for each block). Defined MCF negative deer tissue blocks were also used for monitoring contaminations during the sample preparation. The sections were deparaffinized, washed, and dried. The samples were then suspended in lysis buffer. Deoxyribonucleic acid was purified from sample lysates by phenol/chloroform extraction and ethanol precipitation. Purified DNA was then dissolved in water and quantified by OD₂₆₀. The amount of target DNA used in all PCRs was about 0.5 μ g per reaction, which was reduced from the previous protocols. The OvHV-2-specific PCR was based on the primers initially developed by Baxter et al. (1993), targeting a region of open reading frame 75, and the detailed procedure was carried out as described by Li et al. (1995).

TABLE 1. Free-ranging moose (M), roe deer (R), and red deer (D) diagnosed with MCF after pathologic examination at the National Veterinary Institute, Oslo, Norway, 1982–2005.

Animal	Sex	Age ^a	Condition	Date	Killed or found dead	Materials received for laboratory examination		
						Carcass	Head	Other samples
M1	F	7 yr	Poor	Nov 82	Killed		×	
M2	M	1 yr	Poor	Jun 83	Killed		×	
M3	M	Calf	?	Sep 83	Killed			Eyes, liver, skin, penis
M4	M	2.5 yr	Moderate	Nov 89	Dead		×	Heart, lungs, liver, kidney
M5	F	ad	Good	Nov 93	Killed		×	
M6	M	4 yr	Poor	Dec 93	Killed			Brain, eyes, heart, lungs ^b
M7	F	ad	Moderate	Dec 96	Dead		×	
M8	M	ad	Moderate	Oct 97	Dead	×		
M9	F	ad	Poor	May 02	Killed			Eyes, liver, kidney ^b
M10	M	ad	Good	Jul 03	Dead			Spinal cord, heart, lungs, liver, kidney, small intestine ^b
M11	M	ad	Good	Sep 04	Killed		×	Heart, lungs, liver, kidney
M12	F	ad	Good	Oct 04	Dead			Brain, eyes, nose, mouth ^b
M13	?	Calf	Good	Oct 04	Killed		×	Spinal cord
M14	M	ad	Poor	Apr 05	Killed	×		
M15	F	ad	Poor	Jul 05	Killed		×	
R1	M	1 yr	Poor	May 00	Dead	×		
R2	M	Calf	Good	Nov 04	Killed	×		
D1	F	ad	Good	Nov 01	Killed		×	

^a Individuals with exact age have been age-determined by tooth replacement or examination of annuli in tooth cementum. ad = adult, yr = year(s).

^b All materials were formalin fixed.

^c Carcass without the gastrointestinal tract.

Methods for both CpHV-2-specific PCR and degenerate PCR, amplifying a region of herpesviral DNA polymerase gene (open reading frame 9), have also been described previously (Van Devanter et al., 1996; Li et al., 2001a).

Additionally, frozen, nonfixed tissues from another four animals were examined by both OvHV-2-specific PCR and a generic rhadinovirus PCR at the Section of Virology and Serology, NVI (Table 3). DNA from the samples was isolated with DNeasy Tissue kit (Qiagen Nordic, Oslo, Norway) according to the manufacturer's instructions. A single PCR, specific for OvHV-2, was performed using the outer primer set (556/755) of the protocol described by Baxter et al. (1993). The PCR was performed with the use of HotStar Taq DNA polymerase (Qiagen), with a final concentration of Mg²⁺ of 1.5 mM. Amplification consisted of an initial 15-min step at 95 C, followed by 42 cycles with the following conditions: 94 C for 50 s, 60 C for 15 s, and 72 C for 60 s. A final elongation step at 72 C was performed, followed by chilling to 4 C. Another PCR was performed on the samples, aimed at detecting a wider range of rhadino-

viruses, using partly degenerated primers designed in the polymerase gene (RHV-1: 5'-TGT ACC CCA GCA TYA TCC AGG C, and RHV-2: 5': TTG ATR GCC AGC TGC TGC TT). The PCR was performed as above, but with an annealing temperature of 55 C instead of 60 C in the cycling conditions. Sequencing was performed on the purified PCR products, using the ABI PRISM BigDye Terminator Cycle Sequencing Ready Reaction kit v3.1 (Applied Biosystems Inc., Foster City, California, USA) according to the manufacturer's instructions and analyzed on an ABI PRISM-Avant Genetic Analyser (Applied Biosystems). Software used for sequence analysis were Sequencher version 4.1.4 (Gene Codes Corporation, Ann Arbor, Michigan, USA, <http://www.genecodes.com>) and Fasta similarity search (Fasta, European Bioinformatics Institute, Cambridge, UK, <http://www.ebi.ac.uk/>).

One thousand serum samples, 250 each from free-ranging moose, red deer, roe deer, and wild reindeer, were tested for antibodies against MCFV. Samples were selected among 4,339 sera available at our serum bank for wild cervids (Vikøren et al., 2004). The majority of the samples were from adult animals ($n=823$),

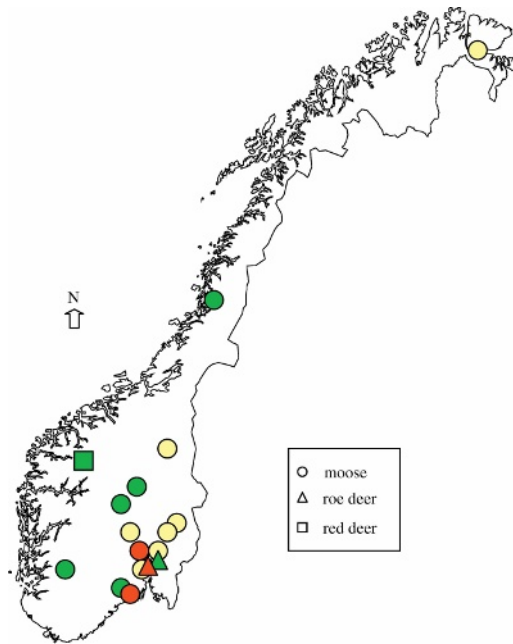


FIGURE 1. Map of Norway showing the locations of the moose, roe deer, and red deer with malignant catarrhal fever (MCF), 1982–2005. Green = OvHV-2 infection, red = CpHV-2 infection, yellow = unknown MCF-virus infection.

whereas 121 were yearlings, 52 were calves, and four were of unknown age. Additionally, serum from 16 adult captive red deer kept at the Norwegian Red Deer Centre at Svanøy, western Norway (61°30'N, 05°05'E) were examined. This farm also keeps sheep, which are held on separate grazing lands.

The sera were tested for specific antibodies to MCFV by competitive inhibition enzyme-linked immunosorbent assay (cELISA) (Li et al., 2001b). The assay was developed using the monoclonal antibody (15-A) against an epitope conserved among all known members of the MCFV group of ruminant rhadinoviruses.

TABLE 2. Results from PCR examination for OvHV-2 DNA and CpHV-2 DNA in formalin-fixed, paraffin-embedded tissues from free-ranging moose (M), roe deer (R), and red deer (D) diagnosed with MCF after pathologic examination.

Animal	Tissues							Final results
	Brain	Eye	Lung	Heart	Liver	Kidney	Lymph node	
M2	Neg/neg ^{a,b}	Pos /neg	— ^c	—	—	—	—	OvHV-2
M3	—	—	—	—	Pos /neg	—	—	OvHV-2
M4	Neg/neg	Neg/neg	Neg/neg	Neg/neg	Neg/neg	Neg/neg	—	Neg
M5	Neg/neg	Neg/neg	—	—	—	—	Neg/neg	Neg
M6	Neg/neg	Neg/neg	Neg/neg	Neg/neg	—	—	—	Neg
M7	Neg/ pos	—	—	—	—	—	—	CpHV-2
M8	Neg/neg	—	Neg/neg	Neg/neg	Neg/neg	—	—	Neg
M9	—	Neg/neg	—	—	Neg/neg	Neg/neg	—	Neg
M10	—	—	—	—	—	—	Pos /neg	OvHV-2
R1	Neg/neg	—	Neg/neg	Neg/neg	Pos /neg	Neg/neg	—	OvHV-2
D1	—	—	—	—	—	—	Pos /neg	OvHV-2

^a Pos=positive; neg = negative.

^b OvHV-2 DNA/CpHV-2 DNA.

^c — = not examined.

TABLE 3. Results from PCR examination for OvHV-2 DNA and rhadinovirus DNA in nonfixed, frozen tissues from free-ranging moose (M), and roe deer (R), diagnosed with MCF after pathologic examination. Rhadinovirus types were confirmed by sequencing, and are indicated as final results.

Animal	Tissues			Final results
	Lymph node	Spleen	Brain	
M11	Neg/pos ^{a,b}	-/- ^c	-/-	CpHV-2
M14	Pos/-	Neg/-	Pos/-	OvHV-2
M15	Pos/-	-/-	Pos/-	OvHV-2
R2	Neg/pos	Neg/pos	-/-	CpHV-2

^a Pos=positive; neg = negative.

^b OvHV-2 DNA/rhadinovirus DNA.

^c - = not examined.

These viruses include ALHV-1, ALHV-2, OvHV-2, CpHV-2, the virus of unknown origin causing MCF in white-tailed deer, and the MCF viruses carried by musk ox, ibex, and oryx (Li et al., 2003a). Sera were scored based on their ability to inhibit binding of 15-A monoclonal antibody to ALHV-1 antigens pre-coated onto microtiter plates. Sera that inhibited binding of the monoclonal antibody 25% greater than or equal to the negative control sera were considered positive (Li et al., 2001b).

RESULTS

Clinical signs, seen in animals found alive, included abnormal behavior, apathy, incoordination, circling, staggered gait, convulsions, and impaired vision. Local veterinary surgeons performed field post-mortems in eight cases and, in six of them (moose and red deer), one or more of the following gross findings were reported: corneal opacity, fibrin clots in the anterior eye chamber, erosions in the mouth and nose, purulent exudates in the respiratory tract and vagina, moderately enlarged lymph nodes, hemorrhagic mucosa in the small intestine, mummified fetuses, and thickening of the skin around the nose, the eyes and on the prepuce.

At the laboratory, necropsy of one of the moose carcasses (M14) revealed alopecia and moderate crusting dermatitis primarily involving the legs, ears, and ventral thorax. Lymph nodes of the trunk were generally enlarged. Both eyes had fibrinopurulent conjunctivitis, peripheral corneal

opacity, and small fibrin clots in the anterior chamber (Fig. 2). There was bilateral purulent nasal discharge, and the mucosa of the nose, pharynx, and trachea were hyperemic and edematous with erosions and pseudomembranes. Large masses of fibrin and pseudomembranes were found in the bronchi of both lungs. In the oral cavity, multiple erosions were seen, particularly on the mucosal surface of the lips, and small longitudinal erosions were present in the anterior part of the esophagus (the gastrointestinal tract had been removed prior to submission). On the surface of the kidneys, small grayish foci were seen. The second moose carcass

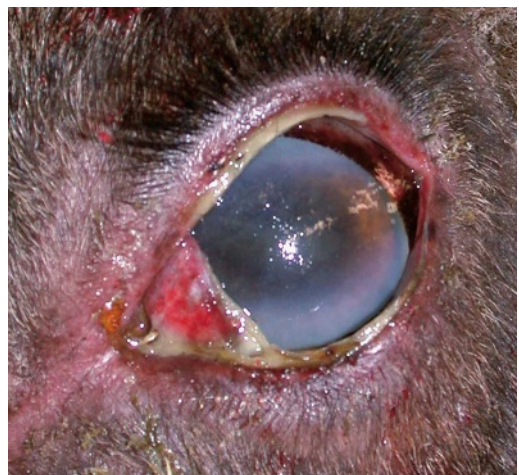

FIGURE 2. Severe fibrinopurulent conjunctivitis and peripheral corneal opacity in a moose (M14) with MCF.

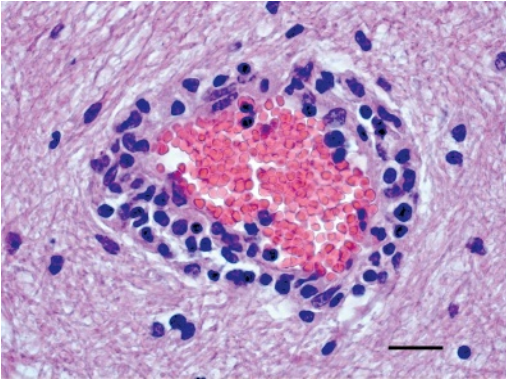


FIGURE 3. Vasculitis and perivascular lymphoid cell infiltrates in the brain of a roe deer (R2) with MCF (CpHV-2 positive). H&E. Bar = 20 μ m.

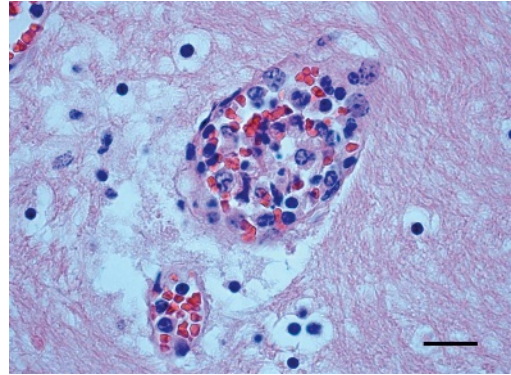


FIGURE 4. Necrotizing and obliterating vasculitis in the brain of a moose (M11) with MCF (CpHV-2 positive). The intima shows a marked hypertrophy of the endothelial cells. H&E. Bar = 20 μ m.

(M8) necropsied at the laboratory was extremely decomposed and no specific gross lesions were noted. In eight moose from which the head was submitted, eye lesions (hyperemic and swollen conjunctivas, corneal opacity and edema, and fibrin clots in the anterior chamber) were common findings, and less frequently purulent nasal discharge, erosions in the nasal mucosa, wet meninges with some cloudiness in the sulci, and edematous lymph nodes.

Examination of the red deer head revealed edematous and diffusely opaque corneas, which were attached to iris with an opaque, fibrin-like material. In the oral cavity, multiple ulcerations were seen on the tongue and on the tips of the buccal papillae. Necropsy of the two roe deer carcasses revealed only nonspecific findings.

In 16 animals, vasculitis and perivasculitis characterized by infiltration of predominantly lymphoid cells, occurred in the parenchyma and leptomeninges of the brain and spinal cord (in two moose, M3 and 9, the CNS was not examined). The vasculitis most often affected the adventitia and media of medium-sized vessels (Fig. 3). However, infiltration of the whole vessel wall and obliteration of the lumen was also seen (Fig. 4). The intima often

showed a marked hypertrophy of the endothelial cells (Fig. 4). Perivascular edema and hemorrhages were common, and some vessels contained thrombi. Multifocal infiltrations of predominantly mononuclear cells occurred in the choroid plexus. Some of the animals also showed focal degenerative changes in nervous parenchyma, and gliosis.

Histologic eye lesions were found in the red deer, one roe deer (R2; R1 was not examined), and in 11 of 12 moose (no lesions detected in M11). In the red deer and moose, lesions were keratitis and uveitis of variable severity. Corneal lesions included epithelial hyperplasia and edema, increased vascularity, and infiltration of predominantly lymphoid cells in the stroma (Fig. 5). Not all animals had prominent keratitis, in some cases corneal lesions were restricted to moderate mononuclear cell accumulation in the limbus. The anterior eye chamber frequently contained fibrin mingled with inflammatory cells, and in some animals the iris was adherent to cornea. The iris, ciliary body, filtration angle, limbus, and conjunctiva showed edema and infiltrates of mononuclear cells to a variable degree. Some of the moose had vascular and perivascular mononuclear infiltrations in the retina, choroid, and sclera. In the roe deer (R2), eye lesions were confined to moderate

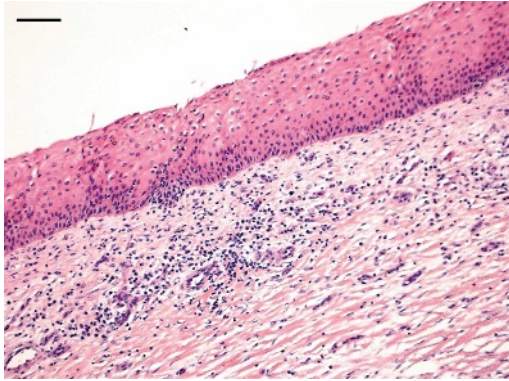


FIGURE 5. Severe keratitis in a moose (M6) with MCF. The corneal stroma shows edema, increased vascularity, and infiltration by predominantly mononuclear cells. Hyperplasia and some infiltration of inflammatory cells can be seen in the corneal epithelium. H&E. Bar = 100 μ m.

mononuclear vasculitis and perivasculitis in iris, choroids, and retina, and edema and cell infiltration in the limbus.

Histologic lesions found in other organs included vascular and perivascular infiltrates of lymphoid cells in the lungs, and multifocal lymphocytic cell accumulations in the interstitium of the kidneys and in the portal triads of the liver. In small intestine, some sloughing of the villi with hemorrhages and diffuse infiltration of inflammatory cells in the lamina propria were seen in the moose and roe deer. Lymph nodes had edema and marked lymphoblastic proliferation in the parafollicular cortex and medullary sinuses, with little development of lymphoid follicles. In skin (M14), focal infiltrates dominated by mononuclear cells, were seen in the epidermis, dermis, and subcutis (perivascular). In some areas, the whole thickness of the epidermis and the superficial portion of the dermis were necrotic. In the epidermis, areas of hyperkeratosis, parakeratosis, and acanthosis were also seen.

Bacteriologic examination isolated *Escherichia coli* in one lung sample and one liver sample from two different moose, and in lungs and liver of a roe deer (R2).

The remaining samples had growth of an unidentified mixture of bacteria.

Of 11 animals tested for the presence of MCFV DNA in formalin-fixed, paraffin-embedded tissues, three moose, one roe deer, and one red deer were positive for OvHV-2 DNA, and one moose was positive for CpHV-2 DNA (Table 2). No signal was detected by the degenerate PCR in any of the tissues examined. Of the four animals in which PCR were run on frozen specimens, OvHV-2 DNA was detected in two moose (Table 3). One moose and one roe deer were positive in the generic rhadinovirus PCR, and sequence analyses of the PCR products from these two animals showed that they shared more than 99.5% nucleotide sequence identity with known CpHV-2 sequence in the polymerase gene, indicating that they were infected with CpHV-2 (Table 3). In summary, of 15 animals tested, OvHV-2 DNA was detected in five moose, one roe deer, and one red deer, whereas CpHV-2 DNA was found in two moose and one roe deer.

Antibodies against MCFV were found in 13 red deer (5%), nine reindeer (4%), five roe deer (2%), and one moose (0.4%). The red deer sera originated from six municipalities; five in western Norway, in which the seroprevalence ranged from 4 to 9%, and one in the southeastern part of the country, where no seropositive red deer was found among 27 examined. One (6%) of 16 captive red deer tested was seropositive.

DISCUSSION

This study confirmed that MCF occurs as a clinical disease in free-ranging moose, roe deer, and red deer in Norway. It is believed to be the first report of this condition in natural populations of both roe deer and red deer, as well as of the identification of causative viruses involved in MCF in free-ranging European cervids. The PCR results showed that the disease may be associated with both OvHV-2 and

CpHV-2 DNA in moose and roe deer, and with OvHV-2 DNA in red deer. Evidence of OvHV-2 infection in red deer by use of PCR has been reported earlier in two animals suffering from MCF in a zoo in Germany (Hänichen et al., 1998). CpHV-2 has been identified as a pathogen for sika deer (Crawford et al., 2002; Keel et al., 2003) and white-tailed deer (Li et al., 2003b) in the USA. We detected CpHV-2 DNA in two moose and one roe deer that were negative for OvHV-2 DNA. The CpHV-2 positive animals had prominent clinical symptoms of MCF seen as abnormal behavior, apathy, and incoordination, and the histologic lesions in the brain of these animals was typical of MCF (Figs. 3 and 4). These results strongly indicate that CpHV-2 may be the cause of MCF in free-ranging moose and roe deer. Both a chronic form of MCF with weight loss, crusting dermatitis, and alopecia, and an acute form with seizures, have been described in CpHV-2-infected sika deer (Crawford et al., 2002; Keel et al., 2003). In white-tailed deer, CpHV-2 infection has been associated with a subacute condition, causing alopecia and weight loss (Li et al., 2003b). In our study, the CpHV-2 positive animals had no (roe deer) or few gross lesions (moose: moderate erosive stomatitis/rhinitis), which indicate that they suffered of an acute form of MCF.

The red deer, two roe deer, and 13 of the 15 examined moose had nonpurulent vasculitis and perivasculitis in the CNS typical of MCF (Barker et al., 1993). In the remaining two moose, the CNS was not examined, but both had histologic eye lesions consistent with MCF. Because few whole carcasses were examined, the overall picture of gross lesions could not be fully elucidated in this study. Lesions in the eye and the mucosa of the mouth and nose seem to be common findings in moose and red deer suffering from MCF. The variability in severity and distribution of the lesions found in individual moose presumably reflects an acute or subacute course of disease. No

MCF specific gross lesions were found in the two roe deer carcasses examined, indicating a peracute/acute course of disease. Reid et al. (1986) found that roe deer inoculated with cells originating from MCFV-infected red deer developed typical MCF, but gave no description of the lesions. The only description of natural MCF infection in roe deer is given by Hänichen and Mannl (1984), reporting MCF in two fenced roe deer. One of these had gross lesions similar to those found in moose and red deer in the present study, whereas the other roe deer had signs of catarrhal abomasitis and enteritis. Thus, there also seems to be individual variation in roe deer during the course of the disease, and in the associated lesions.

The PCR results clearly indicated infections of OvHV-2 and CpHV-2 origin in the cervids in the present study, suggesting both sheep and goat as sources of infection. The sheep-associated MCF cases in free-ranging cervids were scattered throughout Norway (Fig. 1). Sheep farming is common in most parts of the country (Statistics Norway, 2005) and sheep and cervids often share pastures in the woods and mountains during summer. Goat farming is not so common and far less widespread: it is mainly located in the western and northern part of the country (Statistics Norway, 2005). The three CpHV-2 positive cervids all came from municipalities in the eastern part of Norway (Fig. 1), where there are no registered goat farms. However, the moose is not a stationary species, and reported moose might have been infected in areas distant from the locations in which they were found. Another explanation might be that species other than the goat, for example, the cervid species themselves, might carry CpHV-2 and be the source of infection. Li et al. (2003b) found CpHV-2 DNA in peripheral blood leukocytes from two healthy farmed white-tailed deer, which indicates a subclinical or latent infection in these individuals. Persistent MCFV infection has also been demon-

strated in cattle and farmed deer with no evidence of MCF disease, as well as in recovered cattle (O'Toole et al., 1997; Tham, 1997).

The PCR examination of formalin-fixed, paraffin-embedded tissues failed to demonstrate OvHV-2 and CpHV-2 DNA in five out of 11 animals tested. The reason for the failure is not clear. Possible explanations include: 1) low level of viral DNA in tissues of affected animal; or 2) prolonged fixation of the tissues in formalin. It is still not known whether the levels of OvHV-2 DNA in tissues of affected cervids are the same as the levels in cattle or bison; virtually all formalin-fixed, paraffin-embedded tissue samples from these species yielded positive signals by PCR, despite the fact that formalin fixation of tissues can significantly reduce test sensitivity (Crawford et al., 1999). The PCR failure to amplify OvHV-2 DNA in formalin-fixed tissues from cervids with suspect clinical MCF has been previously reported (Hänichen et al., 1998; Li et al., 1999). Considering that the histologic lesions in these five moose were in concordance with those from individuals found positive for OvHV-2 or CpHV-2 DNA, it seems unlikely that these five are true negatives, unless the animals were infected with another so-far-unrecognized MCF-virus.

A low prevalence (0.4–5%) of seropositive animals to MCFV was found in the four species examined, with the highest seroprevalence occurring in red deer. This result is similar to other serosurveys in these species (Li et al., 1996; Frölich et al. 1998; Zarnke et al., 2002). Two of these studies (Li et al., 1996; Frölich et al., 1998) used the originally developed cELISA method (Li et al., 1994) and Zarnke et al. (2002) used the same improved cELISA method as this study (Li et al., 2001b). The seroprevalences found in wild reindeer and moose in Norway were almost identical to those found in these two species in Alaska (4 and 1%, respectively) (Zarnke et al., 2002). In

a survey from Germany, no seropositive animals were found among 253 wild roe deer and 22 wild red deer tested (Frölich et al., 1998). A more heterogeneous picture in prevalence has been found in North American elk. A prevalence of 9% was found in a total of 323 free-ranging elk from five different states in the US, and the authors reported that there was no apparent difference in seroprevalence between the states of origin (Li et al., 1996). Zarnke et al. (2002) found discrepancy in prevalence between two elk populations in Alaska; one showed 35% seropositivity amongst 40 tested whilst the other population had no positive animals among the 11 examined. We tested red deer from six municipalities in which the seroprevalence ranged from 0 to 9%. Sheep farms are very common in western Norway where all the seropositive red deer were found, enabling good opportunities for virus transmission to red deer.

Our serologic findings support the conclusions of Li et al. (1996) that a significant number of nonlethal MCFV infections occur among clinically susceptible cervids. However, the low seroprevalence found in moose and roe deer indicate a more likely lethal outcome of a MCFV infection in these two species, as compared to red deer and reindeer. Whether the seropositive cervids reflect a subclinical infection, or represent individuals that have recovered from clinical MCF, is an open question. We found one seropositive captive red deer, which, according to the history of the owner, is not likely to have suffered clinical MCF. This supports the suggestion that a MCFV infection can be subclinical in red deer. An interesting question that needs further research is whether cervids themselves may constitute a primary source of MCFV infection.

ACKNOWLEDGMENTS

Financial support was provided by the Directorate for Nature Management through the funding of HOP (National Health Surveil-

lance Program for Cervids), and by USDA-Agricultural Research Service CWU 5348-32000-018-00D. The authors are very grateful to the local veterinarians and wildlife management authorities for submission of specimens, and to Vebjørn Veiberg at the Norwegian Red Deer Centre for collecting serum samples from captive red deer. We would also like to thank Lori Fuller and Janice Keller for their technical assistance.

LITERATURE CITED

- ALTMANN, D., H. KRONBERGER, AND K. F. SCHÜPPEL. 1973. Bösartiges Katarrhalfieber (*Coryza Gangraenosa*) bei zwei Elchen, zwei Rentieren und einer Hausziege in Thüringer Zoopark Erfurt. Verhandlungsbericht des Internationalen Symposium über die Erkrankungen der Zootiere 15: 41–49.
- ANDERSSON, P. 1953. Ett fall av elakartad katarralfieber hos älg. (A case of malignant catarrhal fever in moose.) Nordisk Veterinärmedicin 5: 847–854 (In Swedish).
- BARKER, I. K., A. A. VAN DREUMEL, AND N. PALMER. 1993. Malignant catarrhal fever. In Pathology of domestic animals, Vol. 2, 4th Edition, K. V. F. Jubb, P. C. Kennedy and N. Palmer (eds.). Academic Press Inc., San Diego, California, pp. 163–173.
- BAXTER, S. I., I. POW, A. BRIDGEN, AND H. W. REID. 1993. PCR detection of the sheep-associated agent of malignant catarrhal fever. Archives of Virology 132: 145–159.
- CRAWFORD, T. B., H. LI, AND D. O'TOOLE. 1999. Diagnosis of malignant catarrhal fever by PCR using formalin-fixed, paraffin-embedded tissues. Journal of Veterinary Diagnostic Investigation 11: 111–116.
- , ———, S. R. ROSENBERG, R. W. NORHAUSEN, AND M. M. GARNER. 2002. Mural folliculitis and alopecia caused by infection with goat-associated malignant catarrhal fever virus in two sika deer. Journal of the American Veterinary Medical Association 221: 843–847.
- CULLING, C. F. A., R. T. ALLISON, AND W. T. BARR. 1985. Cellular pathology technique, 4th Edition. Butterworth & Co. Ltd., London, UK, 642 pp.
- FRÖLICH, K., H. LI, AND U. MÜLLER-DOBLIES. 1998. Serosurvey for antibodies to malignant catarrhal fever-associated viruses in free-living and captive cervids in Germany. Journal of Wildlife Diseases 34: 777–782.
- HÄNICHEN, T., AND A. MANNL. 1984. Bösartiges Katarrhalfieber bei im Gatter gehalten Rehen (*Capreolus capreolus*). Verhandlungsbericht des Internationalen Symposium über die Erkrankungen der Zootiere 26: 355–361.
- , H. W. REID, H. WIESNER, AND W. HERMANN. 1998. Bösartiges Katarrhalfieber bei Zoowiederkäuern. Tierärztlicher Praxis 26: 294–300.
- HEUSCHELE, W. P., AND H. W. REID. 2001. Malignant catarrhal fever. In Infectious diseases of wild mammals, 3rd Edition, E. S. Williams and I. K. Baker (eds.). State University Press, Ames, Iowa, pp. 157–164.
- KEEL, M. K., J. G. PATTERSON, T. H. NOON, G. A. BRADLEY, AND J. K. COLLINS. 2003. Caprine herpesvirus-2 in association with naturally occurring malignant catarrhal fever in captive sika deer (*Cervus nippon*). Journal of Veterinary Diagnostic Investigation 15: 179–183.
- KLEIBOEKER, S. B., M. A. MILLER, S. K. SCHOMMER, J. A. RAMOS-VARA, M. BOUCHER, AND S. E. TURNQUIST. 2002. Detection and multigenic characterization of a herpesvirus associated with malignant catarrhal fever in white-tailed deer (*Odocoileus virginianus*) from Missouri. Journal of Clinical Microbiology 40: 1311–1318.
- LI, H., D. T. SHEN, D. P. KNOWLES, J. R. GORHAM, AND T. B. CRAWFORD. 1994. Competitive-inhibition enzyme-linked immunosorbent assay for antibody in sheep and other ruminants to a conserved epitope of malignant catarrhal fever virus. Journal of Clinical Microbiology 32: 1674–1679.
- , K. GAILBREATH, D. O'TOOLE, D. P. KNOWLES, J. R. GORHAM, AND T. B. CRAWFORD. 1995. Investigation of sheep-associated malignant catarrhal fever virus infection in ruminants by PCR and competitive inhibition enzyme-linked immunosorbent assay. Journal of Clinical Microbiology 33: 2048–2053.
- , ———, D. A. JESSUP, D. P. KNOWLES, J. R. GORHAM, T. THORNE, D. O'TOOLE, AND T. B. CRAWFORD. 1996. Prevalence of antibody to malignant catarrhal fever virus in wild and domestic ruminants by competitive-inhibition ELISA. Journal of Wildlife Diseases 32: 437–443.
- , W. C. WESTOVER, AND T. B. CRAWFORD. 1999. Sheep-associated malignant catarrhal fever in a petting zoo. Journal of Zoo and Wildlife Medicine 30: 408–412.
- , N. DYER, J. KELLER, AND T. B. CRAWFORD. 2000. Newly recognized herpesvirus causing malignant catarrhal fever in white-tailed deer (*Odocoileus virginianus*). Journal of Clinical Microbiology 38: 1313–1318.
- , J. KELLER, D. P. KNOWLES, AND T. B. CRAWFORD. 2001a. Recognition of another member of the malignant catarrhal fever virus group: An endemic gammaherpesvirus in domestic goats. Journal of General Virology 82: 227–232.
- , T. C. MCGUIRE, U. MÜLLER-DOBLIES, AND T. B. CRAWFORD. 2001b. A simpler, more sensitive competitive inhibition enzyme-linked immunosorbent assay for detection of antibody to

- malignant catarrhal fever virus. *Journal of Veterinary Diagnostic Investigation* 13: 361–364.
- , K. GAILBREATH, L. C. BENDER, K. WEST, J. KELLER, AND T. B. CRAWFORD. 2003a. Evidence of three new members of malignant catarrhal fever virus group in muskox (*Ovibos moschatus*), Nubian ibex (*Capra nubiana*), and gemsbok (*Oryx gazella*). *Journal of Wildlife Diseases* 39: 875–880.
- , A. WUNSCHMANN, J. KELLER, D. G. HALL, AND T. B. CRAWFORD. 2003b. Caprine herpesvirus-2-associated malignant catarrhal fever in white-tailed deer (*Odocoileus virginianus*). *Journal of Veterinary Diagnostic Investigation* 15: 46–49.
- O'TOOLE, D., H. LI, D. MILLER, W. R. WILLIAMS, AND T. B. CRAWFORD. 1997. Chronic and recovered cases of sheep-associated malignant catarrhal fever in cattle. *Veterinary Record* 140: 519–524.
- PLOWRIGHT, W. 1990. Malignant catarrhal fever virus. *In Virus infections of ruminants*, Z. Dinter and B. Morein (eds.). Elsevier Science Publishers B.V., New York, New York, pp. 123–150.
- , R. D. FERRIS, AND G. R. SCOTT. 1960. Blue wildebeest and the aetiological agent of malignant catarrhal fever. *Nature* 188: 1167–1169.
- REID, H. W., D. BUXTON, W. CORRIGALL, A. R. HUNTER, D. A. McMARTIN, AND R. RUSHTON. 1979. An outbreak of malignant catarrhal fever in red deer (*Cervus elaphus*). *Veterinary Record* 104: 120–123.
- , ———, I. POW, AND J. FINLAYSON. 1986. Malignant catarrhal fever: experimental transmission of the “sheep-associated” form of the disease from cattle and deer to cattle, deer, rabbits and hamsters. *Research in Veterinary Science* 41: 76–81.
- STATISTICS NORWAY. 2005. Domestic animals, by county. *In Agricultural Statistics 2003*. Official Statistics of Norway, Oslo/Kongsvinger, Norway, pp. 45–46 (in Norwegian).
- THAM, K. M. 1997. Molecular and clinicopathological diagnosis of malignant catarrhal fever in cattle, deer and buffalo in New Zealand. *Veterinary Record* 141: 303–306.
- VAN DEVANTER, D. R., P. WARRENER, L. BENNETT, E. R. SCHULTZ, S. COULTER, R. L. GARBER, AND T. M. ROSE. 1996. Detection and analysis of diverse herpesviral species by consensus primer PCR. *Journal of Clinical Microbiology* 34: 1666–1671.
- VIKØREN, T., J. THARALDSEN, B. FREDRIKSEN, AND K. HANDELAND. 2004. Prevalence of *Toxoplasma gondii* antibodies in wild red deer, roe deer, moose, and reindeer from Norway. *Veterinary Parasitology* 120: 159–169.
- WARSAME, I. Y., AND M. STEEN. 1989. Malignant catarrhal fever in wild Swedish moose (*Alces alces* L.). *Rangifer* 9: 51–57.
- WILLIAMS, E. S., E. T. THORNE, AND H. A. DAWSON. 1984. Malignant catarrhal fever in a Shira's moose (*Alces alces shirasi* Nelson). *Journal of Wildlife Diseases* 20: 230–232.
- ZARNKE, R. L., H. LI, AND T. B. CRAWFORD. 2002. Serum antibody prevalence of malignant catarrhal fever viruses in seven wildlife species from Alaska. *Journal of Wildlife Diseases* 38: 500–504.

Received for publication 2 November 2005.