

Infection with a Novel Gammaherpesvirus in Northern Elephant Seals (*Mirounga angustirostris*)

Authors: Goldstein, Tracey, Lowenstine, Linda J., Lipscomb, Thomas P., Mazet, Jonna A. K., Novak, Joseph, et al.

Source: Journal of Wildlife Diseases, 42(4) : 830-835

Published By: Wildlife Disease Association

URL: <https://doi.org/10.7589/0090-3558-42.4.830>

The BioOne Digital Library (<https://bioone.org/>) provides worldwide distribution for more than 580 journals and eBooks from BioOne's community of over 150 nonprofit societies, research institutions, and university presses in the biological, ecological, and environmental sciences. The BioOne Digital Library encompasses the flagship aggregation BioOne Complete (<https://bioone.org/subscribe>), the BioOne Complete Archive (<https://bioone.org/archive>), and the BioOne eBooks program offerings ESA eBook Collection (<https://bioone.org/esa-ebooks>) and CSIRO Publishing BioSelect Collection (<https://bioone.org/csiro-ebooks>).

Your use of this PDF, the BioOne Digital Library, and all posted and associated content indicates your acceptance of BioOne's Terms of Use, available at www.bioone.org/terms-of-use.

Usage of BioOne Digital Library content is strictly limited to personal, educational, and non-commercial use. Commercial inquiries or rights and permissions requests should be directed to the individual publisher as copyright holder.

BioOne is an innovative nonprofit that sees sustainable scholarly publishing as an inherently collaborative enterprise connecting authors, nonprofit publishers, academic institutions, research libraries, and research funders in the common goal of maximizing access to critical research.

Infection with a Novel Gammaherpesvirus in Northern Elephant Seals (*Mirounga angustirostris*)

Tracey Goldstein,^{1,2,5} Linda J. Lowenstine,³ Thomas P. Lipscomb,⁴ Jonna A. K. Mazet,² Joseph Novak,⁴ Jeffrey L. Stott,³ and Frances M. D. Gulland¹ ¹ The Marine Mammal Center, 1065 Fort Cronkhite, Sausalito, California 94965, USA; ² University of California Davis School of Veterinary Medicine, Wildlife Health Center, Davis, California 95616, USA; ³ University of California Davis School of Veterinary Medicine, Department of Pathology, Microbiology and Immunology, Davis, California 95616, USA; ⁴ Armed Forces Institute of Pathology, Department of Veterinary Pathology, Washington D.C. 20306, USA; ⁵ Corresponding author (email: goldsteint@tmcc.org)

ABSTRACT: Twenty juvenile northern elephant seals (*Mirounga angustirostris*) that died between 1998 and 2004 had ulcers on the tongue, palatine mucosa, and/or tonsils. Histologic examination of the lesions revealed cytoplasmic swelling, nuclear pyknosis, and eosinophilic to amphophilic intranuclear inclusions bodies suggestive of herpesviral infection. Electron microscopic examination and polymerase chain reaction analysis confirmed the presence of a herpesvirus. Subsequent DNA sequencing identified this to be a new gammaherpesvirus that was similar to Porcine lymphotropic virus 2, Alcephaline herpesvirus 1 (malignant catarrhal fever virus from wildebeest), and Chlorocebus rhadinovirus 1 from African green monkeys. Identical herpesviral DNA was also detected in blood and mucosal swabs collected from five healthy elephant seal pups.

Key words: Elephant seal, gammaherpesvirus, *Mirounga angustirostris*, ulcers.

Northern elephant seals (*Mirounga angustirostris*) range around the north-eastern rim of the Pacific Ocean from eastern Russia to Baja California (Riedman, 1990). These seals spend most of the year at sea but occur along the California coast and offshore islands during their breeding and molting seasons (Stewart and Huber, 1993). The population was hunted almost to extinction in the 1800s but is currently increasing at a rate of 6% annually and now includes approximately 150,000 individuals (Stewart et al., 1994). Minimal genetic variation has been detected in northern elephant seals (Hoelzel et al., 1993), leading to speculation that they should be extremely susceptible to infectious disease (Weber et al., 2004). Although bacterial and parasitic infections (Thornton et al., 1998; Elson-Riggins et al., 2001; Dubey et al., 2004) have been

reported in northern elephant seals, no viruses have been identified to date in this species. In contrast, viral infections are common in Pacific harbor seals (*Phoca vitulina*) and California sea lions (*Zalophus californianus*), which have ranges that overlap with that of the elephant seal (Gulland et al., 1997; Lipscomb et al., 2000). The purpose of this study was to investigate the potential for a viral etiology of ulcerative oral mucosal and tonsillar lesions observed in stranded northern elephant seal pups.

Complete necropsies were performed on 20 elephant seal pups <1 yr of age that died during rehabilitation at The Marine Mammal Center between 1998 and 2004; these seals had ulcers affecting the tongue, palate, and/or tonsils. Collected tissues were fixed in 10% neutral buffered formalin. Blood and mucosal swabs also were collected for molecular analysis as described by Goldstein et al. (2004) from five of these animals at necropsy or just prior to death, and from five healthy elephant seals that were released. Samples from the released animals were collected during the first week following admission in four animals, and during week one and week two in one animal. All pups were admitted during the months of March, April, May, August, or November and those that died were at the rehabilitation center for 1 to 41 days prior to death; those that were released were under care for between 23 to 93 days.

Formalin fixed tissues were embedded in paraffin, sectioned at 5 µm and stained with hematoxylin and eosin (H&E) for

histologic examination (Luna, 1968). Ultrastructural studies were performed on selected tissues that were deparaffinized, hydrated, and post-fixed in 1% osmium tetroxide, then dehydrated, cleared and embedded in epoxy resin. One-micrometer sections were cut and stained with toluidine blue for preliminary light microscopic examination. Thin sections (80–90 nm) were cut and stained with uranyl acetate and lead citrate for electron microscopy. Immunohistochemistry was performed on sections containing inclusion bodies with the avidin–biotin–peroxidase complex method using a commercial mouse monoclonal antibody against the latent membrane protein of Epstein-Barr virus (DakoCytomation California Inc, Carpinteria, CA 93013).

DNA extracted from ulcerated tissues, blood, and mucosal swabs was analyzed using previously published degenerate primers (VanDevanter et al., 1996), followed by elephant seal herpesvirus specific primers, both of which were designed to detect a fragment of the herpesviral DNA polymerase gene (sense: 5'-GGG-GATGTTTCCTTGCCTTA-3', anti-sense: 5'-CCTTAAAACAG GCATCACCT-3'). Positive PCR products were cloned into a plasmid vector, sequenced by the chain termination method (Sanger et al. 1977), and compared to other published herpesviral sequences in the GenBank Database (National Center for Biotechnology Information, National Library of Medicine, Bethesda, Maryland, USA). Primer combinations were used to obtain additional sequence of the elephant seal herpesviral DNA polymerase gene. The phylogenetic relationship between the newly detected virus and other herpesviruses, including other known marine mammal herpesviruses, was established using the NEIGHBOR program of PHYLIP (Phylogeny Inference Package, version 3.5c, University of Washington, Seattle, Washington, USA) and tested by SEQBOOT and CONSENSE programs to determine the degree of support for the particular

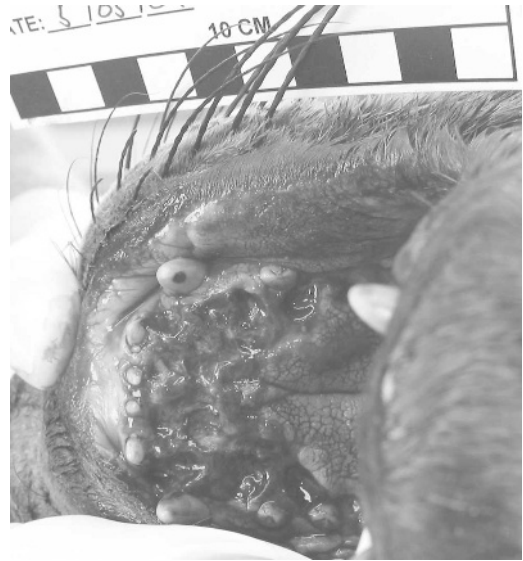

FIGURE 1. Severely ulcerated hard palate observed at necropsy from a weaning-aged elephant seal pup.

tree nodes and to obtain significant bootstrap values (>50%) or those that designate subfamily branches.

The causes of death, as classified according to Colegrove et al. (2005), of the 20 examined pups included verminous pneumonia and arteritis due to *Otostrongylus circumlitus* infection ($n=11$), endotoxemia secondary to acute enterocolitis ($n=2$), septicemia ($n=2$), protozoal meningitis ($n=1$), bacterial meningencephalitis ($n=2$), leptospirosis ($n=1$), and malnutrition ($n=1$). Grossly, the ulcers were 1–5 cm in diameter, and were found on the hard palate, soft palate, tongue, or tonsils (Fig. 1). Histopathologic examination of ulcerated and intact oral and tonsillar epithelium revealed areas of cytoplasmic swelling, nuclear pyknosis, and intranuclear inclusion bodies that varied from diffuse and lightly amphophilic to brightly eosinophilic with peripheral halos (Cowdry type A) (Fig. 2). The inclusions resembled those associated with herpesviral infections in other species. The intranuclear inclusion bodies stained positively by immunohistochemistry for the latent membrane protein of Epstein-

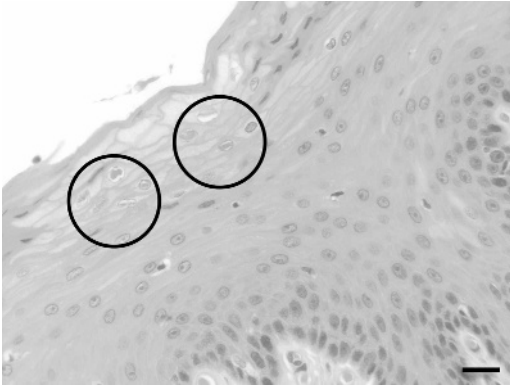


FIGURE 2. Tongue of an elephant seal with herpesvirus infection. Note the cytoplasmic swelling, nuclear pyknosis and eosinophilic intranuclear inclusion bodies (circled). H&E. Bar=20 μ m.

Barr virus (Fig. 3). Transmission electron microscopy revealed 90–110 nm-diameter nonenveloped intranuclear icosahedral nucleocapsids, which occasionally contained a central dense core and enveloped extracellular virions consistent with herpesvirus morphology (Fig. 4).

Herpesviral genomic sequences were detected in DNA extracted from tissue lesions, blood, and mucosal swabs collected at necropsy from seals that died

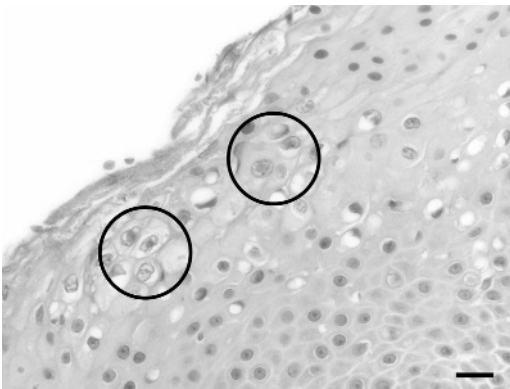


FIGURE 3. Tongue of an elephant seal with herpesvirus infection showing positive immunohistochemical staining (circled) of intranuclear inclusion bodies for the latent membrane protein of Epstein-Barr virus. Avidin–biotin–peroxidase complex method for the latent membrane protein of Epstein-Barr virus counterstained with Mayer's hematoxylin. Bar=20 μ m.

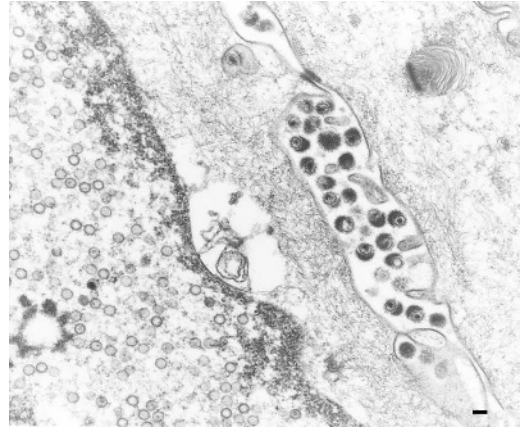


FIGURE 4. Transmission electron micrograph of stratified squamous epithelium covering the tonsil, from an elephant seal pup. Note nonenveloped intranuclear icosahedral nucleocapsids and extracellular enveloped virions consistent with a herpesvirus. Bar=100 nm.

between April and November with oral or tonsillar ulceration. Identical herpesviral DNA was also detected in blood and mucosal swabs from all five of the healthy elephant seal pups that were released following rehabilitation. All five animals were sampled during the first week of admission (one was also sampled during the second week), with all testing positive during the months of March, April, May, and August. A 225 bp fragment of the DNA polymerase gene was detected by PCR with the degenerate primers and a 150 bp fragment was detected using the elephant seal-specific herpesvirus primers; sequences were consistent with a herpesvirus belonging to the *Gammaherpesvirinae*. The two primer pairs were used in combination to obtain a larger fragment (490 bp, Genbank accession number DQ183057) of the DNA polymerase gene that was used in subsequent phylogenetic analysis to further classify the genomic sequence (Fig. 5). The analysis indicated that the elephant seal herpesviral sequence was most similar to Porcine lymphotropic virus 2 (47.6%, GenBank accession number AF191043), Alcephaline herpesvirus 1 (46.6%, GenBank

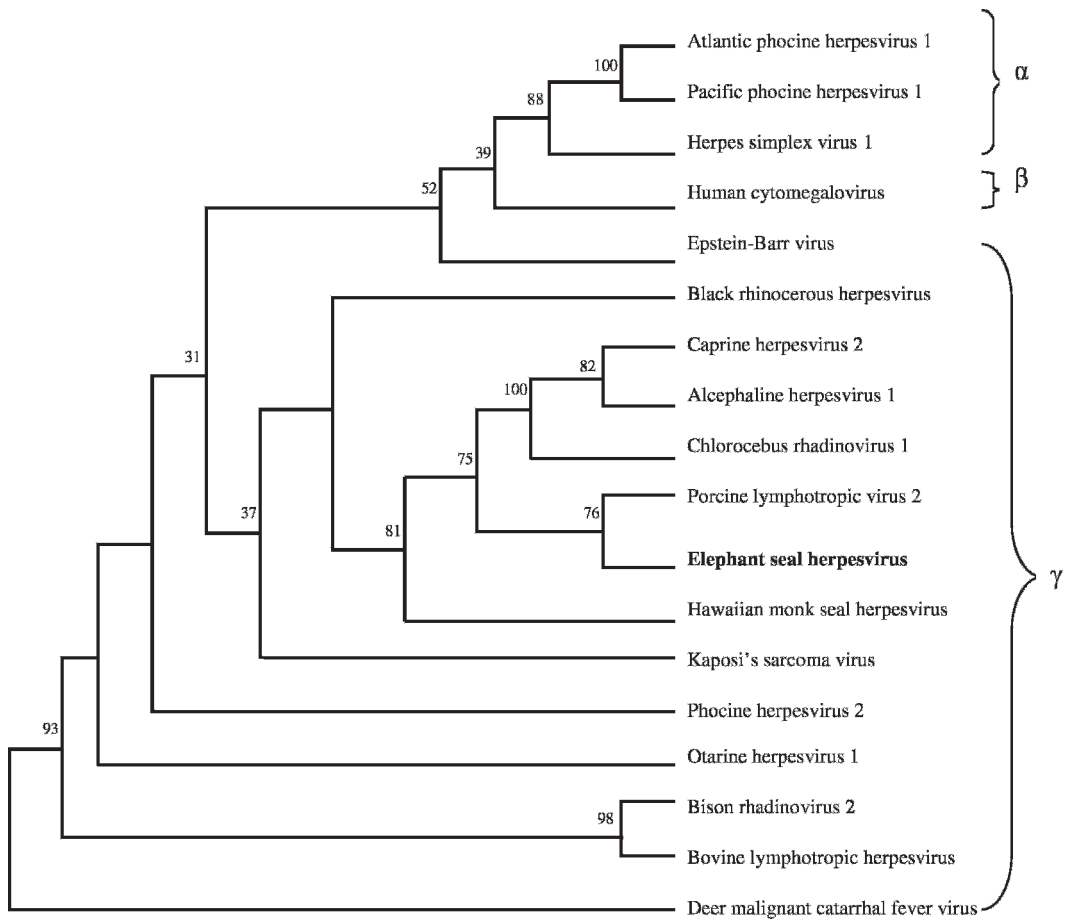


FIGURE 5. Consensus phylogram representing the relationship between the herpesviral sequence detected in northern elephant seals (GenBank accession number DQ183057) and other known herpesviruses from all three subfamilies. This analysis was performed using a 490 bp region of the DNA polymerase gene obtained by using the sense degenerate primer described by VanDevanter et al. (1996) and the elephant seal herpesviral specific anti-sense primer. Significant bootstrap values (>50%) or those that designate subfamily branches are shown. Viruses designated as α , β , γ belong to the alpha, beta, and gamma herpesvirus subfamilies, respectively. Sequences of viruses (GenBank accession numbers shown) are: Atlantic phocine herpesvirus 1 (Goldstein, T., unpubl. data), Pacific phocine herpesvirus 1 (U92269), Herpes simplex virus 1 (X04771), Human cytomegalovirus (AF133597), Epstein-Barr virus (V01555), Black rhinoceros herpesvirus (AF287948), Caprine herpesvirus 2 (AF283477), Alcephaline herpesvirus 1 (AF005370), Chlorocebus rhadinovirus 1 (CRH251573), Porcine lymphotropic virus 2 (AF191043), Hawaiian monk seal herpesvirus (DQ093191), Kaposi's sarcoma-associated herpesvirus (NC_003409), Phocine herpesvirus 2 (Goldstein, T., unpubl. data), Otarine herpesvirus (AF236050), Bison rhadinovirus 2 (AY237364), Bovine lymphotropic herpesvirus (AF031808), Deer malignant catarrhal fever virus (AF387516).

accession number AF005370), and Chlorocebus rhadinovirus 1 from African green monkeys (45.8%, GenBank accession number CRH251573). Compared to previously identified marine mammal herpesviruses, this DNA sequence was most similar to the Hawaiian monk seal herpes-

virus (42.5%, GenBank accession number DQ093191; Goldstein et al., 2006), followed by Otarine herpesvirus-1 (35.3%, GenBank accession number AF236050; Lipscomb et al., 2000) from California sea lions, and Phocine herpesvirus-2 (34.1%, T. Goldstein, unpubl. data) from an

Atlantic harbor seal. A herpesvirus belonging to the *Gammaherpesvirinae* has also been isolated from harbor and grey seals (*Halichoerus grypus*) in Europe (Martina et al., 2003). Although there does not appear to be a clear association between clinical signs and the presence of phocine herpesvirus-2 infections in these seals, there is some evidence to suggest that infection is linked to respiratory disease. All of the gammaherpesviral sequences obtained from pinnipeds to date have aligned most closely with other known herpesviruses in the *Rhadinovirus* (or $\gamma 2$) group rather than the *Lymphocryptovirus* (or $\gamma 1$) group within the *Gammaherpesvirinae*. Little is known about the epidemiology and pathogenesis of Rhadinoviruses, but they have most commonly been associated with respiratory infections and in some cases the development of cancer related disease (Roizman, 1996; Roizman et al., 1992).

This is the first report of a herpesviral infection in northern elephant seals. Although infection with this virus was not the primary cause of death in any of the 20 animals, it was associated with the oral and tonsillar ulcers. Identical herpesviral DNA was also detected in clinical samples from healthy elephant seal pups prior to release from the rehabilitation center and was not associated with clinical signs in these animals. There also does not appear to be an association between the time of year and animals testing positive for the virus in blood or swab samples. Therefore, it is not known whether the presence of the virus in these animals was associated with recent infection or reactivation as a result of being in captivity, or whether the herpesviral infection is ubiquitous in the population. Because herpesviral infections have not been previously reported in northern elephant seals, additional work is needed to understand the epidemiology and pathogenicity of this infection, as well as the prevalence of infection in free-ranging elephant seals.

We would like to thank the staff,

volunteers and interns from The Marine Mammal Center for help collecting samples, especially Denise Greig, Marty Haulena, and Christy McKnight. We are also grateful to the residents and pathologists at the University of California at Davis Veterinary Medical Teaching Hospital and the Armed Forces Institute of Pathology for assisting in the histopathologic examination of tissues, especially Katie Colegrove for photomicrography. Thanks to Brian Aldridge and Ken Jackson for help with the phylogenetic analysis. Samples were collected under the authority of Marine Mammal Protection Act permit number 932-1489-00.

LITERATURE CITED

- COLEGROVE, K. M., D. GREIG, AND F. M. D. GULLAND. 2005. Causes of stranding of phocids (northern elephant seals [*Mirounga angustirostris*] and Pacific harbor seals [*Phoca vitulina*]) along the central California coast, 1992–2001. *Aquatic Mammals* 31: 1–10.
- DUBEY, J. P., T. P. LIPSCOMB, AND M. MENSE. 2004. Toxoplasmosis in an elephant seal (*Mirounga angustirostris*). *Journal of Parasitology* 90: 410–411.
- ELSON-RIGGINS, J. G., L. AL-BANNA, E. G. PLATZER, AND I. KALOSHIAN. 2001. Characterization of *Otostrongylus circumlitus* from Pacific harbor and northern elephant seals. *Journal of Parasitology* 87: 73–78.
- GOLDSTEIN, T., J. A. MAZET, F. M. GULLAND, T. ROWLES, J. T. HARVEY, S. G. ALLEN, D. P. KING, B. M. ALDRIDGE, AND J. L. STOTT. 2004. The transmission of phocine herpesvirus-1 in rehabilitating and free-ranging Pacific harbor seals (*Phoca vitulina*) in California. *Veterinary Microbiology* 103: 131–141.
- , F. M. D. GULLAND, R. C. BRAUN, G. A. ANTONELIS, L. KASHINSKY, T. K. ROWLES, J. A. K. MAZET, L. M. DALTON, B. M. ALDRIDGE, AND J. L. STOTT. 2006. Molecular identification of a novel gamma herpesvirus in the endangered Hawaiian monk seal (*Monachus schauinslandi*). *Marine Mammal Science* 22: 465–471.
- GULLAND, F. M. D., L. J. LOWENSTINE, J. M. LAPOINTE, T. SPRAKER, AND D. P. KING. 1997. Herpesvirus infection in stranded Pacific harbor seals of coastal California. *Journal of Wildlife Diseases* 33: 450–458.
- HOELZEL, A. R., J. HALLEY, S. J. O'BRIEN, C. CAMPAGNA, T. ARNBOM, B. LE BOEUF, K. RALLS, AND G. A. DOVER. 1993. Elephant seal genetic variation and the use of simulation models to

- investigate historical population bottlenecks. *Journal of Heredity* 84: 443–449.
- LIPSCOMB, T. P., D. P. SCOTT, R. L. GARBER, A. E. KRAFFT, M. M. TSAI, J. H. LICHY, J. K. TAUBENBERGER, F. Y. SCHULMAN, AND F. M. D. GULLAND. 2000. Common metastatic carcinoma of California sea lions (*Zalophus californianus*): Evidence of genital origin and association with novel gammaherpesvirus. *Veterinary Pathology* 37: 609–617.
- LUNA, L. G. 1968. Manual of histologic staining methods of the Armed Forces Institute of Pathology, 3rd Edition. McGraw-Hill Company, New York, New York, 258 pp.
- MARTINA, B. E. E., G. M. VERJANS, T. C. HARDER, T. KUIKEN, M. W. G. VAN DE BILDT, P. A. C. VAN BERGEN, AND A. D. M. E. OSTERHAUS. 2003. Seal gammaherpesviruses: Identification, characterization and epidemiology. *Virus Research* 94: 25–31.
- RIEDMAN, M. 1990. Evolution, classification, and distribution of pinnipeds. In *The pinnipeds: Seals, sea lions, and walruses*. University of California Press, Berkeley, California, pp. 74–81.
- ROIZMAN, B. 1996. Herpesviridae. In *Field's virology*, 3rd edition, B. N. Fields, D. M. Knipe, and P. M. Howley (eds.). Lippincott–Raven Publishers, Philadelphia, Pennsylvania, pp. 2221–2229.
- , R. C. DESROSIERS, B. FLECKENSTEIN, C. LOPEZ, A. C. MINSON, AND M. J. STUDDERT. 1992. The family Herpesvirinae: An update. *Archives of Virology* 123: 425–449.
- SANGER, F., S. NICKLEN, AND A. R. COULSON. 1977. DNA sequencing with chain terminating inhibitors. *Proceedures of the National Academy of Sciences, USA* 74: 5463–5467.
- STEWART, B. S., AND H. R. HUBER. 1993. *Mirounga angustirostris*. *Mammalian Species* 449: 1–10.
- , P. K. YOCHEM, H. R. HUBER, R. L. DELONG, R. J. JAMESON, W. J. SYDEMAN, S. G. ALLEN, AND B. J. LE BOEUF. 1994. History and present status of the northern elephant seal population. In *Elephant seals: Population ecology, behavior and physiology*, B. J. LeBoeuf, B. J. Laws and R. M. Laws (eds.). University of California Press, Berkeley, California, pp. 29–48.
- THORNTON, S. M., S. NOLAN, AND F. M. GULLAND. 1998. Bacterial isolates from California sea lions (*Zalophus californianus*), harbor seals (*Phoca vitulina*), and northern elephant seals (*Mirounga angustirostris*) admitted to a rehabilitation center along the central California coast, 1994–1995. *Journal of Zoo and Wildlife Medicine* 29: 171–176.
- VANDEVANter, D. R., P. WARRENER, L. BENNETT, E. R. SCHULTZ, S. COULTER, R. L. GARBER, AND T. M. ROSE. 1996. Detection and analysis of diverse herpesviral species by consensus primer PCR. *Journal of Clinical Microbiology* 34: 1666–1671.
- WEBER, D. S., B. S. STEWART, J. SCHIENMAN, AND N. LEHMAN. 2004. Major histocompatibility complex variation at three class II loci in the northern elephant seal. *Molecular Epidemiology* 13: 711–718.

Received for publication 27 October 2005.