

## **Pulmonary Infection Due to *Mycobacterium goodii* in a Spotted Hyena (*Crocuta crocuta*) from South Africa**

Authors: van Helden, Paul D., van Pittius, Nico C. Gey, Warren, Robin M., Michel, Anita, Hlokwe, Tiny, et al.

Source: Journal of Wildlife Diseases, 44(1) : 151-154

Published By: Wildlife Disease Association

URL: <https://doi.org/10.7589/0090-3558-44.1.151>

---

The BioOne Digital Library (<https://bioone.org/>) provides worldwide distribution for more than 580 journals and eBooks from BioOne's community of over 150 nonprofit societies, research institutions, and university presses in the biological, ecological, and environmental sciences. The BioOne Digital Library encompasses the flagship aggregation BioOne Complete (<https://bioone.org/subscribe>), the BioOne Complete Archive (<https://bioone.org/archive>), and the BioOne eBooks program offerings ESA eBook Collection (<https://bioone.org/esa-ebooks>) and CSIRO Publishing BioSelect Collection (<https://bioone.org/csiro-ebooks>).

Your use of this PDF, the BioOne Digital Library, and all posted and associated content indicates your acceptance of BioOne's Terms of Use, available at [www.bioone.org/terms-of-use](http://www.bioone.org/terms-of-use).

Usage of BioOne Digital Library content is strictly limited to personal, educational, and non-commercial use. Commercial inquiries or rights and permissions requests should be directed to the individual publisher as copyright holder.

---

BioOne is an innovative nonprofit that sees sustainable scholarly publishing as an inherently collaborative enterprise connecting authors, nonprofit publishers, academic institutions, research libraries, and research funders in the common goal of maximizing access to critical research.

# SHORT COMMUNICATIONS

*Journal of Wildlife Diseases*, 44(1), 2008, pp. 151–154  
© Wildlife Disease Association 2008

## Pulmonary Infection Due to *Mycobacterium goodii* in a Spotted Hyena (*Crocuta crocuta*) from South Africa

Paul D. van Helden,<sup>1,6</sup> Nico C. Gey van Pittius,<sup>1</sup> Robin M. Warren,<sup>1</sup> Anita Michel,<sup>2</sup> Tiny Hlokwe,<sup>2</sup> Darshana Morar,<sup>3</sup> Jacques Godfroid,<sup>3</sup> Elizabeth C. du Plessis,<sup>4</sup> and Roy Bengis<sup>5</sup> <sup>1</sup> DST/NRF Centre of Excellence for Biomedical TB Research/MRC Centre for Molecular and Cellular Biology/Division of Molecular Biology and Human Genetics, Department of Biomedical Sciences, Faculty of Health Sciences-Stellenbosch University, PO Box 19063, Tygerberg 7505, South Africa; <sup>2</sup> Bacteriology Section, ARC-Onderstepoort Veterinary Institute, Private Bag X05, Onderstepoort 0110, South Africa; <sup>3</sup> Department of Veterinary Tropical Diseases, Faculty of Veterinary Science, University of Pretoria, Private Bag X04, Onderstepoort 0110, South Africa; <sup>4</sup> Vetpath, PO Box 8464, Pretoria 0001, South Africa; <sup>5</sup> Directorate of Animal Health, Department of Agriculture, Veterinary Investigation Centre, PO Box 12, Skukuza 1350, South Africa; <sup>6</sup> Corresponding author (email: pvh@sun.ac.za)

**ABSTRACT:** We report a case of pyogranulomatous pneumonia due to infection with *Mycobacterium goodii* in an adult female spotted hyena (*Crocuta crocuta*). The lungs of the animal showed consolidated, granulomatous lesions, and they were extensively and severely infiltrated. Polymerase chain reaction sequencing of isolated crude lung tissue DNA, and boiled lung culture samples, all confirmed that the causative organism was *M. goodii*, a recently described fast-growing organism closely related to the nonpathogenic mycobacterial species *M. smegmatis*. The current study illustrates that this organism can be pathogenic and cause extensive pulmonary disease.

**Key words:** *Mycobacterium goodii*, non-tuberculous mycobacterial infection, pulmonary disease, spotted hyena.

In May 2006, an adult female spotted hyena (*Crocuta crocuta*) was captured in the greater Kruger National Park complex (GKNPC), South Africa (24°55' 24'S,

31°31'30"E), owing to her being a problem animal. The animal was apparently healthy, with no external injuries noted. Her body condition was good, she was within normal weight range of an animal of her age (ca. 4 yr old), and all other vital signs were normal. Upon capture, the hyena was tested with the comparative intradermal tuberculin skin-test as part of the bovine tuberculosis surveillance program in the GKNPC, and diagnosed as a positive reactor to bovine purified protein derivative (PPD) (bovine PPD reaction >2 mm larger than avian PPD reaction, warm and edematous). Because she was a positive reactor and a problem animal, she was euthanized and subjected to postmortem examination according to a standard protocol. On examination of the thoracic organs, confluent, consolidated,

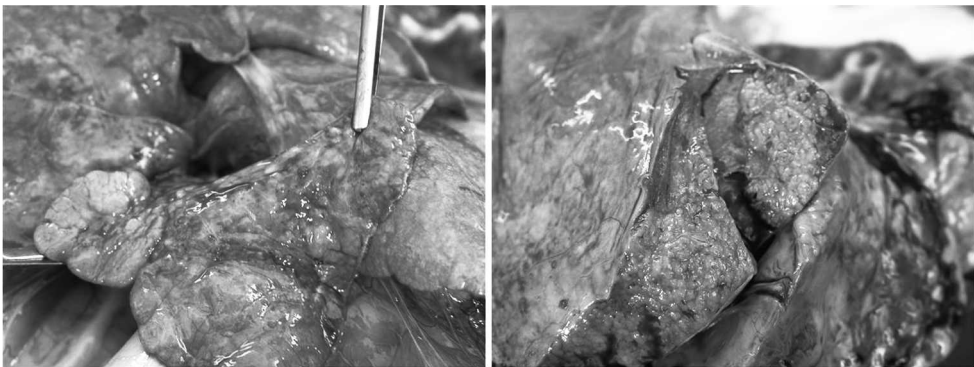


FIGURE 1. Multifocal to confluent inflammatory nodules and lesions observed in the lungs of the hyena.

granulomatous lesions involving the hilar and ventral regions of the middle and caudal lung lobes were observed (Fig. 1). Nodular enlargement of the bronchial lymph nodes was also apparent. All other organs and tissues seemed to be macroscopically normal. Tissue samples were taken from the bronchial lymph nodes and the lungs, and from various other lymph nodes in 10% buffered formalin, for histopathology and culture. Histopathologic examination of lung samples showed a pyogranulomatous pneumonia that was chronic and severe in appearance with multifocal-to-confluent inflammatory nodules, often closely associated with larger bronchi (Fig. 2A). The nodules were characterized by central areas of neutrophil infiltration, surrounded by a mixture of neutrophils, lymphocytes, plasma cells, multinucleate giant cells, and some macrophages (Figs. 2B, C). Lymph node tissues, from the mesenteric, gastrointestinal, retropharyngeal, parotid, axillary, popliteal, mandibular, and mediastinal lymph nodes, and the tonsils, seemed histologically within normal limits, with active lymphoid tissue visible. Mammary lymph nodes were less active. Ziehl-Neelsen staining of lung tissue revealed acid-fast bacilli bacteria compatible with *Mycobacterium* sp. organisms present within the centers of inflammatory nodules.

Lung tissue, bronchial lymph nodes, and pooled aliquots of abdominal, cranial and peripheral lymph nodes were collected for culture and molecular diagnosis. Lung tissue samples yielded acid-fast mycobacteria on MGIT Becton Dickinson and BACTEC Becton Dickinson culture. Crude DNA was extracted directly from the lung tissue samples using the Nucli-Sens DNA extraction kit, according to the manufacturer's instructions (bioMérieux, Marcy l'Etoile, France). Crude lung tissue DNA and boiled MGIT and BACTEC samples were first subjected to a multiplex polymerase chain reaction (PCR) amplification assay to identify members of the *Mycobacterium tuberculosis* complex

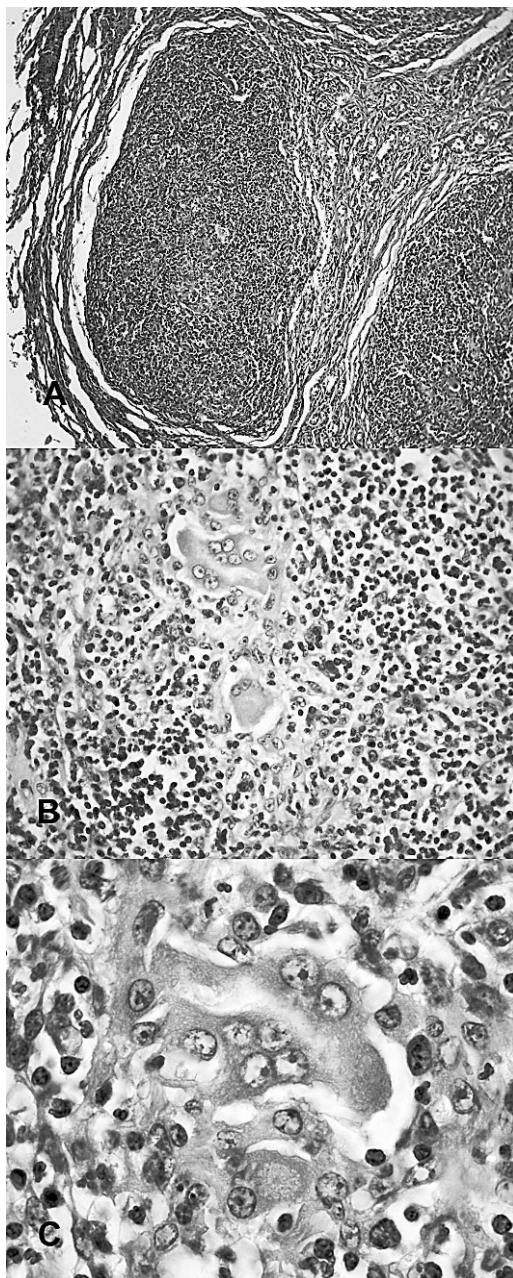


FIGURE 2. Histopathologic examination of lung samples. (A) Solid coalescing pyogranulomatous lesions in lung (10× magnification). (B) Pyogranulomatous pneumonia with central neutrophils and multinucleate giant cells (40× magnification). (C) Pyogranulomatous inflammation in the lung with visible multinucleate giant cell (100× magnification).



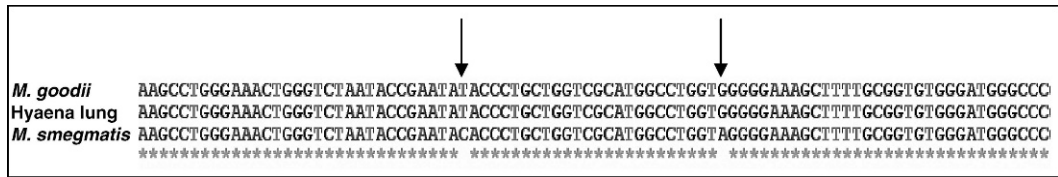


FIGURE 3. Part of the 5'-16S rDNA PCR-sequencing assay result demonstrating similarity between the sequence of the mycobacterial species isolated from the hyena and the sequence of *M. goodii*, indicating the presence of *M. goodii* in the lung tissue of the hyena. Asterisks indicate identical nucleotides within the three sequences, whereas the two arrows point to two significant single nucleotide differences that exist between *M. goodii* and *M. smegmatis* in this part of the 16S rDNA sequence.

(Warren et al., 2006). After negative results for all samples were obtained, they were subjected to a 5'-16S rDNA PCR-sequencing assay, which is able to identify and speciate *Mycobacterium* spp. (Harmen et al., 2003). The results from this assay showed that *Mycobacterium goodii* was present in all the lung samples assayed (both the MGIT and BACTEC cultures and the crude DNA isolated directly from the lung; Fig. 3).

Interferon (IFN)- $\gamma$  enzyme-linked immunosorbent assay (ELISA) using bovine and avian PPD were performed on blood taken before euthanasia (Morar et al., 2007). Although white blood cells of the hyena were reactive (high concanavalin A values), results using bovine and avian PPDs (cattle concentrations) as stimulants were negative (data not shown).

*Mycobacterium goodii* is a recently described fast-growing organism closely related to the mycobacterial species *M. smegmatis* (Brown et al., 1999). Infections with *M. goodii* rarely have been reported, but most commonly (79% of described infections) have been associated with panniculitis and wound infection. One case of *M. goodii*-associated panniculitis was described in a dog, with concurrent endogenous Cushing's disease (Bryden et al., 2004). Three isolated cases of chronic lung disease in humans were mostly associated with chronic lipid pneumonia (Brown et al., 1999). Thus far, there is only one report of isolation of *M. goodii* in Africa (from a pleural effusion in a human immunodeficiency virus-negative human

(Buijtelts et al., 2005) and only two reports worldwide of nonlipoid granulomatous pneumonia associated with *M. goodii* infection (Brown et al., 1999). In the previously described pleural effusion case, it is interesting to note that the patient had been treated for pneumonia, which had improved with amoxicillin treatment, a year before diagnosis with *M. goodii*. This patient also had hookworms in the stool and presented with diarrhea for 3 days. In the case of the hyena described in this study, the axillary lymph node sample and the myocardium showed the presence of *Hepatozoon* sp. organisms, and tapeworm segments were noticeable in the lumen of intestinal sections on histopathologic evaluation. Although these organisms are usually considered incidental, they may be responsible for some of the inflammation, especially in the myocardium where mild lymphoplasmacytic infiltrates were associated with the *Hepatozoon* sp. protozoal parasites. Such organisms could thus promote a T-helper (Th)2-type immune system response, as does the helminth infection seen in the human situation (Maizels and Yazdanbakhsh, 2003). It is not known whether this response would allow colonization by *M. goodii*, although there is evidence to suggest that bacterial colonization and infection takes place more easily under conditions of coinfection by organisms that promote Th2 immune responses (Resende et al., 2007).

The source of *M. goodii* in this case is unknown; however, the hyena had close

contact with a human environment, and food and a human source thus cannot be ruled out. Whether *M. goodii* can be a pulmonary pathogen in the absence of immune system modifications (e.g., coinfections) or in the absence of lipid pneumonia is currently unknown. The histopathologic findings of a pyogranulomatous pneumonia in the hyena are, however, compatible with lesions found in cases of mycobacterial pneumonia in animals, including the large wild cats. The fact that this animal was infected and diseased with *M. goodii* and had negative IFN- $\gamma$  ELISA test results suggests that the positive skin-test was a false-positive result and may be due to cross-reactivity with the *M. goodii* antigens. This is significant with regard to the use of skin-test assays for screening of animals for bovine tuberculosis.

Here, we report the first case of *M. goodii* infection in a nondomestic animal species and in an animal species in Africa. This study shows that this organism can be a pulmonary pathogen, adding to the pathogenic potential for disease reported for this organism.

The authors thank M. de Kock for technical assistance.

#### LITERATURE CITED

- BROWN, B. A., B. SPRINGER, V. A. STEINGRUBE, R. W. WILSON, G. E. PFYFFER, M. J. GARCIA, M. C. MENENDEZ, B. RODRIGUEZ-SALGADO, K. C. JOST, JR., S. H. CHIU, G. O. ONYI, E. C. BOTTGER, AND R. J. WALLACE, JR. 1999. *Mycobacterium wolinskyi* sp. nov. and *Mycobacterium goodii* sp. nov., two new rapidly growing species related to *Mycobacterium smegmatis* and associated with human wound infections: A cooperative study from the International Working Group on Mycobacterial Taxonomy. *International Journal of Systematic Bacteriology* 49: 1493–1511.
- BRYDEN, S. L., A. K. BURROWS, AND A. J. O'HARA. 2004. *Mycobacterium goodii* infection in a dog with concurrent hyperadrenocorticism. *Veterinary Dermatology* 15: 331–338.
- BUIJTELS, P. C., P. L. PETIT, H. A. VERBRUGH, A. VAN BELKUM, AND D. VAN SOOLINGEN. 2005. Isolation of nontuberculous mycobacteria in Zambia: Eight case reports. *Journal of Clinical Microbiology* 43: 6020–6026.
- HARMSSEN, D., S. DOSTAL, A. ROTH, S. NIEMANN, J. ROTHGANGER, M. SAMMETH, J. ALBERT, M. FROSCH, AND E. RICHTER. 2003. RIDOM: Comprehensive and public sequence database for identification of *Mycobacterium* species. *BMC Infectious Diseases* 3: 26.
- MAIZELS, R. M., AND M. YAZDANBAKHSH. 2003. Immune regulation by helminth parasites: Cellular and molecular mechanisms. *Nature Reviews Immunology* 3: 733–744.
- MORAR, D., E. TIJHAAR, A. NEGREA, J. HENDRIKS, D. VAN HAARLEM, J. GODFROID, A. L. MICHEL, AND V. P. RUTTEN. 2007. Cloning, sequencing and expression of white rhinoceros (*Ceratotherium simum*) interferon-gamma (IFN-gamma) and the production of rhinoceros IFN-gamma specific antibodies. *Veterinary Immunology and Immunopathology* 115: 146–154.
- RESENDE, C. T., C. S. HIRSCH, Z. TOOSI, R. DIETZE, AND R. RIBEIRO-RODRIGUES. 2007. Intestinal helminth co-infection has a negative impact on both anti-*Mycobacterium tuberculosis* immunity and clinical response to tuberculosis therapy. *Clinical and Experimental Immunology* 147: 45–52.
- WARREN, R. M., N. C. GEY VAN PITTIUS, M. BARNARD, A. HESSELING, E. ENGELKE, M. DE KOCK, M. C. GUTIERREZ, G. K. CHEGE, T. C. VICTOR, E. G. HOAL, AND P. D. VAN HELDEN. 2006. Differentiation of *Mycobacterium tuberculosis* complex by PCR amplification of genomic regions of difference. *International Journal of Tuberculosis and Lung Disease* 10: 818–822.

*Received for publication 13 June 2007.*