

Canine Distemper Virus in Wild Ferret-Badgers of Taiwan

Authors: Chen, Chen-Chih, Jai-Chyi Pei, Kurtis, Liao, Ming-Huei, and Mortenson, Jack A.

Source: Journal of Wildlife Diseases, 44(2) : 440-445

Published By: Wildlife Disease Association

URL: <https://doi.org/10.7589/0090-3558-44.2.440>

The BioOne Digital Library (<https://bioone.org/>) provides worldwide distribution for more than 580 journals and eBooks from BioOne's community of over 150 nonprofit societies, research institutions, and university presses in the biological, ecological, and environmental sciences. The BioOne Digital Library encompasses the flagship aggregation BioOne Complete (<https://bioone.org/subscribe>), the BioOne Complete Archive (<https://bioone.org/archive>), and the BioOne eBooks program offerings ESA eBook Collection (<https://bioone.org/esa-ebooks>) and CSIRO Publishing BioSelect Collection (<https://bioone.org/csiro-ebooks>).

Your use of this PDF, the BioOne Digital Library, and all posted and associated content indicates your acceptance of BioOne's Terms of Use, available at www.bioone.org/terms-of-use.

Usage of BioOne Digital Library content is strictly limited to personal, educational, and non-commercial use. Commercial inquiries or rights and permissions requests should be directed to the individual publisher as copyright holder.

BioOne is an innovative nonprofit that sees sustainable scholarly publishing as an inherently collaborative enterprise connecting authors, nonprofit publishers, academic institutions, research libraries, and research funders in the common goal of maximizing access to critical research.

Canine Distemper Virus in Wild Ferret-Badgers of Taiwan

Chen-Chih Chen,¹ Kurtis Jai-Chyi Pei,^{2,5} Ming-Huei Liao,³ and Jack A. Mortenson⁴ ¹ Pingtung Rescue Center for Endangered Wild Animals, Pingtung University of Science and Technology, Neipu, Pingtung 91201, Taiwan; ² Institute of Wildlife Conservation, Pingtung University of Science and Technology, Neipu, Pingtung 91201, Taiwan; ³ Department of Veterinary Medicine, National Pingtung University of Science and Technology, Neipu, Pingtung 91201, Taiwan; ⁴ United States Department of Agriculture, Veterinary Services, 530 Center Street NE, Suite 335, Salem, Oregon 97301, USA; ⁵ Corresponding author (email: kcjpei@mail.npust.edu.tw)

ABSTRACT: Canine distemper is an acute or subacute, highly contagious, febrile disease that is caused by canine distemper virus (CDV). Two CDV-infected wild Taiwan ferret-badgers (*Melogale moschata subauantiaca*) were found in Kaohsiung County, southern Taiwan, in 2005. Each case was confirmed by detecting CDV RNA in lung and brain tissues. A suspected third case was detected based on clinical signs and histology. These cases are the first record of wildlife infected by CDV in Taiwan. It is believed that domestic dogs or coexisting wild carnivores infected with the virus were the most likely source, and a serologic survey is needed to fully understand the host range of this virus in Taiwan. In addition, further genetic sequencing is needed to determine the source of these CDV cases.

Key words: Canine distemper virus, carnivores, domestic dogs, *Melogale moschata subauantiaca*, Taiwan ferret-badgers.

Canine distemper virus (CDV), which belongs to the genus *Morbillivirus* within the family *Paramyxoviridae*, is a relative large (150–250 nm) single-stranded RNA virus with a lipoprotein envelope (Deem et al., 2000). Canine distemper is an acute or subacute, highly contagious, febrile disease in many carnivore species, and it can affect respiratory, integumentary, gastrointestinal, or central nervous systems (Appel and Summers, 1995; Van Moll et al., 1995; Fox et al., 1998; Barrett, 1999; Frölich et al., 2000). Transmission of this virus from one individual to the other typically occurs through aerosolization of respiratory exudates. Virus shedding begins approximately 7 days postinfection. An acutely infected carnivore, with or without clinical signs, can shed virus through many body excretions (Appel and Summers, 1995; Deem et al., 2000).

Canine distemper is one of the most dangerous infectious diseases to domestic dogs (*Canis familiaris*) worldwide (Anderson, 1995; Appel and Summers, 1995; Deem et al., 2000; Frölich et al., 2000). Other than Canidae, species of Ailuridae, Mustelidae, Hyaenidae, Ursidae, Viverridae, Procyonidae, and Felidae, have been reported susceptible to CDV, but morbidity and mortality vary greatly among species (Appel et al., 1994; Anderson, 1995; Appel and Summers, 1995; Hur et al., 1999; Deem et al., 2000; Frölich et al., 2000; Hirama et al., 2004). Mustelidae seem to be most susceptible to CDV (Deem et al., 2000), whereas Canidae, and perhaps Viverridae, are less susceptible (Machida et al., 1993; Deem et al., 2000). For example, an outbreak of CDV in the black-footed ferret (*Mustela nigripes*) population in Wyoming, USA, occurred in 1985, where most individuals in the colony died; the population became extinct shortly thereafter (Williams et al., 1988).

In Taiwan, CDV causes disease and mortality in domestic dogs (Wu et al., 2000), but little is known about CDV infections in other species. Recently, a serologic survey examined four farmed masked palm civets (*Paguma larvata*) and two captive leopard cats (*Felis bengalensis*) from central and northern Taiwan; antibodies to CDV were detected in one leopard cat (Ikeda et al., 2001). In this article, we report and discuss two confirmed and one possible case of canine distemper in wild Taiwan ferret-badgers (*Melogale moschata subauantiaca*).

TABLE 1. Details of two sick and one dead wild Taiwan ferret-badgers (*Melogale moschata subauantiaca*) discovered in rural areas in Kaohsiung County, Taiwan in 2005.

No.	Date found	Age	Sex	Physical status	Location	Habitat type
TY1	16 November 2005	Adult	Female	Extremely weak, died in 1 day	Shihdong, Taoyuan	Second-growth forest, found by dirt road
LG1	28 November 2005	Adult	Female	Extremely weak, died in 1 day	Dajin, Liouguei	Second-growth forest, found by hiking trail
LG2	8 December 2005	Adult	Male	Found dead	Jianshan, Liouguei	Second-growth forest, found by dirt road

Taiwan ferret-badgers are small nocturnal animals belonging to the family Mustelidae, commonly found in many habitats (except city and human settlements) at elevations below 2,000 m in southern Taiwan (Pei, 2001). To our knowledge, these are the first known cases of CDV infections of wild carnivores in Taiwan.

In November and December 2005, two extremely weak (TY1, LG1) and one dead (LG2) wild Taiwan ferret-badgers were found in the Taoyuan and Liouguei districts, Kaohsiung County, Taiwan. They were discovered in second-growth forests near farmlands or villages, and they were taken to the Pingtung Rescue Center for Endangered Species (Table 1).

Despite extensive medical care, TY1 and LG1 died the same day of examination. Necropsies were conducted on all three animals, and tissue samples from all major body organs were collected and fixed in 10% neutral buffered formalin for histopathologic examination. Fresh, unfixed brain and lung tissues from samples LG1 and LG2 were available for the detection of the CDV nucleocapsid protein RNA by reverse transcription-polymerase chain reaction (RT-PCR).

For PCR, brain and lung tissues were homogenized, and total RNA was extracted using TRIzol reagent (Invitrogen, Carlsbad, California, USA) and resuspended in diethylpyrocarbonate-treated water (Xiang et al., 2001). The primers CDV-dF (forward: 5'-GGATTGCTGAGGACCTATC-TTGAGGCG; nucleotides 772–797) and

CDV-dR (reverse: 5'-CCAAGATAAC-CATGTACGGTGCTGTTTCAC; nucleotides 1027–1056) were designed from the sequence of CDV nucleocapsid protein. RT-PCR was performed with 5 µl of RNA, 2.5 µl of 0.4 mM dNTP mix, 2.5 µl of 10× RT-PCR buffer, 0.5 µl of 2 mM forward and reverse primers, 0.5 U of Taq DNA polymerase, 0.5 µl (10 U/µl) of AMV reverse transcriptase, and 0.5 µl (40 U/µl) of RNase inhibitor. Ultrapure sterile water was added to obtain a final volume of 25 µl. The final concentration of magnesium chloride was 2.5 mM. Thermocycling conditions for RNA amplification were reverse transcription 42 C (40 min) followed by 35 cycles of denaturation (94 C; 30 sec), annealing (62 C; 30 sec), and extension (72 C; 40 sec). The PCR products were analyzed on a 1.2% Seakem® agarose gel (Lonza Rockland, Inc., Rockland, Maine, USA) after staining with ethidium bromide.

Clinical signs observed with TY1 and LG1 were severe dehydration, apnea, ocular and nasal discharge, diarrhea, hypothermia, convulsions, and coma. All three animals were in good body condition with no evidence of external or internal trauma.

At necropsy, lungs seemed hemorrhagic, and meningeal blood vessels were hyperemic. Histopathologic examination revealed a variety of lesions relating to CDV (Table 2). Mild to moderate diffuse interstitial pneumonia and pulmonary hemorrhage and edema were found in all cases (Fig. 1). Nonpurulent meningo-

TABLE 2. Histopathologic findings and reverse transcription-polymerase chain reaction results of the three canine distemper-suspected wild Taiwan ferret-badgers from Taiwan in 2005.^a

No.	Interstitial pneumonia	Nonpurulent meningoencephalitis	Perivascular cuffing	Eosinophilic inclusion body	RT-PCR
TY1	+	+	+	—	NA
LG1	+	+	+	+	+
LG2	+	+	+	+	+

^a + = positive, — = negative, NA = not available.

cephalitis was found with lymphocytic infiltration and perivascular cuffing in the meninges and cerebral cortex, respectively. Neuronal degeneration was scattered in cerebral cortex and eosinophilic intracytoplasmic and intranuclear inclusion bodies in cerebrum neurons and bronchiolar epithelium were found in LG1 and LG2 (Fig. 1). There were no significant histopathologic changes in other body organs.

Canine distemper virus RNA was detected in all brain and lung samples from LG1 and LG2 using RT-PCR amplification (Table 2). All of these tissues were RT-PCR positive, with expected size of DNA fragment (285 bp).

The detection of RNA of the canine distemper virus confirmed that the LG1 and LG 2 were infected by CDV. For TY1, tissue samples were not available for RT-PCR and eosinophilic inclusion bodies were not observed (Table 2). Clinical signs and lesions in this animal, which included interstitial pneumonia, nonpurulent meningoencephalitis and perivascular cuffing, however, were consistent with canine distemper.

All three cases occurred in a very short time, and all came from a small geographical region, which suggests they might not be independent events. Because it is difficult to detect illness and mortality in wild animal populations, more cases may have been undetected and mortality often is underestimated based only on carcass recovery (Gulland, 1995). Based on the acute lesions found in the three cases presented herein and because all died in

an apparent short period, CDV is highly likely to be new to the wild Taiwan ferret-badger in Taiwan. Further sequencing effort is underway to compare additional samples with other CDV strains from Taiwan.

Because the locations where these animals were found are close to rural villages, it is likely that these ferret-badgers were infected from domestic dogs. A similar case has been suggested for the CDV outbreak in lion populations near Serengeti National Park (Cleaveland et al., 2000) and in the masked palm civet population in Japan (Hirama et al., 2004). It has been estimated that 57% of CDV-infected domestic dogs may become asymptomatic carriers (Deem et al., 2000). Domestic dogs in rural Taiwan are present in high numbers compared with larger urban cities; CDV vaccination efforts in these villages are limited (Chen, pers. obs.). Unrestrained house dogs and a small number of stray dogs were observed in the rural areas where our cases were found.

Nevertheless, the possibility of these wild Taiwan ferret-badgers being infected from other coexisting wild carnivores that were carrying the virus should not be ruled out. As mentioned, unlike Mustelidae, which are highly susceptible to and easily killed by CDV (Deem et al., 2000), some carnivores, such as Viverridae, may be more resistant to CDV infections (Machida et al., 1993). Two Viverridae, the masked palm civet and the small Indian civet (*Viverricula indica*), are also commonly found in the same area (Chen,

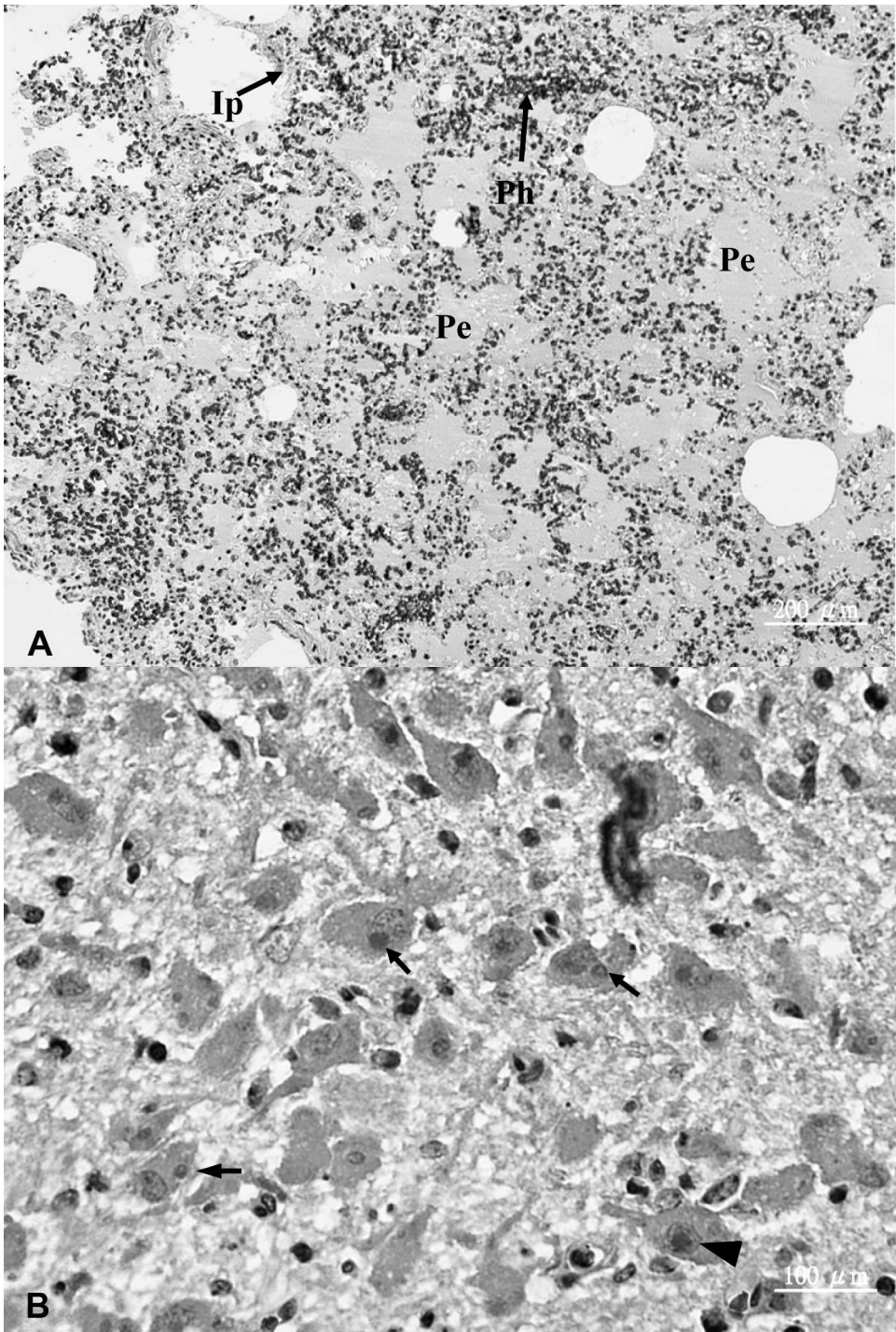


FIGURE 1. Lung (A) and brain (B) from ferret-badgers infected with canine distemper virus. (A) Interstitial pneumonia (Ip) accompanied with pulmonary hemorrhage (Ph) and edema (Pe). H&E stain. (B) Eosinophilic intracytoplasmic (arrows) and intranuclear (arrowhead) inclusion bodies are seen in the neurons. H&E stain.

2002), and they may represent reservoirs of CDV.

The impact of CDV infection to the local population of wild Taiwan ferret-badgers, and other sympatric carnivores, could be significant. For example, in August 1991, one masked palm civet was diagnosed with CDV infection in the Nishi-Tama area, near Tokyo, Japan (Machida et al., 1992, 1993). More than 200 wild raccoon dogs (*Nyctereutes procyonoides*) were found dead in the same area from September to December 1991; canine distemper was diagnosed based on clinical and pathologic results (Machida et al., 1993). The epizootic lasted about 3 mo, and it may have resulted in more than 70% of the raccoon dogs in the Nishi-Tama area (Machida et al., 1993). A timely CDV serologic survey done in both wild carnivores and domestic dogs in Taoyuan and Liouguei, Kaohsiung County will be valuable in assessing the level of CDV exposure in the local wild carnivore community.

The authors thank Zong-Ming Ye for laboratory examinations and the Department of Veterinary Medicine of the National Pingtung University of Science and Technology. Thanks also to the forest ranger, Xin-Da Wu, for help on sample collection and habitat information. Funding was provided by the Taiwan Forest Bureau, Council of Agriculture (grant 94 Forest Management-4.1-Conservation-02).

LITERATURE CITED

- ANDERSON, E. C. 1995. Morbillivirus infections in wildlife (in relation to their population biology and disease control in domestic animals). *Veterinary Microbiology* 44: 319–332.
- APPEL, M. J. G., AND B. A. SUMMERS. 1995. Pathogenicity of morbilliviruses for terrestrial carnivores. *Veterinary Microbiology* 44: 187–191.
- , A. VAN GARDEREN-HOETMER, AND R. A. WOUTERSEN. 1994. Canine distemper epizootic in lions, tigers and leopards in North America. *Journal of Veterinary Diagnostic Investigation* 6: 277–288.
- BARRETT, T. 1999. Morbillivirus infections, with special emphasis on morbilliviruses of carnivores. *Veterinary Microbiology* 69: 3–13.
- CHEN, M. T. 2002. Activity patterns and habitat use of sympatric small carnivores at low elevations in southern Taiwan. MS Thesis, Texas A&M University-Kingsville, Texas, 91 pp.
- CLEAVELAND, S., M. G. J. APPEL, W. S. K. CHALMERS, C. CHILLINGWORTH, M. KAARE, AND C. DYE. 2000. Serological and demographic evidence for domestic dogs as a source of canine distemper virus infection for Serengeti wildlife. *Veterinary Microbiology* 72: 217–227.
- DEEM, S. L., L. H. SPELMAN, R. A. YATES, AND R. J. MONTALI. 2000. Canine distemper in terrestrial carnivores: A review. *Journal of Zoo and Wildlife Medicine* 31: 441–451.
- FOX, J. G., R. C. PEARSON, AND J. R. GORHAM. 1998. Viral diseases. In *Biology and diseases of the ferret*, J. G. Fox (ed.). Lippincott Williams & Wilkins, Baltimore, Maryland, pp. 355–374.
- FRÖLICH, K., O. CZUPALLA, L. HAAS, J. HENTSCHKE, J. DEDEK, AND J. FICKEL. 2000. Epizootiological investigations of canine distemper virus in free-ranging carnivores from Germany. *Veterinary Microbiology* 74: 283–292.
- GULLAND, F. M. D. 1995. The impact of infectious diseases on wild animal populations—a review. In *Ecology of infectious diseases in natural populations*, B. T. Grenfell and A. P. Dobson (eds.). Cambridge University Press, Cambridge, UK, pp. 20–51.
- HIRAMA, K., Y. GOTO, M. UEMA, Y. ENDO, R. MIURA, AND C. KAI. 2004. Phylogenetic analysis of the hemagglutinin (H) gene of canine distemper viruses isolated from wild masked palm civet (*Paguma larvata*). *Journal of Veterinary Medicine Science* 66: 1575–1578.
- HUR, K., J. S. BAE, J. H. CHOI, J. H. KIM, S. W. KWON, K. W. LEE, AND D. Y. KIM. 1999. Canine distemper virus infection in binturongs (*Arctictis binturong*). *Journal of Comparative Pathology* 121: 295–299.
- IKEDA, Y., K. NAKAMURA, T. MIYAZAWA, M. C. CHEN, T. F. KUO, J. A. LIN, T. MIKAMI, C. KAI, AND E. TAKAHASHI. 2001. Seroprevalence of canine distemper virus in cats. *Clinical and Diagnostic Laboratory Immunology* 8: 641–644.
- MACHIDA, N., N. IZUMISAWA, T. NAKAMURA, AND K. KIRYU. 1992. Canine distemper virus infection in a masked palm civet (*Paguma larvata*). *Journal of Comparative Pathology* 107: 439–443.
- , K. KIRYU, K. OH-ISHI, E. KANDA, N. IZUMISAWA, AND T. NAKAMURA. 1993. Pathology and epidemiology of canine distemper in raccoon dogs (*Nyctereutes procyonoides*). *Journal of Comparative Pathology* 108: 383–392.
- PEI, K. J. C. 2001. Daily activity budgets of the Taiwan ferret badger (*Melogale moschata subaurantiaca*) in captivity. *Endemic Species Research* 3: 1–11.
- VAN MOLL, P., S. ALLDINGER, W. BAUMGARTNER, AND M. ADAMI. 1995. Distemper in wild carnivores: An

- epidemiological, histological and immunocytochemical study. *Veterinary Microbiology* 44: 193–199.
- WILLIAMS, E. S., E. T. THOME, M. J. APPEL, AND D. W. BELITSKY. 1988. Canine distemper in black-footed ferrets (*Mustela nigripes*) from Wyoming. *Journal of Wildlife Diseases* 24: 385–398.
- WU, S. C., L. L. CHUEH, V. F. PANG, C. R. JENG, C. C. LEE, AND C. H. LUI. 2000. Pathology and RT-PCR employed in the identification of canine distemper virus infection in Taiwan. *Journal of the Chinese Society of Veterinary Science* 26: 328–338.
- XIANG, X., D. QIU, R. D. HEGELE, AND W. C. TAN. 2001. Comparison of Different methods of total RNA extraction for viral detection in sputum. *Journal of Virological Methods* 94: 129–135.

Received for publication 6 November 2006.