



FOUR CASES OF SYSTEMIC MYCOSIS IN CERVIDS

Authors: FLETCH, A. L., and ANDERSON, R. C.

Source: Bulletin of the Wildlife Disease Association, 5(1) : 12-15

Published By: Wildlife Disease Association

URL: <https://doi.org/10.7589/0090-3558-5.1.12>

BioOne Complete (complete.BioOne.org) is a full-text database of 200 subscribed and open-access titles in the biological, ecological, and environmental sciences published by nonprofit societies, associations, museums, institutions, and presses.

Your use of this PDF, the BioOne Complete website, and all posted and associated content indicates your acceptance of BioOne's Terms of Use, available at www.bioone.org/terms-of-use.

Usage of BioOne Complete content is strictly limited to personal, educational, and non - commercial use. Commercial inquiries or rights and permissions requests should be directed to the individual publisher as copyright holder.

BioOne sees sustainable scholarly publishing as an inherently collaborative enterprise connecting authors, nonprofit publishers, academic institutions, research libraries, and research funders in the common goal of maximizing access to critical research.

FOUR CASES OF SYSTEMIC MYCOSIS IN CERVIDS

Mycotic diseases in wild animals are poorly documented. Pier (1962. Proc. 1st National White-tailed Deer Dis. Symp., Univ. of Georgia, Athens. 151-153) reviewed the available literature concerned with mycotic infections in deer and related wild ruminants and Ainsworth and Austwick (1959. Commonw. Agric. Bur. Anim. Hlth. Rev. Ser. 6) reviewed the subjects in animals in general.

Pulmonary and cerebral mycosis was reported in roe deer (*Capreolus capreolus*) and red deer (*Cervus elaphus*) by Bouvier (1967. Schweizer Arch. Tierheilk. 109:404. Abst. in Vet. Bull. 38: #1541). Rittenbach and Gunther (1963. Mh. Vet. Med. 18:887. Abst. in Vet. Bull. 34: #1690) reported unspecified mycotic involvement of the nasal cavity and associated bony structures in the head of a deer.

CASE HISTORIES

Case 1

A female white-tailed deer (*Odocoileus virginianus borealis*) about one week of age, was captured in Algonquin Park, Ontario. A few days later it became anorexic, listless and unable to support body weight. First one and then the other of the hind limbs became weak, followed by the front limbs. Breathing was irregular.

At necropsy the brain was swollen and there was discoloration of the pia-arachnoid covering of the frontal lobes of the cerebral hemispheres. Beneath this area was a cylindrical lesion approximately four centimeters in diameter extending deep into the frontal lobes. The center of the lesion was dark red and friable; the periphery was pink. There was no evidence of injury to the cranium and all other organs appeared normal.

Histological examination showed a severe encephalitis containing an organism resembling *Mucor* sp.

Case 2

This two-week old female white-tailed fawn was captured a few hours after birth at Niagara Falls, Ontario. At about two weeks of age it became bloated, partially anorexic and constipated. Growth was retarded and the animal was killed at three weeks of age following experimental exposure to *Pneumostongylus tenuis* (see Anderson, 1965. Path. vet. 2: 360).

At necropsy, pearl-like swellings bulged from the surface of the lungs. Other organs appeared normal.

On histological examination, two kinds of fungal elements were present in the lungs; branched, septate mycelia and chlamydospores or blastospores suggestive of *Candida albicans* or a *Chromoblastomyces* sp.

Case 3

A female caribou calf (*Rangifer tarandus terraenovae*) was shipped by air from Newfoundland to Guelph. Three days after experimental exposure to *P. tenuis* it became listless and anorexic. Body temperature was normal. The animal's appetite returned to normal on the sixth day following

exposure to *P. tenuis*, however there was evidence of posterior ataxia suggestive of infection with *P. tenuis* (Anderson and Strelive, 1968. Can. J. Zool. 46 (3): 503). After the tenth day the animal's appetite was irregular and death occurred on day 14, at which time blood flowed from the mouth and external nares.

At necropsy, multiple hemorrhagic areas one to four millimeters in diameter were scattered throughout the lungs (figure 1). Small whitish foci were located in the center of the hemorrhages. The trachea was full of blood-tinged froth and several blood clots. The brain appeared swollen and the epidural space was filled with hemorrhagic, edematous material.

Histologically the lungs showed focal necrosis and suppuration. Fungal hyphae resembling *Aspergillus spp.* were present in the center of these lesions (figure 2). A pure culture of *Aspergillus fumigatus* was grown from lung tissue on Sabouraud dextrose agar⁽¹⁾ (figure 3). Third stage *P. tenuis* larvae were present in the spinal cord (Anderson and Strelive, *ibid*).

Case 4

A ten month old male white-tailed deer, recently captured in the wild, was exposed to Epizootic Hemorrhagic Disease (EHD) virus and examined at necropsy following death 13 days after exposure.

A focal lesion approximately three centimeters in diameter was present mid-way down the trachea on the epithelial lining. The center of the lesion contained greyish-green filaments and the periphery was hemorrhagic. Other organs contained lesions typical of experimental infection with EHD virus (Karstad et al., 1961. Am. J. vet. Res. 22: 227).

Histologically, necrosis and hemorrhage of the epithelial and sub-epithelial tissues were evident. Fungal hyphae resembling *Aspergillus spp.* were present in the lesion (figure 4). *Aspergillus fumigatus* was grown on Sabouraud dextrose agar from a swab of the lesion.

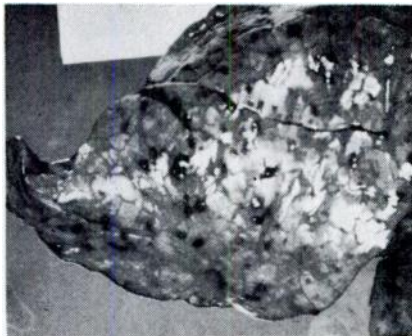


FIGURE 1. Lung of a caribou calf with hemorrhagic lesions containing *Aspergillus*.

¹British Drug Houses (Canada) Ltd., Barclay Avenue, Toronto, Ontario, Canada

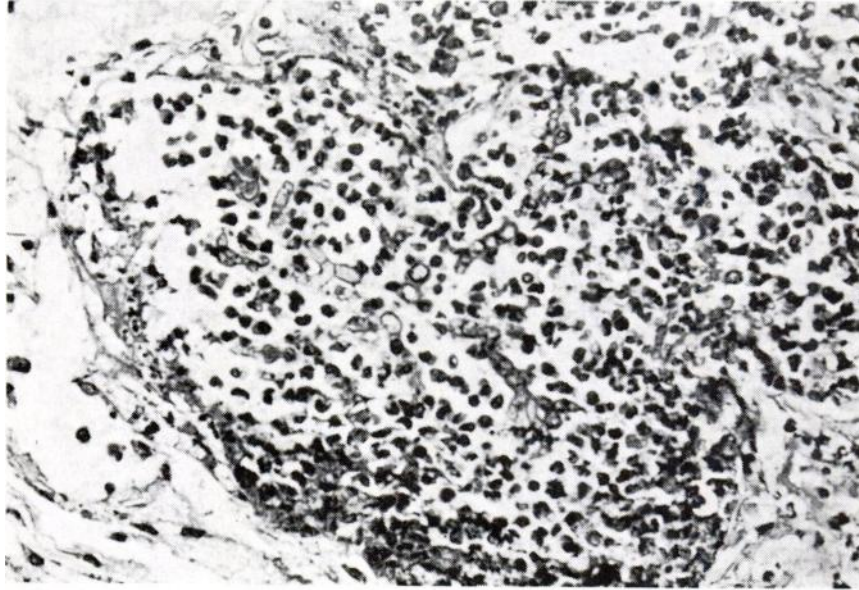


FIGURE 2. *Focal necrotic lesion in the lung shown in figure 1 containing fungal elements in a purulent exudate. PAS stain.*



FIGURE 3. *Fungal elements from a Sabouraud agar plate inoculated with material from lesions shown in Figures 1 and 2. Cotton blue-stained wet mount.*



FIGURE 4. Trachea of a white-tiled deer with fungal hyphae (arrows) under the epithelium and in thrombi in sub-epithelial vessels. PAS stain.

DISCUSSION

The fawn described as Case 1 was reported as showing marked neurological signs that could be associated with mycotic involvement of the brain. There was impairment of ability to bear weight on first the hind and then front legs. One would expect that this infection occurred by the hematogenous route as no external injury to the cranium, that would have allowed entry of the organism, was found. However, there was no evidence of a generalized mycosis.

Pulmonary aspiration of mycotic spores may have occurred in Cases 2 and 3. Both animals were being fed milk by bottle. Suspensions of *P. tenuis* larvae in sterile saline were mixed in the milk at the time of oral exposure, however there was no histological evidence of pulmonary involvement with *P. tenuis* larvae.

The lesion described in Case 4 could be explained by *Aspergillus fumigatus* acting as an opportunist or secondary invader. This deer had been anorexic and lethargic for four days before death.

ACKNOWLEDGEMENTS

Appreciation is expressed to Dr. T. Hulland, Department of Pathology, Ontario Veterinary College, for his comments on the histology of some of the cases described.

A. L. FLETCH and R. C. ANDERSON

Section of Wildlife Diseases
Ontario Veterinary College, and Department of Zoology
Ontario Agricultural College
University of Guelph, Guelph, Ontario

July 16, 1968