

THE OCULAR FUNDUS OF NORMAL WHITE-TAILED DEER (*Odocoileus virginianus*) 1

Author: DUKES, THOMAS W.

Source: Bulletin of the Wildlife Disease Association, 5(1) : 16-17

Published By: Wildlife Disease Association

URL: <https://doi.org/10.7589/0090-3558-5.1.16>

BioOne Complete (complete.BioOne.org) is a full-text database of 200 subscribed and open-access titles in the biological, ecological, and environmental sciences published by nonprofit societies, associations, museums, institutions, and presses.

Your use of this PDF, the BioOne Complete website, and all posted and associated content indicates your acceptance of BioOne's Terms of Use, available at www.bioone.org/terms-of-use.

Usage of BioOne Complete content is strictly limited to personal, educational, and non - commercial use. Commercial inquiries or rights and permissions requests should be directed to the individual publisher as copyright holder.

BioOne sees sustainable scholarly publishing as an inherently collaborative enterprise connecting authors, nonprofit publishers, academic institutions, research libraries, and research funders in the common goal of maximizing access to critical research.

THE OCULAR FUNDUS OF NORMAL WHITE-TAILED DEER
(*Odocoileus virginianus*)¹

The eye is not only the organ of sight but also a window through which clues to the state of the vascular and central nervous systems can be obtained. In order to evaluate changes seen in the ocular fundus of diseased animals, one must first be familiar with the normal anatomy which varies considerably among different species. This note describes the normal ocular fundus of twenty deer.

The eyes of deer were large and easily examined. The use of a topical mydriatic* facilitated examination but was not essential when the eyes were examined in a darkened area. The animals examined were restrained off the ground by assistants holding them around the thorax and abdomen and immobilizing the legs. The head was held in a natural position keeping the globe of the eye in its natural position. The ophthalmoscopic examination was performed by the technique described by Krawitz for the canine and feline (J.A.V.M.A., 147(1): 33-37, 1965). The ocular fundus was photographed using the technique described by Barnett, K. and C. R. Keeler (Vet. Rec. 80(21): 624-627, 1967). Both techniques worked well for deer and have also been used successfully on other wild species including frogs, alligators, snakes, chinchillas, antelope and coyotes. Photographs were taken with the Kowa RC-2 hand held fundus camera** using Ektachrome X or Kodachrome X.

The superior part of the fundus was a bright iridescent yellow-green, speckled with darker spots called Stars of Winslow. These darker spots result from defects in the tapetum lucidum when small choroidal vessels traverse the tapetum perpendicularly. Masses of pigment granules could be seen in this area also, especially toward the edges of the tapetum. The lower half of the fundus was deeply pigmented with the optic papilla (disc, nerve head) lying at the upper edge of this area. A macular area free of large vessels was seen temporally to the disc but no distinct fovea was observed.

The optic disc of normal white-tailed deer (*Odocoileus virginianus*) was markedly elongated horizontally (Fig. 1) rather than oval to round as seen in the common domestic ruminants such as goats and cattle. This elongated shape was also seen in antelope (*Antilocapra americana*). In both species the ends of the disc were slightly wider than the centre. The disc was mottled pink-cream, especially on its lateral edges, where nerve tissue was present. The amount of the pink nerve tissue varied with the individual. Frequently, the central area of the disc was white and crossed by grey lines.

¹ Material for this study was supplied by Pittmann-Robertson Project 93-R, a cooperative project between the Texas Parks and Wildlife Department and the Department of Veterinary Pathology, College of Veterinary Medicine and the Texas Agricultural Experiment Station, Texas A & M University.

*1% Tropicamide (Mydriacyl, Alcon Laboratories, Fort Worth, Texas).

**Keeler Optical Products, Inc., 5536 Baltimore Avenue, Philadelphia, Pennsylvania, 19143.

These grey lines (the lamina cribrosa) were seen since the surface of the nerve head is depressed and since histologically the optic nerve spreads at the globe leaving the sclera covered only with the transparent retina in the central areas of the disc. The disc margins were distinct except where blurred by large masses of nerve fibres seen frequently at the nasal margin. These opaque white (myelinated) nerve fibres were seen leaving the disc in areas where the pigmentation of the fundus gave them a contrasting background (Fig. 1a).

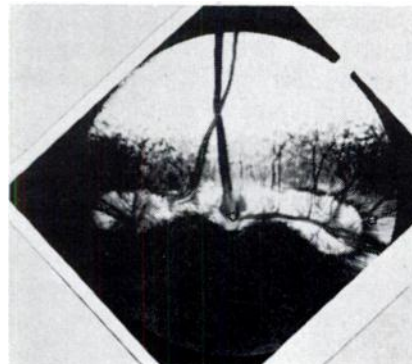
The deer fundus had a rich and complex central retinal arterial supply. The vessels appeared to arise from three areas on the disc — one located centrally and two laterally. The amount of vascular connection between these points varied with the individual. Pulsations were seen in the central retinal vein. Since this is considered normal in other species the same conclusion was reached for deer. The arrangement of the vessels at the disc was highly variable but the general pattern was one of an inverted "Y" or "T". The dorsal artery and vein were entwined in some cases. The retinal arteries were smaller (diameter ratio of 3:2) and brighter red than the veins and had a light reflex on their surface (Fig. 1b) resulting from the reflection of light from the blood column and thicker arterial wall. Frequently, in animals less than one year of age, remnants of the hyaloid artery that supplies the lens in prenatal life, were seen emerging from the center of the disc. This short thick grey white thread would wave in the vitreous as the eye moved (Fig. 1c). This resembled Bergmeister's papilla in man. The presence of this structure in young cattle has been reported (L. Z. Saunders in Jubb & Kennedy, Pathology of Domestic Animals, Vol. II, pg. 432, 1963), and is considered a normal finding in young ruminants.

A definitive clinical and pathological study of the deer eye is in progress.

FIGURE 1. *A normal ocular fundus of*
Odocoileus virginianus.

- (a) medullated nerve fibres
- (b) artery
- (c) Bergmeister's papilla

For comparison see the fundus photographs of domestic animals published by Barnett (Vet. Rec., 77(51): 1554-1555, 1965).



THOMAS W. DUKES
Dept. of Veterinary Pathology
Texas A and M University
College Station, Texas, 77843
 July 17, 1968