

## WEB NECROSIS IN MUTE SWANS—A REPORT OF AN OUTBREAK\*

Authors: YATES, VANCE J., MILLER, LOUISE T., JASTY, V., WILLEY, CHARLES H., and HOLTZINGER, MARIAN

Source: Bulletin of the Wildlife Disease Association, 5(1) : 33-34

Published By: Wildlife Disease Association

URL: <https://doi.org/10.7589/0090-3558-5.1.33>

---

The BioOne Digital Library (<https://bioone.org/>) provides worldwide distribution for more than 580 journals and eBooks from BioOne's community of over 150 nonprofit societies, research institutions, and university presses in the biological, ecological, and environmental sciences. The BioOne Digital Library encompasses the flagship aggregation BioOne Complete (<https://bioone.org/subscribe>), the BioOne Complete Archive (<https://bioone.org/archive>), and the BioOne eBooks program offerings ESA eBook Collection (<https://bioone.org/esa-ebooks>) and CSIRO Publishing BioSelect Collection (<https://bioone.org/csiro-ebooks>).

Your use of this PDF, the BioOne Digital Library, and all posted and associated content indicates your acceptance of BioOne's Terms of Use, available at [www.bioone.org/terms-of-use](http://www.bioone.org/terms-of-use).

Usage of BioOne Digital Library content is strictly limited to personal, educational, and non-commercial use. Commercial inquiries or rights and permissions requests should be directed to the individual publisher as copyright holder.

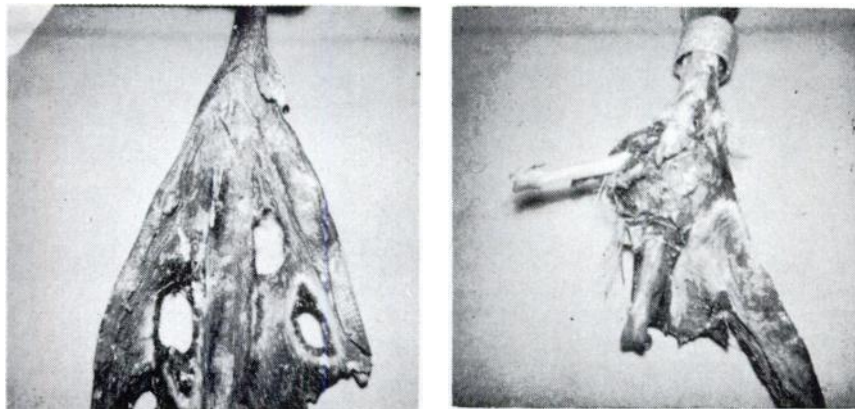
---

BioOne is an innovative nonprofit that sees sustainable scholarly publishing as an inherently collaborative enterprise connecting authors, nonprofit publishers, academic institutions, research libraries, and research funders in the common goal of maximizing access to critical research.

**WEB NECROSIS IN MUTE SWANS — A REPORT OF AN OUTBREAK\***

In August and early September, 1967, a total of 22 mute swans (*Cygnus olor*) was submitted to the Diagnostic Laboratory of the Department of Animal Pathology, University of Rhode Island, by the R.I. State Department of Natural Resources. These swans were mainly taken from the Pawcatuck River near Westerly, R.I.; however, three were from waters near Little Compton, R.I. The diseased swans were observed when the birds were caught for routine banding and sexing. Eighteen of the swans were male, two were female, and the sex of two was not recorded. The banding period had been scheduled to correspond with the time of molting.

All 22 swans submitted showed necrotic lesions involving the foot web alone or of the foot web and one or more of the interphalangeal joints. The lesions of the foot webs varied in severity, from a small irregular leathery necrotic lesion of one web to lesions so extensive that the webs were completely eroded from both feet. The area at the margin between the necrotic tissue and the healthy tissue was usually swollen, reddened and warm. In some swans the interphalangeal joints of the digits were very swollen, abnormally warm and tender. These joints usually contained an increased amount of viscid synovial fluid. The joint involvement only occurred in swans that had necrotic lesions involving the webs of the feet. In a few of the cases the inflammation extended to the tarsometatarsophalangeal joint. In the most severe cases the flesh had fallen off the distal portion of one or more digits exposing the phalangeal bones. Figures 1 and 2 show some of the diseased foot webs. The general condition of the swans varied with the extent of the lesions. Those with lesions involving the interphalangeal joint were usually poorly fleshed and inactive.



FIGURES 1 and 2: *Feet of swans showing stages of web necrosis.*

\* Contribution #1291 of the R.I. Agricultural Experiment Station.

Samples of joint fluid, and tissue of the involved webs were taken from several swans for microbiological determinations. Web tissues were also collected for histological examination. Paraffin sections of these tissues were stained with hematoxylin-eosin and by Gridley's technique. The bacteriological examination consisted of inoculating blood and PPLO agar plates and incubating them at 37 C under aerobic and anaerobic conditions. Tissue fragments and joint fluids were also inoculated onto potato and Sabouraud's agar and incubated at 21 C to determine the presence of fungi. Chicken embryo kidney cells were inoculated with tissue suspensions in the search for viruses.

At the time of submission all swans were placed in clean, dry quarters and fed grass clippings and chicken pellets. Approximately half of the diseased swans were injected every other day for two weeks with antibiotics and their foot lesions sprayed with an antifungal preparation.

Histologically, the foot-web lesion consisted of hyperkeratosis of the epidermis and thickening of dermal layers. The epidermal layers in many places showed areas of necrosis. Branching and septate hyphae, indistinguishable from those of *Aspergillus*, were often found in the necrotic zones. Chronic inflammatory lesions were found in the dermis. These consisted of proliferating fibroblasts, lymphocytes, and a few heterophilic leucocytes. The bacteriological and virological examinations were negative; however, *Aspergillus* and several other genera of fungi were found on the plates inoculated with the tissue fragments.

Although fungi were found in the stained tissue sections and were isolated from tissue suspensions, it is the authors' opinion that the fungi were secondary invaders and were only found in the tissue after it had been debilitated by some obscure injury or by a bacterial or viral infection. Three of the diseased swans succumbed to the disease, and two were sacrificed in the collection of tissues. The rest showed a gradual improvement in general condition and the inflammation of their webs and joints subsided. When it was felt the swans had recovered sufficiently, they were released. The treatment procedure did not alter the rate or extent of recovery.

VANCE J. YATES<sup>1</sup>, LOUISE T. MILLER<sup>1</sup>, V. JASTY<sup>1</sup>, CHARLES H. WILLEY<sup>2</sup>,  
and MARIAN HOLTZINGER<sup>3</sup>

<sup>1</sup>*Department of Animal Pathology, University of Rhode Island, Kingston, R.I. 02881*

<sup>2</sup>*Vermont Fish & Game Department, Roxbury, Vermont*

<sup>3</sup>*Roger Williams Hospital, Department of Bacteriology, Providence, R.I.*

October 2, 1968