



LOCOISM IN ELK

Authors: ADCOCK, J. L., and KEISS, R. E.

Source: Bulletin of the Wildlife Disease Association, 5(2) : 121-124

Published By: Wildlife Disease Association

URL: <https://doi.org/10.7589/0090-3558-5.2.121>

BioOne Complete (complete.BioOne.org) is a full-text database of 200 subscribed and open-access titles in the biological, ecological, and environmental sciences published by nonprofit societies, associations, museums, institutions, and presses.

Your use of this PDF, the BioOne Complete website, and all posted and associated content indicates your acceptance of BioOne's Terms of Use, available at www.bioone.org/terms-of-use.

Usage of BioOne Complete content is strictly limited to personal, educational, and non - commercial use. Commercial inquiries or rights and permissions requests should be directed to the individual publisher as copyright holder.

BioOne sees sustainable scholarly publishing as an inherently collaborative enterprise connecting authors, nonprofit publishers, academic institutions, research libraries, and research funders in the common goal of maximizing access to critical research.

LOCOISM IN ELK

A Disease Resembling Cerebral Pseudolipidosis

A previously unreported fatal disease of elk (*Cervus canadensis*), clinically characterized by nervous disturbances, has been observed since 1966 in a localized area in Colorado. This locality includes the mountainous region in and immediately adjacent to a triangular area bounded by the Tarryall Reservoir and the towns of Bailey and Jefferson, southwest of Denver.

Occurrence of this disease has been limited to the months of March through August during each of the past 3 years. In early spring plants of the genera *Astragalus* and *Oxytropis* are among the first green forage plants available to elk in this locality. These locoweeds persist in abundance throughout the summer. It has been established by analysis of ruminal contents that elk ingest these plants.

As is true of many diseases of wildlife, the incidence of this disorder is difficult to determine. Many elk exhibiting signs suggestive of the disease have been seen by ranchers and wildlife conservation officers but could not subsequently be found for further study. The largest number of dead elk found in this area in a single year was 35, during the spring and summer of 1967.

Although data regarding the clinical features of this disease are still fragmentary and incomplete, the following have been observed: emaciation, extreme weakness and depression, fine and coarse generalized muscular tremors, stumbling and incoordination. One elk had posterior ataxia and "hopped" uphill with difficulty, its hindlimbs spraddled. The head and neck of another animal were repeatedly flexed strongly toward the left. Ages of affected animals ranged from 1 to 9 years and both sexes were involved.

To date, gross and histopathologic studies have been conducted on tissues obtained at necropsy from 8 naturally-occurring cases of the disease. Formalin was the routine fixative used. Emaciation and serous atrophy of adipose tissue were consistent features. Grey matter of

the brains was slightly pale and the livers were pale tan with abnormal prominence of individual lobules. Renal cortices were pale, with congestive mottling in some instances. Lymph nodes throughout the body were swollen and pale. Other features occasionally observed included pulmonary congestion and edema, excessive amounts of serosanguinous fluid in serous cavities, pale blood and serous atrophy of bone marrow. Numerous pieces of locoweeds were found in the ruminal contents of each of 4 affected elk in which ingesta were examined.

The most striking histopathologic alterations were those observed in the nervous system. The characteristic change consisted of swelling and fine vacuolation of the cytoplasm of neurons accompanied by axonal dystrophy (Figures 1 and 3). The oil-red-O and periodic acid-Schiff techniques did not reveal either lipid or polysaccharide within the vacuoles in neuronal cytoplasm and their content remains undetermined. Neurons affected in this fashion were widespread throughout the cerebral cortex, basal

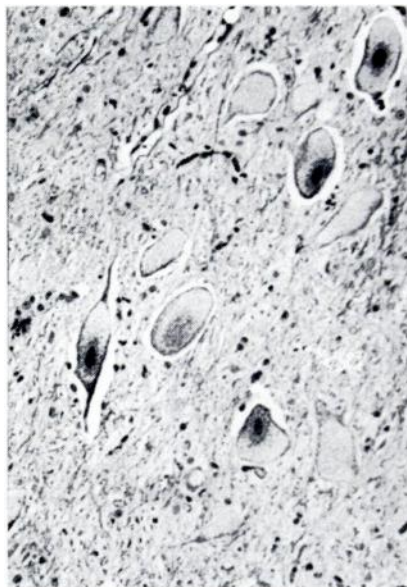


FIGURE 1. *Spontaneous locoism. Swollen, vacuolated neurons in hypoglossal nucleus. H. & E., X 150.*

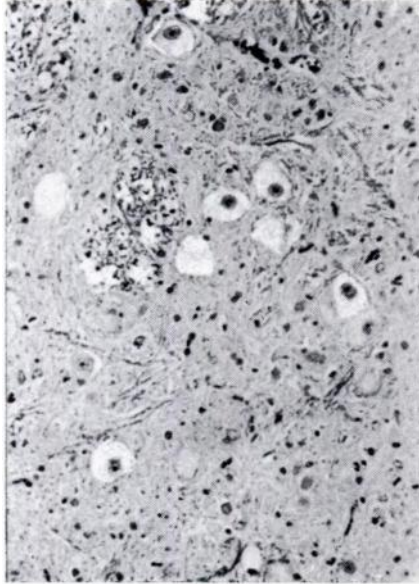


FIGURE 2. *Experimental locoism. Swollen, vacuolated neurons and dystrophic axons in inferior olivary nucleus. H. & E., X 150.*

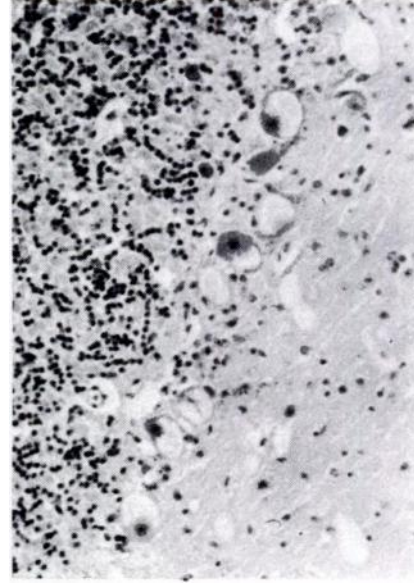


FIGURE 3. *Spontaneous locoism. Enlarged, vacuolated Purkinje cells in cerebellum. H. & E., X 150.*

nuclei, hippocampus, diencephalon, mid-brain, pons, medulla oblongata and cerebellum. Neurons of the spinal cord, Gasserian ganglion, spinal ganglia, myenteric plexus, and the ganglion cell layer and inner nuclear layer of the retina were similarly involved. Dystrophic axons were present in the optic nerve head and optic nerve fiber layer of the retina.

In addition to the neuronopathy, marked cytoplasmic swelling and vacuolation were noted in epithelial cells of the choroid plexuses, hepatocytes (Figure 4), acinar cells of the pancreas and salivary glands, follicular cells of the thyroid, and proximal tubular epithelium of the kidney (Figure 5). Collections of macrophages with vacuolated cytoplasm occurred in lymph nodes (Figure 6) and spleen. Thus, the disease is a generalized one affecting multiple organ systems. The content of vacuoles in the aforementioned epithelial cells and macrophages has not been identified. Oil-red-O and periodic acid-Schiff methods applied to liver sections yielded negative results.

Since there was reason to suspect that ingestion of locoweeds might be the cause of this disease, an attempt was made to reproduce it experimentally. For this purpose whole plants of the genera *Astragalus* and *Oxytropis* were collected in the spring of 1968 from the location in which the disease had occurred. Because of the early stage of growth of these plants, species identification was not practical. These plants were mixed, dried, formed into pellets and then fed to a normal elk. This animal was a 4- or 5-year-old female originally trapped in Rocky Mountain National Park and maintained for 3 years at the Colorado Division of Game, Fish and Parks Wildlife Research Center in Fort Collins.

Pelleted locoweed was fed at the following daily rates: 180 gm. for 1 day, 200 gm. for 4 days, 500 gm. for 90 days, 1000 gm. for 14 days, then 2000 gm. for 32 days (a total of 141 days). The pellets were fed mixed with gradually decreasing amounts of grain for the first 90 days, after which time no grain was provided. Alfalfa hay was offered free choice during the first 85 days, then at

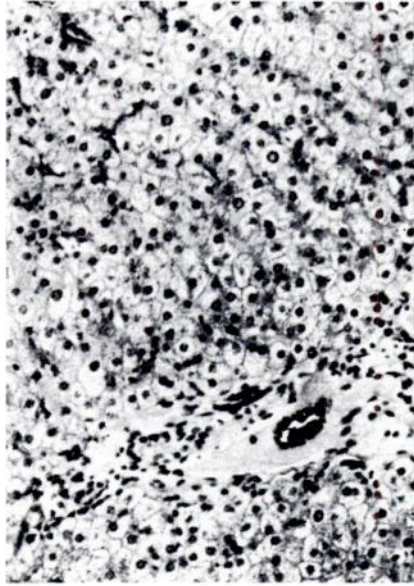


FIGURE 4. *Spontaneous locoism. Hepatocytes are enlarged and vacuolated. H. & E., X 150.*

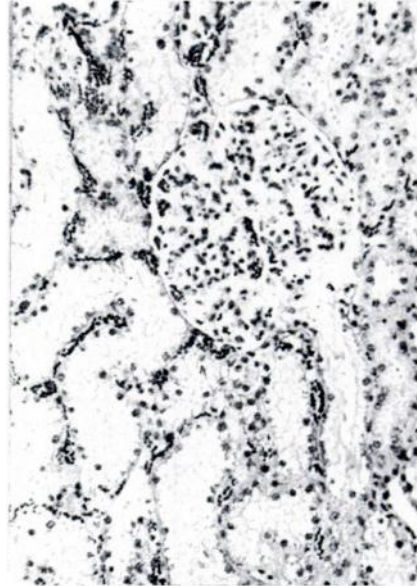


FIGURE 5. *Spontaneous locoism. Swelling and vacuolation of proximal tubular epithelium. H. & E., X 150.*

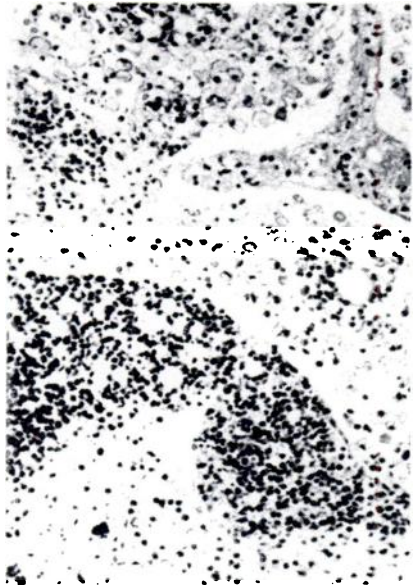


FIGURE 6. *Spontaneous locoism. Macrophages with vacuolated cytoplasm in medullary sinuses of lymph node. H. & E., X 150.*

the rate of 5 lbs. daily for the remainder of the feeding trial. All the pelleted locoweed provided was consumed with the exception of small amounts not eaten during a 5 day period early in the trial. Fresh water was available at all times.

The only clinical abnormalities noted in this elk were moderate progressive weight loss and depression which occurred in the latter part of the experiment. At the conclusion of the trial the animal was killed and subjected to postmortem examination. Gross changes included pallor of the grey matter in the brain, greyish-tan pallor of the hepatic parenchyma with accentuation of lobular architecture, and paleness of the renal cortex. Unfortunately, information pertaining to other parenchymatous organs, lymphoid tissues, and eyes was not obtained, and specimens of these tissues were not preserved for microscopic study. Brain, liver, and kidney were, however, fixed in formalin. Histopathologic examination of these 3 organs revealed lesions identical in character to those observed in the naturally-occurring cases. Therefore, although the full-blown clinical

features of the spontaneous disorder were not elicited experimentally, gross and microscopic alterations in the brain (Figure 2), liver and kidney were faithfully reproduced.

The signs and lesions encountered in this disease bear a close resemblance to those described in cerebral pseudolipidosis of Aberdeen-Angus calves in Australia (Whittem and Walker, 1957, J. Path. Bact., 74: 281-288), a disease of undetermined etiology. *Swainsona* poisoning of sheep in Australia (Hartley and Kater, 1965, Austral. Vet. J., 41: 107-111) and *Astragalus mollissimus* poisoning of horses in Kansas (Oehme, Bailie and Hulbert, 1968, J.A.V.M.A., 152(3): 271-278) appear to be closely related, both pathologically and etiologically, to the disease of Colorado elk reported in this article.

Efforts are currently underway to identify the species of *Astragalus* and *Oxytropis* responsible for spontaneous locoism in elk. Further feeding trials will be conducted to compare the effects of individual species of these plants.

Clinical and pathologic features of this condition will be described in greater detail elsewhere.

Acknowledgements

The authors are indebted to Wildlife Conservation Officers E. R. Chisholm, W. J. Forgett, and H. Lanning for their assistance in gathering field observations and collecting animals included in this study. Invaluable histotechnical assistance was provided by Mrs. Mary Witkop.

J. L. ADCOCK

*Department of Pathology
College of Veterinary Medicine and
Biomedical Sciences
Colorado State University,
Fort Collins, Colorado 80521*

and

R. E. KEISS

*Colorado Division of Game, Fish
and Parks
Laboratory Research Center
Fort Collins, Colorado*

February 20, 1969

REVIEW

Scientific Writing for Graduate Students, edited by Peter Woodford. The Rockefeller University Press. 1968. 190 pp. \$5.75.

The Council of Biology Editors, Inc., has issued its second manual. The first, *Style Manual for Biological Journals*, has been universally accepted as the bible by most English language journals throughout the world and has been translated into several foreign languages. It was prepared by the Committee on Form and Style and is currently being revised. A new edition will appear shortly.

This new volume, *Scientific Writing for Graduate Students*, is a manual on the teaching of scientific writing, prepared by the CBE committee on graduate training in scientific writing. The book was written because the members of the Council of Biology Editors, like all editors of scientific journals, are acutely aware that many scientists write badly. Although the reasons may be complex, one contributing factor seems clear: few universities provide formal training in scientific writing, and few even encourage their students to develop a rational technique for writing scientific papers through the study of any of the excellent available textbooks.

This book is an encouragement to have scientists themselves make the effort to teach their students better writing. The manual is intended primarily for use by the *teacher* of scientific writing. Nevertheless, sufficiently motivated students will be able to use this manual directly if no instructor is available.

The above material is mainly excerpted from the preface to the volume. It is not only recommended reading but every member of the Wildlife Disease Association is urged to study this book. It should prove helpful to all, writers, readers, and listeners alike, if you would follow its teachings when preparing your research observations for communication to your colleagues. — Carlton M. Herman.