

CAUSES OF BALD EAGLE MORTALITY, 1960–1965

Authors: COON, N. C., LOCKE, L. N., CROMARTIE, E., and REICHEL, W. L.

Source: Journal of Wildlife Diseases, 6(1) : 72-76

Published By: Wildlife Disease Association

URL: <https://doi.org/10.7589/0090-3558-6.1.72>

BioOne Complete (complete.BioOne.org) is a full-text database of 200 subscribed and open-access titles in the biological, ecological, and environmental sciences published by nonprofit societies, associations, museums, institutions, and presses.

Your use of this PDF, the BioOne Complete website, and all posted and associated content indicates your acceptance of BioOne's Terms of Use, available at www.bioone.org/terms-of-use.

Usage of BioOne Complete content is strictly limited to personal, educational, and non - commercial use. Commercial inquiries or rights and permissions requests should be directed to the individual publisher as copyright holder.

BioOne sees sustainable scholarly publishing as an inherently collaborative enterprise connecting authors, nonprofit publishers, academic institutions, research libraries, and research funders in the common goal of maximizing access to critical research.

CAUSES OF BALD EAGLE MORTALITY, 1960-1965

Introduction

Even though bald eagles (*Haliaeetus leucocephalus*) have been protected by Federal law since 1940, the continental population is apparently still declining, as indicated by recent nationwide surveys by the National Audubon Society (Sprunt and Ligas, 1966. Proc. 62nd Annual Convention, Nat. Audubon Soc., Sacramento, Calif.). In 1961 the Bureau of Sport Fisheries and Wildlife began investigations into the causes of this decline through studies of the effects of environmental pollution on eagles. Results of experimental studies with DDT have been discussed by Locke, Chura, and Stewart, (1966, Condor 68(5): 497-502), Stickel, *et al.* (1966, Trans. North

Amer. Wild. Conf. 31: 190-200), and Chura and Stewart (1967, Wilson Bull., 79(4): 441-448). Tissues from field collected eagles and eggs are analyzed for pesticide residue content at the Patuxent Wildlife Research Center as part of the National Pesticide Monitoring Program (Johnson, *et al.*, 1967, Pesticides Monitoring J., 1(1): 7-13). This paper reports necropsy results on 76 bald eagles that died during the period 1960-1965. The organochlorine residues in the 41 collected in 1964-1965 have been reported upon by Reichel, *et al.* (1969, Pesticides Monitoring J., 3(3): 142-144). Residue levels of those collected earlier were summarized by Stickel, *et al.* (*ibid.*).

Materials and Methods

Routine post-mortem examinations were performed. Eagles not skinned prior to arrival at the Patuxent Center were aged as either adult or immature on the basis of plumage; the main criterion was the presence of an all-white head. Twelve birds could not be sexed, either because tissue in the genital area had been destroyed by injury or because post-mortem changes were advanced. Carcasses and organs were weighed. Selected tissues were fixed in 10% formalin, embedded in paraffin, and sectioned. Sections were stained by hematoxylin and eosin, periodic-acid Schiff, Ziehl-Neelsen acid-fast, or Prussian blue techniques.

When an infectious agent was suspected, liver and/or heart blood was inoculated onto 5% sheep blood agar plates and incubated for 24 hours at 37.5 C. As the primary objective of this program was the determination of the organochlorine pesticide residues in the bald eagle tissues, the eagles were not necrop-

sied until the chemical analysis could be conducted. Consequently, the majority of the bald eagles discussed in this paper had been held in freezers for periods of several months (frequently 18 to 24 months) prior to necropsy. Attempts to isolate bacteriological agents were usually unsuccessful and the damage caused by the freezing and thawing of the tissues made meaningful histological interpretation of tissue sections largely impossible. Thus we believe that the prolonged storage was undoubtedly a major factor in our inability to make a diagnosis in 17 (22%) cases. Parasites were collected and preserved. For each eagle, the brain, liver, and carcass remains (all except the outer wing joints, skin, feet, and gastro-intestinal tract) were saved for chemical analysis. Laboratory procedures for the analysis of pesticide residues are described by Reichel, *et al.* (1969, Bull. Environ. Contamination and Tox., 4(1): 24-30).

Results

Sixty-four eagles were submitted from 21 of the contiguous states. An additional nine birds were from Alaska, and three were from Canadian provinces.

Of the 64 birds from the United States, exclusive of Alaska, 43 (67%) were from the eastern Great Plains states and the valleys of the Missouri and Mississippi Rivers (Fig. 1). Of these, 31 were recovered during November, December, January, and February. During the last winter census conducted by the National Audubon Society, that of January 1963, 55% of all bald eagles reported were in this same area (Sprunt and Ligas, 1963, Continental Bald Eagle Project, Nat. Audubon Soc., N.Y. Progress Report, 3: 1-6).

Thirty-two eagles (12 males, 17 females, and three of unknown sex) were classed as adults, 43 (14 males, 20 females, and nine of unknown sex) were immatures, and one (a male) could not be aged. In all, 37 were females, 27 males, and 12 could not be sexed.

Causes of Death

These 76 bald eagles, although a substantial number, by the very nature of their collection, cannot be taken to represent a random sample of the total population. Consequently, the causes of death diagnosed in this sample may not be representative. Further, determination of cause of death cannot be assumed to explain why eagles are declining, for many other factors, including reproductive success, determine the status of a population. Determinations of cause of death, however, indicate that several factors, including gunshot wounds or other trauma, parasitism, bacterial infection, and pesticide poisoning, have been involved (Table 1).

Trauma was the most frequent cause of death, with gunshot injury taking the largest toll (62%). Of 55 bald eagles which died of injuries, 45 had been shot, seven had impact injuries, two were trapped, and one was electrocuted. Of those shot, 15 were adults, 29 were immatures, and one could not be aged. Even though twice as many immatures as white-headed adults (29 as compared

to 15) had been shot, it is evident that shooting has not always been the result of mistaken identity. In general, eagles that had been shot were in good condition, fat, and carried low levels of pesticide residues. There were no statistically significant differences between pesticide residues in shot birds and in birds that died of other causes ($P < 0.05$; analysis of variance on log-transformed data). In only one eagle was the parasitic burden believed to have been responsible for mortality. An adult female found ill near Cairo, Nebraska, on November 12, 1965, died in captivity 2 days later. When necropsied, the eagle weighed 7 pounds (3.2 kilos), had no abdominal or subcutaneous fat, and had breast muscles greatly atrophied. Enteritis was present, and large numbers of coccidial oocysts were found in the lumen of the small intestine; however, attempts to sporulate these oocysts were unsuccessful. Pesticide residue levels in this eagle were too low for these chemicals to have been responsible for death. The pesticide residues in ppm in the brain of this bird were dieldrin, 0.8; pp' DDD, -0.4; p, p' - DDE, 8.9; p p' - DDT, none detectable. Coccidial oocysts were found also in another adult female eagle from Nebraska and in an immature male from Michigan, but they were not believed to be the cause of death.

A bipolar staining, Gram - negative, non-hemolytic cocci-bacillus was isolated from the heart, liver, and lungs of an adult female eagle found dead in Otoe County, Nebraska, on February 19, 1965. Although insufficient biochemical tests were performed to completely characterize this isolate, we believe the bacterium to be *Pasteurella multocida*. In addition, this eagle had significant levels of dieldrin (3.9 ppm) in its brain. This level of dieldrin in the brain is somewhat below the 4 to 5 ppm (wet weight) level reported by Stickel, Stickel, and Spann (1968, Chemical Fallout: Current Research on Persistent Pesticides, First Rochester Conf. on Toxicity, June 4-6) as indicating that a bird has died of dieldrin poisoning. It is possible that the

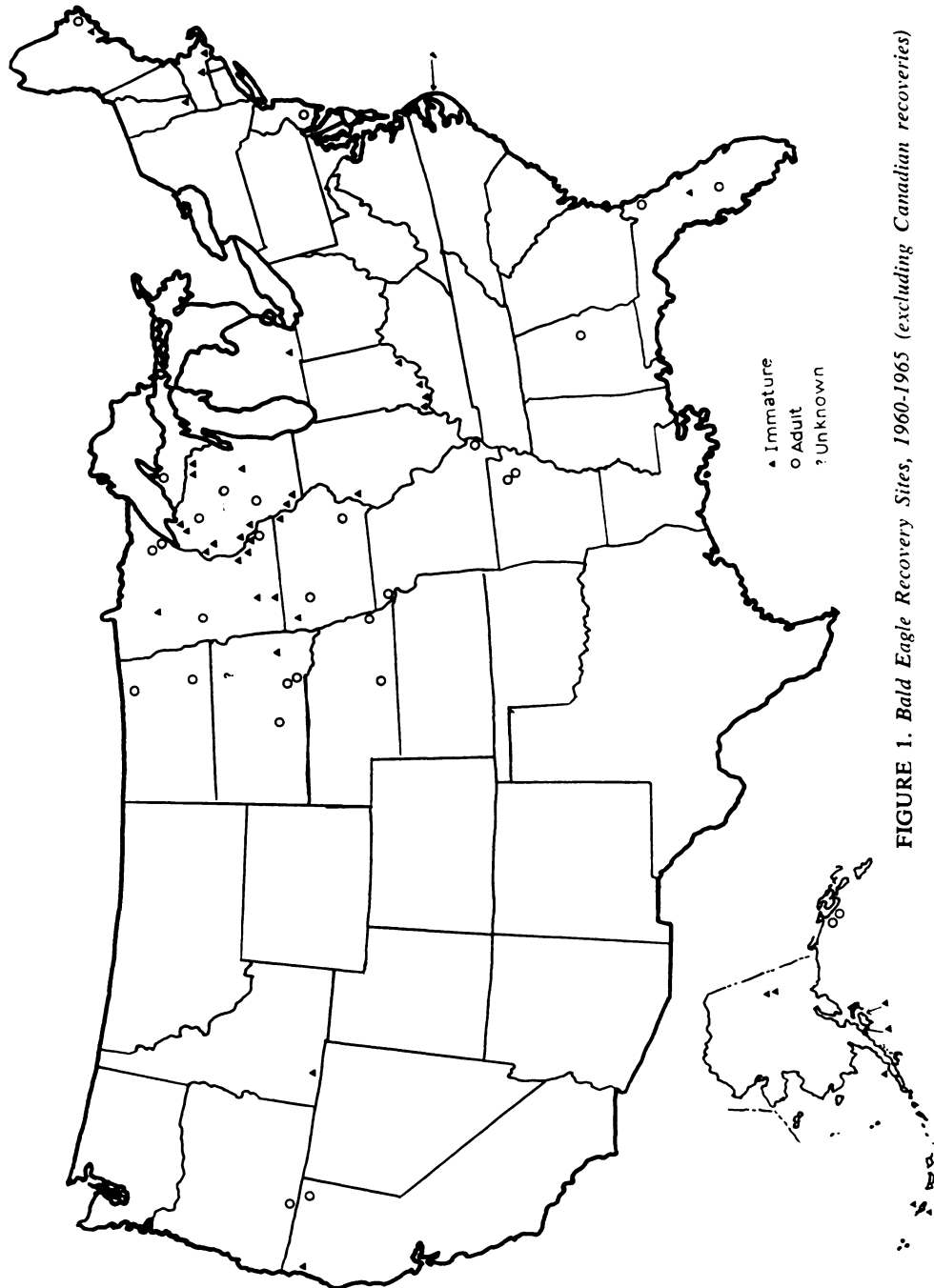


FIGURE 1. Bald Eagle Recovery Sites, 1960-1965 (excluding Canadian recoveries)

TABLE 1. Causes of Bald Eagle Mortality, 1960-1965

Year	Age	Sex	No. of Birds	Cause of Death
1960	Adult	Female	1	No cause determined
1961	Adult	Female	1	Impact
	Adult	Unknown	1	Shot
	Immature	Female	1	No cause determined
1962	Adult	Female	1	Shot
	Adult	Female	1	No cause determined
1963	Adult	Female	3	No cause determined
	Adult	Female	2	Shot
	Adult	Female	1	Trapped (+hemorrhagic enteritis)
	Adult	Female	1	Impact
	Adult	Male	1	No cause determined
	Adult	Unknown	1	Shot
	Immature	Female	1	Shot
	Immature	Female	1	No cause determined
	Immature	Unknown	2	Shot
	1964	Adult	Female	1
Adult		Male	1	Shot
Adult		Male	1	No cause determined
Immature		Female	3	Shot
Immature		Female	1	Dieldrin poisoning suspected
Immature		Female	1	No cause determined
Immature		Male	1	Shot
Immature		Male	1	No cause determined (impacted cloaca)
Immature		Unknown	1	Shot
Immature		Unknown	1	Impact
Unknown		Male	1	Shot
1965	Adult	Female	3	Shot
	Adult	Female	1	Fowl Cholera
	Adult	Female	1	Possible coccidiosis
	Adult	Male	5	Shot
	Adult	Male	4	No cause determined (one with acute intestinal obstruction)
	Adult	Unknown	1	Trapped
	Immature	Female	9	Shot
	Immature	Female	2	Impact
	Immature	Female	1	No cause determined
	Immature	Male	8	Shot
	Immature	Male	2	Impact
	Immature	Male	1	Electrocuted
	Immature	Male	1	No cause determined (?bacterial infection)
	Immature	Unknown	4	Shot
	Immature	Unknown	1	No cause determined

death of the bird was caused by the combined effects of the bacterial infection and dieldrin intoxication.

One eagle, a thin, immature female, which was found dead beneath a known roosting tree near Vernon, Vermont, on April 30 or May 1, 1964, had no injuries or other lesions noted at necropsy. Chemical analysis revealed 8.0 ppm of dieldrin in brain tissues, suggesting that the eagle died of dieldrin intoxication (Stickel, *et al.*, 1968). This is the same bald eagle discussed by Stickel *et al.* (1966).

Three eagles, one each from Minnesota, Wisconsin, and Michigan, had enteritides of unknown etiology. The Minnesota eagle, an adult female, had been captured in a wolf trap in Mille Lacs County during December 1963, and therefore died as a result of trauma; however, in addition, it had hemorrhagic enteritis of the small intestine.

An adult male was found alive but too weak to fly near Winter, Wisconsin,

on January 23, 1965. Although given vitamins and antibiotics, the eagle failed to recover and died after a few days in captivity. At necropsy, a large, oblong fecalith, 65 mm x 35 mm, was obstructing the colon, which was necrotic. The cloaca also was obstructed by a hard spherical mass of concentric layers of urates and fecal material.

The cloaca of an immature male eagle, found dead in Washtenaw County, Michigan, during October 1964, was impacted with a spherical hard mass of urates and fecal material.

Although trauma, primarily by shooting, is the greatest cause of mortality among the bald eagles examined in our laboratory, there are other factors such as low levels of pesticides or their metabolites which may be major factors in explaining the decrease of the bald eagle population. Recent work has shown that non-lethal amounts of DDE can cause the production of thin shelled eggs in sparrow hawks and mallards.

Acknowledgements

The eagles included in this report were submitted to the Patuxent Wildlife Research Center by 41 different cooperators throughout the United States. Outstanding among these were U.S. Game Management agents of the Bureau of Sport Fisheries and Wildlife and other employees of the Federal and State governments. R. Romero performed certain of the necropsy examinations. L. Young prepared the tissues for microscopic examinations. V. Adomaitis, G. Bagley, T. Lamont, C. Menzie, B. Mulhern, and R. Prouty participated in the chemical analyses of specimens. L. F. Stickel offered many helpful suggestions during the preparation of this manuscript.

N. C. COON, L. N. LOCKE, E. CROMARTIE, and W. L. REICHEL

*Patuxent Wildlife Research Center
Bureau of Sport Fisheries and Wildlife
Laurel, Maryland 20810*

August 20, 1969.