

VERMINOUS PNEUMONIA IN THE CALIFORNIA SEA LION (*Zalophus californianus*)

Authors: MORALES, G. A., and HELMBOLDT, C. F.

Source: Journal of Wildlife Diseases, 7(1) : 22-27

Published By: Wildlife Disease Association

URL: <https://doi.org/10.7589/0090-3558-7.1.22>

The BioOne Digital Library (<https://bioone.org/>) provides worldwide distribution for more than 580 journals and eBooks from BioOne's community of over 150 nonprofit societies, research institutions, and university presses in the biological, ecological, and environmental sciences. The BioOne Digital Library encompasses the flagship aggregation BioOne Complete (<https://bioone.org/subscribe>), the BioOne Complete Archive (<https://bioone.org/archive>), and the BioOne eBooks program offerings ESA eBook Collection (<https://bioone.org/esa-ebooks>) and CSIRO Publishing BioSelect Collection (<https://bioone.org/csiro-ebooks>).

Your use of this PDF, the BioOne Digital Library, and all posted and associated content indicates your acceptance of BioOne's Terms of Use, available at www.bioone.org/terms-of-use.

Usage of BioOne Digital Library content is strictly limited to personal, educational, and non-commercial use. Commercial inquiries or rights and permissions requests should be directed to the individual publisher as copyright holder.

BioOne is an innovative nonprofit that sees sustainable scholarly publishing as an inherently collaborative enterprise connecting authors, nonprofit publishers, academic institutions, research libraries, and research funders in the common goal of maximizing access to critical research.

VERMINOUS PNEUMONIA IN THE CALIFORNIA SEA LION (*Zalophus californianus*)

Parafilaroides decorus has been recognized since 1947 as a pulmonary parasite of the California sea lion (Dougherty and Herman, 1947, Proc. Helm. Soc., Wash. 14: 77-87). The life cycle of this parasite remained unknown until recently when the opaleye fish (*Girella nigricans*) was

suggested as an intermediate host (Dailey, 1969, Abs. Am. Soc. Par. 76: 46-47).

The purpose of this paper is to describe the histopathologic changes seen in the lungs of two infected captive sea lions, and to correlate them with the proposed life cycle of the parasite.

Case Histories

Case 1.

A 9-month-old male California sea lion was submitted to the Department of Animal Diseases, University of Connecticut, Storrs, for necropsy. The animal had died at the Sherwood Forest Zoo, Hartford, Conn., after showing signs of respiratory distress.

Gross pathology: External examination revealed an animal in fair nutritional condition. The lungs were congested. The diaphragmatic lobes had several dark purple depressed patches surrounded by minute emphysematous bullae, intermingled with numerous white foci 0.3 to 0.5 cm in diameter which were seen also in cut sections throughout the parenchyma. The apical and cardiac lobes were less involved. No other gross abnormality was seen in the remaining visceral organs or skin.

Histopathology and parasitology: The lungs were fixed by infusion of 10% formalin via the trachea, embedded in paraffin, sectioned, and stained with hematoxylin and eosin (H & E). The remaining organs were fixed in formalin and treated in the same manner.

Examination of the lungs revealed well defined groups of parasites (the mature females containing high numbers of embryos in uteri), surrounded by a slight granulomatous inflammatory reaction composed of histiocytes, a few plasma cells, and lymphocytes (Figs. 1, 2). The

major bronchi and bronchioles contained a fibrinous exudate, mixed with pieces of larvae, neutrophils, and cellular debris (Fig. 3); adjacent alveoli had thickened and congested walls, their lumina were flooded with a homogeneous pink exudate containing numbers of neutrophils and mononuclear cells. Alveolar hemorrhages were also present and larvae were seen breaking through the walls of alveoli. Subpleural, septal, and interlobular edema were common features (Fig. 4). Noteworthy was the almost complete absence of eosinophils in the inflammatory reaction. No lesions were seen in the other organs examined, yet microfilarid larvae were seen in the brain, kidney, liver, and lung capillaries (Fig. 5). At no time did these larvae cause any tissue reaction.

A hemolytic streptococcus was isolated on blood agar inoculated with lung material.

Following histopathologic examination, formalized lung tissue was examined for parasites. The parenchyma was teased apart and the white nodules dissected out. Each nodule consisted of 2 to 5 coiled nematodes surrounded by a glossy white membrane. They were identified as *P. decorus* (Dougherty and Herman, *op. cit.*) by Dr. L. Penner and R. Eckerlin of the Department of Parasitology, University of Connecticut, Storrs.

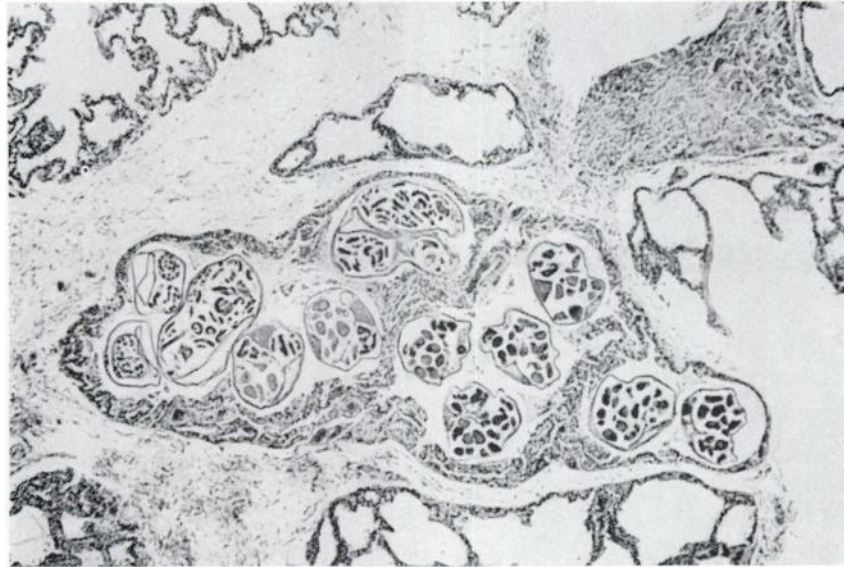

FIGURE 1. Well-defined group of female parasites in the lung parenchyma. Note numerous embryos in uteri and the slight inflammatory reaction. X 30.

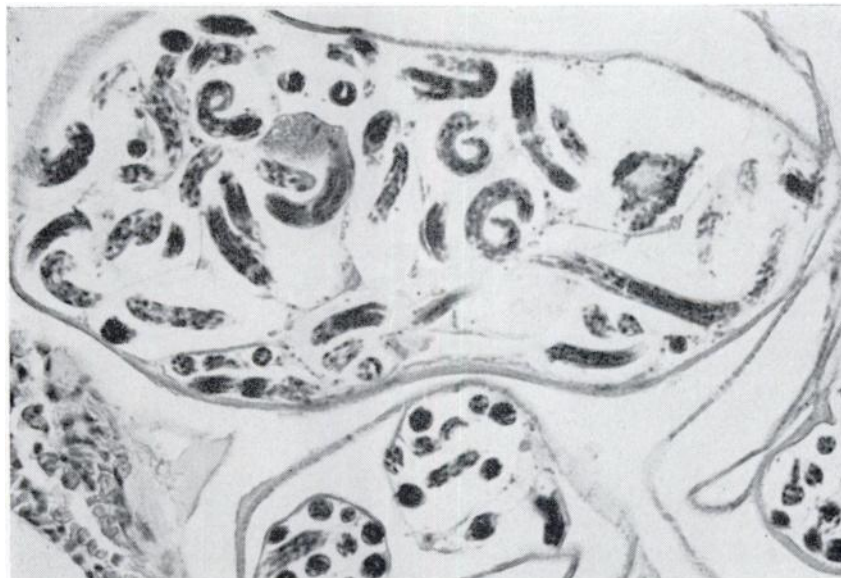

FIGURE 2. Higher magnification of Figure 1. X 480.

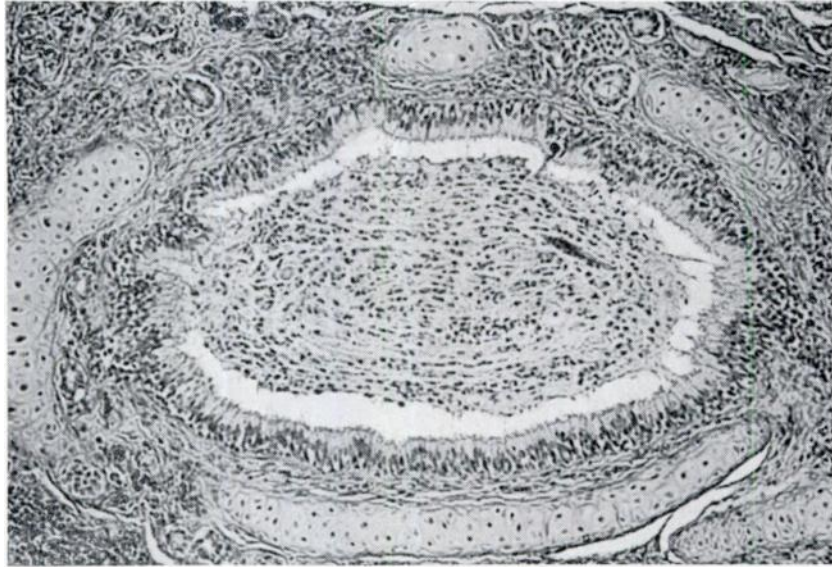


FIGURE 3. *Bronchus of a sea lion with a thick fibrinous exudate containing polymorphonuclear cells and a small piece of larva. X 190.*

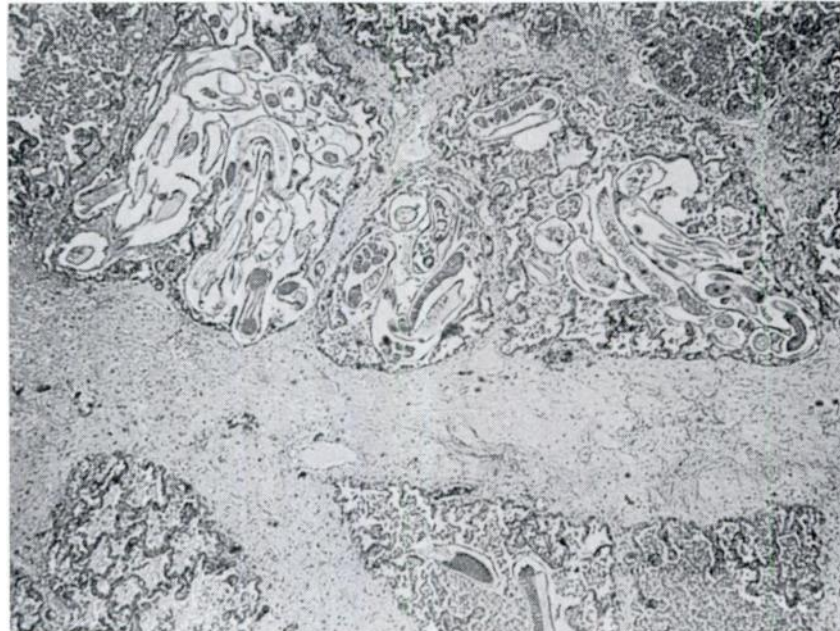


FIGURE 4. *Lung with several groups of parasites and severe interlobular edema with a fibrinous background. X 30.*

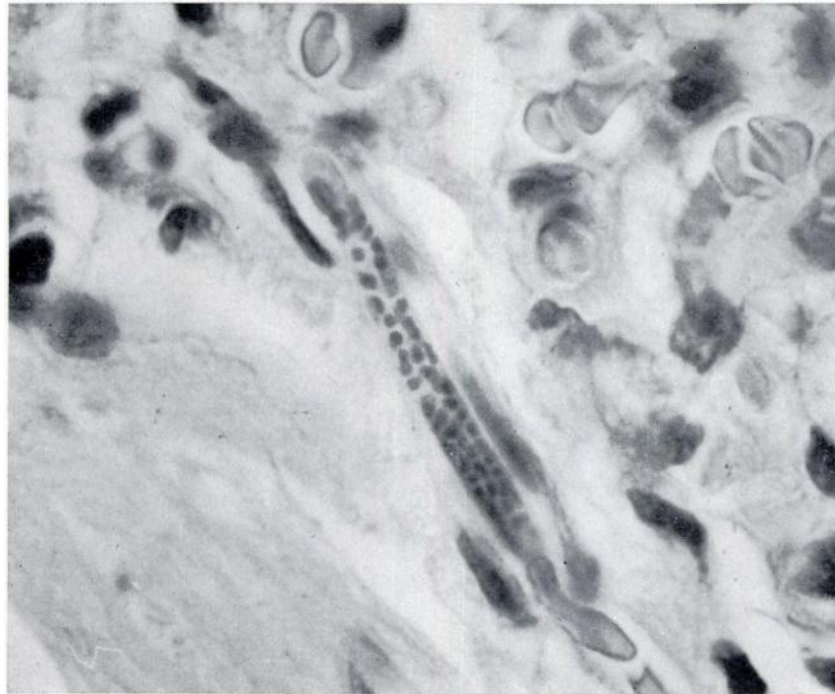


FIGURE 5. *Microfilarid larva in lung capillary. X 1,200.*

Case 2.

An 18-month-old female California sea lion died at the same location (Sherwood Forest Zoo, Hartford, Conn.) and was submitted for necropsy. The animal had been sick for 2 weeks with vomiting and increasing loss of weight.

At necropsy the trachea and bronchi contained a thick fibrinous exudate. Other gross and parasitologic findings were similar to those seen in the previous case. A coagulase positive staphylococcus was isolated on blood agar inoculated with lung material.

Tissues for histopathology were treated

in the same manner as those in Case 1.

Microscopic examination of the lungs revealed a more severe granulomatous reaction around the mature parasites. The lumen of adjacent alveoli contained numerous macrophages and foreign body giant cells in the process of engulfing pieces of larvae and cellular debris (Fig. 6). Neutrophils and eosinophils were scattered throughout the parenchyma. The major bronchi and bronchioles were filled with a thick fibrinous exudate containing inflammatory cells and pieces of larvae.

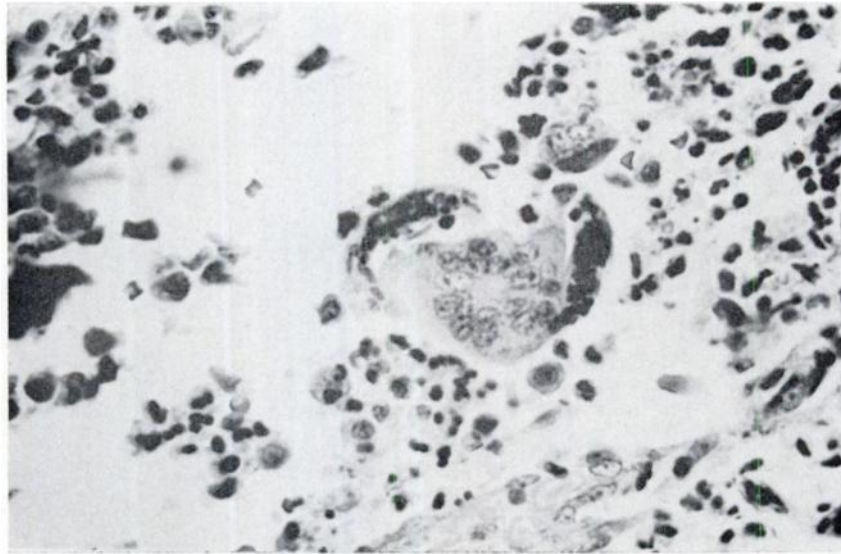


FIGURE 6. Numerous alveolar macrophages and giant cells in the process of engulfing pieces of larvae. X 480.

Discussion

Verminous pneumonia in captive pinnipeds has been reported on several occasions. However, identification of the parasites involved, description and evaluation of histopathologic findings have not been reported (Brown *et al.*, 1960, J. Am. Vet. Med. Assoc. 137: 534-538; Wolinski and Landowski, 1962, Nord. Vet.-Med., Suppl. 1, 14: 125-137; Van Haaften, 1962, Nord. Vet.-Med., Suppl. 1, 14: 138-140; Menschel *et al.*, 1966, Berl. U. Münch. tierarztl. Wochschr. 79: 333-337; Johnson and Ridgway, 1969, J. Am. Vet. Med. Assoc. 155: 1064-1072; Wilson *et al.*, 1969, Bull. Wildlife Dis. Assoc. 5: 412-418).

The pathologic changes observed in Case 1 were of an acute nature. It seems likely that the animal was overwhelmed by the massive migration of the first stage larvae on their way to bronchioles, causing hemorrhage and inflammation, creating a suitable environment for the invasion of pathogenic bacteria. The almost complete absence of eosinophils and giant

cells in the inflammatory reaction could be explained on the grounds of the overwhelming destruction of lung tissue by the migration of the first stage larvae, coupled by the secondary bacterial invasion leading to an acute death, and also possibly to the absence of age hypersensitivity to the adult worms and larvae.

Case 2 represents an older animal in which the cellular reaction consisting mainly of alveolar macrophages, foreign body giant cells, and eosinophils could be explained on the grounds of a developing resistance due to past experience with the parasite, or to the possibility of a primary low parasitic infestation as it would allow the building up of a resistance to the injurious parasites, but predisposing the animal to the action of secondary pathogenic bacteria.

The microfilaria seen in the brain, kidney, liver, and lung could not be identified. Since no parasites were seen in the right cardiac ventricle or under

the skin (although the authors realize the difficulty existing in finding some of them), it was assumed that *Dirofilaria immitis* and *Dipetelonema* spp. were not the cause of the microfilaremia. The possibility of aberrant forms of *P. decorus* became attractive but not supportable.

This study has raised some questions that offer challenging opportunities for research:

1. Is verminous pneumonia caused by *P. decorus* a self-limiting infection in

captive pinnipeds, due to the absence of the proposed intermediate host (*Girella nigricans*) in zoo pools?

2. If the parasite persists in captive pinnipeds, is it because it has a direct life cycle also, or because other fish fed to them, or crustacea (e.g., copepods) could also serve as intermediate hosts?

3. How do larvae migrate from the intestinal tract to their final destination in the lungs — through lymphatics or portal circulation?

Acknowledgements

The authors wish to thank Dr. L. R. Penner and Mr. R. Eckerlin of the Department of Parasitology, University of Connecticut, for their valuable assistance in the identification of the parasites.

Scientific Contribution No. 422, Storrs Agricultural Experiment Station, University of Connecticut, Storrs 06268.

G. A. MORALES and

C. F. HELMBOLDT

Department of Animal Diseases

University of Connecticut

Storrs, Connecticut 06268

April 20, 1970
