

FURTHER STUDIES ON “LIMEY-DISEASE” OF TASMANIAN MUTTON BIRDS (*Puffinus tenuirostris*)

Authors: MUNDAY, B. L., MASON, R. W., WELLS, R. J. H., and
ARUNDEL, J. H.

Source: Journal of Wildlife Diseases, 7(2) : 126-129

Published By: Wildlife Disease Association

URL: <https://doi.org/10.7589/0090-3558-7.2.126>

The BioOne Digital Library (<https://bioone.org/>) provides worldwide distribution for more than 580 journals and eBooks from BioOne's community of over 150 nonprofit societies, research institutions, and university presses in the biological, ecological, and environmental sciences. The BioOne Digital Library encompasses the flagship aggregation BioOne Complete (<https://bioone.org/subscribe>), the BioOne Complete Archive (<https://bioone.org/archive>), and the BioOne eBooks program offerings ESA eBook Collection (<https://bioone.org/esa-ebooks>) and CSIRO Publishing BioSelect Collection (<https://bioone.org/csiro-ebooks>).

Your use of this PDF, the BioOne Digital Library, and all posted and associated content indicates your acceptance of BioOne's Terms of Use, available at www.bioone.org/terms-of-use.

Usage of BioOne Digital Library content is strictly limited to personal, educational, and non-commercial use. Commercial inquiries or rights and permissions requests should be directed to the individual publisher as copyright holder.

BioOne is an innovative nonprofit that sees sustainable scholarly publishing as an inherently collaborative enterprise connecting authors, nonprofit publishers, academic institutions, research libraries, and research funders in the common goal of maximizing access to critical research.

FURTHER STUDIES ON "LIMEY-DISEASE" OF TASMANIAN MUTTON BIRDS (*Puffinus tenuirostris*)

B. L. MUNDAY*, R. W. MASON*, R. J. H. WELLS** and J. H. ARUNDEL**

Abstract: "Limey-disease" of mutton birds has been shown to be a form of nephritis probably associated with infection of the ureters and collecting ducts by a coccidium. The parasite has been identified as an *Eimeria* sp., but does not appear to be identical with other avian, renal coccidia.

INTRODUCTION

The short-tailed shearwater (*Puffinus tenuirostris*) or Tasmanian mutton bird is a transequatorial migrant which nests during the southern summer in south-eastern Australia with the center of breeding distribution in the Bass Strait Islands. During the autumn months, just prior to the departure of these birds for the northern hemisphere, the young, as-yet-flightless birds are removed from their burrows by seasonal workers, and processed to provide "squab" carcasses, feathers for "down" sleeping bags, etc., and oil for medicinal purposes. Despite the facts that some hundreds of thousands of chicks have been taken annually for many years, that the adults are late-maturing and that the female lays only one egg per year, the population of mutton birds is not decreasing, and consequently the industry should continue to be of some economic importance in the immediate future.

However, between one and five percent of the chicks are affected by "limey-disease" which is characterized by soiling of the vent feathers by whitish ("limey") excrement, and frequently also by loss of bodily condition. The number of diseased birds varies with seasons and location. It is asserted by processors that the disease is more prevalent in wet seasons, and is particularly common in those parts of the rookeries which are low-lying and heavily overgrown by vegetation.

The disease is a cause of economic loss, not only because of the loss of one to five percent of the birds caught, but also because the inclusion of diseased carcasses in with marketable birds is claimed to taint the whole consignment (carton pack, if fresh, or barrel, if salted).

Over a period of years a number of workers^{7,9,10,11} have studied "limey disease", and have established that the condition is a form of nephritis, leading to uricaemia and, in some cases, the formation of urate-concretions in the cloaca. These investigators have found that the disease is probably not caused by starvation or by infection with certain bacteria and *Chlamydia* spp., but some slight evidence has been accumulated to suggest that an infectious bronchitis (IB)-type virus might be implicated.

The investigations, to be described, were undertaken to further study the possible viral etiology of the disease, and to examine the birds for other possible causes of the kidney lesions.

MATERIALS AND METHODS

During 1969 twenty mutton birds, believed to be suffering from limey disease, were collected on Big Dog Island (Furneaux Group, Bass Strait), frozen and dispatched to Mt. Pleasant Laboratories, where they were thawed and tissues prepared for inoculation into embryonated fowl eggs for the detection of *Chlamydia*

* Mt. Pleasant Laboratories, P.O. Box 46, Launceston South, Tasmania, Australia.

** Faculty of Veterinary Science, University of Melbourne, Parkville, Victoria, Australia.

spp.¹⁰ and IB-type viruses.² Tissues were also retained for histopathology.

In 1970 one of the authors (BLM) collected seventeen "limey birds" and examined them in the field, returning to the laboratory with samples (in Hanks SSS with antibiotics) for virus isolation, and histopathology. In this instance the material for virus isolation was passaged in both embryonated fowl eggs and chick-embryo kidney cells.⁶ Kidneys from more birds were later collected by co-operators on Big Dog Island and forwarded to the laboratory either fresh or preserved in formal saline; no virological examinations were carried out on these samples.

RESULTS

1. Isolation of Viruses and *Chlamydia*

No viruses or *Chlamydia* were detected in any of the tissues examined.

2. Gross Pathology

Not all birds discarded by the processors as being "limey", exhibited typical lesions, and it is probable that the term is used to cover a number of disease entities. The majority of chicks did have lesions indistinguishable to those reported by previous authors,^{7,11} namely one or more of the following, soiling of the vent feathers by granular, white excrement, yellowish (instead of white) fat, shrunken musculature, enlarged, pale kidneys, distended ureters and distention of the intestines as a result of accumulation of urates (two samples were composed of 80% uric acid) in the cloaca.

3. Microscopic Pathology

As noted by Munday⁷ no specific lesions were detected outside the urinary system, where inflammation of the ureters and collecting ducts was the most characteristic change. However, in the latest investigations, coccidial parasites were found in the intrarenal ureters and collecting ducts. In one instance one of the organisms was detected in a distal tubule cell. The degree of infestation varied from the presence of a few oocysts in the epithelial cells and lumina of these

ducts to distention of the ureters with oocysts. Sexual stages of the coccidium were also detected, but in smaller numbers than oocysts.

Twenty-two of the specimens collected in 1970 were both suitable for histopathological examination and had lesions of the renal system. Coccidia were detected in nine of these. Retrospective examination of the 1969 samples revealed coccidia in one of the kidneys with inflammatory changes. It should be mentioned that these latter samples were of poor quality because of freezing and subsequent thawing, and in addition, in many instances, the gross lesions were not typical of limey disease.

Lesions were noted in the walls and supporting tissues of the intrarenal and proximal extrarenal ureters, and less often, the collecting ducts. The more acute changes consisted of edema and infiltration of the tissues by heterophiles, lymphocytes and plasma cells. This stage merged into one in which there was an absence of heterophiles, with, in some instances, an admixture of large mononuclear cells or a predominance of plasma cells. The process then became dominated by lymphocytes with finally the formation of lymphoid follicles in the walls and adventitia of the ureters. The ureteral epithelial cells tended to degenerate and desquamate, sometimes forming cellular casts. In a few birds there were foci of chronic interstitial nephritis, and the kidneys of one which had a cloacal concretion were affected by a typical uric-acid nephrosis.

4. Morphology of Isolated Coccidia

Oocysts were collected from unpreserved kidneys, and had the following characteristics.

The oocysts were round or subspherical. Based on measurements of 30 oocysts, they ranged from 25.2 to 31.2 μ in length by 22.7 to 30.9 μ in width and averaged 27.6 μ by 26.3 μ . The wall was smooth and a micropyle was not present.

Each sporulated oocyst contained four small sporocysts 9.5 μ by 5.7 μ and a large residual body 10.7 μ by 10.4 μ . The general impression gained on examination of the sporulated oocysts was that of a

large oocyst with four very small sporocysts, a large residual body and a great deal of space in the oocyst.

Each sporocyst contained two sporozoites which is characteristic of *Eimeria*.

On the basis of these findings it was decided that the parasite was an *Eimeria* sp., but further identification was not possible as the organism does not appear to have been previously described.

The parasite is illustrated in Figure 1.

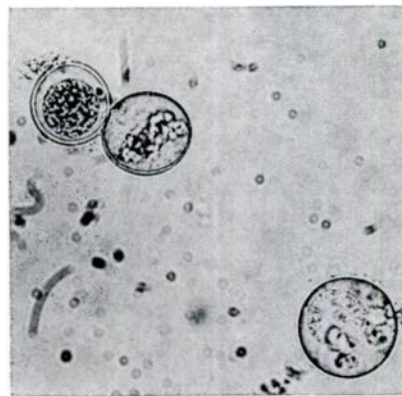


Figure 1. Oocysts obtained from the kidneys of *Puffinus tenuirostris* X 400.

DISCUSSION

Although the present studies have not permitted an unequivocal case to be established for the definition of "limey disease" as a form of avian renal coccidiosis, there is good evidence to support the premise that an *Eimeria* sp. is the cause of this condition. Starvation, aerobic bacteria, *Chlamydia* spp. and IB-type viruses do not appear to be involved in the etiology of the disease^{7,9,10,11} whereas fairly good correlation was found between the occurrence of renal coccidiosis and "limey disease".

The coccidium itself is markedly different from *E. truncata*,⁸ *E. somateriae*¹ and the unnamed species occurring in the woodcock (*Philohela minor*).⁸ Comparison with renal coccidia of the great-horned owl (*Bubo virginianus*)¹ and Cory's shearwater (*Puffinus diomedea*)⁸ is not possible as details of the oocysts of these coccidia are not available.

There remains much to be done to establish unequivocally that "limey disease" is caused by a renal coccidium, and the epidemiology of the infection poses many intriguing questions, especially as the birds are absent from the breeding area for some five months of the year.

Acknowledgements

The authors wish to thank Mr. and Mrs. F. Willis of Flinders Island for assistance in the collection of samples, and Mr. G. Goodsall for technical help.

LITERATURE CITED

1. CHRISTIANSEN, M. 1952. Nyrecoccidiose hos vildtevende andefugle (Anseriformes). *Eimeria somateriae* n. sp. hos ederfugl [*Somateria mollissima* (L.)]. Nord. Vet. Med. 4: 1173-1191.
2. CUMMING, R. B. 1963. Infectious avian nephrosis (uraemia) in Australia. Aust. vet. J. 39: 145-147.
3. DAVIES, S. F. M., L. P. JOYNER, and S. B. KENDALL. 1963. Coccidiosis. Oliver & Boyd, Edinburgh & London, 264 pp.
4. HELMBOLDT, C. F. 1967. An unidentified protozoan parasite in the kidney of the great-horned owl (*Bubo virginianus*). Bull. Wildlife Disease Assoc. 3: 23-25.
5. HOWES, D. W., G. A. TANNOCK, and B. SINKOVIC. 1962. The assessment of a potency standard for infectious laryngotracheitis vaccine in dose-response experiments. Proc. Wld. Poult. Sci. Cong. 12: 344-348.
6. LOCKE, L. M., W. H. STICKEL, and S. A. GEIS, 1965. Some diseases and parasites of captive woodcock. J. Wildlife Management. 29: 156-161.

7. MUNDAY, B. L. 1966. Diseases of Tasmania's Free-living Animals. Tas. Dept. Agric. Res. Bull. No. 5. 29 pp.
8. MUNDAY, B. L. 1970. Unpublished data.
9. MUSHIN, R., and F. M. ASHBURNER. 1962. Gastrointestinal microflora of mutton birds. (*Puffinus tenuirostris*) in relation to "limey" deasese. J. Bact. 83: 1260-1267.
10. MYKYTOWYCZ, R., D. SURREY-DANE, and M. BEECH. 1955. Ornithosis in the Petrel, *Puffinus tenuirostris* (Temminck). Austral. J. Exp. Biol. 33: 629-636.
11. MYKYTOWYCZ, R. 1963. "Limey-bird disease" in chicks of the Tasmanian mutton-bird (*Puffinus tesuirostris*). Avian Diseases. VII: 67-79.

Received for publication December 30, 1970
