

## GASTRIC LESIONS IN THE SNOWSHOE HARE 1

Authors: IVERSEN, J. O., HOFF, G. L., YUILL, T. M., and HANSON, R. P.

Source: Journal of Wildlife Diseases, 8(1) : 7-9

Published By: Wildlife Disease Association

URL: <https://doi.org/10.7589/0090-3558-8.1.7>

---

The BioOne Digital Library (<https://bioone.org/>) provides worldwide distribution for more than 580 journals and eBooks from BioOne's community of over 150 nonprofit societies, research institutions, and university presses in the biological, ecological, and environmental sciences. The BioOne Digital Library encompasses the flagship aggregation BioOne Complete (<https://bioone.org/subscribe>), the BioOne Complete Archive (<https://bioone.org/archive>), and the BioOne eBooks program offerings ESA eBook Collection (<https://bioone.org/esa-ebooks>) and CSIRO Publishing BioSelect Collection (<https://bioone.org/csiro-ebooks>).

Your use of this PDF, the BioOne Digital Library, and all posted and associated content indicates your acceptance of BioOne's Terms of Use, available at [www.bioone.org/terms-of-use](http://www.bioone.org/terms-of-use).

Usage of BioOne Digital Library content is strictly limited to personal, educational, and non-commercial use. Commercial inquiries or rights and permissions requests should be directed to the individual publisher as copyright holder.

---

BioOne is an innovative nonprofit that sees sustainable scholarly publishing as an inherently collaborative enterprise connecting authors, nonprofit publishers, academic institutions, research libraries, and research funders in the common goal of maximizing access to critical research.

## GASTRIC LESIONS IN THE SNOWSHOE HARE<sup>1</sup>

J. O. IVERSEN<sup>2</sup>, G. L. HOFF<sup>3</sup>, T. M. YUILL<sup>3</sup>, R. P. HANSON<sup>3</sup>

**Abstract:** During routine necropsies of snowshoe hares, *Lepus americanus*, captured in north-central Alberta, lesions in the glandular portion of the stomach were observed in 34.5% (444/1286) of trapped hares as opposed to 10% (12/120) of snared hares and 0% (0/10) of shot hares. Among the trapped hares, gastric lesions were almost twice as common in juveniles as in adults, 43.7% (293/670) and 24.5% (151/616) respectively. There was no significant differences in the frequency of lesions between sexes. A gross and a microscopic description of the lesions are presented.

### INTRODUCTION

The vulnerability of the snowshoe hare to stressors (i.e., noxious stimuli) was suggested by reports on "shock disease"<sup>1</sup> and "trap sickness".<sup>1,4</sup> "Shock disease", a pathological condition with depletion of glycogen stores of the liver and hypoglycemia, was reported to have been associated with a decline in numbers of the snowshoe hare during the 1930's in Minnesota and was hypothesized to be responsible for the die-off of the snowshoe hare throughout its range in North America. Selye<sup>10</sup> considered "shock disease" of the snowshoe hare to be a manifestation of the general adaptation syndrome. Although the gross and microscopic pathology of "shock disease" was described in detail, mention was not made of gastric lesions.<sup>1</sup> The "trap sickness" syndrome of the snowshoe hare is a confinement phenomenon associated with terminal features (viz., hypoglycemic shock) similar to those described for "shock disease".<sup>1,4</sup> Although the reports on "trap sickness" do not mention hemorrhagic erosions or ulcers in the stomachs of snowshoe hares, these lesions were observed in the present study, in hares with the "trap sickness" syndrome.

### MATERIALS AND METHODS

The capture and handling of live snowshoe hares has been previously described.<sup>7,8,9</sup>

### RESULTS

During routine necropsies of snowshoe hares captured in north-central Alberta, lesions in the glandular portion of the stomach were observed in 34.5% (444/1286) of trapped hares as opposed to 10% (12/120) of snared hares and 0% (0/10) of shot hares. Among the trapped hares, gastric lesions were almost twice as common in juveniles as in adults, 43.7% (293/670) and 24.5% (151/616) respectively. There was no significant differences in the frequency of lesions between sexes.

Grossly, the lesions were brown to black depressed areas in the glandular region of the stomach (Figure 1). The lesions of the gastric mucosa were often multiple and varied from less than 1 mm in diameter to elongated erosions, 2 mm by 6-20 mm. The annular lesions were located frequently on top of rugae, had a brownish center circumscribed by a tanish yellow, and penetrated deeply into the mucosa. Some long linear black erosions occurred adjacent to and at the base of rugae. The entire mucosal surface of the fundic region frequently appeared red while the antrum appeared a pinkish white. The lesions were frequently associated with stomach contents that were: 1) fluid to semi-solid, 2) viscid, 3) clear to yellow-green, and 4) relatively free of ingesta.

<sup>1</sup> Supported in part by NIH grants AI00175 and AI00771.

<sup>2</sup> Present address: School of Veterinary Medicine, University of Saskatchewan, Saskatoon, Sask.

<sup>3</sup> Department of Veterinary Science, University of Wisconsin, Madison, Wisconsin 53706.

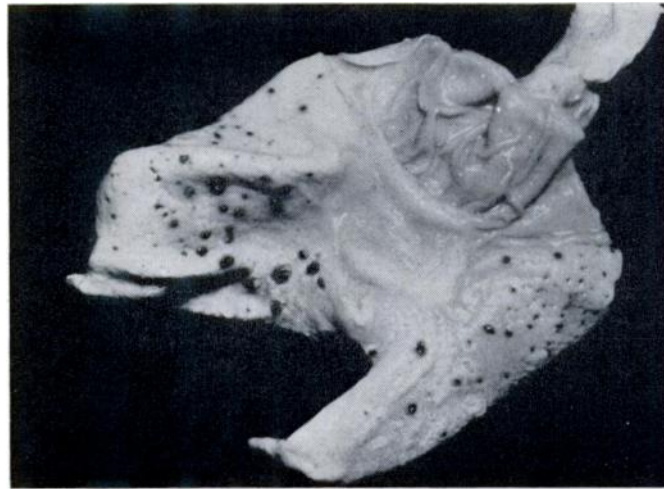


FIGURE 1. Multiple lesions in the glandular region of the stomach of a snowshoe hare.

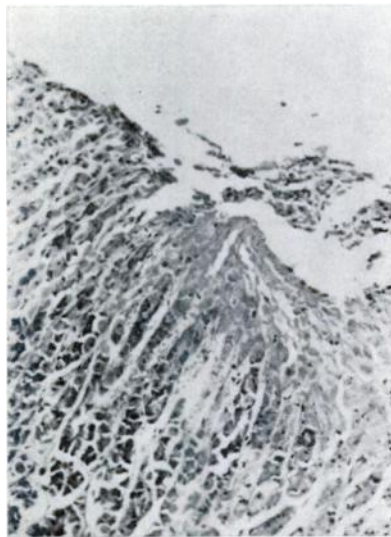


FIGURE 2. Gastric erosion of snowshoe hare with necrosis of superficial mucosa and intramucosal hemorrhage, H. & E. X 375.

Microscopically, the lesions consisted of necrotic craters which frequently reached but seldom penetrated the mus-

cularis mucosa (Figure 2). Cellular and nuclear outlines were absent in the necrotic superficial mucosa but chief and parietal cells were visible at the base of the erosions. Extensive intramucosal hemorrhages occurred and red blood cells were seen in the lumen of the gastric glands. The mucosal vessels were engorged and thrombi were occasionally observed. Edema occurred in the adjacent submucosa. The submucosa and the mucosa adjacent to the erosions were free of leukocytic infiltration. In the series of stomachs examined, there was no evidence that the erosions were caused by parasites, in fact over one-third of the hares with gastric lesions did not have the stomach worm, *Obeliscoides cuniculi*. These lesions were similar to restraint-induced "stress ulcers" reported for a wide range of experimental animals.<sup>3</sup>

#### DISCUSSION

The gastric lesions in the hares were associated with hypoglycemia and the "trap sickness" syndrome. The lesions were observed in over 85% of the captured hares with "trap sickness" symptoms, whereas they were observed in less

than 30% of the captured hares which appeared normal. "Trap sickness" in snowshoe hares was characterized by lethargy, hypoglycemia, and terminal opisthotonic seizures and the syndrome was believed due to stress induced as a result of entrapment.<sup>1</sup>

Entrapment involves factors known to induce "stress ulcers" in experimental animals. The lesions have been induced experimentally by immobilization, restraint, and other modifications of the environment.<sup>10</sup> In terms of restraint, it seems the method of restraint is unimportant because similar lesions occurred with each of the various techniques, and the incidence of lesions after 24 hours of restraint was always 80% to 100%.

Bonfils and coworkers<sup>2</sup> have shown the incidence of gastric lesions is inversely related to restraint volume i.e., the smaller the cage, the higher the incidence of lesions.

During their cyclic peak populations, snowshoe hares may experience a number of adverse stimuli which may reduce physiologic reserves and such hares might be more prone to develop gastric lesions when trapped. However, in April, 1971, a dead hare was found in the forest and this animal had extensive stomach lesions, indicating that gastric erosions can occur in free-ranging hares. The frequency of gastric lesions in trapped hares might serve as a useful index to the health of a hare population.

#### Acknowledgement

The snowshoe hares were provided through the courtesy of Mr. Lloyd B. Keith, Department of Wildlife Ecology, University of Wisconsin.

#### REFERENCES

1. ADAMS, L. 1959. An analysis of a population of snowshoe hares in northwestern Montana. *Ecol. Monographs*, 29: 141-170.
2. BONFILS, S., CL. RICHIR, F. POTET, G. LIEFOOGHE, and A. LAMBLING. 1959. "Ulcère" Expérimental de Contrainte du Rat Blanc. II. Anatomie — pathologie des lésions gastriques et de différentes lésions viscérales. *Rev. Franc. Etudes Clin. Biol.* 4: 888-894.
3. BRODIE, D. A., and H. M. HANSON. 1960. A study of the factors involved in the production of gastric ulcers by the restraint technique. *Gastroenterology*, 38: 353-360.
4. DODDS, D. G., and J. S. MACKIEWICZ. 1961. Some parasites and diseases of snowshoe hares in Newfoundland. *J. Wildl. Mgmt.*, 25: 409-414.
5. GREEN, R. G., and C. A. EVANS. 1940. Studies on a population cycle of snowshoe hares on the Lake Alexander area. *J. Wildl. Mgmt.*, 4: 220-238.
6. GREEN, R. G., and C. L. LARSON. 1938. A description of shock disease in the snowshoe hare. *Am. J. Hyg.*, 28: 190-212.
7. HOFF, G. L., T. M. YUILL, J. O. IVERSEN, and R. P. HANSON. 1969. Snowshoe hares and the California encephalitis virus group in Alberta, 1961-1968. *Bull. Wildl. Dis. Assoc.*, 5: 254-259.
8. KEITH, L. B., and E. C. MESLOW. 1968. Trap response by snowshoe hares. *J. Wildl. Mgmt.*, 32: 795-801.
9. KEITH, L. B., E. C. MESLOW, and O. J. RONSTAD. 1968. Techniques for snowshoe hare population studies. *J. Wildl. Mgmt.*, 32: 801-812.
10. SELYE, H. 1946. The general adaptation syndrome and diseases of adaptation. *J. Clin. Endocrinol.*, 6: 117-230.

*Received for publication April 18, 1971*