

ANTLER MALFORMATION PRODUCED BY LEG INJURY IN WHITE-TAILED DEER 1

Authors: MARBURGER, R. G., ROBINSON, R. M., THOMAS, J. W.,
ANDREGG, M. J., and CLARK, K. A.

Source: Journal of Wildlife Diseases, 8(4) : 311-314

Published By: Wildlife Disease Association

URL: <https://doi.org/10.7589/0090-3558-8.4.311>

The BioOne Digital Library (<https://bioone.org/>) provides worldwide distribution for more than 580 journals and eBooks from BioOne's community of over 150 nonprofit societies, research institutions, and university presses in the biological, ecological, and environmental sciences. The BioOne Digital Library encompasses the flagship aggregation BioOne Complete (<https://bioone.org/subscribe>), the BioOne Complete Archive (<https://bioone.org/archive>), and the BioOne eBooks program offerings ESA eBook Collection (<https://bioone.org/esa-ebooks>) and CSIRO Publishing BioSelect Collection (<https://bioone.org/csiro-ebooks>).

Your use of this PDF, the BioOne Digital Library, and all posted and associated content indicates your acceptance of BioOne's Terms of Use, available at www.bioone.org/terms-of-use.

Usage of BioOne Digital Library content is strictly limited to personal, educational, and non-commercial use. Commercial inquiries or rights and permissions requests should be directed to the individual publisher as copyright holder.

BioOne is an innovative nonprofit that sees sustainable scholarly publishing as an inherently collaborative enterprise connecting authors, nonprofit publishers, academic institutions, research libraries, and research funders in the common goal of maximizing access to critical research.

ANTLER MALFORMATION PRODUCED BY LEG INJURY IN WHITE-TAILED DEER ^[1]

R. G. MARBURGER^[2], R. M. ROBINSON^[3], J. W. THOMAS^[4], M. J. ANDREGG^[5], and
K. A. CLARK^[3]

Abstract: Field observations of 36 white-tailed bucks with malformed antlers suggested a cause-effect relationship between rear leg injury and antler malformation. Experimental procedures involving six bucks indicated that contralateral antler malformation can be produced by amputation of a rear leg.

INTRODUCTION

Observations of male white-tailed deer (*Odocoileus virginianus*) in the wild for many years suggested a correlation between malformed antlers and limping. Many bucks with antler deformities accompanied by old leg injuries have been reported by hunters. The possibility of a cause-effect relationship between these two conditions is suggested: Cowan¹ states, in reference to mule deer (*Odocoileus hemionus columbianus*). "Certain bucks have been known to produce deformed antlers of the same type for several successive years, thus ruling out the possibility of injury to the growing antler as cause of the deformity". Seton² and Clark³ suggested that bodily injuries which occurred while the antlers were developing could produce abnormal antlers, with the abnormal antler developing on the same side as the injury. Moore⁴ described antler deformities in moose (*Alces alces*) and caribou (*Rangifer tarandus*), with deformed antlers always associated with one or more molars in bad condition on the same side of the head as the deformity. Clark³ noted malformation of antlers attributed to trauma to the antlers or "other parts" of the body.

Penrose⁵ reported that smaller antlers resulted on the opposite side of the head following unilateral castration in a sika deer (*Cervus nippon*).

The following observations, made by the authors, supported the suggestion that a cause-effect relationship might exist between malformation of antlers and leg injuries. A white-tailed buck bearing symmetrical antlers was shot in the left shoulder with a tranquilizer gun, breaking the scapula. A belled collar was placed around his neck for identification and the animal was released. A left antler failed to develop in each of two successive years. Another buck reared in captivity accidentally fractured the left tuber calcis, rendering the leg immobile. The right antler developed abnormally (Fig. 1) each year from injury until death five years later. Similar observations were made with two other deer that were accidentally injured. One mature buck broke the metatarsal bone just below the left hock when antler growth was about 75 percent complete. Within two weeks, the antler tip on the right side grew downward. This animal died before further observations could be made. A buck fawn broke the right femur and the leg was amputated high in the thigh. This accident and subsequent am-

[1] A contribution of a cooperative project between the Texas Parks and Wildlife Department and the Department of Veterinary Pathology, College of Veterinary Medicine and the Texas Agricultural Experiment Station, Texas A&M University; supported by Texas Pittman-Robertson Project W-93-R.

[2] Texas Parks and Wildlife Department, Kerrville, Texas.

[3] Department of Veterinary Pathology, Texas A&M University, College Station, Texas.

[4] Northeastern Forest Experiment Station, U.S. Forest Service, Morgantown, West Virginia.

[5] Texas Parks and Wildlife Department, Hunt, Texas.

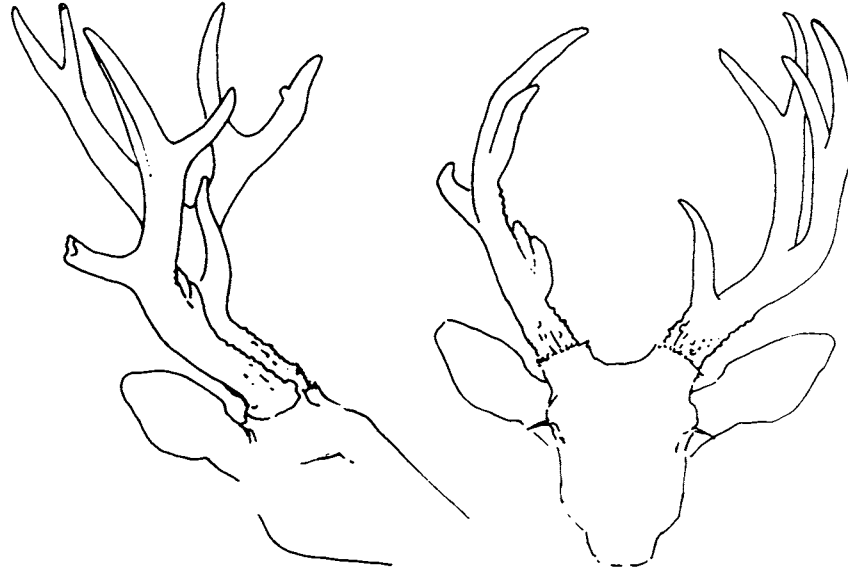


FIGURE 1. Antler deformity of deer with cracked tuber calcis, five years after injury.

putation occurred prior to antler development and the antlers did not develop well on either side of the head. These observations, together with those reported by other workers, prompted the initiation of a study to examine the relationship between leg injury and antler deformity. This paper reports the results of that study.

METHODS

Observations were made in thirteen counties of the Edwards Plateau of Texas during the hunting seasons of 1963 and 1964. Ice houses and hunters' camps were visited and all abnormal antlers and all recognizable body injuries were recorded.

Experimental studies were then initiated, using bucks which had been reared in captivity, to determine if antler deformity could be artificially produced by either amputation or neurectomy. Surgery was performed while the antlers were hardened (to simulate hunting season conditions, when most injuries would be expected to occur). All of the deer were approximately four and one-half years old at the

beginning of the experiment and had normal symmetrical antlers.

The first year, the left hind leg of one deer was amputated 7.6 cm below the hock, two deer were subjected to neurectomies by the removal of one-half of the flexor branch of the tibial nerve, and one deer was kept as an untreated control. During the second year, the two deer on which neurectomies had been performed and another normal buck were subjected to amputations. A fourth was retained as an untreated control.

RESULTS

Thirty-two bucks killed by hunters had deformed antlers, and of these, twenty-two (69%) had either old gunshot wounds or healed leg fractures. Ten deer had antler deformity but no obvious injury. Six of these ten, all from the same geographic area, had more than one antler coming from the base of the corona, suggesting a non-traumatic etiology.

In all of the experimental animals, antler development began in mid-April

and continued at the same rate throughout the growing period. All deer shed the velvet from the antlers at about the same time. During the first year, the amputee (left rear leg) produced a deformed antler (Fig. 2) contralateral to the amputated leg. The deer on which neurectomies had been performed did not show any change

in the pattern of antler development. The second year, the three amputees (left rear legs) produced deformed antlers contralateral to the amputated leg. The two deer that had undergone neurectomy earlier developed antlers which were much more severely deformed than those of the other experimental deer (Fig. 3).

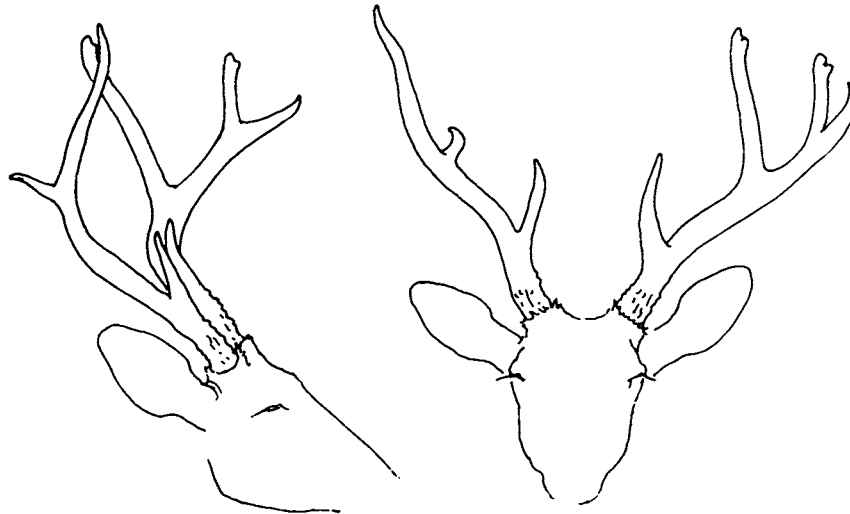

FIGURE 2. Typical antler deformity of deer with left rear leg amputated.

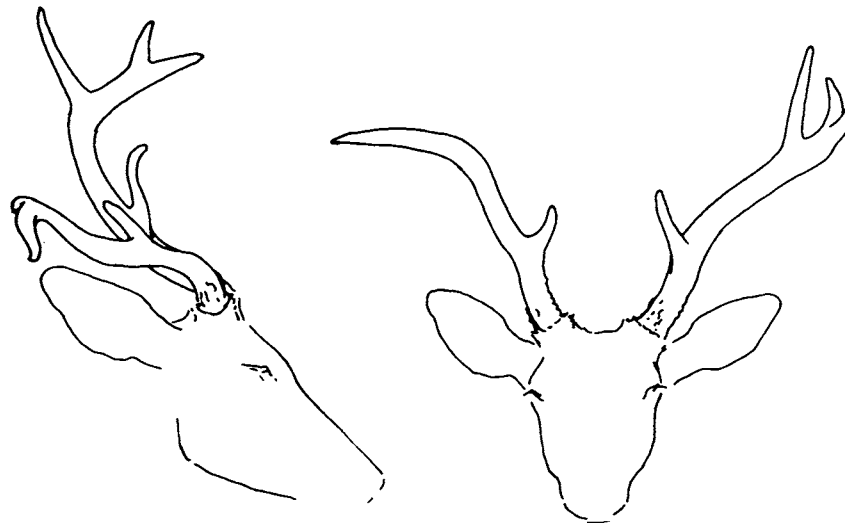

FIGURE 3. Antler deformity of deer with left leg amputated following neurectomy the previous year.

DISCUSSION

Observations made during the examination of deer killed by hunters agree with prior observations and strongly suggest a close relationship between injury and antler malformation. All of the animals with rear leg injuries or amputations produced malformed antlers contralateral to the injury. The amputees showed more pronounced antler deformities than the deer with accidental leg injuries and amputation following neurectomy produced the most pronounced malformations. These experimental results indicate a cause-relationship between bodily injury and antler malformation, indicating that

when the site of bodily injury is a rear leg, the antler on the opposite side will be affected.

This demonstration of non-adjacent somatic influence on developing bone is highly significant and further work to ascertain the mechanism of action is indicated. Many varied and novel explanations for this phenomenon have been advanced by various individuals. The authors believe that complex neural relationships are involved; however, the purpose of this report is to draw attention to the occurrence of this phenomenon, and explanation of etiological pathways is undetermined.

LITERATURE CITED

1. COWAN, I. M. 1956. Life and times of the coast black-tailed deer. In *Deer of North America*, ed. by W. P. Taylor, Harrison, Pennsylvania, Stackpole Co., 668 pp.
2. SETON, E. T. 1937. *Lives of Game Animals*. Hoofed Animals, Vol. 3, Literary Guild of America, New York, 780 pp.
3. CLARK, H. C. 1916. Malformed antlers in deer. *Calif. Fish and Game* 2: 119-123.
4. MOORE, W. H. 1931. Notes on antler growth of Cervidae. *J. Mamm.* 12: 169-170.
5. PENROSE, C. B. 1924. Removal of the testicle of a sika deer followed by deformity of antler on the opposite side. *J. Mamm.* 5: 116.

Received for publication October 27, 1971