

SURFACE AND VISCERAL LYMPHOCYSTIS DISEASE IN A WHITE CRAPPIE, *Pomoxis annularis* *

Author: HUIZINGA, H. W.

Source: Journal of Wildlife Diseases, 9(4) : 349-351

Published By: Wildlife Disease Association

URL: <https://doi.org/10.7589/0090-3558-9.4.349>

The BioOne Digital Library (<https://bioone.org/>) provides worldwide distribution for more than 580 journals and eBooks from BioOne's community of over 150 nonprofit societies, research institutions, and university presses in the biological, ecological, and environmental sciences. The BioOne Digital Library encompasses the flagship aggregation BioOne Complete (<https://bioone.org/subscribe>), the BioOne Complete Archive (<https://bioone.org/archive>), and the BioOne eBooks program offerings ESA eBook Collection (<https://bioone.org/esa-ebooks>) and CSIRO Publishing BioSelect Collection (<https://bioone.org/csiro-ebooks>).

Your use of this PDF, the BioOne Digital Library, and all posted and associated content indicates your acceptance of BioOne's Terms of Use, available at www.bioone.org/terms-of-use.

Usage of BioOne Digital Library content is strictly limited to personal, educational, and non-commercial use. Commercial inquiries or rights and permissions requests should be directed to the individual publisher as copyright holder.

BioOne is an innovative nonprofit that sees sustainable scholarly publishing as an inherently collaborative enterprise connecting authors, nonprofit publishers, academic institutions, research libraries, and research funders in the common goal of maximizing access to critical research.

SURFACE AND VISCERAL LYMPHOCYSTIS DISEASE IN A WHITE CRAPPIE, *Pomoxis annularis**

H. W. HUIZINGA, Department of Biological Sciences, Illinois State University
Normal, Illinois 61761, U.S.A.

G. E. COSGROVE, Biology Division Oak Ridge National Laboratory,
Oak Ridge, Tennessee 37830, U.S.A.

INTRODUCTION

Lymphocystis disease is a viral infection of fish which appears as a macroscopic cauliflower-like growth on various body surfaces. The causative agent, a DNA-type pox virus, induces tremendous hypertrophy of infected subepidermal connective tissue cells.¹ Lymphocystis has been reported from both marine^{2,3} and freshwater^{4,5} fishes. Several species of freshwater centrarchid fishes are commonly infected. The extensive literature has been reviewed^{2,4,6} but there are few records of visceral involvement. Nigrelli and Smith⁷ observed hypertrophic cells in the gastrointestinal tract, spleen and ovary of *Ceratocanthus schoepflii*. Smith⁸ found two cases of visceral infection in *Stellifer lanceolatus*, but did not specify the organs involved. Since fish have been infected by oral inoculation of viral infected tissue,⁶ visceral involvement may occur more commonly than has been previously diagnosed.

MATERIALS AND RESULTS

A white crappie, *Pomoxis annularis* (total length 17 cm) was collected in the Mackinaw River at Route 51 near El

Paso, Illinois. At the lower edge of the eye was a white, irregular, somewhat friable, papillary growth of about 1 cm greatest dimension (Fig. 1). The fish was fixed and stored in 10% formalin for about four years as a museum specimen. Necropsy was then performed, the head decalcified, and histologic preparations of the skin lesion and major viscera were studied. The growth was a typical lymphocystis lesion, probably originating from hypertrophied connective tissue cells lying under the thin, displaced epidermis (Figs. 2, 3). The mean diameter of 10 infected cells (sectioned at level of the nucleus) was 173 microns. The unusual feature of this case was the presence of isolated lymphocystis - infected cells throughout the spleen (Fig. 4). It could not be determined if these cells were "metastatic" from the ocular lesion or of local origin. The hyaline capsule surrounding individual cells was especially well-demonstrated by the Periodic Acid Schiff staining reaction, suggesting a useful technique for diagnosis of widely scattered lymphocystis cells in visceral organs (Fig. 4).

*Research supported jointly by Illinois State University and the U.S. Atomic Energy Commission under contract with the Union Carbide Corporation.

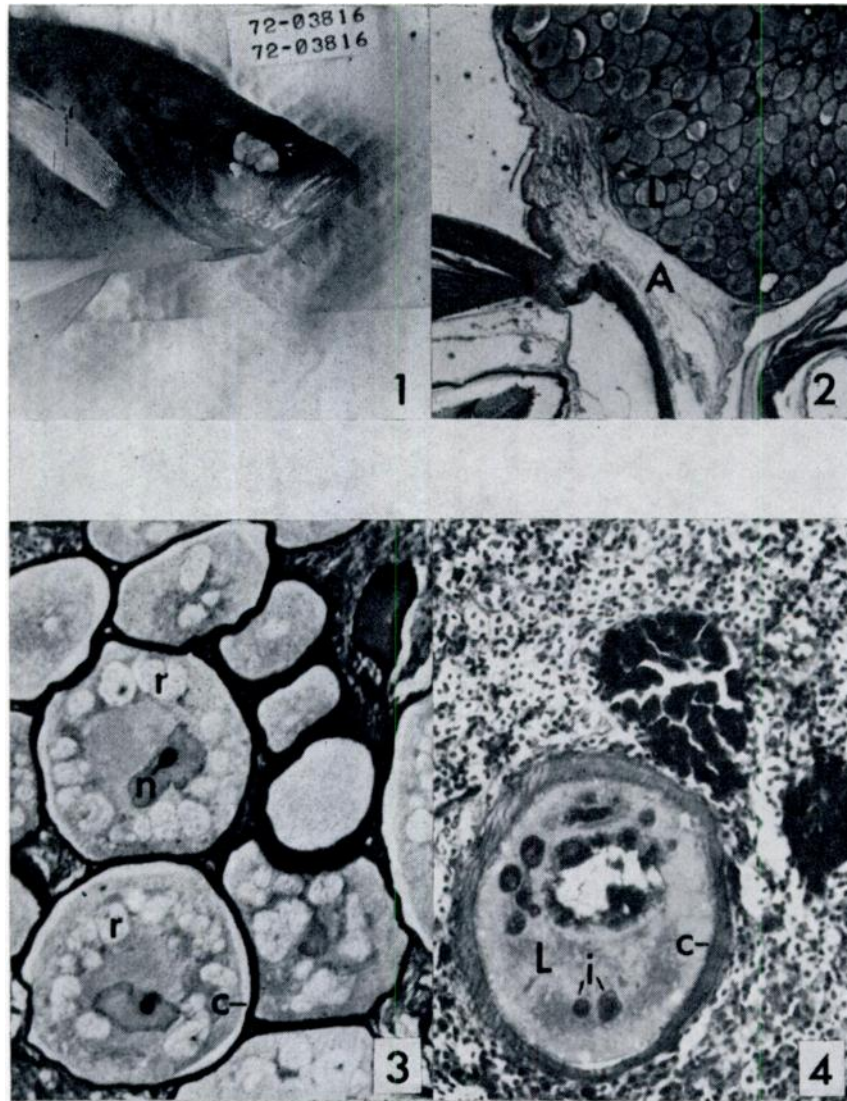


FIGURE 1. White crappie with lymphocystis growth at base of eye. (X 0.6)

FIGURE 2. Section of lymphocystis growth (L) at region of attachment (A) near eye. PAS stain. (X 25)

FIGURE 3. Higher power section of growth with details of lymphocystis-infected cells: nucleus (n) with nucleolus, reticular "virus" inclusions (r), capsule (c). H & E stain. (X 160)

FIGURE 4. Section of spleen with single lymphocystis cell (L). Note PAS stained inclusions (i) and hyaline capsule (c). (X 200)

LITERATURE CITED

1. DUNBAR, C. E. and K. WOLF. 1966. The cytological course of experimental lymphocystis in the bluegill. *J. Inf. Dis.* 116: 466-472.
2. LOPEZ, D. M., M. M. SIEGEL, A. R. BEASLEY and L. S. DIETRICH. 1969. Biochemical and morphologic studies of lymphocystis disease. *NCI Monograph* 31: 223-236.
3. NIGRELLI, R. F. and G. M. SMITH. 1939. Studies on lymphocystis disease in the orange filefish, *Ceratacanthus schoepfii* (Walbaum) from Sandy Hook Bay, N.J. *Zoologica* 24: 255-264.
4. NIGRELLI, R. F. and G. RUGGIERI. 1965. Studies on virus diseases of fishes. Spontaneous and experimentally induced cellular hypertrophy (lymphocystis disease) in fishes of the New York Aquarium, with a report of new cases and an annotated bibliography (1874-1965). *Zoologica* 50: 83-96.
5. SMITH, F. G. 1970. A preliminary report of lymphocystis disease in the fish of the Sapelo Island, Georgia area. *J. Wildl. Dis. (Proceedings Annual Conference)* 6: 469-471.
6. WEISSENBERG, R. 1965. Fifty years of research on the lymphocystis virus disease of fishes (1914-1964). *Ann. N.Y. Acad. Sci.* 126: 362-374.

Received for publication 2 May 1973
