

## **Wing Abnormality in a Wild-Hatched Whooping Crane (*Grus americana*) Chick from the Nonmigratory Population in Louisiana, USA**

Authors: Vasseur, Phillip L., Zimorski, Sara E., Szyszkoski, Eva K., LaCour, James M., Lankton, Julia S., et al.

Source: Journal of Wildlife Diseases, 55(4) : 954-957

Published By: Wildlife Disease Association

URL: <https://doi.org/10.7589/2018-09-234>

---

BioOne Complete ([complete.BioOne.org](https://complete.BioOne.org)) is a full-text database of 200 subscribed and open-access titles in the biological, ecological, and environmental sciences published by nonprofit societies, associations, museums, institutions, and presses.

Your use of this PDF, the BioOne Complete website, and all posted and associated content indicates your acceptance of BioOne's Terms of Use, available at [www.bioone.org/terms-of-use](https://www.bioone.org/terms-of-use).

Usage of BioOne Complete content is strictly limited to personal, educational, and non - commercial use. Commercial inquiries or rights and permissions requests should be directed to the individual publisher as copyright holder.

---

BioOne sees sustainable scholarly publishing as an inherently collaborative enterprise connecting authors, nonprofit publishers, academic institutions, research libraries, and research funders in the common goal of maximizing access to critical research.

## Wing Abnormality in a Wild-Hatched Whooping Crane (*Grus americana*) Chick from the Nonmigratory Population in Louisiana, USA

Phillip L. Vasseur,<sup>1,6</sup> Sara E. Zimorski,<sup>2</sup> Eva K. Szyszkoski,<sup>2</sup> James M. LaCour,<sup>3</sup> Julia S. Lankton,<sup>4</sup> and L. Abbigail Granger<sup>5</sup> <sup>1</sup>Louisiana Department of Wildlife and Fisheries, Rockefeller Wildlife Refuge, 5476 Grand Chenier Highway, Grand Chenier, Louisiana 70643, USA; <sup>2</sup>Louisiana Department of Wildlife and Fisheries, White Lake Wetlands Conservation Area, PO Box 480, Gueydan, Louisiana 70542, USA; <sup>3</sup>Louisiana Department of Wildlife and Fisheries, PO Box 98000, Baton Rouge, Louisiana 70898, USA; <sup>4</sup>US Geological Survey, National Wildlife Health Center, 6006 Schroeder Road, Madison, Wisconsin 53711, USA; <sup>5</sup>Louisiana State University School of Veterinary Medicine, Skip Bertman Drive, Baton Rouge, Louisiana 70803, USA; <sup>6</sup>Corresponding author (email: pvasseur@wlf.la.gov)

**ABSTRACT:** We describe a wing abnormality in a wild-hatched Whooping Crane (*Grus americana*) chick from the reintroduced Louisiana, US nonmigratory population. Despite its seemingly compromised flight ability, the chick fledged, reached independence, and lived until 13 mo of age. Necropsy revealed an axial malunion near the left carpus likely resulting from trauma.

In April 2016, a pair of Whooping Cranes (*Grus americana*) from the reintroduced Louisiana, US nonmigratory population (King et al. 2018) hatched two chicks. This was the first documented successful breeding of wild Whooping Cranes in Louisiana since 1939 (Lynch 1984). Approximately 4 wk posthatch, one chick disappeared and we suspect it had been killed by a predator, although no remains were discovered. When the surviving chick was around 6 wk old, we observed an abnormality of its left wing. The distal end of the wing drooped conspicuously and the chick, which seemed lethargic at times, repeatedly adjusted its left wing to a folded position along the side of its body, which is a behavior performed more frequently by fatigued chicks (Ellis et al. 1999). The placement of the wing relative to a typical resting position improved over time, but some of the primary remiges were twisted at the carpus and protruded when the wing was tucked against the side of the body. Over the course of the chick's development, the wing abnormality was more apparent as remiges became more clearly visible, and we noted the chick was unable to fully extend its left wing, which was maintained at an abnormal angle at the carpal joint (Fig. 1).

Typically, chicks are capable of sustained flight by 80–100 d old (Urbanek and Lewis 2015). It was toward the latter end of this range when we first observed the chick making a short, low-altitude flight (i.e., <100 m distance and <50 m altitude). The chick made additional flights of similar magnitude and eventually covered a distance (>100 m) that we determined was sufficient to declare it fledged at 123 d old. However, we could not conclude that the chick's wing abnormality caused the prolonged fledging period because the timing may have been influenced by constraints on the flight ability of the adult male, who underwent a complete remigial molt during the chick's development. The Whooping Crane periodically undergoes a synchronous remigial molt during which it becomes flightless for approximately 6 wk (Urbanek and Lewis 2015). The adult male regained his ability to fly 1 wk prior to the chick's fledge date. Because males have a tendency to initiate flights in a family group (Dellinger 2018), it is possible that the adult male's flightless period contributed to the chick's delayed fledging.

The chick remained with its parents for the next several months near its natal grounds, which consisted of agricultural lands (i.e., crawfish, rice, and fallow fields). As the next breeding season approached, both parents displayed aggressive behavior toward the chick, signaling their intention to begin the nesting process free from a dependent offspring. We captured the chick on 10 February 2017 while it was still associating with its parents and performed a physical examination. Upon inspection of the left wing, we



FIGURE 1. Whooping Crane (*Grus americana*) juvenile LW1-16 (center) from the Louisiana, USA nonmigratory population at approximately 14 wk old in 2016. Note the disparity between the fully extended right wing and the partially extended left wing, which is held at an abnormal angle from the carpal joint. Also note the shorter length of the seventh and eighth primary remiges of the left wing, which were delayed in growth but eventually reached full size.

noted contraction of the propatagium and tightness of the tendon which was displaced ventrally, creating a fold on the underside of the leading edge of the wing next to the carpal joint. We attached leg bands and a very high frequency transmitter for identification and tracking purposes, then collected blood and other biologic samples. Once we released the chick, the parents aggressively prevented it from rejoining them, thus finalizing their separation. The chick stayed near (<2.5 km) its parents, who began nesting within days of the chick's capture. However, it is common for immature Whooping Cranes to remain in the vicinity of their natal area (Urbanek and Lewis 2015), so it is conceivable that the wing abnormality did not play a significant role in the distance it maintained from its parents following independence. This same pair of adults raised two healthy chicks in 2018, and GPS data indicated comparable average distances traveled by the families from the nest during the postfledging periods in 2016 (1.0 km) and 2018 (1.4 km), further suggesting

the range of the chick with the wing abnormality was not significantly compromised.

During an aerial survey on 10 May 2017, we found the immature crane, which blood analysis indicated was a female, dead in a dry pasture. Her carcass was shipped to the US Geological Survey, National Wildlife Health Center (Madison, Wisconsin, USA) where a necropsy revealed a neck fracture and severe hemorrhage in the right pectoral muscle and right lung that possibly resulted from collision with a barbed wire fence near the location where the carcass was found. Radiographs showed a moderate (about 30 degree) caudal angulation associated with the distal diaphysis of the radius and ulna (Fig. 2). The distal epiphysis of the radius was narrow and the joint space between the radius and radial carpal bone was ill-defined. The major metacarpal bone was moderately cranially displaced. Osseous findings were consistent with an axial malunion of the left radius and ulna with moderate left carpal subluxation.

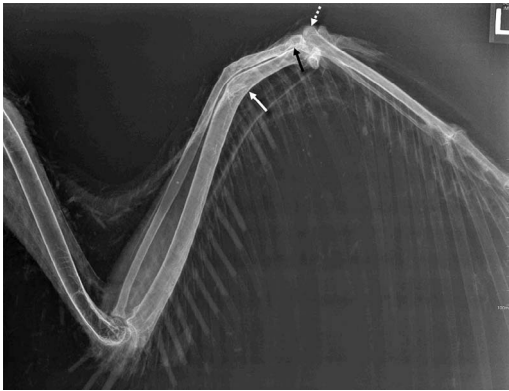


FIGURE 2. Ventral-dorsal view radiograph taken at necropsy of the left wing of a 13 mo old Whooping Crane (*Grus americana*) from the Louisiana, USA nonmigratory population with a wing abnormality. A moderate (about 30°) caudal angulation was present associated with the distal diaphysis of the radius and ulna (white arrow), with a marked reduction in the radioulnar gap and mild irregular shape of both cortices cranially at the location of the angulation. A fracture line was not visible. The distal epiphysis of the radius was narrow and the joint space between the radius and radial carpal bone was ill-defined (black arrow). The major metacarpal bone was moderately cranially displaced (dotted white arrow). Osseous findings were consistent with an axial malunion of the left radius and ulna with moderate left carpal subluxation.

Necropsy findings also confirmed our field assessment regarding the contraction of the left propatagium and tightened, displaced tendon, which was likely secondary to the fracture, with the abnormal angle of the bone likely causing excessive tension on adjacent soft tissue structures.

Wing abnormalities have been reported in captive-reared Whooping Crane chicks (Olsen and Langenberg 1996; Kelley and Hartup 2008) and rarely in wild Whooping Crane populations (Novakowski 1965). A commonly described abnormality that affects primarily waterfowl and larger waterbirds is angel wing, a developmental deformity of the carpometacarpal region resulting in the displacement of primary remiges (Azmanis et al. 2014). Protein-rich diets, nutrient deficiencies, and genetic predisposition are thought to be contributing factors (Kear 1973; Serafin 1982; Zsivanovits et al. 2006). It is not known

if diet or a genetic factor contributed to the abnormality in the Louisiana chick, although there was no evidence of metabolic bone disease or other skeletal abnormalities. Therefore, we suspect that a traumatic event led to a fracture near the carpal joint when the chick was between 5–6 wk old, resulting in contracture of the propatagium during the healing process. This likely compromised the chick's flight ability and possibly contributed to its premature death.

We thank the Louisiana Department of Wildlife and Fisheries, Louisiana Wildlife and Fisheries Foundation, US Fish and Wildlife Service, International Crane Foundation, Louisiana State University AgCenter, US Geological Survey Patuxent Wildlife Research Center, and US Geological Survey National Wildlife Health Center for their financial or technical support. Additional funding provided by the Chevron Corporation, ConocoPhillips, Coypu Foundation, Cameron LNG, Entergy, and many private donors. R. Elsey, J. Marty, and J. Amory provided valuable comments on an earlier draft. We also thank the private landowners who granted us access to their properties in order to monitor the cranes. Any use of trade, firm, or product names is for descriptive purposes only and does not imply endorsement by the US Government.

#### LITERATURE CITED

- Azmanis PN, Wernick MB, Hatt JM. 2014. Avian luxations: Occurrence, diagnosis and treatment. *Vet Quart* 34:11–21.
- Dellinger TA. 2018. Florida's nonmigratory whooping cranes. In: *Whooping cranes: Biology and conservation*, French JB Jr, Converse SJ, Austin JE, editors. Academic Press, San Diego, California, pp. 179–194.
- Ellis DH, Archibald GW, Swengel S, Kepler CB. 1999. Compendium of crane behavior. Part 1: Individual (nonsocial) behavior. In: *Proceedings of the 1987 international crane workshop*, Harris JT, editor. Qiqihar, Heilongjiang Province, China, 1–10 May; International Crane Foundation, Baraboo, Wisconsin, pp. 225–234.
- Kear J. 1973. Notes on the nutrition of young waterfowl, with special reference to slipped wing. *Int Zoo Yearb* 13:97–100.
- Kelley C, Hartup BK. 2008. Risk factors associated with developmental limb abnormalities in captive whooping cranes. In: *Proceedings of the 10th North*

- American crane workshop*, Folk MJ, Nesbitt SA, editors. Zacatecas City, Zacatecas, Mexico, 7–10 February; North American Crane Working Group, Gambier, Ohio, pp. 119–124.
- King SL, Selman W, Vasseur PL, Zimorski SE. 2018. Louisiana nonmigratory whooping crane reintroduction. In: *Whooping cranes: Biology and conservation*, French JB Jr, Converse SJ, Austin JE, editors. Academic Press, San Diego, California, pp. 469–484.
- Lynch JJ. 1984. A field biologist. In: *Flyways: Pioneering waterfowl management in North America*, Hawkins AS, Hanson RC, Nelson HK, Reeves HM, editors. US Fish and Wildlife Service, Washington, DC, pp. 35–40.
- Novakowski N. 1965. The day we rescued a whooping crane. *Audubon Mag* 67:230–233.
- Olsen GH, Langenberg JA. 1996. Veterinary techniques for rearing crane chicks. In: *Cranes: Their biology, husbandry, and conservation*, Ellis DH, Gee GF, Mirande CM, editors. National Biological Service, Washington, DC, International Crane Foundation, Baraboo, Wisconsin, pp. 100–103.
- Serafin JA. 1982. The influence of diet composition upon growth and development of sandhill cranes. *Condor* 84:427–434.
- Urbanek RP, Lewis JC. 2015. Whooping crane (*Grus americana*). In: *The birds of North America*, Poole AF, editor. Cornell Lab of Ornithology, Ithaca, New York. <https://doi.org/10.2173/bna.153>. Accessed January 2019.
- Zsivanovits P, Monks DJ, Forbes NA. 2006. Bilateral valgus deformity of the distal wings (angel wing) in a northern goshawk (*Accipiter gentilis*). *J Avian Med Surg* 20:21–26.
- Submitted for publication 28 September 2018.*  
*Accepted 27 February 2019.*