

ARGAS (PERSICARGAS) GIGANTEUS SOFT TICK INFECTION WITH RICKETTSIA HOOGSTRAALI AND RELAPSING FEVER BORRELIA ON WILD AVIAN SPECIES OF THE DESERT SOUTHWEST, USA

Authors: Latas, Patricia, Auckland, Lisa D., Teel, Pete D., and Hamer, Sarah A.

Source: Journal of Wildlife Diseases, 56(1) : 113-125

Published By: Wildlife Disease Association

URL: <https://doi.org/10.7589/2018-11-275>

The BioOne Digital Library (<https://bioone.org/>) provides worldwide distribution for more than 580 journals and eBooks from BioOne's community of over 150 nonprofit societies, research institutions, and university presses in the biological, ecological, and environmental sciences. The BioOne Digital Library encompasses the flagship aggregation BioOne Complete (<https://bioone.org/subscribe>), the BioOne Complete Archive (<https://bioone.org/archive>), and the BioOne eBooks program offerings ESA eBook Collection (<https://bioone.org/esa-ebooks>) and CSIRO Publishing BioSelect Collection (<https://bioone.org/csiro-ebooks>).

Your use of this PDF, the BioOne Digital Library, and all posted and associated content indicates your acceptance of BioOne's Terms of Use, available at www.bioone.org/terms-of-use.

Usage of BioOne Digital Library content is strictly limited to personal, educational, and non-commercial use. Commercial inquiries or rights and permissions requests should be directed to the individual publisher as copyright holder.

BioOne is an innovative nonprofit that sees sustainable scholarly publishing as an inherently collaborative enterprise connecting authors, nonprofit publishers, academic institutions, research libraries, and research funders in the common goal of maximizing access to critical research.

ARGAS (*PERSICARGAS*) *GIGANTEUS* SOFT TICK INFECTION WITH *RICKETTSIA* *HOOGSTRAALI* AND RELAPSING FEVER *BORRELIA* ON WILD AVIAN SPECIES OF THE DESERT SOUTHWEST, USA

Patricia Latas,^{1,5} Lisa D. Auckland,² Pete D. Teel,³ and Sarah A. Hamer^{2,4}

¹ Awe Pono Avian Health, 7223 E Camino Valle Verde, Tucson, Arizona 85715, USA

² Department of Veterinary Integrative Biosciences, Texas A&M University, 4458 TAMU, College Station, Texas 77843, USA

³ Department of Entomology, Texas A&M AgriLife Research, 2475 TAMU, College Station, Texas 77843, USA

⁴ Schubot Exotic Bird Health Center, Texas A&M University, 4467 TAMU, College Station, Texas 77843, USA

⁵ Corresponding author (email: pjlatastdvm@gmail.com)

ABSTRACT: Changing climatic conditions and the northward expansion of ticks and pathogens are of immense importance to human, animal, and environmental health assessment and risk management. From 2014 through 2015, a wildlife rehabilitation center in south-central Arizona, US noted soft ticks (*Argasidae*) infesting 23 birds, including Cooper's Hawks (*Accipiter cooperii*), Gray Hawks (*Buteo plagiatus*), Harris's Hawks (*Parabuteo unicinctus*), Red-tailed Hawks (*Buteo jamaicensis*), Great Horned Owls (*Bubo virginianus*), Common Ravens (*Corvus corax*), and a Greater Roadrunner (*Geococcyx californianus*), during the late summer seasonal rainy seasons. The parasites numbered in the hundreds on individual birds. Infested birds were moribund, obtunded, or paralyzed on presentation, with no prior histories of illness or evidence of trauma. Tick and avian blood samples were collected for vector-borne pathogen analysis focusing on the molecular detection of *Rickettsia* and *Borrelia* species. Ticks were identified as the neotropical species of soft tick, *Argas (Persicargas) giganteus*; their occurrence in the southern US on raptors represented an expansion of host range. Pathogen testing of ticks showed that 41% of 54 ticks were infected with *Rickettsia hoogstraalii* and 23% of 26 ticks were infected with a relapsing fever *Borrelia*; both agents are associated with uncertain health consequences. Among the blood samples, one was infected with the same *Borrelia* spp.; this Red-tailed Hawk also had *Borrelia*-positive ticks. With supportive therapy, the majority of birds, 74% (17/23), recovered and were released or permanent residents. The management of soft tick-infested birds and mitigation of future disease risk will require additional characterizations of these poorly studied soft ticks and their associated pathogens.

Key words: *Argas giganteus*, relapsing fever *Borrelia*, *Rickettsia hoogstraalii*, southwest US, tick paralysis, wild birds.

INTRODUCTION

Northward range expansions of arthropod vectors are increasingly detected, often associated with the concomitant expansion of associated pathogens and disease risks. For example, neotropical migratory birds have been implicated in the importation of exotic neotropical ticks to the US (Hasle 2013; Mukherjee 2014) with conservative estimates of >19 million neotropical ticks imported each spring, including ticks infected with *Rickettsia* spp. of human and animal health concern (Cohen et al. 2015). Climate change is attributed to shifting geographic ranges of several tick species (Sonenshine 2018); for example, Lyme disease risk in eastern and central Canada is predicted to increase with

climate change (Ogden et al. 2008b), as *Ixodes scapularis* ticks deposited by northbound migratory birds (Ogden et al. 2008a) may encounter suitable climates for their survival and spread.

External parasites are not uncommon on avian patients presented to wildlife care facilities. Although the accurate identification of the parasites is essential to properly prevent infestation, treat patients, and assess risk of release back into the wild, birds arriving to rehabilitation centers can also serve as sentinels for local parasite occurrence.

Many neotropical avian species pass through the desert southwestern US during migration, and also nest in the region. Geographic range expansions of neotropical avian species are increasingly documented by

both researchers and citizen science entities (Rappole et al. 2011; eBird 2018). Although limited data are available regarding the parasites of birds in the desert southwest, pathogens have been documented from diverse wildlife species in the adjacent country of Mexico (Aguirre et al. 1992) and from ticks found within the desert southwest (Armed Forces Pest Management Board 2012; Manzano-Román 2012; Hasle 2013; Justice-Allen et al. 2016).

From 2009 through 2015 during the late summer rainy season, soft ticks (Argasidae) were noted on several birds presented to the Tucson Wildlife Center, a wildlife rehabilitation facility in south-central Arizona that admits 3,000–4,000 animals per year, of which three quarters are birds. During our study in 2014–15, we noted tick infestations on approximately 1% of the birds taken in during these years, and all the infested birds were sampled. Each infested bird showed all or a combination of moribundity, obtundity, and paralysis on presentation without prior history of illness or evidence of trauma. The appearance of a previously undetected tick species in a situation where diverse bird species showed severe clinical manifestations was cause of great concern not only for bird health and conservation, but also for unknown zoonotic risk to humans. Our objectives were to identify the species of tick and to test ticks and avian blood samples for selected tick-borne pathogens to detail the host–vector–pathogen interactions that may be important for improving bird health.

MATERIALS AND METHODS

The hosts

Samples collected from 2014 to 2015 were used for this study. Each animal underwent physical examination and was routinely checked for external parasites. Birds included resident, active rehabilitation, pending release, and newly admitted from the wild but not yet housed in the facility. Affected birds were immediately placed in oxygen-supported intensive care units. Fluid therapy with 2.5% dextrose/0.45% sodium chloride (Baxter Healthcare, Deerfield, Illinois, USA) was given twice a day at 10% body weight

subcutaneously. Antibiotic therapy initially used was ceftazidime (ceftazidime for injection, Sandoz Inc., Princeton, New Jersey, USA) at 75 mg/kg intramuscularly twice daily for 7 d. As pathogen identification became available, antibiotic treatment was changed to doxycycline (Vibramycin Monohydrate [doxycycline monohydrate] for Oral Suspension, Pfizer Laboratories, New York, New York, USA) at 20 mg/kg twice a day orally for 7 d. Necropsy examinations were performed on all deceased birds with ticks. Histopathologic and biopsy specimens were submitted to Zoo/Exotic Pathology Services (Carmichael, California, USA). Patients received ivermectin (IVOMEC 1% Injection, Merial Limited, Duluth, Georgia, USA) at 0.2 mg/kg orally and as topical application directly on the ticks and pyrethrin powder (Zodiac® Flea & Tick Powder for Dogs, Puppies, Cats & Kittens, Wellmark International, Schaumburg, Illinois USA) on individual birds for prevention of reinfestation upon release to outdoor pens. Permethrin powder for premise use (Prozap Garden & Poultry Dust, Neogen Corporation, Lexington, Kentucky, USA) was applied to access points, to soil, and to permanent perches of outdoor enclosures. Organic material and perches were removed and replaced with nonorganic, nonporous materials.

Ticks were removed from birds using fine-tipped forceps, stored in 70% ethanol, and saved for further analysis. Clinical pathology samples included blood collected via medial tarsal vein for determination of packed cell volume and blood smears examined in house. Additionally, blood samples were submitted for clinical pathologic analysis to Avian and Exotic Clin Path Labs (Wilmington, Ohio, USA) and for tick-borne pathogen analysis to Texas A&M University (College Station, Texas, USA).

The vectors

Ticks were identified morphologically at Texas A&M University and vouchered at the US National Tick Collection (Georgia Southern University, Statesboro, Georgia, USA) and the Texas A&M University Insect Collection. Morphologic identifications were made using a reference key (Estrada-Peña et al. 2006) and supporting information of the descriptions of *Argas* (*Persicargas*) *giganteus* (Kohls and Clifford 1968) and *Argas* *keiransi* (Estrada-Peña et al. 2003). In the laboratory, ticks were identified molecularly to genus using PCR DNA sequencing methods as follows. From a random subset of ticks from different birds, DNA was extracted from individual ticks using the E.Z.N.A. tissue DNA kit (Omega Bio-Tek, Norcross, Georgia, USA). Each tick was sliced into quarters with a sterile scalpel blade and incubated overnight at 55 C. We

extracted DNA the next day as per the manufacturer's instructions. We subjected DNA extracts to PCR of the 12S mitochondrial ribosomal DNA (rDNA), resulting in a 360-base pair (bp) product using the T1B and T2A primers (Beati and Keirans 2001). A subset of samples was also subjected to two additional PCRs, one to amplify the internal transcribed spacer 2 (ITS2) region resulting in a 1.2-kb product using the ITS2-7923-F and ITS2-7923-R primers (Zahler et al. 1995), and a second to amplify the 16S mitochondrial rDNA resulting in a 460-bp product using the 16S+1 and 16S-1 primers (Mangold et al. 1998). The 12S and ITS2 PCR reactions were carried out as previously described (Cohen et al. 2015) and the 16S PCR reaction was carried out as previously described (Mangold et al. 1998). All positive samples were treated with ExoSAP-IT (Affymetrix, Santa Clara, California, USA) and submitted for Sanger sequencing (Eton Biosciences, San Diego, California, USA). Sequences were compared to those in the GenBank database of the National Center for Biotechnology Information to facilitate identification. Tick sequences generated in this study were deposited to GenBank (MH717088-9 and MK078102).

The pathogens

Tick and blood samples were screened for *Rickettsia* and *Borrelia* species. The DNA from a 50–100- μ L sample of whole blood was extracted in the same manner as for the ticks described above, but with a 30-min incubation time. Initial *Rickettsia* screen was done by amplification of a 617-bp region of the *gltA* gene using the primers RrCS 372 and RrCS 989 (Williamson et al. 2010). Reactions were performed in 15- μ L volumes using 1.5 μ L of extracted DNA with 0.67 μ M each primer and FailSafe PreMix E buffer and enzyme (Epicentre Technologies Corp., Chicago, Illinois, USA). Confirmation of positive results was accomplished by amplifying an 856-bp region of the *ompB* gene with primers rOmpB 120-M59 and rOmpB 120-807 (Raoult et al. 2001). Additionally, all the *gltA*-negative blood samples and a small number of *gltA*-negative tick samples were subjected to the *ompB* reaction. The PCR purification and bidirectional DNA sequencing for both genes were performed as above.

Samples were tested for *Borrelia* in an iterative process using up to five independent PCRs. First, samples were subjected to a nested PCR to amplify the 16S-23S rRNA intergenic spacer (IGS) region of *Borrelia* species (Bunikis et al. 2004). Samples that produced a positive result in the IGS assay were then subjected to four additional assays: a qPCR (qualitative or real-time PCR) with Lyme group- and relapsing fever group-specific probes to amplify the 16S rRNA

gene of *Borrelia* (Tsao et al. 2004), and three assays to detect the *glpQ* gene of relapsing fever *Borrelia* (Bacon et al. 2005; Ullmann et al. 2005; Fomenko et al. 2011). Sanger sequencing was performed on all amplicons of the target size as described earlier. Pathogen sequences generated in this study were deposited to GenBank (MH717090-5).

RESULTS

The hosts

In 2014–15, large numbers of soft ticks were found on 23 individuals of seven avian species (Table 1) at the Tucson Wildlife Center, most during the rainy season months of August, September, and October. Of the 23 infested birds, ticks were noted at the time of intake on seven birds (one nestling, two fledglings, three immatures, and one adult), whereas ticks were presumably acquired on site for the remaining 16 birds (Table 1). The ticks were primarily found on the feet, legs, and leg axillae and were distributed across all age groups and sexes (Fig. 1A, B). Species included Cooper's Hawk (*Accipiter cooperii*, $n=4$), Gray Hawk (*Buteo plagiatus*, $n=2$), Harris's Hawk (*Parabuteo unicinctus*, $n=3$), Red-tailed Hawk (*Buteo jamaicensis*, $n=6$), Great Horned Owl (*Bubo virginianus*, $n=5$), Common Raven (*Corvus corax*, $n=2$), and Greater Roadrunner (*Geococcyx californianus*, $n=1$). Birds newly admitted with ticks were typically reported to have fallen from the nest or were found recumbent on the ground.

Once in rehabilitation, physical examination of birds showed all or a combination of peracute sternal recumbence, distal-to-proximal ascending paralysis, pale mucous membranes, dehydration, air hunger, and inability to swallow with normal level of consciousness if they were not obtunded (Table 1 and Fig. 2A, B). Birds showed diminished distal reflexes, diminished response to toe pinch, and lack of facial expression or attempt to move. Hundreds of small, firmly attached ticks were present on the birds (Fig. 3), with edema, ecchymoses and petechiae at attachment sites. Presumptive identification was that of an argasid tick of unknown species.

TABLE 1. Twenty-three birds of seven species are shown with basic data identifying their species, age category, the presence of *Argas (Persicargas) giganteus* larval ticks immediately on admission (not acquired at the facility) or on examination after being in the facility for treatment of other conditions or preparation for release (assumed to have been acquired on the premises), differential blood cell counts, if ticks collected from them were positive for *Rickettsia hoogstraalii*, and final disposition of each bird.^a

Species ^b	Age ^c	Acquisition of ticks		Paralysis	Anemia ^d	Leukocytosis ^e	Eosinophilia ^f	Rickettsia + ticks	Disposition ^g
		Before admission	After admission						
COHA	F	No	Yes	No	—	++	—	No	R
COHA	I	No	Yes	No	—	+++	—	Yes	R
COHA	I	No	Yes	No	+	++	—	No	E
COHA	A	No	Yes	Yes	—	++	—	No	R
HRSH	F	No	Yes	No	+	+	+	No	R
HRSH	F	Yes	No	No	+	++	+	No	D
HRSH	N	Yes	No	No	ND	ND	ND	No	R
GRHA	I	Yes	No	Yes	—	++	—	No	T
GRHA	I	Yes	No	No	—	—	—	No	T
RTHA	I	No	Yes	Yes	+	+++	+	Yes	D
RTHA	A	No	Yes	Yes	—	—	+	No	resident
RTHA	A	No	Yes	No	+	+	+	No	R
RTHA	A	No	Yes	No	+	++	+	Yes	R
RTHA	F	No	Yes	Yes	+	+	+	Yes	E
RTHA	A	No	Yes	Yes	+	—	+	No	R
GHOW	I	No	Yes	No	ND	ND	ND	No	R
GHOW	A	No	Yes	No	+	+++	+	No	R
GHOW	A	Yes	No	Yes	+	++	+	No	E
GHOW	N	No	Yes	No	+	++	+	No	E
GHOW	I	No	Yes	No	—	++	+	No	R
CORA	F	No	Yes	No	—	++	—	No	R
CORA	F	Yes	No	No	—	++	—	No	R
GRRO	I	Yes	No	No	+	+	+	No	R
% of total	30	70	30	48	78	57	17		

^a — = not outside of normal values; ND = not done.
^b COHA = Cooper's Hawk (*Accipiter cooperii*); HRSH = Harris's Hawk (*Parabuteo unicinctus*); GRHA = Gray Hawk (*Buteo plagiatus*); RTHA = Red-tailed Hawk (*Buteo jamaicensis*); GHOW = Great Horned Owl (*Bubo virginianus*); CORA = Common Raven (*Corvus corax*); GRRO = Greater Roadrunner (*Geococcyx californianus*).
^c F = fledgling; I = immature; A = adult; N = nestling.
^d Packed cell volume $\leq 45\%$.
^e + = white blood cell count $\geq 17,000$; ++ = white blood cell $\geq 21,000$; +++ = white blood cell $\geq 40,000$.
^f + = greater than normal values.
^g R = released; E = euthanized; D = died; T = transferred.

Complete blood counts and blood chemistry values across species in general demonstrated marked anemia, leukocytosis with heterophilia, and eosinophilia (Table 1). Leukocytosis was detected in 78% (18/23) of the birds, with 61% (14/23) greater than 21,000 cells per μL total white blood cell count (WBC); heterophilia in 30% (7/23; 17% (4/23) of the birds had absolute heterocyte counts $\geq 20,000$ cells/ μL), and eosinophilia in 57% (13/23). Thirteen percent (3/23) of birds had white blood cell within normal ranges and 7% (2/23) were not sampled. Thirteen birds were sampled for pathogen analysis, including 17% (4/23) of birds from which only ticks were sampled, 30% (7/23) from which only blood was sampled, and 7% (2/23) from which both ticks and blood were sampled (Table 2).

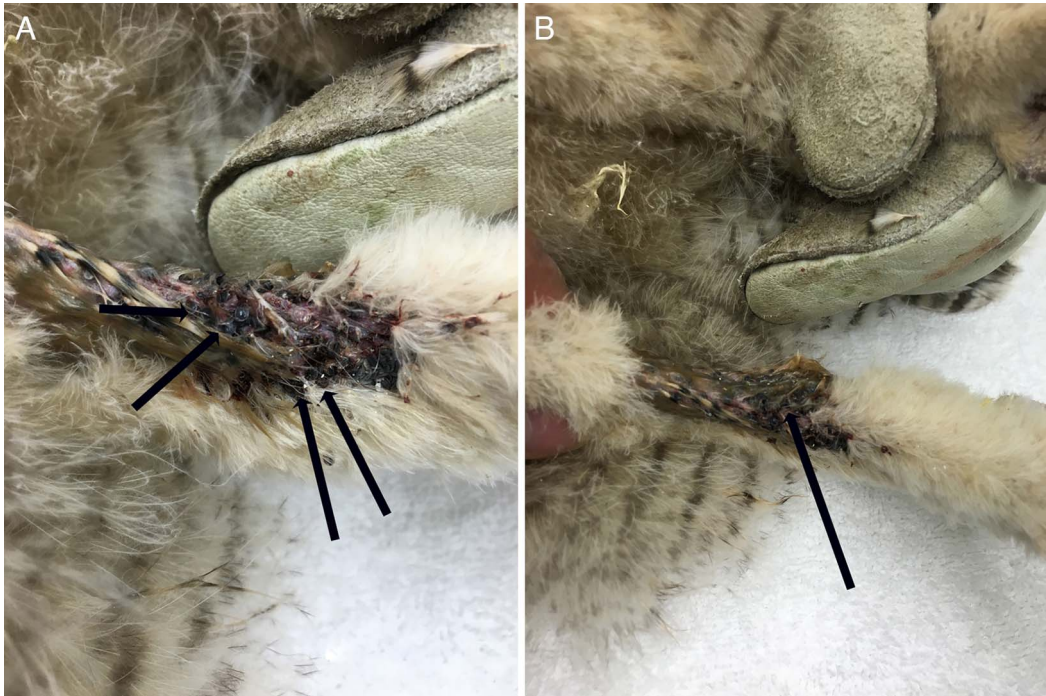


FIGURE 1. On physical examination, numerous larvae of *Argas (Persicargas) giganteus* ticks were discovered on the tarsometatarsal area of a nestling Great Horned Owl (*Bubo virginianus*), from Tucson, Arizona, USA, May 2015. This photograph illustrates (A) the dense spatial arrangement of the ticks and (B) the subcutaneous reaction with hemorrhage (black arrows). Numerous small ticks were firmly attached and remained so following direct acaricide application.

A total of 25% (6/24) of birds died or were euthanized. In these birds, gross findings included focal ecchymoses and petechiae on the skinned surface at the sites of tick attachments. No other significant lesions were found. Histopathologic examination in one Red-tailed Hawk of feathered skin with and without attached parasites, liver, intestines, ventriculus and proventriculus, pancreas, gall bladder, spleen, kidneys, heart, and lungs showed significant severe diffuse lymphoplasmacytic perivascular dermatitis and cellulitis with multifocal acute hemorrhagic necrotizing dermatitis at the site of tick attachments. Incidental findings were protozoan enteropathy and erosive ventriculitis, and the remaining tissues exhibited no significant lesions.

A total of 75% (18/24) of the admitted birds survived. Removal of the ticks was associated with recovery from paralysis; following other supportive care and treatments, the time ranged from 3 d to 7 d for recovery from

complete recumbency to normal perching and eating. The packed cell volume rebounded to normal levels in 1–2 wk, and eosinophilia returned to normal levels in 2–4 wk. Leukocytosis generally tended to respond more rapidly following substitution of doxycycline treatment for ceftazidime. Of the 17 survivors, two birds were transferred to another facility, one bird was a resident, and, after obtaining normal blood parameters and being declared free of ticks for more than 2 wk, 57% (13/23) of birds were released (Table 1).

The vectors

The vast majority of ticks seen in birds were six-legged larval soft ticks. Additionally, an unidentified eight-legged life stage was found on some birds. The soft ticks were examined morphologically (Fig. 4) and identified as larval *A. (P.) giganteus* (Kohls and Clifford 1968). Morphologic characteristics for the

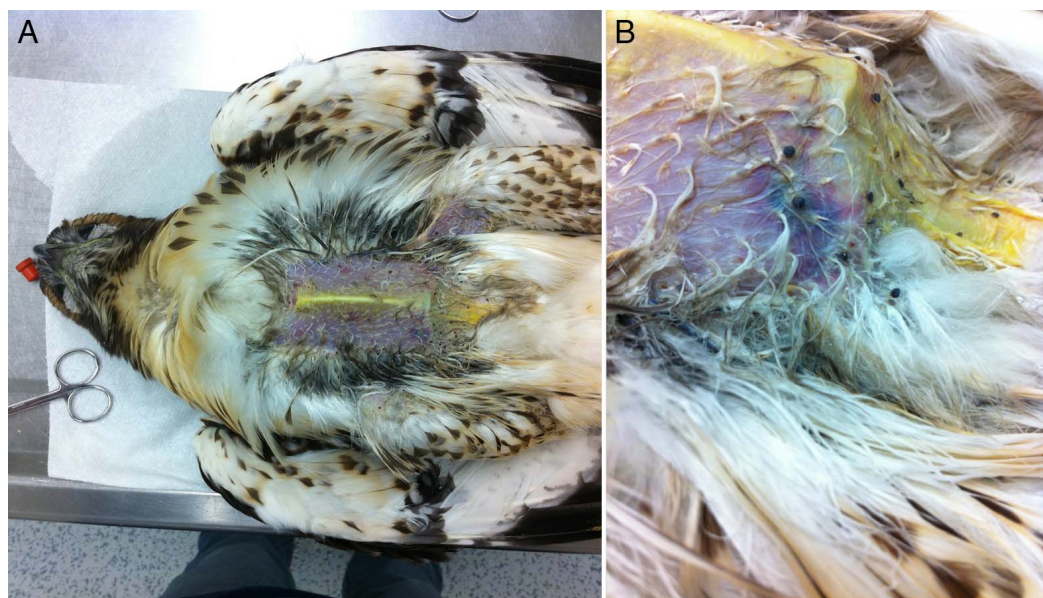


FIGURE 2. A deceased Red-tailed Hawk (*Buteo jamaicensis*) from Tucson, Arizona, USA, was examined and photographed August 2014. (A) A small number of larval *Argas* (*Persicargas*) *giganteus* ticks are seen in typical locations on the ventrum and leg axillae. (B) The right lateral view of the same bird shows the pectoral area with head to the left, illustrating the large ecchymoses and hemorrhage at the attachment site of the ticks.

genus *Argas* included a flattened body with dorsal and ventral surfaces equal in area, and sutural line present with an overall leathery integument. Species-level identification was based upon setal patterns on tarsi I and on shape, dimensions, and dentition of the hypostome, as well as their relatively large size (“*giganteus*”). Seventeen specimens were selected at random for 12S rRNA tick identification PCR; all amplified and yielded sequences of sufficient quality for approximately 330 nucleotides. In this assessed region, sequences were identical to each other, yet not represented in GenBank, with the closest matches being *Argas persicus* (65% query coverage; 88% identity; KJ133581) and *Argas miniatus* (64% query coverage; 87% identity; KC769590). A total of seven specimens for which we had 12S rRNA sequences was randomly selected for ITS-2 and 16S tick identification PCR; all amplified, and three amplicons were selected at random for sequencing. Sequencing of ITS-2 resulted in one tick failing the sequencing reaction; the other two produced forward sequences that were of sufficient quality for approximately

the first 450 nucleotides. In this assessed region, sequences were identical to each other, yet they were not represented in GenBank, with the closest matches being *Argas walkerae* (46% query coverage; 87% identity; KJ133611) and *A. persicus* (22% query coverage; 97% identity; KJ133607). 16S sequencing resulted in all three samples producing forward sequences of approximately 405 nucleotides that were of sufficient quality. In this assessed region, sequences were identical to each other, yet they were not represented in GenBank, with the closest matches being *A. keiransi* (94% query coverage; 96% identity; KJ465101) and *A. persicus* (99% query coverage; 90% identity; GU451248).

The pathogens

From each bird ($n=6$) for which ticks were collected (Table 2), a range of six to 150 ticks were collected per bird. We assayed a total of 54 individual ticks for pathogen prevalence, comprising a random selection of six to 10 ticks per bird. Based on the *gltA* screening for

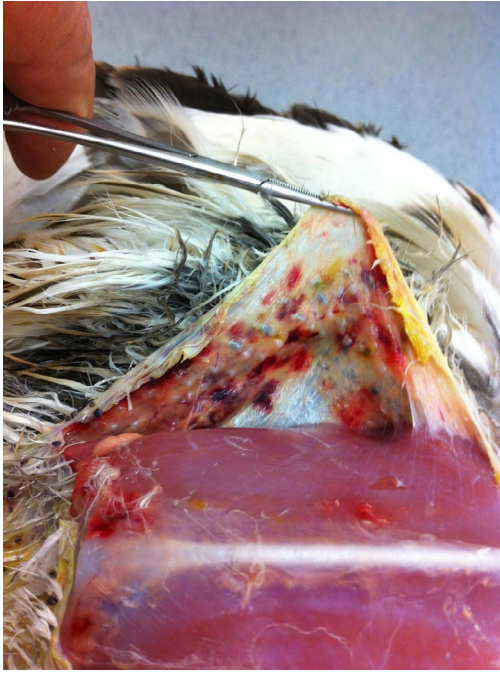

FIGURE 3. The deceased Red-tailed Hawk (*Buteo jamaicensis*) from Tucson, Arizona, USA, August 2014, is shown in the same view as Figure 1, with the ventral skin reflected to demonstrate extensive subcutaneous with hemorrhage and edema associated with *Argas (Persicargas) giganteus* tick insertion. The penetration of the bite into the underlying musculature is also visible.

Rickettsia, 22 of 54 (41%) ticks were positive, in which four birds were associated with positive ticks in which 30–100% of the individual ticks from these birds tested positive (Table 2). In all cases, ticks testing positive in the *gltA* screening assay were confirmed as positive in the *ompB* confirmatory assay. Likewise, the random selection of *gltA*-negative ticks were also negative in the *ompB* assay. All *gltA* sequences were of sufficient quality for a length of approximately 596 nucleotides. In this assessed region, sequences were identical to each other, with three taxa that had an equivalent level of sequence homology in GenBank: uncultured *Rickettsia* sp. clone (94% query coverage; 99% identity; KF360024), *Rickettsia* endosymbiont of *Haemaphysalis sulcata* (94% query coverage; 99% identity; DQ081187), and *Rickettsia hoogstraalii* isolate Rg-731 (94% query cover-

age; 99% identity; MF379282). All *ompB* sequences were of sufficient quality for a length of approximately 671 nucleotides. In this assessed region, sequences were identical to each other, with the closest matches in GenBank being *R. hoogstraalii* strain RCCE3 (97% query coverage; 99% identity; EF629536) and *Rickettsia* sp. scc31 (93% query coverage; 99% identity; DQ105802).

Of the nine avian blood samples tested for *Rickettsia* using the *gltA* screening assay, three yielded an amplicon of the appropriate size but sequencing reactions failed. All nine avian blood samples were also tested for *Rickettsia* using the *ompB* assay, of which six yielded amplicons of the appropriate size but sequencing reactions failed (Table 2).

We assayed a total of 26 individual ticks using the *Borrelia* IGS assay. Of these, six ticks (23%) removed from two birds yielded amplicons of approximately 800 bp. Resulting sequences were identical to each other, but with poor matches to sequences in GenBank: *Borrelia anserina* Es. (100% query coverage; 85% identity; CP013704), *Borrelia anserina* BA2 (100% query coverage; 85% identity; CP005829), and *Borrelia* sp. IM/19 (100% query coverage; 76% identity; DQ000285). Using the 16S qPCR assay, all six of these ticks hybridized with the relapsing fever probe with cycle threshold values ranging from 27.5 to 30.1 in the 45-cycle assay; two amplicons were attempted to be sequenced but both reactions failed. Of the three assays for *glpQ* gene, five of the six ticks amplified using the Fomenko et al. (2011) assay but with failed sequences, all six ticks failed PCR using the Bacon et al. (2005) assay, and five of the six ticks amplified using the Ullmann et al. (2005) assay. Of these five ticks, three were successfully sequenced and identical to each other with the following related taxa in GenBank: *Borrelia anserina* Es. (99% query coverage; 96% identity; CP013704), *Borrelia anserina* BA2 (99% query coverage; 96% identity; CP005829), and uncultured *Borrelia* sp. isolate Carios spiro-2 (99% query coverage; 91% identity; EF688576). All six individual *Borrelia*-positive ticks were also positive for *Rickettsia* (Table 2).

TABLE 2. The details of wild avian infestation with larval *Argas (Persicargas) giganteus* ticks and tick and avian blood infections with agents in the genus *Rickettsia* and *Borrelia* are presented. We assayed a total of 54 individual ticks for pathogen prevalence comprised of a random selection of 6–10 ticks per bird. Based on the *gltA* screening for *Rickettsia*, 22 of 54 (41%) ticks were positive, in which four birds were associated with positive ticks in which 30–100% of the individual ticks from these birds tested positive. Several avian tick and blood samples in our study were associated with PCR amplicons and DNA sequences with imperfect matches to known relapsing fever *Borrelia* species in the GenBank database.^a

Species ^b	Ticks removed	Ticks		Blood	
		% <i>Rickettsia</i> positive (no. positive/ no. tested)	% <i>Borrelia</i> positive (no. positive/ no. tested)	<i>Rickettsia</i> (gene)	% <i>Borrelia</i> positive (no. positive/ no. tested)
RTHA	8	100 (8/8)	50 (3/6)	—	—
COHA	40	30 (3/10)	0 (0/8)	—	—
GRHA	50	50 (5/10)	0 (0/3)	Negative	Negative
RTHA	150	100 (6/6)	100 (3/3)	Negative	60 (3/5)
GHOW	0	—	—	Positive (<i>ompB</i>)	Negative
GHOW	0	—	—	Positive (<i>ompB</i>)	Negative
COHA	0	—	—	Positive (<i>gltA</i> , <i>ompB</i>)	Negative
CORA	0	—	—	Negative	Negative
RTHA	0	—	—	Positive (<i>gltA</i> , <i>ompB</i>)	Negative
RTHA	0	—	—	Positive (<i>gltA</i> , <i>ompB</i>)	Negative
HRSH	0	—	—	Positive (<i>ompB</i>)	Negative
GRRO	25	0 (0/10)	0 (0/3)	—	—
GRHA	15	0 (0/10)	0 (0/3)	—	—

^a — = not tested.
^b RTHA = Red-tailed Hawk (*Buteo jamaicensis*); COHA = Cooper's Hawk (*Accipiter cooperii*); GRHA = Gray Hawk (*Buteo plagiatus*); GHOW = Great Horned Owl (*Bubo virginianus*); CORA = Common Raven (*Corvus corax*); HRSH = Harris's Hawk (*Parabuteo unicinctus*); GRRO = Greater Roadrunner (*Geococcyx californianus*).

Of the nine avian blood samples tested for *Borrelia* using the IGS assay, 11% (1/9) yielded an amplicon of approximately 800 bp that produced a sequence that was identical to the sequences recovered from the ticks on the same birds reported above (Table 2). Using the 16S qPCR assay, this blood was positive for relapsing fever *Borrelia* with a cycle threshold value of 22.9 in the 45-cycle assay; the amplicon failed the sequence reaction. Of the three assays for the *glpQ* gene, this blood sample was negative on the Fomenko et al. (2011) assay yet positive on both of the others; yielding a failed sequence in the Bacon et al. (2005) assay and a sequence with the same related taxa in GenBank as reported above for the ticks in the Ullmann et al. (2005) assay. The single bird with a positive blood sample was a Red-tailed Hawk and this bird also had *Borrelia*-positive ticks attached with the same *Borrelia* sequence as in the blood.

DISCUSSION

Wildlife rehabilitators can play important roles in the front line of disease surveillance and sentinel pathogen detection. We document wild bird infestations with large numbers of the soft tick *A. giganteus* in which approximately one third of infested birds showed distal-to-proximal ascending paralysis and other infested birds were obtunded or showed air hunger and inability to swallow. Numbers of infested birds were small, totaling 23 raptors and related species over the 2-yr period of investigation at a rehabilitation center in Arizona, that admits 2,250–3,000 birds per year. Among the infested birds included individuals with attached ticks at the time of intake from the wild as well as resident birds that acquired ticks on site at the center. Ticks in general are rarely found on birds presented to this facility (well under 10 cases




FIGURE 4. Photograph of (A) dorsal and (B) ventral views of a representative *Argas (Persicargas) giganteus* larval tick, one of many dozens, removed from a moribund Red-tailed Hawk (*Buteo jamaicensis*) in Tucson, Arizona, USA, August 2014. Scale bar=1 mm.

per year), and no infested bird showed paralysis prior to this investigation. In years 2009–13 records indicated similar ticks were noted on other birds, but data were not collected and no specimens of ticks were collected.

Globally, at least 10 species of argasid ticks are known to be involved with paralysis in birds, and even more species of argasid and ixodid ticks have been associated with paralysis in humans and other mammals (Mans et al. 2008). In this study, morbidity via direct injury, blood loss, and immunological impact to the patients was severe, in some cases mitigating their eventual release and potential survival in the wild. Argasid infestations in tropical climates are associated with extensive mortality and morbidity (Hoogstraal 1985). Direct forms of damage include tissue destruction caused by the tick mouth parts and by the local inflammatory reaction of host to tick saliva; loss of blood, which in massive infestations can cause acute anemia; and paralysis caused by tick salivary toxins (Luttrell et al. 1996). All these manifestations were documented here.

Treatment for tick paralysis includes immediate removal of ticks to stop further exposure to salivary toxins. We found *A. giganteus* difficult to remove manually and slow to die immediately from topical application of acaricides. Without accurate knowledge of the natural history of *A. giganteus*, the diagnosis, prevention, treatment, and release criteria for afflicted avian species are difficult to assess and define. Wildlife managers need to be advised how to treat suspect infested nests with appropriate control methods. Critical supportive care for the birds, standard doxycycline antibiotic treatment, and application of acaricides all contributed to the recovery and eventual release of most of the birds. Removal of organic perching, debris, and nesting material was likely essential to prevent expansion of the infestation. Follow-up clinical pathologic analysis and examinations need to meet criteria for release back into the wild.

Little is known about the natural history of *A. giganteus*. Its preferred habitat is presumed to be porous organic materials or crevices (Furman and Loomis 1984). It has been recorded from Arizona, California, New

Mexico and Utah in the US, and from Sonora, Mexico, on small passerines (Kohls and Clifford 1968; Furman and Lewis 1984). *Argas giganteus* larvae attach firmly to the host in their hundreds and feed for prolonged periods through a number of days without retreat, similar to those of *Argas brevipes* (Kohls et al. 1961). It is postulated that *A. giganteus* could be brought northward from the neotropics by migratory hawks, and infest other species by nest sharing, nest building, and nesting behavior (Philips et al. 2002; Belozero 2003; Butler et al. 2003). In the Sonoran Desert, nesting sites and materials for large raptorial species of birds are at a premium, and nest competition is well known (Stensrude 1965; La Porte 2017). Coopers' Hawks, Harris's Hawks, and Gray Hawks often build substantial nests; however, they will also pirate existing nests and steal nesting materials. Great Horned Owls use preexisting nests built by other species. These behaviors could contribute to dispersal of nidicolous and roost-inhabiting tick species, perhaps including *A. giganteus*. Ticks were found on newly admitted birds, birds being held in hospital cages who had not arrived with ticks, birds in flight aviaries ready for release that were uninfested on prior examination, and resident birds. Although it is possible that a few of the ticks were missed on initial examination, the ticks typically appeared in large numbers on the host and it is unlikely that a massive infestation would be missed at admission or on routine examination. It also appeared that the ticks were highly mobile and migrated to adjacent cages rapidly. Thus, it is difficult to determine if ticks emerged in situ, ex situ, or, most likely, both on newly admitted patients. Isolation and biosecurity measures of infested birds are warranted. Because *A. giganteus* was not represented with any DNA sequences in GenBank, the deposition of sequences from our study linked to the definitive morphologic identification of the species will facilitate future molecular-based identification of this tick species.

Although we cannot conclude that the *Rickettsia* and *Borrelia* detected in ticks or blood from the birds in this study contributed

to the clinical status of the birds, the tick-host-pathogen associations and novel pathogen genetic data that we documented may be useful in future etiologic investigations. Based on DNA sequences from two different genes, we conclude that *R. hoogstraalii* or a closely related species infected several of the ticks removed from birds. *Rickettsia hoogstraalii* is a spotted fever group rickettsia with unknown pathogenicity originally isolated in 2006 from *H. sulcata* ticks in Croatia (Duh et al. 2010) and *Carios capensis* ticks in the US (Mattila et al. 2007). *Rickettsia hoogstraalii* infections occur in humans and wildlife (Vatansever 2018), with increasing detections in ticks removed from wild animals worldwide. Since its description, *R. hoogstraalii* has been detected in ticks from Italy, Spain, Japan, Ethiopia, Turkey, and the western Indian Ocean Islands (Kawabata et al. 2006; Marquez et al. 2008; Dietrich et al. 2014; Orkun et al. 2014; Chisu et al. 2017).

Several avian tick and blood samples in our study were associated with PCR amplicons and DNA sequences with imperfect matches to known relapsing fever *Borrelia* species in the GenBank database (<93% sequence homology). Tick-borne relapsing fever *Borrelia* spp. infect humans and animals worldwide; in the western US human infection is often linked to sleeping in rustic cabins or limestone caves in mountainous areas where *Ornithodoros* ticks are present, and the disease is characterized by recurring episodes of fever, headache, muscle and joint aches, and nausea (Dworkin et al. 2008). Relapsing fever remains a neglected disease, with little known about the ecology of disease as it relates to wild vertebrate reservoirs, tick species distributions, and zoonotic potential (Talagrand-Reboul et al. 2018). The presence of these agents in the birds at a wildlife care center should be considered as a zoonotic risk to humans and other patients, and adequate precautions and protocols should be taken. Introduction of new pathogens from exotic ticks of migrating birds is well documented and concern regarding zoonotic potential is well justified (Hamer et al. 2012; Maday 2018; Rainey et al. 2018).

The Sonoran Desert is supported by a decidedly tropical rainy season in the late summer and early autumn. With alterations in climate, including increased rainfall from El Niño Southern Oscillation events and stronger hurricanes over the Gulf of California, there may be increased northward expansion of neotropical flora and fauna, including tick vectors and vector-borne diseases (Estrada-Peña 2001; Gatewood et al. 2009; Randolph 2010). The Gray Hawks in this study are an example of such species that have expanded their breeding range northward in the last 10 yr (eBird 2018). Further investigations to characterize the natural history of *A. giganteus*, associated envenomation and pathogens, and options for tick control and bird treatment will aid in protecting avian health. Additionally, ecological tracking of changing patterns of avian migration and associated importation of ticks and pathogens is necessary to predict and mitigate future disease risk.

ACKNOWLEDGMENTS

Our study was made possible by the staff and volunteers at Tucson Wildlife Center and generous assistance and advice from Drury Reavill from Zoo/Exotic Pathology Services, Carmichael, California, US. The authors thank Lorenza Beati at the US National Tick Collection and Karen Wright at the Texas A&M University Insect Collection for archiving the specimens, and Mark Pilgard of the Centers for Disease Control and Prevention for assistance with *Borrelia* primers. We thank Gabriel Hamer for the photo of a larval tick as seen in Figure 4.

LITERATURE CITED

- Aguirre AA, McLean RG, Cook RS, Quan TJ. 1992. Serologic survey for selected arboviruses and other potential pathogens in wildlife from Mexico. *J Wildl Dis* 28:435–442.
- Armed Forces Pest Management Board. 2012. Tick-borne diseases: Vector surveillance and control. *Armed Forces Pest Management Board Technical Guide* No. 26. Armed Forces Pest Management Board Information Services Division, Silver Spring, Maryland, 40 pp.
- Bacon RM, Pilgard MA, Johnson BJ, Piesman J, Biggerstaff BJ, Quintana M. 2005. Rapid detection methods and prevalence estimation for *Borrelia lonestari* glpQ in *Amblyomma americanum* (Acari: Ixodidae) pools of unequal size. *Vector Borne Zoonotic Dis* 5:146–156.
- Beati L, Keirans JE. 2001. Analysis of the systematic relationships among ticks of the genera *Rhipicephalus* and *Boophilus* (Acari: Ixodidae) based on mitochondrial 12S ribosomal DNA gene sequences and morphological characters. *J Parasitol* 87:32–48.
- Belozerov VN, Van Niekerk DJ, Butler HJ. 2003. Population structure of *Argas arboreus* (Acari: Argasidae) ticks associated with seasonally abandoned mixed heronries, dominated by Cattle Egrets (*Bubulcus ibis*), in South Africa. *Onderstepoort J Vet Res* 70:325–330.
- Bunikis J, Garpmo U, Tsao J, Berglund J, Fish D, Barbour AG. 2004. Sequence typing reveals extensive strain diversity of the Lyme borreliosis agents *Borrelia burgdorferi* in North America and *Borrelia afzelii* in Europe. *Microbiology* 150:1741–1755.
- Butler HJ, Van Niekerk DJ, Belozerov VN. 2003. Population structure of *Argas arboreus* (Acari: Argasidae) ticks associated with seasonally abandoned mixed heronries, dominated by Cattle Egrets (*Bubulcus ibis*), in South Africa. *Onderstepoort J Vet Res* 70:325–330.
- Chisu V, Leulmi H, Masala G, Piredda M, Foxi C, Parola P. 2017. Detection of *Rickettsia hoogstraalii*, *Rickettsia helvetica*, *Rickettsia massiliae*, *Rickettsia slovaca* and *Rickettsia aeschlimannii* in ticks from Sardinia, Italy. *Ticks Tick Borne Dis* 8:347–352.
- Cohen EB, Auckland LD, Marra PP, Hamer SA. 2015. Avian migrants facilitate invasions of Neotropical ticks and tick-borne pathogens into the United States. *Appl Environ Microbiol* 81:8366–8378.
- Dietrich M, Lebarbenchon C, Jaeger A, Le Rouzic C, Bastien M, Lagadec E, McCoy KD, Pascalis H, Le Corre M, Dellagi K, et al. 2014. *Rickettsia* spp. in seabird ticks from western Indian Ocean islands, 2011–2012. *Emerg Infect Dis* 20:838–842.
- Duh D, Punda-Polic V, Avsic-Zupanc T, Bouyer D, Walker DH, Popov VL, Jelovsek M, Gracner M, Trilar T, Bradaric N, et al. 2010. *Rickettsia hoogstraalii* sp. nov., isolated from hard- and soft-bodied ticks. *Int J Syst Evol Microbiol* 60:977–984.
- Dworkin MS, Schwan TG, Anderson DE, Borchardt SM. 2008. Tick-borne relapsing fever. *Infect Dis Clin North Am* 22:449–468.
- eBird. 2018. *Gray Hawk*. <https://ebird.org/barchart?r=US-AZ&bmo=1&emo=12&byr=1900&eyr=2018&spp=grayhaw2>. Accessed June 2018.
- Estrada-Peña A. 2001. Forecasting habitat suitability for ticks and prevention of tick-borne diseases. *Vet Parasitol* 98:111–132.
- Estrada-Peña A, Venzal JM, González-Acuña D, Guglielmone AA. 2003. *Argas (Persicargas) keiransi* n. sp. (Acari: Argasidae), a parasite of the Chimango, *Milvago c. chimango* (Aves: Falconiformes) in Chile. *J Med Entomol* 40:766–769.
- Estrada-Peña A, Venzal JM, González-Acuña D, Mangold AJ, Guglielmone AA. 2006. Notes on New World *Persicargas* ticks (Acari: Argasidae) with description

- of female *Argas (P.) keiransi*. *J Med Entomol* 43:801–809.
- Fomenko NV, Borgoyakov VIu, Panov VV. 2011. [Genetic features of *Borrelia miyamotoi* transmitted by *Ixodes persulcatus*]. *Mol Gen Mikrobiol Virusol* 2:12–17. Russian.
- Furman DP, Loomis EC. 1984. The ticks of California (Acari: Ixodida). *Bulletin of the California Insect Survey*. University of California Press, Berkeley, California, pp. 10–11.
- Gatewood AG, Liebman KA, Vourc'h G, Buniks J, Hamer SA, Cortinas R, Melton F, Cislo P, Kitron U, Tsao J, et al. 2009. Climate and tick seasonality are predictors of *Borrelia burgdorferi* genotype distribution. *Appl Environ Microbiol* 75:2476–2483.
- Hamer SA, Goldberg TL, Kitron UD, Brawn JD, Anderson TK, Loss SR, Walker ED, Hamer GL. 2012. Wild birds and urban ecology of ticks and tick-borne pathogens. *Emerg Infect Dis* 18:1589–1595.
- Hasle G. 2013. Transport of ixodid ticks and tick-borne pathogens by migratory birds. *Front Cell Infect Microbiol* 3:48.
- Hoogstraal H. 1985. Argasid and nuttalliellid ticks as parasites and vectors. *Adv Parasitol* 24:135–238.
- Justice-Allen A, Orr K, Schuler K, McCarty K, Jacobson K, Meteyer C. 2016. Bald eagle nestling mortality associated with *Argas radiatus* and *Argas ricei* tick infestation and successful management with nest removal in Arizona, USA. *J Wildl Dis* 52:940–944.
- Kawabata H, Ando S, Kishimoto T, Kurane I, Takano A, Nogami S, Fujita H, Tsurumi M, Nakamura N, Sato F, et al. 2006. First detection of *Rickettsia* in soft-bodied ticks associated with seabirds, Japan. *Microbiol Immunol* 50:403–406.
- Kohls GM, Clifford CM. 1968. The subgenus *Persicargas* (Ixodoidea, Argasidae, *Argas*). 6. *A. (P.) giganteus*, n. sp., from wild birds in Western United States and Sonora, Mexico. *Ann Entomol Soc Am* 61:1113–1116.
- Kohls GM, Hoogstraal H, Clifford CM. 1961. Observations on the Subgenus *Argas* (Ixodoidea, Argasidae, *Argas*). 5. Study of *A. brevipes* Banks, 1908, from birds in Arizona and California, USA., and Baja California, Mexico. *Ann Entomol Soc Am* 54:869–877.
- La Porte A. 2017. *Gray Hawk expansion in the San Pedro River Valley: Diet, habitat, and landscape change*. PhD Dissertation, University of Arizona, Tucson, Arizona, 198 pp.
- Luttrell MP, Creekmore LH, Mertins JW. 1996. Avian tick paralysis caused by *Ixodes brunneus* in the Southeastern United States. *J Wildl Dis* 32:133–136.
- Maday J. 2018. *Longhorned ticks now in four states*. <https://www.drovers.com/article/longhorned-ticks-now-four-states>. Accessed June 2018.
- Mangold AJ, Bargues MD, Mas-Coma S. 1998. Mitochondrial 16S rDNA sequences and phylogenetic relationships of species of *Rhipicephalus* and other tick genera among Metastriata (Acari: Ixodidae). *Parasitol Res* 84:478–484.
- Mans BJ, Gothe R, Neitz AWH. 2008. Tick toxins: Perspectives on paralysis and other forms of toxicoses caused by ticks. In: *Ticks: Biology, disease and control*, Bowman AS, Nuttall PA, editors. Cambridge University Press, Cambridge, UK, pp. 108–126.
- Manzano-Román R, Díaz-Martín V, de la Fuente J, Pérez-Sánchez R. 2012. Soft ticks as pathogen vectors: Distribution, surveillance and control. In: *Parasitology*, Shah MM, editor. InTech, Rijeka, Croatia, pp. 125–162.
- Marquez FJ, Rodriguez-Liebana JJ, Soriguer RC, Muniaín MA, Bernabeu-Wittel M, Caruz A, Contreras-Chova F. 2008. Spotted fever group *Rickettsia* in brown dog ticks *Rhipicephalus sanguineus* in southwestern Spain. *Parasitol Res* 103:119–122.
- Mattila JT, Burkhardt NY, Hutcheson HJ, Munderloh UG, Kurtti TJ. 2007. Isolation of cell lines and a rickettsial endosymbiont from the soft tick *Carios capensis* (Acari: Argasidae: Ornithodorinae). *J Med Entomol* 44:1091–1101.
- Mukherjee N, Beati L, Sellers M, Burton L, Adamson S, Robbins RG, Karim S. 2014. Importation of exotic ticks and tick-borne spotted fever group rickettsiae into the United States by migrating songbirds. *Ticks Tick Borne Dis* 5:127–134.
- Ogden NH, Lindsay LR, Hanincová K, Barker IK, Bigras-Poulin M, Charron DF, Heagy A, Francis CM, O'Callaghan CJ, Schwartz I, et al. 2008a. Role of migratory birds in introduction and range expansion of *Ixodes scapularis* ticks and of *Borrelia burgdorferi* and *Anaplasma phagocytophilum* in Canada. *Appl Environ Microbiol* 74:1780–1790.
- Ogden NH, St-Onge L, Barker IK, Brazeau S, Bigras-Poulin M, Charron DF, Francis CM, Heagy A, Lindsay LR, Maarouf A, et al. 2008b. Risk maps for range expansion of the Lyme disease vector, *Ixodes scapularis*, in Canada now and with climate change. *Int J Health Geogr* 7:24.
- Orkun Ö, Karaer Z, Çakmak A, Nalbantoğlu S. 2014. Identification of tick-borne pathogens in ticks feeding on humans in Turkey. *PLoS Negl Trop Dis* 8:e3067.
- Philips JR, Hunt GW, Matteson SW. 2002. Arthropods from a zone-tailed hawk nest in Texas. *Southwest Entomol* 27:293–295.
- Rainey T, Occi JL, Robbins RG, Egizi A. 2018. Discovery of *Haemaphysalis longicornis* (Ixodida:Ixodidae) parasitizing a sheep in New Jersey, United States. *J Med Entomol* 55:757–759.
- Randolph SE. 2010. To what extent has climate change contributed to the recent epidemiology of tick-borne diseases? *Vet Parasitol* 167:92–94.
- Raoult D, Fournier PE, Fenollar K, Jensenius M, Prieur T, de Pina JJ, Caruso G, Jones N, Laferl H, Rosenblatt JE, et al. 2001. *Rickettsia africae*, a tick-borne pathogen in travelers to sub-Saharan Africa. *N Engl J Med* 344:1504–1510.
- Rappole JH, Glasscock S, Goldberg K, Song D, Faridani S. 2011. Range change among new world tropical and subtropical birds. *Bonn Zool Monogr* 57:151–167.
- Sonenshine DE. 2018. Range expansion of tick disease vectors in North America: Implications for spread of

- tick-borne disease. *Int J Environ Res Public Health* 15:E478.
- Stensrude C. 1965. Observations on a pair of Gray Hawks in southern Arizona. *Condor* 67:319–321.
- Talagrand-Reboul E, Boyer PH, Bergström S, Vial L, Boulanger N. 2018. Relapsing fevers: Neglected tick-borne diseases. *Front Cell Infect Microbiol* 8:98.
- Tsao JI, Wootton JT, Bunikis J, Luna MG, Fish D, Barbour AG. 2004. An ecological approach to preventing human infection: Vaccinating wild mouse reservoirs intervenes in the Lyme disease cycle. *Proc Natl Acad Sci U S A* 101:18159–18164.
- Ullmann AJ, Gabitzsch ES, Schulze TL, Zeidner NS, Piesman J. 2005. Three multiplex assays for detection of *Borrelia burgdorferi* sensu lato and *Borrelia miyamotoi* sensu lato in field-collected *Ixodes* nymphs in North America. *J Med Entomol* 42:1057–1062.
- Vatansever Z. 2018. *Haemaphysalis parva* (Neumann, 1897) (Figs. 100–102). In: *Ticks of Europe and North Africa: A guide to species identification*, Estrada-Peña A, Mihalca AD, Petney TN, editors. Springer International Publishing, Cham, Switzerland, pp. 259–263.
- Williamson PC, Billingsley PM, Teltow GJ, Seals JP, Turnbough MA, Atkinson SF. 2010. *Borrelia*, *Ehrlichia*, and *Rickettsia* spp. in ticks removed from persons, Texas, USA. *Emerg Infect Dis* 16:441–446.
- Zahler M, Gothe R, Rinder H. 1995. Diagnostic DNA amplification from individual tick eggs, larvae and nymphs. *Exp Appl Acarol* 19:731–736.

Submitted for publication 24 November 2018.

Accepted 16 May 2019.