



## **Mycoplasma conjunctivae-Associated Keratoconjunctivitis in Norwegian Muskox (*Ovibos moschatus*)**

Authors: Handeland, Kjell, Madslie, Knut, Bretten, Tord, Røtvei, Ingolf, Våge, Jørn, et al.

Source: Journal of Wildlife Diseases, 56(2) : 489-491

Published By: Wildlife Disease Association

URL: <https://doi.org/10.7589/2019-04-103>

---

BioOne Complete ([complete.BioOne.org](https://complete.bioone.org)) is a full-text database of 200 subscribed and open-access titles in the biological, ecological, and environmental sciences published by nonprofit societies, associations, museums, institutions, and presses.

Your use of this PDF, the BioOne Complete website, and all posted and associated content indicates your acceptance of BioOne's Terms of Use, available at [www.bioone.org/terms-of-use](https://www.bioone.org/terms-of-use).

Usage of BioOne Complete content is strictly limited to personal, educational, and non-commercial use. Commercial inquiries or rights and permissions requests should be directed to the individual publisher as copyright holder.

---

BioOne sees sustainable scholarly publishing as an inherently collaborative enterprise connecting authors, nonprofit publishers, academic institutions, research libraries, and research funders in the common goal of maximizing access to critical research.

## *Mycoplasma conjunctivae*-Associated Keratoconjunctivitis in Norwegian Muskox (*Ovibos moschatus*)

Kjell Handeland,<sup>1,5,6</sup> Knut Madslie,<sup>1</sup> Tord Bretten,<sup>2</sup> Ingolf Røtvei,<sup>3</sup> Jørn Våge,<sup>1</sup> and Torstein Tengs<sup>4</sup> <sup>1</sup>Norwegian Veterinary Institute, PO Box 750 Sentrum, 0106 Oslo, Norway; <sup>2</sup>Norwegian Environment Agency, PO Box 5672 Torgarden, 7485 Trondheim, Norway; <sup>3</sup>Oppdal Bygdealmening, Inge Krokanns veg 11, 7340 Oppdal, Norway; <sup>4</sup>Norwegian University of Life Sciences, PO Box 5003, 1432 Ås, Norway; <sup>5</sup>Present address: Østvedthagen 57, 3943 Porsgrunn, Norway; <sup>6</sup>Corresponding author (email: kjellhandeland@gmail.com)

**ABSTRACT:** In late summer 2014, an outbreak of ocular disease occurred in the Norwegian muskox (*Ovibos moschatus*) population. Animals showed rings of pus around their eyes and one euthanized animal was diagnosed with acute keratoconjunctivitis. The DNA sequence analysis of eye-swab samples from this animal revealed a high abundance of *Mycoplasma conjunctivae*.

The muskox (*Ovibos moschatus*) is an arctic ruminant belonging to the bovid subfamily Caprinae. The Norwegian population was introduced (1947–53) from Greenland and lives on the high mountain plateau of Dovrefjell in southern Norway. Its defined home range encompasses 34,000 ha (center: 62°20'N, 9°30'E) and domestic sheep (*Ovis aries*) are also present during the summer season. Muskox and sheep generally avoid each other and close interspecies contact is only seen at salt-lick sites established for sheep. The health status of the muskox population is monitored by the Norwegian Nature Inspectorate in cooperation with the Norwegian Veterinary Institute as part of the Health Surveillance Program for Cervids and Muskox. Three major disease outbreaks have been recognized in this muskox population: an outbreak of contagious ecthyma in the summer of 2004 (Vikøren et al. 2008) and two outbreaks of pneumonia in the summers of 2006 (Ytrehus et al. 2008) and 2012 (Handeland et al. 2014). The primary cause of the 2012 pneumonia outbreak was found to be *Mycoplasma ovipneumoniae* and cograzing sheep were considered the likely source of infection. We report an outbreak of ocular disease, presumably infectious keratoconjunctivitis (IKC), that occurred in the late summer of 2014.

Infectious keratoconjunctivitis is a common transmissible ocular disease in ruminants worldwide. The primary cause varies between species and clinical signs range from mild conjunctivitis to severe keratoconjunctivitis. *Mycoplasma conjunctivae* is considered the primary agent of IKC in domestic and wild Caprinae (Egwu 1989; Mayer et al. 1996). In a study of Norwegian sheep herds, *M. conjunctivae* was the most frequently isolated agent, followed by *Moraxella ovis* (Åkerstedt and Hofshagen 2004). Whereas clinical signs are normally moderate in domestic sheep, severe outbreaks have been reported in wild Caprinae in the European Alps and in the Pyrenees (Giacometti et al. 2002). In sheep populations this agent seems to be self maintained by healthy carriers (Janovsky et al. 2001), whereas infection of wild Caprinae has been considered dependent on transmission from sheep (Belloy et al. 2003). However, recent studies suggest that *M. conjunctivae* may also occur endemically in wildlife populations (Gelormini et al. 2017).

During a field visit on 5 September 2014 primarily conducted to necropsy two muskox calves found dead by hikers, we detected a small herd of muskoxen with rings of pus around their eyes. A new field visit was carried out on 16 September and another three herds were inspected. All inspections were carried out using binoculars or a telescope at approximately 100- to 200-m distance. From a total of 37 muskoxen in the four herds inspected (approx. 15% of the total population), 95% (35/37) showed unilateral or bilateral rings of pus around their eyes (Fig. 1). Some individuals displayed forced blinking and squeezing of the eyelids and numerous flies were observed around the heads of the animals.



FIGURE 1. Muskox (*Ovibos moschatus*) from Dovrefjell, Norway with crusts (pus) around the eye, 10 September 2014.

On 17 September, an old bull displaying locomotory problems was reported to the Norwegian Nature Inspectorate. At inspection, the bull showed signs of posterior paresis, held its right eye closed, and was euthanized on animal welfare grounds. At postmortem, the right eye was surrounded with a ring of semisolid pus and showed signs of acute keratoconjunctivitis, with hyperemic conjunctiva and an opaque cornea, covered by a mucopurulent exudate. The left eye seemed clinically unaffected. Swab samples were taken from the conjunctival sac of each eye and preserved in an in-house virus transport medium containing penicillin, streptomycin, and amphotericin B.

We extracted DNA from the swabs using the NucliSENS easyMAG DNA/RNA extraction system (bioMérieux, Inc., Durham, North

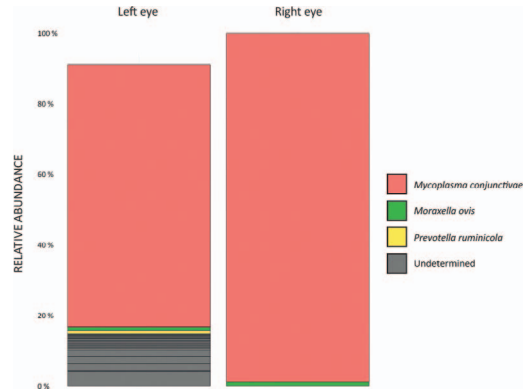


FIGURE 2. Relative abundance plots for bacterial DNA sequence variants found in eye swabs from a muskox (*Ovibos moschatus*) with clinical keratoconjunctivitis in its right eye that was euthanized on 17 September 2014.

Carolina, USA). The DNA was amplified using the 16S V4 primers developed by the Earth Microbiome Project (2019). This primer pair targets the V4-part of the 16S small-subunit ribosomal (r)RNA gene (5'–3', primer names indicate position within 16S gene), 515F (tail for Illumina sequencing/indexing)-GTGYCAGCMGCCGCGGTAA; and 806R (tail for Illumina sequencing/indexing)-GGACTACNVTGGGTWTCTAAT. The PCR products were sequenced using the Illumina MiSeq system (Illumina Inc., San Diego, California, USA). Raw fastq reads were analyzed using the DADA2 R package with default settings (DADA2 Pipeline Tutorial v. 1.12; Callahan et al. 2016). Relative abundance plots for the 20 most abundant sequence variants were made using the Silva database version 132 for annotation (SILVA rRNA database project 2019). A BLAST search of the partial *M. conjunctivae* 16S sequence against the nucleotide collection in GenBank confirmed the identity of the sequence (National Center for Biotechnology Information 2019). For both eyes, the dominant bacterial species identified was *M. conjunctivae* (Fig. 2). In addition, a few sequences from *Moraxella ovis* and *Prevotella ruminicola* were identified, as well as sequence variants that could not be reliably identified at the species level. Some of these

sequences could conceivably reflect sample contamination or sequencing errors.

Our field observations indicated an extensive outbreak of transmissible eye disease in the muskox population. Although only confirmed by postmortem examination of one animal, we suggest this to be an outbreak of IKC, primarily caused by *M. conjunctivae*. This infection has not previously been reported in muskox and we suspect cograzing domestic sheep as a primary source of infection. *Mycoplasma conjunctivae* is transmitted through animal contact (Hosie 1988) and may also be transmitted by eye-frequenting flies (*Musca* spp.; Fernández-Aguilar et al. 2019). Fernández-Aguilar et al. (2019) demonstrated a close association between *M. conjunctivae* in the eyes and nose (the route of excretions from the eye) and suggested nasal secretions as an important source for *M. conjunctivae* transmission. We consider flies to have contributed to the rapid spread of *M. conjunctivae* in muskox. The salt-lick sites created artificial interspecies contact with the potential risk of transmission from sheep to muskox, both via flies and nasal secretions. Since the muskox destroy salt stone racks, the stones are placed directly on the ground, a position that increases the risk of contamination with nasal secretions. Further studies should be carried out to compare *M. conjunctivae* isolates from sheep and muskox by molecular methods and to determine whether the muskox may serve as a maintenance host for *M. conjunctivae*.

#### LITERATURE CITED

- Åkerstedt J, Hofshagen M. 2004. Bacteriological investigations of infectious keratoconjunctivitis in Norwegian sheep. *Acta Vet Scand* 45:19–26.
- Belloy L, Janovsky M, Vilei EM, Pilo P, Giacometti M, Frey J. 2003. Molecular epidemiology of *Mycoplasma conjunctivae* in Caprinae: Transmission across species in natural outbreaks. *Appl Environ Microbiol* 69:1913–1919.
- Callahan BJ, McMurdie PJ, Rosen MJ, Han AW, Johnson AJ, Holmes SP. 2016. DADA2: High-resolution sample inference from Illumina amplicon data. *Nat Methods* 13:581–583.
- Earth Microbiome Project. 2019. *16S Illumina amplification protocol*. [www.earthmicrobiome.org/protocols-and-standards/16s/](http://www.earthmicrobiome.org/protocols-and-standards/16s/). Accessed October 2019.
- Egwu GO. 1989. *Ovine keratoconjunctivitis: Some studies on the role of Mycoplasma conjunctivae*. PhD Thesis, University of Liverpool, Liverpool, UK, 269 pp.
- Fernández-Aguilar X, López-Olvera JR, Ribas MP, Begovoeva M, Velarde R, Cardells J, Cabezón O. 2019. *Mycoplasma conjunctivae* in insect vectors and anatomic location related to transmission and persistence. *Vet Microbiol* 228:7–11.
- Gelormini G, Gauthier D, Vilei EM, Crampe JP, Frey J, Ryser-Degiorgis MP. 2017. Infectious keratoconjunctivitis in wild Caprinae: Merging field observations and molecular analyses sheds light on factors shaping outbreak dynamics. *BMC Vet Res* 13:67.
- Giacometti M, Janovsky M, Belloy L, Frey J. 2002. Infectious keratoconjunctivitis of ibex, chamois and other Caprinae. *Rev Sci Tech* 21:335–345.
- Handeland K, Tengs T, Kokotovic B, Vikøren T, Ayling RD, Bergsjø B, Sigurðardóttir ÓG, Bretten T. 2014. *Mycoplasma ovipneumoniae*—A primary cause of severe pneumonia epizootics in the Norwegian muskox (*Ovibos moschatus*) population. *PLoS One* 9:e106116.
- Hosie BD. 1988. Keratoconjunctivitis in a hill sheep flock. *Vet Rec* 122:40–43.
- Janovsky M, Frey J, Nicolet J, Belloy L, Goldschmidt-Clermont E, Giacometti M. 2001. *Mycoplasma conjunctivae* infection is self-maintained in the Swiss domestic sheep population. *Vet Microbiol* 83:11–22.
- Mayer D, Nicolet J, Giacometti M, Schmitt M, Wahli T, Meier W. 1996. Isolation of *Mycoplasma conjunctivae* from conjunctival swabs of Alpine ibex (*Capra ibex ibex*) affected with infectious keratoconjunctivitis. *J Vet Med B* 43:155–161.
- National Center for Biotechnology Information. 2019. *Basic local alignment search tool (BLAST)*. <http://blast.ncbi.nlm.nih.gov/Blast.cgi>. Accessed October 2019.
- SILVA rRNA database project 2019. *Archive file repository*. [www.arb-silva.de/no\\_cache/download/archive/release\\_132/](http://www.arb-silva.de/no_cache/download/archive/release_132/). Accessed October 2019.
- Vikøren T, Lillehaug A, Åkerstedt J, Bretten T, Haugum M, Tryland M. 2008. A severe outbreak of contagious ecthyma (orf) in a free-ranging musk ox (*Ovibos moschatus*) population in Norway. *Vet Microbiol* 127:10–20.
- Ytrehus B, Bretten T, Bergsjø B, Isaksen K. 2008. Fatal pneumonia epizootic in musk ox (*Ovibos moschatus*) in a period of extraordinary weather conditions. *Ecohealth* 5:213–223.

Submitted for publication 25 April 2019.

Accepted 6 September 2019.