



Esophageal stricture caused by rib osteoma in a cat: case report

Authors: Cunha, Simone CS, Corgozinho, Katia B, Martins, Mauro C,
and Ferreira, Ana MR

Source: Journal of Feline Medicine and Surgery Open Reports, 1(1)

Published By: SAGE Publishing

URL: <https://doi.org/10.1177/2055116915589835>

BioOne Complete (complete.BioOne.org) is a full-text database of 200 subscribed and open-access titles in the biological, ecological, and environmental sciences published by nonprofit societies, associations, museums, institutions, and presses.

Your use of this PDF, the BioOne Complete website, and all posted and associated content indicates your acceptance of BioOne's Terms of Use, available at www.bioone.org/terms-of-use.

Usage of BioOne Complete content is strictly limited to personal, educational, and non - commercial use. Commercial inquiries or rights and permissions requests should be directed to the individual publisher as copyright holder.

BioOne sees sustainable scholarly publishing as an inherently collaborative enterprise connecting authors, nonprofit publishers, academic institutions, research libraries, and research funders in the common goal of maximizing access to critical research.



Esophageal stricture caused by rib osteoma in a cat: case report

Simone CS Cunha¹, Katia B Corgozinho², Mauro C Martins³
and Ana MR Ferreira¹

Journal of Feline Medicine and Surgery
Open Reports
 1–6

© The Author(s) 2015
 Reprints and permissions:
sagepub.co.uk/journalsPermissions.nav
 DOI: 10.1177/2055116915589835
jfmsopenreports.com



Abstract

Case summary A 6-year-old male domestic shorthair cat presented with frequent food regurgitation and dysphagia. Plain thoracic radiographs revealed a calcified mass overlying the topography of the mediastinum, as well as dilation of the cervical portion of the esophagus due to an accumulation of food. Endoscopic examination showed a severe extraluminal esophageal stricture at the mediastinum entrance. Surgery and a gastric tube were declined by the cat's owner, with palliative support preferred. However, 1 year later, the cat presented with severe cachexia, dysphagia, salivation, dehydration and inspiratory dyspnea. Thoracic computed tomography was performed to evaluate the possibility of surgical resection. A mass of bone density originating in the second left rib was observed. The mass did not appear to have invaded adjacent structures but marked compression of the mediastinal structures was observed. Surgical resection was performed and a prosthetic mesh was used to reconstruct the thoracic wall. Transient Horner's syndrome developed in the left eye postoperatively, and was resolved within 4 weeks. Histopathology revealed a benign osteoma. Thirty-two months after surgery, the cat was well and free of disease.

Relevance and novel information Rib tumors should be included in a differential diagnosis in cats with extraluminal esophageal stricture. CT should be performed for treatment planning. Surgical treatment was curative in this case.

Accepted: 3 November 2014

Introduction

Esophageal strictures can be congenital or acquired. The latter can be due to injury from ingestion of caustic chemicals, esophageal foreign bodies, esophageal surgery, or intra- or extraluminal mass lesions (neoplasia or abscesses).^{1,2} In cats, esophageal strictures are commonly associated with the administration of doxycycline.^{1,2} However, primary esophageal tumors, such as squamous cell carcinoma, have also been associated with esophageal stricture.³ In addition, mediastinal masses, such as lymphoma and thymoma, are frequently diagnosed in cats and can cause extraluminal esophageal compression.^{2,4} Clinical signs of esophageal stricture include regurgitation of solid food shortly after feeding, dysphagia and salivation. Useful diagnostic modalities for esophageal disease included plain radiography, fluoroscopy, barium radiography, computed tomography (CT) and an endoscopy.^{1,2}

To our knowledge, this paper reports the first case of esophageal stricture caused by a rib osteoma in a cat. Successful treatment was achieved with surgical resection.

Case summary

A 6-year-old male domestic shorthair cat presented with frequent food regurgitation and dysphagia. Clinical signs had become apparent 3 months earlier, and, according to the cat's owner, had been getting worse. Solid food was regurgitated shortly after feeding several times a day, although liquid meals were tolerated.

A clinical examination revealed normal mucous membranes, mild dehydration, a rectal temperature of 39.3°C, a body weight of 5.8 kg, a dry coat and normal auscultation. The cat had only received deworming medication 6 months earlier and had no history of doxycycline administration.

¹Fluminense Federal University, Niterói, Rio de Janeiro, Brazil

²Federal Rural University of Rio de Janeiro, Veterinary Institute, Seropédica, Rio de Janeiro, Brazil

³Veterinary Reference Center, Barra da Tijuca, Rio de Janeiro, Brazil

Corresponding author:

Simone CS Cunha DVM, PhD, Fluminense Federal University, Rua Vital Brazil Filho, 64, Niterói, Rio de Janeiro, Brazil
 Email: simonecsc@gmail.com



Creative Commons CC-BY-NC: This article is distributed under the terms of the Creative Commons Attribution-NonCommercial 3.0 License (<http://www.creativecommons.org/licenses/by-nc/3.0/>) which permits non-commercial use, reproduction and distribution of the work without further permission provided the original work is attributed as specified on the SAGE and Open Access page (<http://www.uk.sagepub.com/aboutus/openaccess.htm>).

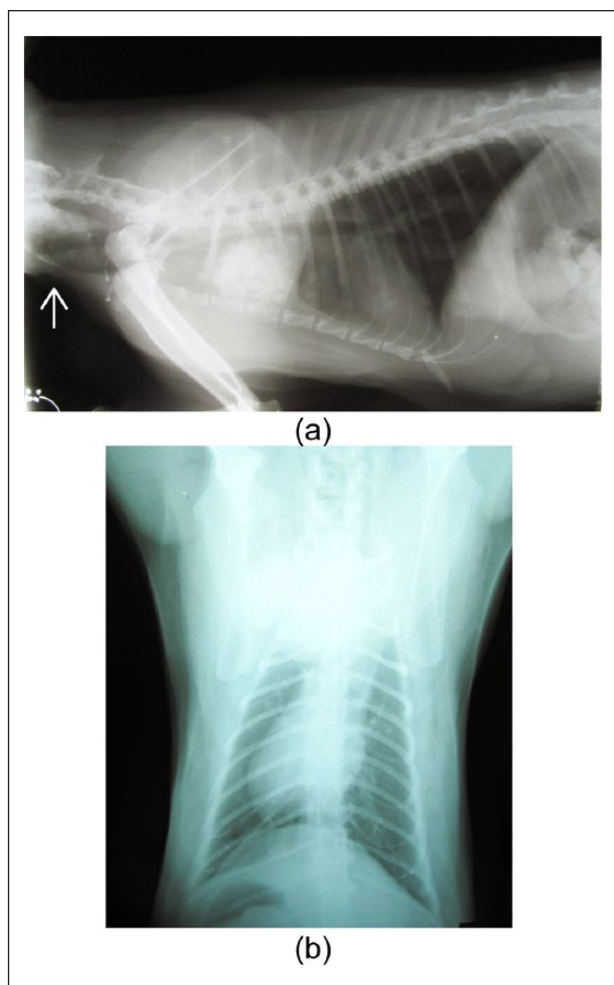


Figure 1 A calcified mass overlying the topography of the mediastinum was revealed in the examined cat. (a) A lateral thoracic radiograph reveals dilation of the cervical esophagus (white arrow) and the presence of a calcified mass (black arrow). (b) A ventrodorsal radiograph shows the mass

Blood tests, feline immunodeficiency virus (FIV) and feline leukemia virus (FeLV) serology, cervical and thoracic survey radiographs, abdominal ultrasound and an endoscopy were performed. The hematologic results and abdominal ultrasound were unremarkable, and serology for both FIV and FeLV was negative. However, the radiographs revealed a calcified mass overlying the topography of the cranial mediastinum and dilation of the esophagus due to a soft tissue density consistent with ingesta (Figure 1). An endoscopic examination showed a severe extraluminal esophageal stricture at the entry to the mediastinum.

Based on these results, the presumed diagnosis was neoplasia (osteosarcoma, condrosarcoma, lymphoma or carcinoma). When a fine-needle aspiration of the thoracic mass was performed, the cytology results suggested a tumor of mesenchymal origin, and an osteosarcoma was suspected.

A surgical approach was considered. However, owing to the large dimensions of the mass detected, wide margins would be required if the mass was an osteosarcoma, and the brachial plexus would potentially be affected. Both the surgeons and the cat's owner considered surgery to be an aggressive treatment approach. Insertion of a gastric tube was proposed as a supportive treatment, and this was also declined by the owner. However, the owner agreed to a trial of liquid meals. Hill's a/d prescription diet (15 ml) was offered to the cat every 2 h. Omeprazole (1 mg/kg Gaviz; Agener União) was also administered orally q24h, while sucralfate (0.25 g/ml Sucrafilm; EMS) was administered orally q8h. Regurgitation became less frequent, although it continued to occur 2–3 times daily. Marked weight loss was noted but the owner declined a gastric tube owing to the observed activity level of the cat.

Twelve months later, the cat presented with severe cachexia, dysphagia and salivation. It weighed 3.5 kg and exhibited severe dehydration, pale mucous membranes, stertor, inspiratory dyspnea and had a rectal temperature of 37.2°C. An infusion of Ringer's lactate solution was started, and ceftriaxone (50 mg/kg Rocephin; Roche) was administered subcutaneously q24h. The animal was found to be starving and was struggling to consume any food. The cat could not swallow anything.

The owner was advised to submit the cat to surgery or euthanasia. A thoracic CT examination was performed to evaluate the possibility of surgical resection because radiographs were not able to evaluate the exact origin of the mass and its adherence/invasion in relation to adjacent structures. A 24 G intravenous catheter was placed in the cephalic vein and anesthesia was induced with propofol (Propofol; Biosintetica). Anesthesia was maintained with isoflurane (Forane; Abbott) in 100% oxygen. The CT examination was performed in sternal recumbency. Images were acquired with soft tissue, and bone algorithms and a non-ionic iodinated contrast agent (300 mg I/ml iohexol) was administered. A hyperattenuating and heterogeneous mass was detected with bone density, and it originated in the second left rib. The mass appeared irregular, yet had well-defined margins. No invasion of adjacent structures was observed. However, marked compression of mediastinal structures (eg, cranial cava, esophagus, trachea, brachiocephalic trunk and left subclavian artery) was observed. The dimensions of the mass were $5.0 \times 3.5 \times 4.2$ cm³. Esophageal dilation was noted (both pre- and postlesion), with food retention observed in the cervical portion. The trachea was shifted to the right with mild stenosis. Restricted expansion of the apical lobe of the left cranial lung lobe was also observed, with no evidence of edema, masses or lung metastasis (Figure 2).

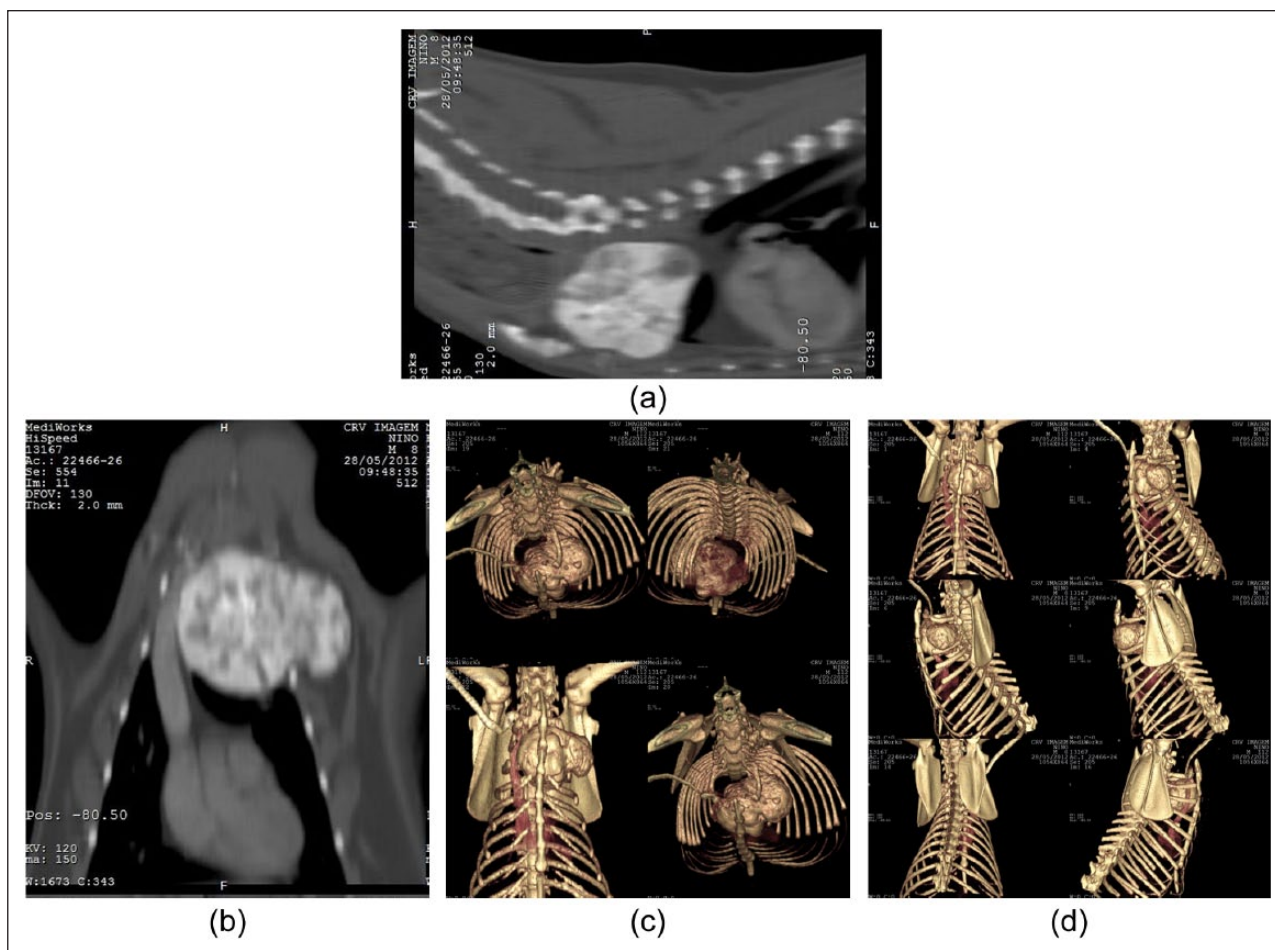


Figure 2 (a–d) Thoracic computed tomography (sagittal and dorsal multiplanar reconstruction and rendering volume) revealed a heterogeneous mass with bone density. The mass was found to originate in the second left rib with esophageal and tracheal compression

Based on these results, surgery was the preferred option. Blood tests were performed and only mild anemia and lymphopenia were detected. Biochemistry analyses further revealed normal levels of alanine transaminase, blood urea nitrogen, creatinine, potassium, glucose, albumin and globulin.

Methadone (0.3 mg/kg Mytedon; Cristalia) was administered intramuscularly 15 mins prior to anesthetic induction with diazepam (0.2 mg/kg IV Valium; Roche), and this was immediately followed by intravenous (IV) administration of 4 mg/kg propofol. Anesthesia was maintained with isoflurane. The patient was placed in right lateral recumbency and a skin incision was made through the underlying muscle to the level of the chest wall. A left intercostal thoracotomy was performed cranial and caudal to the mass, and the chest wall was removed en bloc. Intercostal vessels caudal to the ribs were also ligated. The mass was not adherent to intrathoracic structures (Figure 3), and four ribs were resected. A polypropylene prosthetic mesh (Marlex; Chevron

Phillips) was used to reconstruct the thoracic wall. A piece of mesh larger than the defect was cut and the periphery was folded over by 1 cm to allow a more solid area to hold sutures. Musculature was approximated and the skin was closed routinely. A gastric tube was also placed.

After surgery, 50 mg/kg ceftriaxone was administered intravenously Q24h for 10 days, 0.1 mg/kg meloxicam (Maxicam; Ourofino) was administered subcutaneously (SC) Q24h for 3 days, 0.3 mg/kg methadone was administered intramuscularly q8h for 5 days and 25 mg/kg metamizole (Novalgina; Sanofi) was administered SC q12h for 3 days. Horner's syndrome was observed immediately in the left eye after recovery from anesthesia (Figure 4). Food was given by gastric tube and Hill's a/d was started 24 h after surgery (5 ml q3h on day 1, 10 ml q3h on day 2, 15 ml q3h on day 3 and 20 ml q3h on day 4). On day 5, Hill's a/d was given orally and was well accepted. Seven days after surgery, small amounts of dry food were introduced, also with

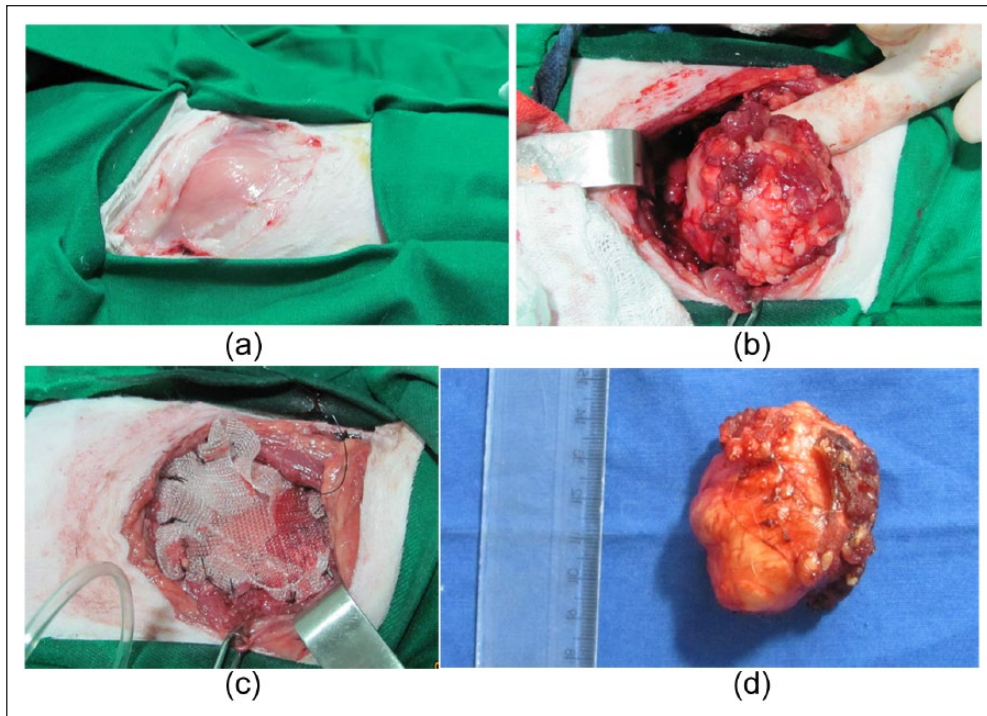


Figure 3 An intraoperative photograph the rib mass resection performed. (a) The rib mass was observed after an incision in the skin was made. (b) The lateral thorax was entered at the proposed intercostal space of the excision and the mass was not found to be adherent to any of the intrathoracic structures. (c) A polypropylene mesh was used to reconstruct the defect after resection of the chest wall. (d) The rib mass (osteoma) measured $5.0 \times 3.5 \times 4.2 \text{ cm}^3$

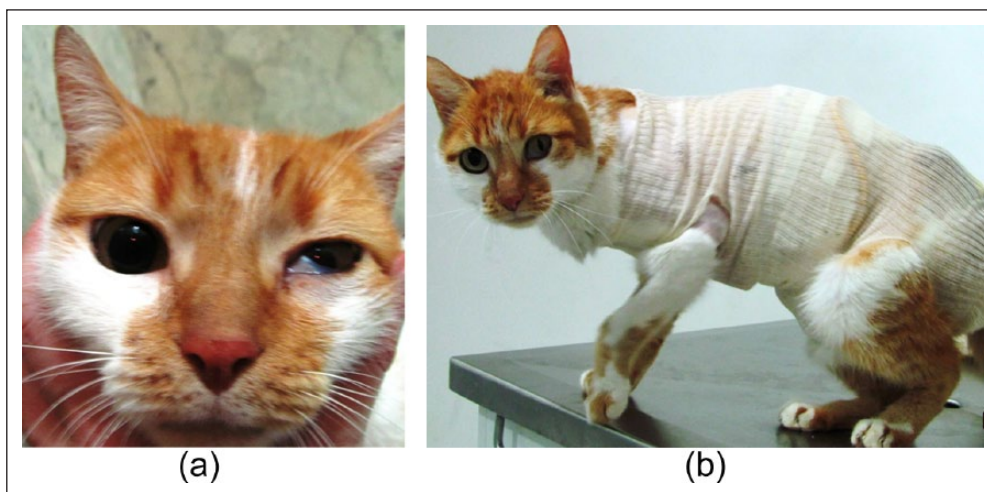


Figure 4 Transient Horner's syndrome was observed (a) 24 h and (b) 7 days after surgical resection of the rib osteoma

good acceptance, and regurgitation was no longer observed. The gastric tube was removed 2 weeks after surgery and Horner's syndrome completely resolved within 4 weeks of surgery.

Histopathology revealed bone proliferation characterized by immature bone with a trabecular pattern and osteoblasts without atypia, and these were permeated by spindle cell stroma. In peripheral areas,

compact bone was noted. The final diagnosis was a rib osteoma.

The cat gained weight and experienced a normal life in the years following surgery. In plain radiographs obtained 2 years after surgery, there was no evidence of esophageal dilation or recurring osteoma (Figure 5). Regurgitation and dysphagia also completely resolved and the cat has remained free of disease 32 months after surgery.

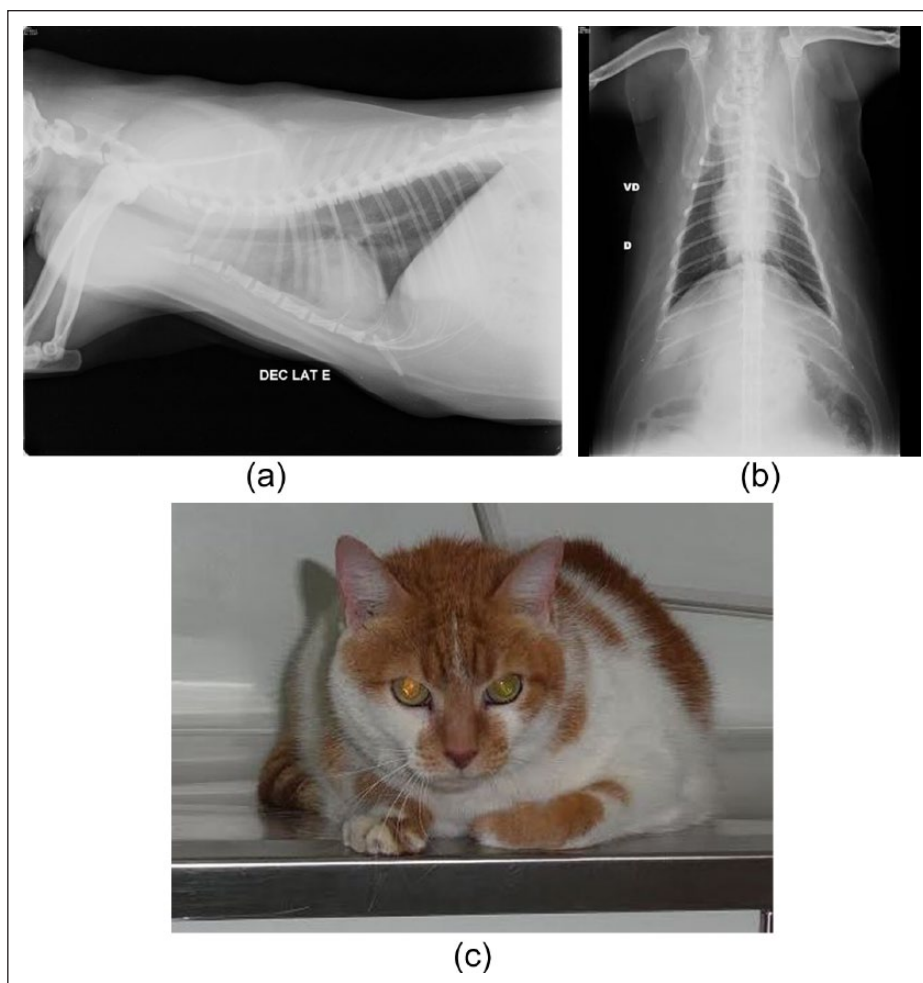


Figure 5 (a and b) Plain radiographs and (c) photograph of the cat obtained 2 years after rib osteoma surgery

Discussion

Esophageal diseases in cats are usually associated with benign strictures resulting from cicatrix or esophageal intraluminal (squamous cell carcinoma, neuroendocrine carcinoma) or extraluminal (mediastinal lymphoma) masses.^{2,4} However, in the present case, an osteoma arising from the second rib was compressing the esophagus, thereby causing esophageal obstruction and dilation. To our knowledge, this is the first report of a rib osteoma causing an esophageal obstruction.

Reported clinical signs of esophageal stricture have included regurgitation and/or vomiting of dry food, followed by liquid meals, consistent with worsening of a stricture.^{2,4} In the present case, the cat initially regurgitated dry food and then progressed to severe dysphagia of liquid meals and even saliva within a year. This was probably due to mass growth and subsequent esophageal compression. Inspiratory dyspnea was considered to have occurred secondary to compression of the tracheal lumen by the mass because there was no evidence of aspiration pneumonia in the CT scans.

Osteomas are benign tumors of bone. Radiographically, these tumors are well circumscribed, dense bony projections, and they are not usually painful on palpation.^{5,6} Histologically, osteomas are composed of tissue that is nearly indistinguishable from reactive bone.^{5,6} In the present case, cytology revealed a mesenchymal tumor, yet an osteoma vs an osteosarcoma could not be distinguished. Histopathology was conclusive for osteoma because there were no malignant findings.

Treatment for osteoma is simple surgical excision, which is usually curative.^{5,6} Surgery was initially declined by the owner and, based on the radiographs obtained, was also considered too aggressive by the surgeons. Surgery was only attempted after a CT scan showed that the mass was not invading adjacent structures. The surgical resection performed was considered curative, with no recurrence observed in the following 3 years. In addition, the cat was eating and drinking normally, and there was no clinical evidence of esophageal motility problems, even after several months of severe dilation of the cervical portion.

Meshes are used for the reconstruction of large chest wall defects in humans because they are associated with a significantly lower rate of respiratory complications and shorter hospital stays compared with autogenous muscle flap reconstructions. Furthermore, mesh provides additional rigidity when sutured under tension.⁷⁻⁹ Generally, prosthetic mesh is associated with a low rate of infection and other complications. However, in a study of prosthetic mesh reconstructions of chest wall defects in a cohort of dogs, an increased risk of complications was observed.¹⁰ Specifically, the odds for postoperative complications were 12.8 times more likely for prosthetic reconstructions than with autogenous techniques.¹⁰ The complications reported include incisional seroma, deep infection and pleural effusion.¹⁰ In the present case, a Marlex prosthetic mesh was used for reconstruction of the thoracic wall, and there were no complications during the postoperative period.

Horner's syndrome developed in the left eye immediately after surgery. However, this condition was transient and resolved within 4 weeks. In the present case, the onset of Horner's syndrome was associated with traumatic nerve dysfunction. Horner's syndrome (miosis, enophthalmos, third eyelid protrusion and ptosis) can also manifest due to ipsilateral sympathetic nerve dysfunction.¹¹ The sympathetic pathway consists of first- (hypothalamus to T1-T3), second- (T1-T3 to cranial cervical ganglion) and third-order (cranial cervical ganglion to pupillary dilator muscle) neurons. Loss of sympathetic innervation to the face (Horner's syndrome) and dysfunction of the lateral thoracic nerve (efferent for cutaneous trunci reflex) are common because of the proximity of these nerves to the brachial plexus.¹¹

Conclusions

Esophageal strictures can be caused by extraluminal masses, and rib tumors should also be included in a differential diagnosis. CT should be performed before

surgical resection; in the present case, this was key to treatment planning. Successful treatment of the rib osteoma included surgical resection.

Funding The authors received no specific grant from any funding agency in the public, commercial or not-for-profit sectors for the preparation of this case report.

Conflict of interest The authors do not have any potential conflicts of interest to declare.

References

- 1 Valdés A. **Esophageal stenosis in cats.** Proceedings of the 34th World Small Animal Veterinary Congress WSAVA, Sao Paulo, Brazil, 2009.
- 2 Frowde PE, Battersby IA, Whitley NT, et al. **Oesophageal disease in 33 cats.** *J Feline Med and Surg* 2011; 13: 564-569.
- 3 Berube D, Scott-Moncrieff JC, Rohleder J, et al. **Primary esophageal squamous cell carcinoma in a cat.** *J Am Anim Hosp Assoc* 2009; 45: 291-295.
- 4 Willard MD. **Esophagitis and esophageal strictures.** In: August JR (ed). *Consultations in feline internal medicine.* St Louis, MO: Elsevier, 2006, pp 80-86.
- 5 Dernell WS and Straw RC. **Tumors of the skeletal system.** In: Withrow SJ and Macewen EG (eds). *Small animal clinical oncology.* 4th ed. St Louis, MO: Saunders, 2007, pp 541-583.
- 6 Gassel AD and Huber ML. **What is your diagnosis? A 2.0 × 1.75-cm well-circumscribed ovoid mineralized opacity over the left mandible.** *J Am Vet Med Assoc* 2002; 220: 1151-1152.
- 7 Sabanathan S, Shah R, Mearns AJ, et al. **Chest wall resection and reconstruction.** *Br J Hosp Med* 1997; 57: 255-259.
- 8 Kroll SS, Walsh G, Ryan B, et al. **Risks and benefits of using Marlex mesh in chest wall reconstruction.** *Ann Plast Surg* 1993; 31: 303-306.
- 9 Novoa N, Benito P, Jimenez MF, et al. **Reconstruction of chest wall defects after resection of large neoplasms: ten year experience.** *Interact Cardiovasc Thorac Surg* 2005; 4: 250-255.
- 10 Liptak JM, Dernell WS, Rizzo AS, et al. **Reconstruction of chest wall defects after rib tumor resection: a comparison of autogenous, prosthetic, and composite techniques in 44 dogs.** *Vet Surg* 2008; 37: 479-487.
- 11 Coates JR and Levine JM. **Performing the Neurological Examination.** In: August JR (ed). *Consultations in feline internal medicine.* St Louis, MO: Elsevier, 2006, pp 421-495.