



Stevens–Johnson syndrome/toxic epidermal necrolysis caused by cefadroxil in a cat

Authors: Sartori, Roberta, and Colombo, Silvia

Source: Journal of Feline Medicine and Surgery Open Reports, 2(1)

Published By: SAGE Publishing

URL: <https://doi.org/10.1177/2055116916653616>

BioOne Complete (complete.BioOne.org) is a full-text database of 200 subscribed and open-access titles in the biological, ecological, and environmental sciences published by nonprofit societies, associations, museums, institutions, and presses.

Your use of this PDF, the BioOne Complete website, and all posted and associated content indicates your acceptance of BioOne's Terms of Use, available at www.bioone.org/terms-of-use.

Usage of BioOne Complete content is strictly limited to personal, educational, and non - commercial use. Commercial inquiries or rights and permissions requests should be directed to the individual publisher as copyright holder.

BioOne sees sustainable scholarly publishing as an inherently collaborative enterprise connecting authors, nonprofit publishers, academic institutions, research libraries, and research funders in the common goal of maximizing access to critical research.



Stevens–Johnson syndrome/toxic epidermal necrolysis caused by cefadroxil in a cat

Roberta Sartori¹ and Silvia Colombo²

Journal of Feline Medicine and Surgery
Open Reports
 1–6

© The Author(s) 2016
 Reprints and permissions:
sagepub.co.uk/journalsPermissions.nav
 DOI: 10.1177/2055116916653616
jfmsopenreports.com

This paper was handled and processed by the European Editorial Office (ISFM) for publication in JFMS Open Reports



Abstract

Case summary A 5-year-old, spayed female, indoor-only domestic shorthair cat was referred with an acute history of multifocal cutaneous and mucocutaneous erosive-ulcerative lesions and skin detachment. The lesions occurred on the seventh day of therapy with cefadroxil. Erosive-ulcerative and occasionally crusted lesions were apparent on the medial and lateral canthus of both eyes, ventral neck, abdomen, perivulvar region, periungual skin and medial aspect of the front and hindlimbs. Diffuse and severe exfoliation was present on the dorsum and tail base and in both external ear canals. The cat was also dehydrated, tachycardic and febrile. Histopathological examination revealed extensive epidermal ulceration, interface dermatitis with vacuolar degeneration, apoptosis at multiple epidermal levels and basal, suprabasal and spinous dermoepidermal detachment. The histopathological diagnosis was consistent with Stevens–Johnson syndrome/toxic epidermal necrolysis (SJS/TEN). The recently reported Algorithm of Drug Causality in Epidermal Necrolysis (ALDEN), currently used in human medicine, was applied and a score of +6 was calculated; this supported the view that SJS/TEN in this cat was very likely to be associated with cefadroxil administration.

Relevance and novel information This clinical communication reports cefadroxil as a very probable cause of SJS/TEN in a cat; the ALDEN was applied in this case and supported diagnosis.

Accepted: 16 May 2016

Introduction

Stevens–Johnson syndrome (SJS) and toxic epidermal necrolysis (TEN) are variants of a spectrum of immune-mediated diseases, which also includes erythema multiforme (EM) minor and major.^{1,2} In people, SJS and TEN are caused by drugs in the vast majority of cases, while EM is usually due to viral infections, mostly herpes simplex. For this reason, SJS and TEN are often referred to as one entity (SJS/TEN), while EM is considered a separate disease.³ Recently, an algorithm to assess drug causality in human cases of SJS/TEN has been proposed (Algorithm of Drug Causality in Epidermal Necrolysis [ALDEN]), and proved to be very sensitive in comparison with case-control studies.⁴ The ALDEN has also been used in a series of cases of TEN in dogs.⁵

In animals, the aetiological classification of this group of diseases is not as well-defined, and the diagnosis is

currently based on clinical criteria, which can be useful to differentiate EM from the more severe forms, SJS and TEN.² Histopathological examination, in most cases, cannot clearly distinguish between EM, SJS and TEN, as the microscopic features of the different conditions often overlap.^{2,3} According to a recent review, EM cases in cats are associated with feline herpesvirus infections, as well as administration of antibiotics and aurothioglucose.³

¹Servizi Dermatologici Veterinari, Opera, Milan, Italy

²Servizi Dermatologici Veterinari, Legnano, Milan, Italy

Corresponding author:

Roberta Sartori DVM, Servizi Dermatologici Veterinari, via Sporting Mirasole 39, Opera, Milan, Italy
 Email: sartori.roberta@hotmail.com



Creative Commons Non Commercial CC-BY-NC: This article is distributed under the terms of the Creative Commons Attribution-NonCommercial 3.0 License (<http://www.creativecommons.org/licenses/by-nc/3.0/>) which permits non-commercial use, reproduction and distribution of the work without further permission provided the original work is attributed as specified on the SAGE and Open Access pages (<https://us.sagepub.com/en-us/nam/open-access-at-sage>).

TEN, or SJS/TEN, has been rarely reported in cats and it has invariably been associated with drugs, such as flea dips containing d-limonene,⁶ feline leukaemia virus (FeLV) antiserum,⁷ cefaloridine, hetacillin, ampicillin,⁸ griseofulvin,⁹ penicillin, aurothioglucose and cephalexin.¹⁰ Currently, SJS and TEN in animals are believed to be analogues of the human diseases, while the same cannot be stated of EM.³

The aim of this case report is to describe the clinical and histological features of a feline case of SJS/TEN and to evaluate drug causality in this cat by means of the ALDEN.

Case description

A 5-year-old, spayed female, indoor-only domestic short-hair cat was referred with an acute history of multifocal cutaneous and mucocutaneous erosive-ulcerative lesions and skin detachment. The lesions were rapidly worsening and occurred on the seventh day of therapy with cefadroxil (Cefacure tabs; MSD Animal Health) 25 mg/kg PO q24h, prescribed by the primary veterinarian for vomiting and diarrhoea of unknown origin. According to the owner, the cat had no history of exposure to any other medication or toxin.

On general physical examination, the cat was 3% dehydrated, its heart rate was 250 bpm and its temperature was 39.6°C. On dermatological examination, there were large areas of erosion/ulceration due to epidermal detachment affecting the ventral neck, abdomen, vulvar lips and perivulvar region, periungual skin and medial aspect of the front and hindlimbs (Figures 1 and 2); the footpads were unaffected. Erosive-ulcerative and crusted lesions were apparent on the medial and lateral canthus of both eyes (Figure 3). Diffuse and severe exfoliation was present on the dorsum and tail base and in both external ear canals. The oral cavity and anus were not affected.

Differential diagnoses for this presentation were adverse drug reaction, EM major, SJS/TEN, vasculitis,

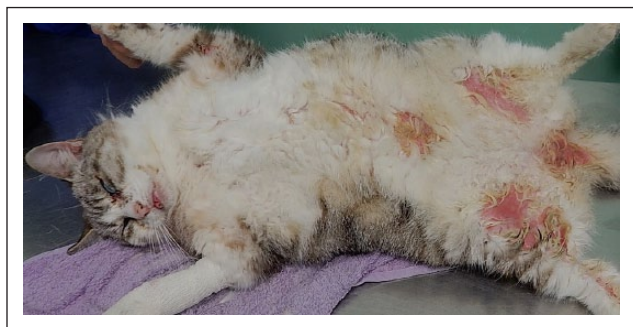

Figure 1 Erosive-ulcerative lesions on the ventral abdomen, perivulvar region and medial aspect of the front and hindlimbs of a 5-year-old, spayed female domestic shorthair cat

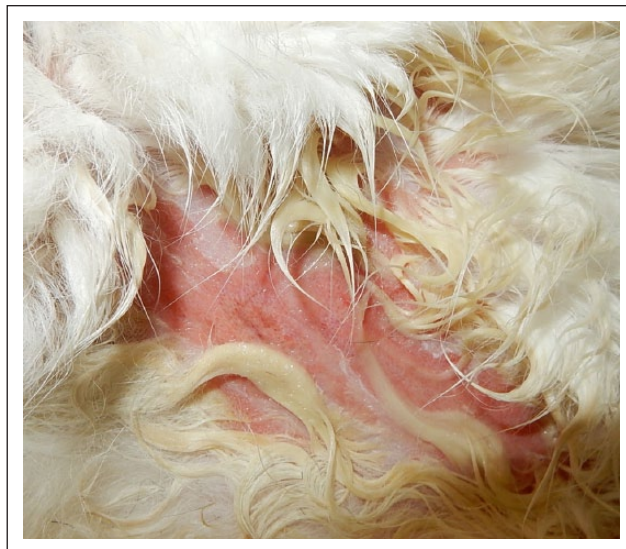

Figure 2 Close-up of an erosive-ulcerative lesion due to epidermal detachment on the ventral abdomen

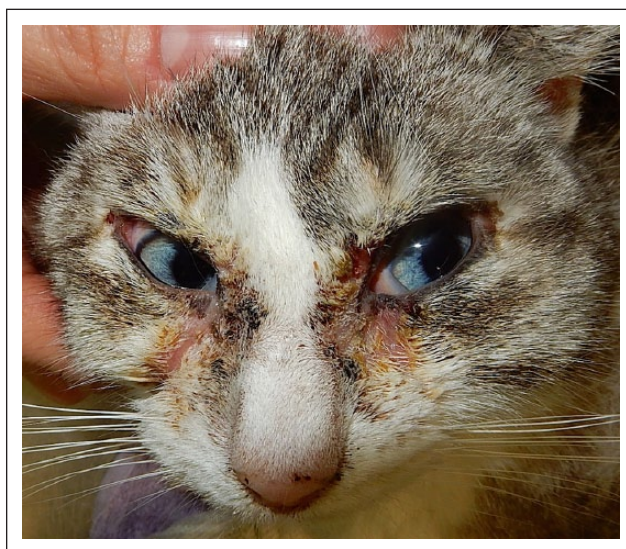

Figure 3 Erosive-ulcerative and crusted lesions on the medial and lateral canthus of both eyes

pemphigus vulgaris, bullous pemphigoid and exfoliative dermatitis secondary to thymoma.

Complete blood cell count revealed leukocytosis ($22.86 \times 10^9/l$; reference interval [RI] $2.87\text{--}17.02 \times 10^9/l$), neutrophilia ($13.05 \times 10^9/l$; RI $1.48\text{--}10.29 \times 10^9/l$) with toxic changes and lymphocytosis ($8.06 \times 10^9/l$; RI $0.92\text{--}6.88 \times 10^9/l$). Serum biochemical abnormalities included hypergammaglobulinaemia (17.7 g/l ; RI $4.5\text{--}12.4 \text{ g/l}$), hyperphosphoraemia (2.36 mmol/l ; RI $0.8\text{--}2.0 \text{ mmol/l}$), hypertriglyceridaemia (1.42 mmol/l ; RI $0.22\text{--}0.92 \text{ mmol/l}$) and increased serum aspartate aminotransferase (41.38 U/l ; RI $15\text{--}35$). Serologies for FeLV and feline immunodeficiency virus were both negative, and

thoracic radiographs and abdominal ultrasound examination did not show any abnormality. Skin biopsies were taken with a 6 mm punch and samples were fixed in 10% buffered formalin. Sections were paraffin-embedded and stained with haematoxylin-eosin, following standard procedures. Histopathological examination revealed extensive epidermal ulceration, interface dermatitis with vacuolar degeneration, apoptosis at multiple epidermal levels and basal, suprabasal and spinous dermoepidermal detachment. There was a subepidermal mononuclear infiltrate, hair follicle telogenisation and atrophy, and a lymphocytic infiltrate was apparent in the follicular infundibulum (Figures 4–7). No sebaceous glands were detected.

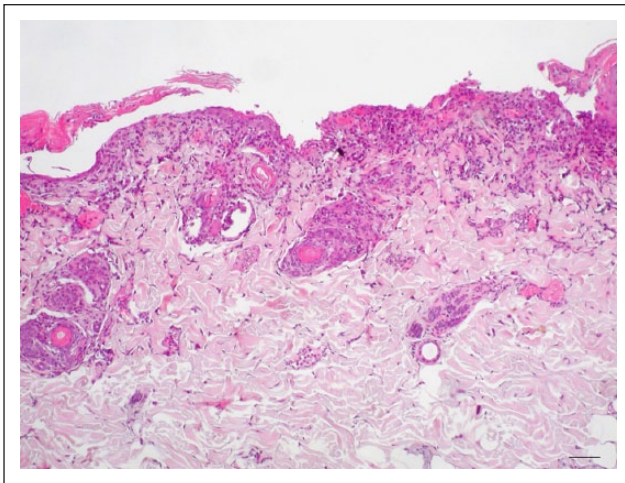


Figure 4 Light photomicrograph of a section of affected skin, showing suprabasal epidermal detachment and follicular atrophy. No sebaceous glands are detected (haematoxylin and eosin, bar = 200 μ m)

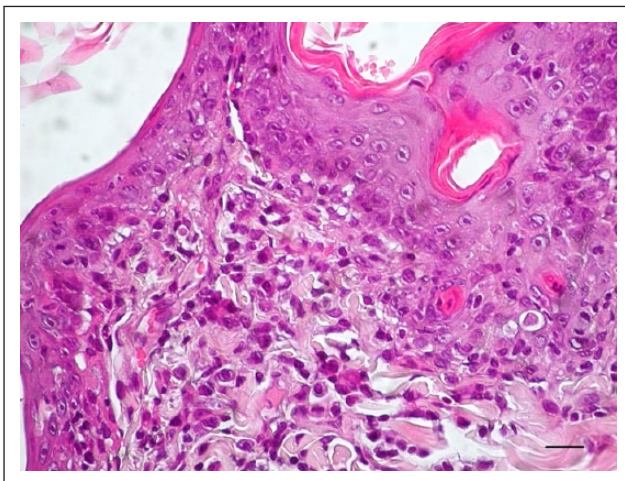


Figure 5 Light photomicrograph of a section of affected skin, showing apoptotic cells at various levels of the epidermis, vacuolar degeneration of basal cells and subepidermal mononuclear infiltrate (haematoxylin and eosin, bar = 50 μ m)

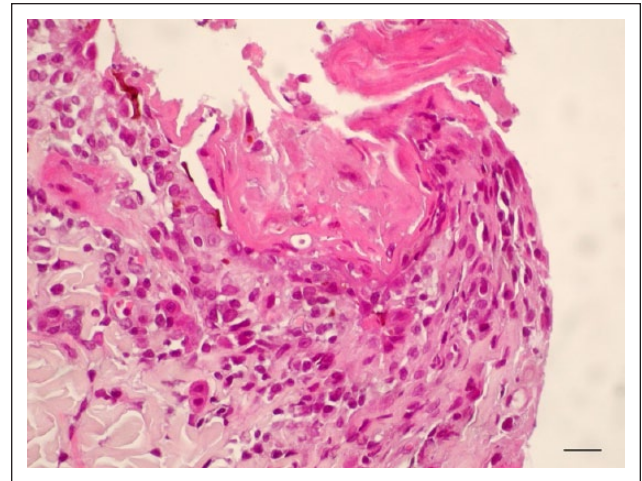


Figure 6 Epidermal necrosis due to confluence of multiple apoptotic cells (haematoxylin and eosin, bar = 50 μ m)

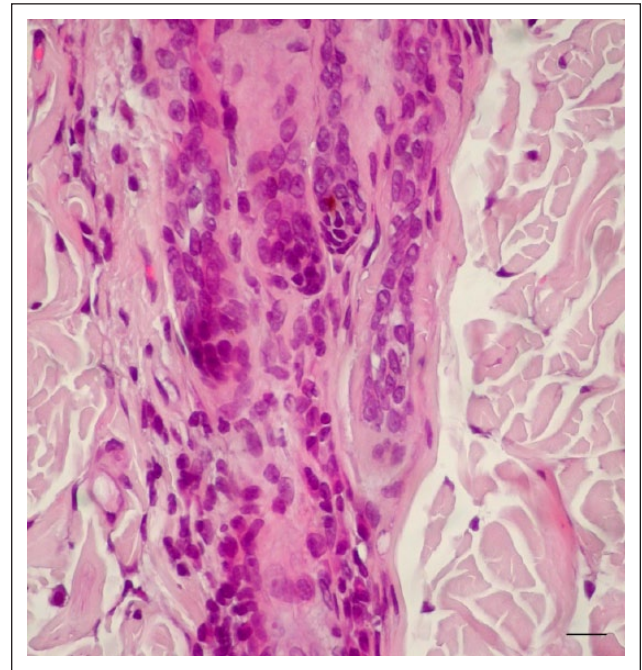


Figure 7 Lymphocytic infiltrate in the follicular infundibulum (haematoxylin and eosin, bar = 50 μ m)

The histopathological diagnosis was consistent with SJS/TEN. The recently reported algorithm for ALDEN, currently used in human medicine, was applied to this case and a score of +6 was calculated, meaning that SJS/TEN in this cat is very likely to be associated with cefadroxil administration (Table 1).

The cat was hospitalised and treated with intravenous fluids (Ringer's lactate 7.5 ml/h), marbofloxacin (Marbocyl; Vetoquinol) 2 mg/kg IV q24h and methadone hydrochloride (Synthadon; ATI) 0.2 mg/kg IV q6h to control cutaneous pain. The dermatological lesions worsened rapidly, leading to >30% of the body surface

Table 1 Details of the algorithm of drug causality for Stevens–Johnson syndrome (SJS)/toxic epidermal necrolysis (TEN) (Algorithm of Drug Causality in Epidermal Necrolysis) applied to the case

Criterion	Values	Rules to apply	Score*
Delay from initial drug component intake to onset of reaction (index day)	Suggestive +3	From 5–28 days	3
	Compatible +2	From 29–56 days	
	Likely +1	From 1–4 days	
	Unlikely –1	>56 days	
	Excluded –3	Drug started on or after the index day In case of previous reaction to the same drug, only changes for: Suggestive: +3, from 1–4 days Likely: +1, from 5–56 days	
Drug present in the body on index day	Definite 0	Drug continued up to index day or stopped at a time point <5 times the elimination half-life before the index day	0
	Doubtful –1	Drug stopped at a time point prior to the index day by >5 times the elimination half-life but liver or kidney function alterations or suspected drug interactions are present	
	Excluded –3	Drug stopped at a time point prior to the index day by >5 times the elimination half-life, without liver or kidney function alterations or suspected drug interactions	
Prechallenge/rechallenge	Positive specific for disease and drug: 4	SJS/TEN after use of same drug	0
	Positive specific for disease or drug: 2	SJS/TEN after use of similar drug or other reaction with same drug	
	Positive unspecific: 1	Other reaction after use of similar drug	
	Not done/unknown	No known previous exposure to this drug	
	Negative –2	Exposure to this drug without any reaction (before or after reaction)	
Dechallenge	Neutral 0	Drug stopped (or unknown)	0
	Negative –2	Drug continued without harm	
Type of drug (notoriety)	Strongly associated 3	Drug of the 'high risk' list according to previous case-control studies	3
	Associated 2	Drug with definite but lower risk according to previous case-control studies	
	Suspected 1	Several previous reports, ambiguous epidemiology results (drug 'under surveillance')	
	Unknown 0	All other drugs including newly released ones	
	Not suspected –1	No evidence of association from previous epidemiology study with sufficient number of exposed controls Intermediate score = total of all previous criteria	
Other cause	Possible –1	Rank all drugs from highest to lowest intermediate score If at least one has an intermediate score >3, subtract 1 point from the score of each of the other drugs taken by the patient (another cause is more likely)	
Final score –12 to 10			6

Modified from Sassolas et al⁴

*<0, very unlikely; 0–1, unlikely; 2–3, possible; 4–5, probable; ≥6, very probable

affected by skin detachment. The cat became anorexic, severely depressed and hypothermic (36.2°C) and after 4 days of hospitalisation, the owner elected euthanasia for the cat.

Discussion

SJS/TEN is a rare, acute, life-threatening reaction affecting the skin and mucosae, characterised by extensive necrosis and detachment of the epidermis, observed in

people, dogs and cats.¹⁰ An algorithm of drug causality (ALDEN) is currently used in human medicine to assess a 'very probable', 'probable', 'possible', 'unlikely' or 'very unlikely' role of a drug, in order to clearly identify in each patient not only which molecule probably caused the reaction, but also which medications could safely be administered to the patient.⁴ In veterinary medicine, ALDEN has been recently applied to a series of canine TEN cases, and a 'probable' causality for carprofen in a dog was established.⁵

To our knowledge, in this case ALDEN was applied for the first time in a feline patient. In the cat of this report a 'very probable' causality for SJS/TEN was assigned to cefadroxil, a first generation cephalosporin, according to the +6 score obtained. The 7 day delay from initial cefadroxil administration to the onset of the reaction was scored +3 (Table 1). In humans, cephalosporins are classified as 'moderate risk' for the development of drug reactions,¹¹ while in veterinary medicine they are among the most commonly implicated drugs.¹⁰ For this reason, in the present case a score of +3 was assigned (Table 1). According to the literature, there are not many descriptions of SJS/TEN in cats: caprine antiserum against FeLV, injected intraperitoneally and subcutaneously in a FeLV-positive patient in an attempt to treat FeLV-associated gingivitis was the first drug to be associated with feline TEN.⁷ Other cases implicated cephaloridine prescribed to treat pyelonephritis, ampicillin for a respiratory infection and hetacillin for an abscess.⁸ Griseofulvin,⁹ penicillin, aurothioglucose and cefalexin have also been reported to cause TEN in feline patients.¹⁰ A d-limonene-based insecticidal shampoo caused severe acute epidermal necrosis in a cat.⁶ Regarding prechallenge, unknown previous exposure to this drug was scored 0 (Table 1). Rechallenge with the same drug provides the most definitive proof of drug causality; however, this is generally not recommended. This cat could not be rechallenged because of the rapidly worsening lesions and extreme pain, resulting in the owner electing euthanasia.

As far as the clinical features are concerned, no apparent age, breed or sex predilections are reported. There is usually an acute onset of systemic signs, such as pyrexia, anorexia, lethargy and depression.³ This cat was pyrexic, dehydrated and tachycardic at the time of the clinical consultation. Initial skin lesions of SJS/TEN in dogs and cats are erythematous or purpuric, with macular or patchy eruptions, followed by blisters and skin detachment. The percentage body surface area (BSA) where the epidermis is detached or easily detachable is used to separate SJS (<10%) and TEN (>30%), both in human and veterinary medicine.^{2,3,12} Percentage of BSA detachment in humans is calculated using a burn unit method.¹ However, lesions including epidermal detachment are progressive, and this cat had a skin involvement of >30% at the worst stage of the disease.

In this cat, erosive/ulcerative lesions involved the ventral neck, abdomen, perivulvar region, periungual skin and medial aspect of the front and hindlimbs. The cat also presented exfoliative dermatitis on the dorsum and tail base and in both external ear canals. Ocular and vulvar mucocutaneous junctions were affected, as well as periungual skin, while there was no mucosal involvement. This is in contrast with the literature, because it is stated that more than one mucosa is usually involved.³ In a recent case series of TEN in three dogs,⁵ two cases had only one mucosa involved. Again, lesions in these extremely severe reactions are progressive; it cannot be excluded that if this cat had survived longer, mucosal erosions would have been observed.

The histological lesions in SJS and TEN reflect the pathogenesis, namely lymphocyte-mediated epidermal cell death, which is more extensive than in EM. The lesions progress from single cell necrosis to clusters of dying cells to full-thickness confluent necrosis. The infiltration of lymphoid cells is usually sparse. Microscopic features of the different conditions often overlap; histopathological examinations do not reliably differentiate EM, SJS and TEN.³ In this case, histopathological analysis revealed extensive epidermal ulceration, interface dermatitis with vacuolar degeneration, apoptosis at multiple epidermal levels and dermoepidermal detachment, consistent with a diagnosis of SJS/TEN, while full-thickness confluent necrosis was not observed. Multiple epidermal levels apoptosis was recently reported as the most common pattern of TEN in dogs.⁵

Regarding prognosis, the overall mortality associated with SJS/TEN in people is 39.7%.¹³ A prognosis score (SCORTEN, score for TEN) has been constructed, considering age, concurrent diseases, serum urea, bicarbonate and glucose levels, tachycardia and the percentage of BSA involved.¹⁴ Optimal management is strongly required; most patients need to be transferred in intensive care units or burns centres.^{12,13,15} Identification and withdrawal of the candidate drug through careful evaluation of the history is mandatory. In veterinary medicine, intensive care units are often unavailable and the disease is usually fatal.³ Advanced supportive therapy, pain therapy, antibiotic and symptomatic therapy for cutaneous and mucosal ulcerations are imperative. Adjunctive immunosuppressive therapy could contemplate the use of glucocorticoids, ciclosporin and intravenous immunoglobulins.³ Our cat was hospitalised and treated with methadone hydrochloride, antibiotics and fluid therapy, but after 4 days the owner elected euthanasia owing to the cat's rapidly worsening conditions.

Conclusions

We report cefadroxil as a very probable cause of SJS/TEN in a cat according to the ALDEN, applied for the first time in a feline patient. Detailed descriptions of

SJS/TEN cases in cats are lacking in literature, and a rapid diagnosis and dedicated supportive therapy is mandatory to improve the prognosis.

Acknowledgements We are very grateful to Dr Chiara Noli (BiEsseA Laboratorio Analisi Veterinarie, Milano, Italy) for the histopathological examination, and to the staff of Clinica Veterinaria Gran Sasso (Milan, Italy) for referring and taking care of the cat reported herein. We also wish to thank Professor Francesca Abramo for her help with the microscopic images.

Funding The authors received no financial support for the research, authorship, and/or publication of this article.

Conflict of interest The authors declared no potential conflicts of interest with respect to the research, authorship, and/or publication of this article.

References

- 1 Bastuji-Garin S, Rzany B, Stern RS, et al. **Clinical classification of cases of toxic epidermal necrolysis, Stevens-Johnson syndrome and erythema multiforme.** *Arch Dermatol* 1993; 129: 92–96.
- 2 Hinn AC, Olivry T, Luther PB, et al. **Erythema multiforme, Stevens-Johnson syndrome and toxic epidermal necrolysis in the dog: clinical classification, drug exposure and histopathological correlations.** *Vet Allergy Clin Immunol* 1998; 6: 13–20.
- 3 Yager JA. **Erythema multiforme, Stevens-Johnson syndrome and toxic epidermal necrolysis: a comparative review.** *Vet Dermatol* 2014; 25: 406–426.
- 4 Sassolas B, Haddad C, Mockenhaupt M, et al. **ALDEN, an algorithm for assessment of drug causality in Stevens-Johnson syndrome and toxic epidermal necrolysis: comparison with case-control analysis.** *Clin Pharmacol Ther* 2010; 88: 60–68.
- 5 Banovic F, Olivry T, Bazzle L, et al. **Clinical and microscopic characteristics of canine toxic epidermal necrolysis.** *Vet Pathol* 2015; 52: 321–330.
- 6 Lee JA, Budgin JB and Mauldin EA. **Acute necrotizing dermatitis and septicemia after application of a d-limonene-based insecticidal shampoo in a cat.** *J Am Vet Med Assoc* 2002; 221: 258–262.
- 7 Scott DW, Halliwell REW, Goldschmidt MH, et al. **Toxic epidermal necrolysis in two dogs and a cat.** *J Am Anim Hosp Assoc* 1979; 15: 271–279.
- 8 Scott DW and Miller WH. **Idiosyncratic cutaneous adverse reactions in the cat: literature review and report of 14 cases (1990–1996).** *Feline Pract* 1998; 26: 10–15.
- 9 Mason KY and Rosser EJ. **Cutaneous drug eruptions.** In: VonTscherner C and Halliwell REW (eds). *Advances in veterinary dermatology*. Vol 1. London: Baillière Tindall, 1990, pp 426–433.
- 10 Miller WH, Griffin CE and Campbell KL. **Autoimmune and immune-mediated dermatoses.** In: Miller WH, Griffin CE and Campbell KL (eds). *Muller and Kirk's small animal dermatology*. 7th ed. St Louis, MO: Elsevier Mosby, 2013, pp 432–500.
- 11 Mockenhaupt M, Viboud C, Dunant A, et al. **Stevens-Johnson syndrome and toxic epidermal necrolysis: assessment of medication risks with emphasis on recently marketed drugs. The Euro-SCAR study.** *J Invest Dermatol* 2008; 128: 35–44.
- 12 Mockenhaupt M. **The current understanding of Stevens-Johnson syndrome and toxic epidermal necrolysis.** *Exp Rev Clin Immunol* 2011; 7: 803–815.
- 13 Oen IMM, van der Vlies CH, Roeleveld YWF, et al. **Epidemiology and costs of patients with toxic epidermal necrolysis: a 27-year retrospective study.** *J Eur Acad Dermatol Venerol* 2015; 29: 2444–2450.
- 14 Bastuji-Garin S, Fouchard N, Bertocchi M, et al. **SCORTEN: a severity-of-illness score for toxic epidermal necrolysis.** *J Invest Dermatol* 2000; 115: 149–53.
- 15 Valeyrie-Allanore L and Roujeau JC. **Epidermal necrolysis (Stevens-Johnson syndrome and toxic epidermal necrolysis).** In: Goldsmith LA, Katz SI, Gilchrist BA, et al (eds). *Fitzpatrick's dermatology in general medicine*. 8th ed. New York: McGrawHill Medical, 2012, pp 439–448.