



Periaortic lymphoma in a cat

Authors: Bree, Laura, Bergamino, Chiara, Mullins, Ronan, Kelly, Pamela, and Shiel, Robert

Source: Journal of Feline Medicine and Surgery Open Reports, 3(2)

Published By: SAGE Publishing

URL: <https://doi.org/10.1177/2055116917729627>

BioOne Complete (complete.BioOne.org) is a full-text database of 200 subscribed and open-access titles in the biological, ecological, and environmental sciences published by nonprofit societies, associations, museums, institutions, and presses.

Your use of this PDF, the BioOne Complete website, and all posted and associated content indicates your acceptance of BioOne's Terms of Use, available at www.bioone.org/terms-of-use.

Usage of BioOne Complete content is strictly limited to personal, educational, and non - commercial use. Commercial inquiries or rights and permissions requests should be directed to the individual publisher as copyright holder.

BioOne sees sustainable scholarly publishing as an inherently collaborative enterprise connecting authors, nonprofit publishers, academic institutions, research libraries, and research funders in the common goal of maximizing access to critical research.



Periaortic lymphoma in a cat

Laura Bree, Chiara Bergamino, Ronan Mullins, Pamela Kelly and Robert Shiel

Journal of Feline Medicine and Surgery Open Reports
1–6

© The Author(s) 2017

Reprints and permissions:

sagepub.co.uk/journalsPermissions.nav

DOI: 10.1177/2055116917729627

journals.sagepub.com/home/jfmsopenreports

This paper was handled and processed

by the European Editorial Office (ISFM)

for publication in *JFMS Open Reports*



Abstract

Case summary A 14-year-old neutered male Siamese cat was presented with a 3 month history of lethargy, inappetence, dehydration, hindlimb ataxia and intermittent proprioceptive deficits in the hindlimbs. Physical examination revealed low body condition score (1.75/5), pallor and bilateral basilar grade II/VI systolic heart murmur. Neurological examination revealed hindlimb ataxia, severe atrophy of the hindlimb musculature, intermittent hindlimb proprioceptive deficits and normoreflexia. Clinicopathological investigations revealed non-regenerative anaemia (haematocrit 0.17 l/l; reference interval [RI] 0.24–0.45 l/l) and increased feline pancreatic lipase concentration (Spec fPL test [IDEXX] 8.3 µg/l; RI 0.1–3.5 µg/l). Feline leukaemia virus antigen and feline immunodeficiency virus antibody tests were negative. Thoracic and abdominal imaging revealed a soft tissue structure in the area of the thoracoabdominal aorta. CT confirmed a periaortic contrast-enhancing mass extending from the level of T9–L2, with associated intervertebral infiltration at the level of T11–T12. Post-mortem examination confirmed the presence of a solid, white, multinodular, well-demarcated mass encircling the aorta extending from T9–L2. Based on histopathology and immunohistochemistry, a diagnosis of B-cell lymphoma was made. Lymphoma was also identified histopathologically within the kidneys and spleen. Evidence of mild Wallerian degeneration was present within the spinal cord, indicating compression at the level of the periaortic mass.

Relevance and novel information To our knowledge, this is the first report of periaortic lymphoma in the cat. Although periaortic tumours are exceptionally rare in veterinary medicine, lymphoma should be considered as a differential in cats.

Accepted: 28 July 2017

Case description

A 14-year-old neutered male Siamese cat presented to University College Dublin Veterinary Hospital with a 3 month history of lethargy, inappetence, dehydration, hindlimb ataxia and intermittent proprioceptive deficits in the hindlimbs. The owners reported a mild pre-existing abnormal hindlimb gait. More recently the owners noticed left-sided hindlimb weakness. Seven weeks prior to presentation, a short course of anti-inflammatory dosages of prednisolone resulted in a temporary improvement in appetite and energy levels.

At presentation, the cat weighed 3.84 kg with a body condition score of 1.5/5. Physical examination revealed dullness, decreased skin turgor, capillary refill time >2 s and tacky mucous membranes, which were consistent with severe dehydration, estimated as approximately 8%. A grade II/VI basilar systolic murmur was auscultated bilaterally. Pulses were weak but synchronous with

the heartbeat. Abdominal palpation revealed mild cranial to mid-abdominal discomfort. Orthopaedic examination identified a crouched and cautious gait. There was mild discomfort on hyperextension of the coxofemoral joints. Examination of the stifles and tarsi was unremarkable. There was moderate bilateral hindlimb muscle atrophy. Neurological examination identified obtunded mentation and lethargy, with moderate proprioceptive ataxia affecting the hindlimbs. The

University College Dublin, Section of Veterinary Clinical Sciences, Dublin, Ireland

Corresponding author:

Laura Bree MVB, Section of Veterinary Clinical Sciences, University College Dublin School of Veterinary Medicine, Belfield, Dublin 4, Ireland
Email: laura.bree@ucd.ie



Creative Commons Non Commercial CC BY-NC: This article is distributed under the terms of the Creative Commons

Attribution-NonCommercial 4.0 License (<http://www.creativecommons.org/licenses/by-nc/4.0/>) which permits non-commercial use, reproduction and distribution of the work without further permission provided the original work is attributed as specified on the SAGE and Open Access pages (<https://us.sagepub.com/en-us/nam/open-access-at-sage>).

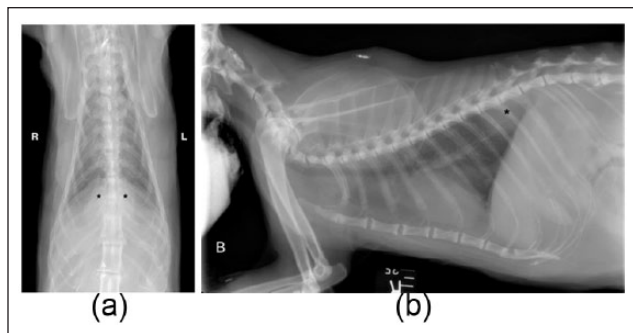


Figure 1 (a) Radiograph of the thorax, dorsoventral view. There is an ill-defined homogeneous soft tissue opacity centred on the mid-dorsal aspect of the diaphragm (*). (b) Radiograph of the thorax, right lateral view. There is an ill-defined homogeneous soft tissue opacity centred on the mid-dorsal aspect of the diaphragm (*)

cat fell on the left hindlimb when turning. Assessment of postural reactions identified normal conscious proprioception with absent hopping reflex in the hindlimbs. Spinal reflexes were normal, but there was reduced muscle tone in the hindlimbs. Discomfort was identified on palpation of the spine, at the level of the thoracolumbar junction. Cranial nerve examination revealed mildly delayed menace response bilaterally. Neurolocalisation was consistent with a T3–L3 white matter lesion, although paresis and hindlimb findings may have been due to weakness. Reduced mentation was suspected to be due to dehydration and malaise. Ocular examination revealed bilateral corneal ulceration and decreased tear production (Schirmer tear testing <10 mm bilaterally).

Haematology identified moderate non-regenerative anaemia (haematocrit 0.17 l/l; reference interval [RI] 0.24–0.45 l/l) and moderate lymphopenia (lymphocyte $0.61 \times 10^9/l$; RI $1.5\text{--}7 \times 10^9/l$). Blood smear identified macroplatelets 1+, with adequate platelet number and normal morphology of white cells. Biochemistry identified increases in amylase activity (amylase 2645 U/l; RI 0–1184 U/l), mild hyperglycaemia (glucose 8.5 mmol/l; RI 3–6.5 mmol/l) and mild-to-moderate hypertriglyceridaemia (triglyceride 1.5 mmol/l; RI 0.09–0.68 mmol/l). Feline pancreatic lipase concentration was consistent with pancreatitis (pancreatic lipase 8.3 $\mu\text{g/l}$; RI 0.1–3.5 $\mu\text{g/l}$). Testing for feline leukaemia virus antigen and feline immunodeficiency virus antibody was negative. Serum folate and cobalamin concentrations were within their respective RIs.

Echocardiography was unremarkable. Mean systolic blood pressure was 151 mmHg (RI <160 mmHg).

Thoracic radiography showed a homogeneous soft tissue opacity centred on the mid-dorsal aspect of the diaphragm, extending caudally into the retroperitoneal space and cranially to the level of the ninth thoracic vertebra (T9) (Figure 1a,b). Orthogonal radiographs of the lumbar

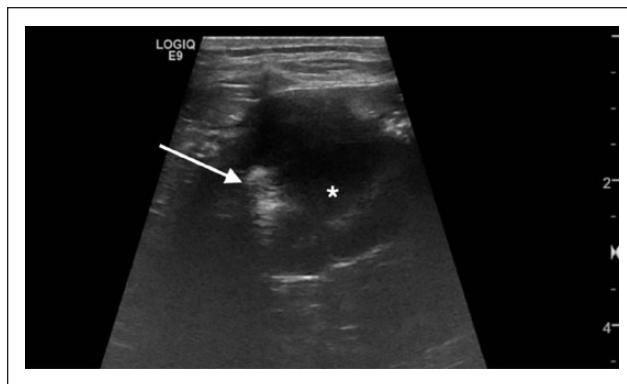


Figure 2 Ultrasound image of the ileocolic junction. There is an eccentric hypoechoic mass (*) with complete loss of layering. The hyperechoic line represents gas within the intestinal lumen (arrow)

spine and pelvis (ventrodorsal and lateral views) revealed sacralisation of the seventh lumbar vertebra (L7) and narrowing of the L6–L7 intervertebral disc space. Abdominal ultrasound identified a well-defined homogeneous hypoechoic pancreatic nodule (approximately 2 cm in diameter). At the level of the ileocolic junction, there was severe, eccentric wall thickening (approximately 1.5 cm), with complete loss of layering and peripheral focal hyperechoic peritoneal fat (Figure 2). There was a mild increase in echogenicity of both kidneys.

The cat was rehydrated and treated for pancreatitis (gastroprotectants and gastrointestinal diet), abdominal pain (buprenorphine 10 $\mu\text{g/kg}$ IV q6h) and corneal ulceration (lubricant and topical antibiotic). There was an initial improvement in demeanour and appetite within the first 24 h. However, repeated neurologic and physical examinations during 4 days of hospitalisation revealed decreased hindlimb reflexes, deteriorating mentation status (despite normalisation of hydration status) and appetite. CT of the abdomen was performed to examine the thoracoabdominal soft tissue mass identified on radiography.

A pre- and post-contrast (Ioversol 300 mgI/ml; dose: 2 ml/kg IV) CT study of the thorax and abdomen was performed under general anaesthesia. A large (approximately 8.1 cm length \times 2.1 cm height \times 3 cm width), heterogeneous, ill-defined soft tissue-attenuating (57 HU) mass, with strong and heterogeneous contrast enhancement (130 HU) was present in the retroperitoneal space, extending from the level of the mid-ventral aspect of T9–L2 (Figure 3a,b). No contrast-filling defects within the aortic lumen were observed, indicating flow patency and lack of invasion. At the level of T11–T12 intervertebral disc space, the mass extended into the left intervertebral foramen; however, the spinal cord had normal appearance in all series. Skeletal structures adjacent to the mass showed no abnormalities.

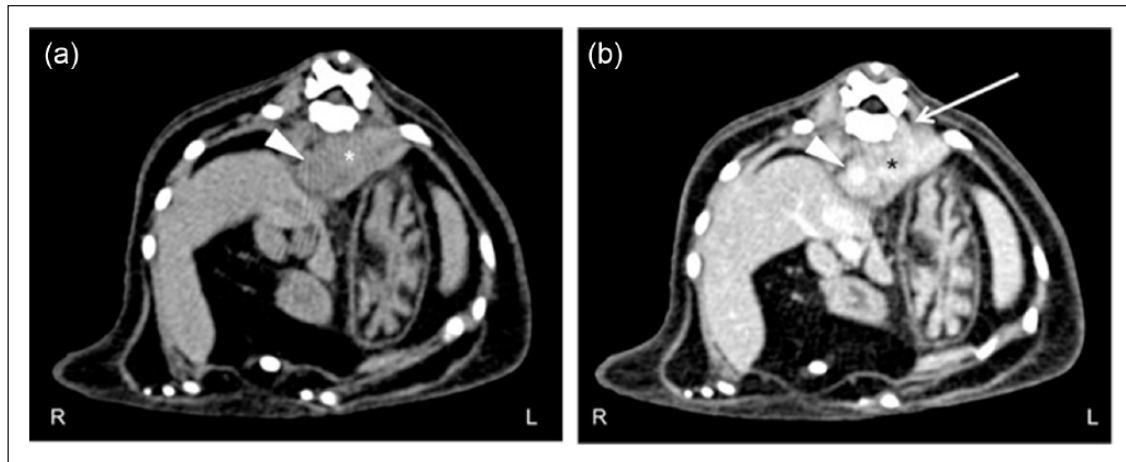


Figure 3 CT study of the cranial abdomen, soft tissue window, (a) pre- and (b) post-contrast. Right to the left of the image and dorsal to the top. A heterogeneous strongly contrast enhancing mass (*) surrounding the aorta (arrowhead) is present. In the post-contrast image (b) the mass is extending into the left intervertebral foramen (arrow)

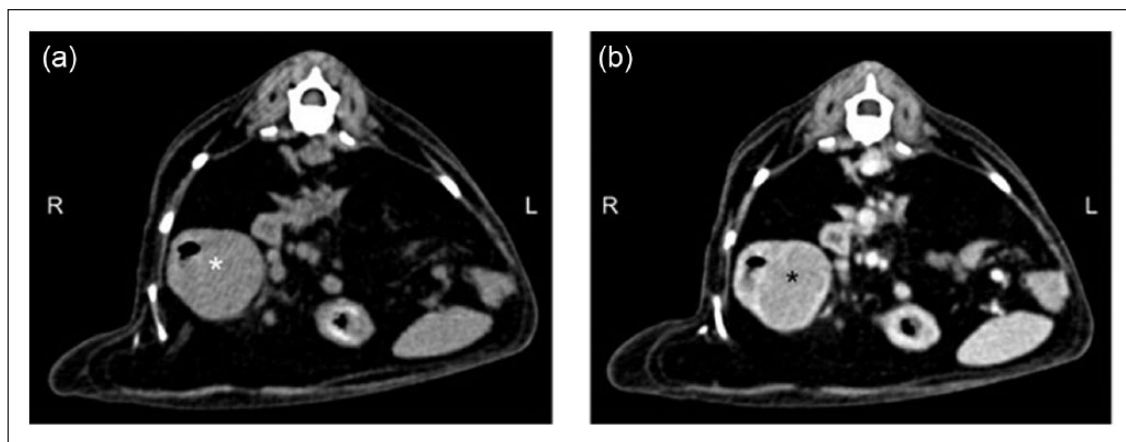


Figure 4 (a,b) CT study of the mid-abdomen, soft tissue window, (a) pre- and (b) post-contrast series. Right to the left of the image and dorsal to the top. A homogeneous contrast-enhancing, soft tissue-attenuating mass (*) is present at the ileocolic junction

The previously sonographically described mass at the ileocolic junction (approximately 2 cm length \times 2.2 cm height \times 2.5 cm width) had homogeneous soft tissue attenuation (50 HU) with moderate peripheral rim and moderate central contrast enhancement (100 HU) (Figure 4a,b). Abdominal lymph nodes, spleen and liver appeared unremarkable. The corticomedullary ratio of the right kidney was reduced, with irregular cortical margins. There was a small hypoattenuating, non-contrast-enhancing area within the cranial cortex of the left kidney. The thoracic study identified a small amount of pleural effusion retracting the left cranial lung lobe and multifocal areas of consolidation within the right cranial and caudal and left caudal lung lobes. A round, well-defined soft tissue (46 HU) nodule (approximately 0.4 cm diameter) was identified within the accessory lobe (Figure 5). Thoracic lymph nodes had

normal appearance. Ultrasound-guided fine-needle aspirates of the ileocolic junction were performed. Cytology was non-diagnostic.

Five days after initial presentation, the cat rapidly deteriorated, becoming anorexic and increasingly dull despite normal electrolyte concentration and stable non-regenerative anaemia (haematocrit 0.19 l/l; RI 0.24–0.45 l/l). Repeat biochemistry was similar to before. The cat was not considered adequately stable for anaesthesia for exploratory laparotomy to gain a histological diagnosis. The periaortic lesion was considered too close to the aorta to perform a fine-needle aspirate safely. Given the cat's previous response to glucocorticoids, dexamethasone was prescribed (0.3 mg/kg IV); there was no improvement. The cat was euthanased owing to rapid deterioration in mental status and worsening paraparesis.

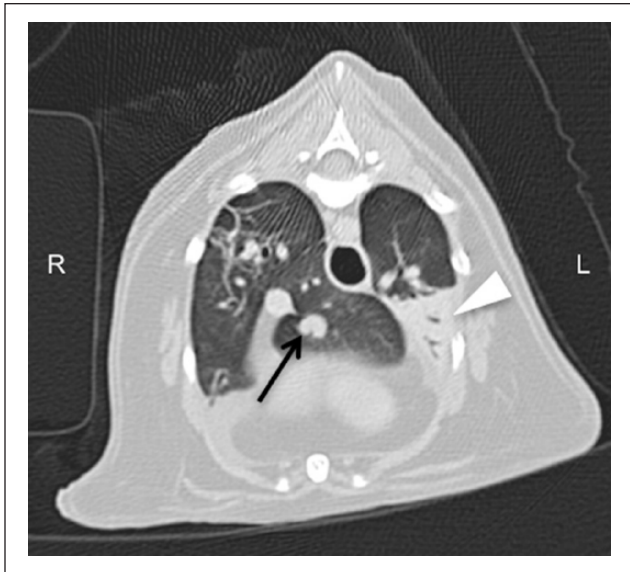


Figure 5 CT post-contrast study of the thorax, lung window. Right to the left of the image and dorsal to the top. A homogeneous contrast-enhancing nodule (arrow) is present within the accessory lobe. There is consolidation of the left caudal lung lobe (arrowhead)

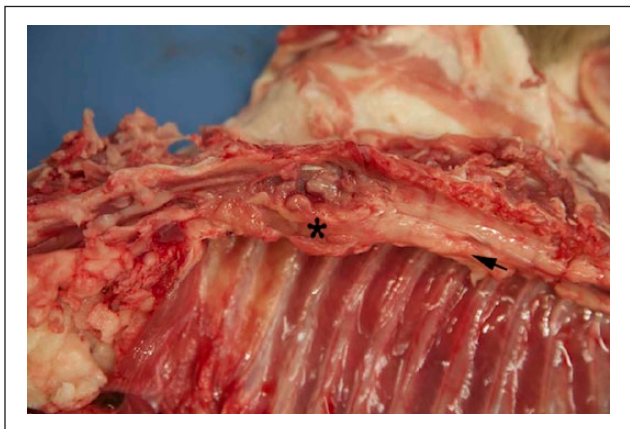


Figure 6 Post-mortem image of focal, pale, white-yellow, multinodular, shiny, well-demarcated mass (*) encircling the aorta (arrow)

A post-mortem examination was performed. A focal, pale, white-yellow, multinodular, shiny, well-demarcated mass encircled the aorta at the level of vertebrae T9–L2 (Figure 6). There was no gross evidence of extension into the spinal cord. Similar masses were also noted within the kidneys and spleen (Figure 7). Histological examination of the periaortic mass revealed a non-encapsulated, infiltrative mass of pleomorphic round cells with single prominent nucleoli, scant eosinophilic cytoplasm and multifocal areas of necrosis (Figure 8). The mass had a moderately high mitotic index of 6 per 10 high power fields ($\times 400$) with

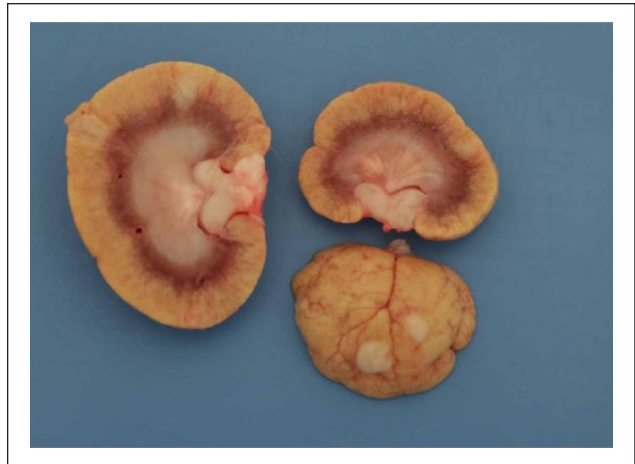

Figure 7 Post-mortem image of both kidneys showing the multiple, pale, white-yellow soft masses within the cortex and extending to within the medulla

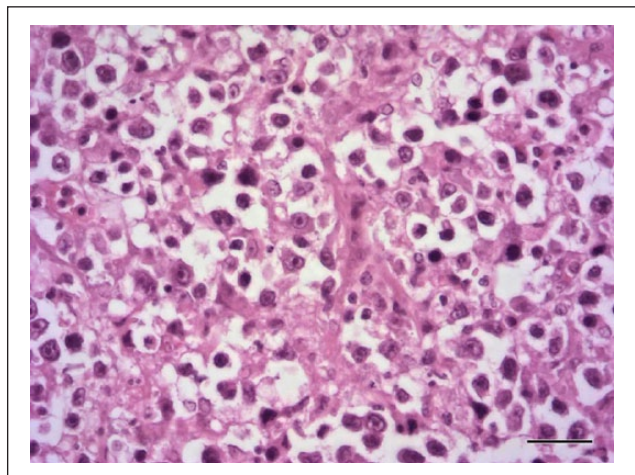


Figure 8 Histopathology of the periaortic mass. The mass is composed of pleomorphic round cells with single prominent nucleoli and scant eosinophilic cytoplasm. Haematoxylin and eosin $\times 400$, scale bar = 25 μm

few bizarre mitotic figures. The lesions within the spleen and kidneys showed a similar population of round neoplastic cells (Figure 9). Histological examination of the spinal cord at the level of periaortic mass revealed evidence of Wallerian degeneration with multiple dilated myelin sheaths that occasionally contained swollen axons (spheroids) and rare macrophages (Figure 10). The post-mortem examination findings were consistent with multisystemic periaortic lymphoma. Immunohistochemistry using cell phenotype markers PAX 5 and CD3 (T-cell marker) revealed that approximately 20% of large neoplastic cells displayed strong, specific nuclear labelling with PAX5 (B-cell marker) and did not label with CD3. Scattered throughout the mass were numerous small, non-neoplastic

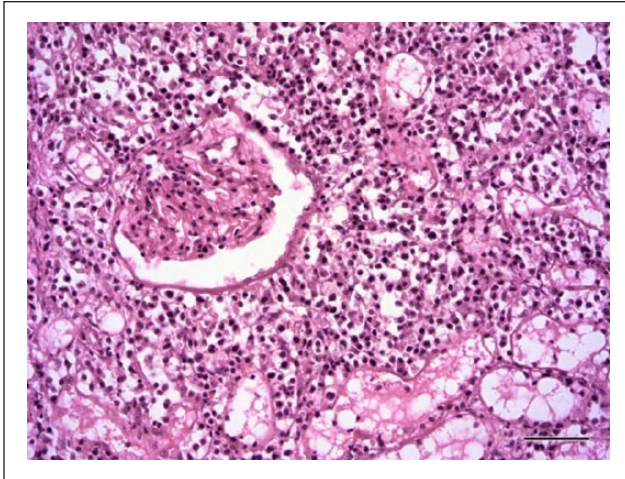


Figure 9 Histopathology of the periaortic mass. The mass is composed of pleomorphic round cells with single prominent nucleoli and scant eosinophilic cytoplasm. Haematoxylin and eosin $\times 400$, scale bar = 25 μm

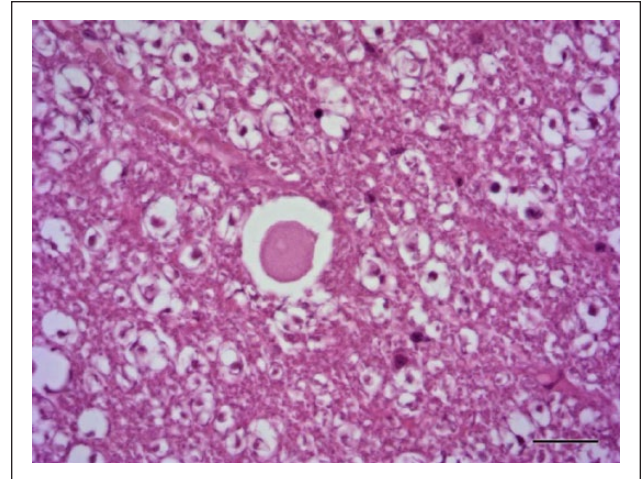


Figure 10 Histopathology of one of the renal masses. The mass is composed of pleomorphic round cells that expand the interstitium surrounding glomeruli and tubules. Haematoxylin and eosin $\times 200$, scale bar = 50 μm

round cells that exhibited strong membranous labelling for CD3. The immunohistochemistry findings were supportive of a diagnosis of B-cell lymphoma.

Incidental findings at post-mortem examination included a bronchoalveolar adenoma of the left cranial lung lobe, multifocal exocrine pancreatic hyperplasia and mild pancreatic fibrosis.

Discussion

This case report describes an extremely unusual form of feline lymphoma. Lymphoid neoplasia has an estimated incidence of 200 per 100,000 cats at risk.¹ Involvement of extranodal sites is well described, including the alimentary tract, kidney, central nervous system, trachea, skin, nasal cavity, eye, retrobulbar space and skin. In the case presented, multisystemic periaortic B-cell lymphoma was confirmed. Periaortic neoplasia has not been previously reported in the veterinary literature with the exception of a single case report of a periaortic hemangiosarcoma in a dog.² There are isolated reports of periaortic lymphoma in people,^{3,4} who typically have the B-cell phenotype. There are also reports of post-grafting infiltrative cardiac and aortic lymphoma in people with specific exogenous substances.^{5,6}

The tumour in the current case extended into the retroperitoneal space. The retroperitoneum is a potential space, within the abdominal cavity, with mediastinal and retro-pleural communication, comprising fat, loose connective tissue, nerves, lymph nodes, blood vessels (aorta, vena cava) and organs (kidneys, ureters and adrenals). The retroperitoneum is bordered dorsally by the vertebral bodies, epaxial muscles and ventrally by the peritoneum, the diaphragm and anus form the cranial and caudal borders. Retroperitoneal neoplasia is

relatively uncommon in cats, aside from primary renal lymphoma. Liptak et al reported a group of 14 dogs with retroperitoneal sarcomas;⁷ haemangiosarcoma was the most common histological diagnosis ($n = 9/14$). Primary neoplasms of the retroperitoneum in people are also rare, accounting for only 0.1–0.2% of all malignancies; they are either mesodermal, neurogenic or lymphatic (reticuloendothelial) in origin.

The clinical presentation in this case was chronic and non-specific (lethargy, inappetence and dehydration), aside from neurological deficits in the hindlimbs. Similarly, in dogs with retroperitoneal neoplasia, non-specific (lethargy, weight loss, inappetence) or neurological signs (lower motor neuron deficits to the hindlimbs) were most common.⁷ Retroperitoneal neoplasia is rare in the cat, aside from renal lymphoma. It is rarely confined to the kidneys (16%) and usually involves other abdominal organs (36%).⁸ Despite circumferential growth of the tumour encircling the aorta, no contrast-filling defects within the aortic lumen were observed, indicating flow patency. This accounts for the lack of clinical signs of vascular occlusion to the caudal trunk and pelvic limbs. In people, retroperitoneal neoplasia usually presents later in the disease as clinical signs do not develop until the mass has reached a substantial size. Periaortic and retroperitoneal neoplasia usually leads to visible abdominal enlargement, often preceded by abdominal discomfort and changes in satiety.

Neurolocalisation identified a T3–L3 lesion, presumably due to non-invasive compression of the spinal cord at T11–T12. CT identified lateralised (left) compression at this level. Extradural neoplastic paraparesis, defined as compression of the spinal cord from an

extramedullary neoplasm, is not discussed in veterinary medicine and appears to be a rare event in people with primary aortic, mediastinal or retroperitoneal neoplasia, and is most commonly seen with paravertebral or other neurogenic neoplasms.⁹

In the CT findings of the cat described, the periaortic lesion was heterogeneous in all series and there was strong contrast enhancement. CT appearance of lymphoma in the cat has been previously described to be of both homogeneous and heterogeneous attenuation. The CT characteristics of retroperitoneal lymphoma in people are that they are typically noted to be homogeneous in both plain and contrast-enhanced series,^{9,10} and consistently strongly enhancing. Imaging findings are described in one of the four reported cases of periaortic lymphoma in people. Lu et al³ described a homogeneous strongly enhancing, concentric periaortic B-cell lymphoma, discovered incidentally in an 87-year-old man. In general, lymphoma in cats and people appears to be strongly contrast enhancing on CT.^{3,9–12}

A mass was identified at the ileocolic junction on both ultrasound and CT but was not identified on post-mortem. According to previous publications,^{13,14} and based on the location and ultrasonographic features of the mass at the ileocolic junction, one of the most likely differential diagnosis was alimentary lymphoma. A possible explanation for the discrepancy of the mass being confirmed on CT examination but not detected on post-mortem examination was not found in the literature, but may have been due to glucocorticoids administered prior to euthanasia. The absence of ultrasonographically detectable parenchymal splenic changes has been previously described in cats with confirmed lymphoma.¹⁴ In some of those cases the only ultrasonographic finding that could be visualised was splenomegaly,^{12,14} which relies on a subjective evaluation. The renal changes described on both ultrasound and CT in this case are not typical of renal lymphoma.^{1,15} Ultrasonographic imaging usually reveals bilateral (>80%) irregular renomegaly with hypoechoic subcapsular thickening; neither feature was detected in this case. Fine-needle aspirate of the kidney may have aided an ante-mortem diagnosis. Renal lymphoma is mostly B cell in origin.¹⁶

Conclusions

This is the first case report of periaortic lymphoma in the veterinary literature. Although rare, lymphoma should be considered as a differential for periaortic masses in the cat.

Conflict of interest The authors declared no potential conflicts of interest with respect to the research, authorship, and/or publication of this article.

Funding The authors received no financial support for the research, authorship, and/or publication of this article.

References

- Vail D. **Feline lymphoma and leukaemia.** In: Withrow J, Page R and Vail D (eds). *Small animal clinical oncology*. 5th ed. St Louis, MO: Elsevier, 2013, pp 638–653.
- Guinan J, Fischetti A, Garate AP, et al. **Primary periaortic haemangiosarcoma in a dog.** *Can Vet J* 2012; 53: 1214–1218.
- Lu M, Millstein J, Menard M, et al. **Periaortic lymphoma as a mimic of posttraumatic intramural haematoma.** *Emerg Radiol* 2006; 13: 35–38.
- Carro C, Camilleri L, Garcier JM, et al. **Periaortic lymphoma mimicking aortic aneurysm.** *Eur J Cardiothorac Surg* 2004; 25: 1126.
- Bonnichsen C, Derani J, Maleszewski J, et al. **Recurrent Epstein-Barr virus associated diffuse large B-cell lymphoma in an ascending aorta graft.** *Circulation* 2013; 128: 1481–1483.
- Vivacqua A, Kerwin K, Tubbs R, et al. **Lymphoma of prosthetic aortic graft presenting as recurrent embolization.** *Ann Thorac Surg* 2015; 99: 306–307.
- Liptak J, Dernell W, Ehrhart E, et al. **Retroperitoneal sarcomas in dogs: 14 cases (1992–2002).** *J Am Vet Med Assoc* 2004; 224: 1471–1477.
- Gabor L, Malik R and Canfield P. **Clinical and anatomical features of lymphosarcoma in 118 cats.** *Aust Vet J* 1998; 76: 725–732.
- Rajiah P, Sinha R, Cuevas C, et al. **Imaging of uncommon retroperitoneal masses.** *Radiographics* 2011; 31: 949–976.
- Neville A and Herts B. **CT characteristics of primary retroperitoneal neoplasms.** *Crit Rev Comput Tomogr* 2004; 45: 247–270.
- Dugas B, Hoover J and Pechman R. **Computed tomography of a cat with primary intratracheal lymphosarcoma before and after systemic chemotherapy.** *J Am Anim Hosp Assoc* 2011; 47: e131–e137.
- Manzella A, Borba-Filho P, D'Ippolito G, et al. **Abdominal manifestations of lymphoma: spectrum of imaging features.** *ISRN Radiol* 2013; 48: 483069–483711.
- Penninck D, Moore A, Tidwell A, et al. **Ultrasonography of alimentary lymphosarcoma in the cat.** *Vet Radiol Ultrasound* 1994; 35: 299–306.
- Grooters AM, Miyabayashi T, Biller DS, et al. **Ultrasonographic appearance of feline alimentary lymphoma.** *Vet Radiol Ultrasound* 1994; 35: 468–472.
- Nyland TS and Mattoon JS. **Spleen.** In: Nyland and Mattoon JS (eds). *Small animal diagnostic ultrasound*. 3rd ed. St Louis, MO: Elsevier, 2015, pp 400–467.
- Moore A. **Extranodal lymphoma in the cat.** *J Feline Med Surg* 2013; 15: 379–390.