



## **Follow-up monitoring in a cat with leishmaniosis and coinfections with *Hepatozoon felis* and ‘*Candidatus Mycoplasma haemominutum*’**

Authors: Attipa, Charalampos, Neofytou, Kyriaki, Yiapanis, Christos, Martínez-Orellana, Pamela, Baneth, Gad, et al.

Source: Journal of Feline Medicine and Surgery Open Reports, 3(2)

Published By: SAGE Publishing

URL: <https://doi.org/10.1177/2055116917740454>

---

BioOne Complete ([complete.BioOne.org](https://complete.BioOne.org)) is a full-text database of 200 subscribed and open-access titles in the biological, ecological, and environmental sciences published by nonprofit societies, associations, museums, institutions, and presses.

Your use of this PDF, the BioOne Complete website, and all posted and associated content indicates your acceptance of BioOne’s Terms of Use, available at [www.bioone.org/terms-of-use](https://www.bioone.org/terms-of-use).

Usage of BioOne Complete content is strictly limited to personal, educational, and non - commercial use. Commercial inquiries or rights and permissions requests should be directed to the individual publisher as copyright holder.

---

BioOne sees sustainable scholarly publishing as an inherently collaborative enterprise connecting authors, nonprofit publishers, academic institutions, research libraries, and research funders in the common goal of maximizing access to critical research.



# Follow-up monitoring in a cat with leishmaniosis and coinfections with *Hepatozoon felis* and 'Candidatus Mycoplasma haemominutum'

*Journal of Feline Medicine and Surgery Open Reports*  
1–6

© The Author(s) 2017

Reprints and permissions:

sagepub.co.uk/journalsPermissions.nav

DOI: 10.1177/2055116917740454

journals.sagepub.com/home/jfmsopenreports

This paper was handled and processed by the European Editorial Office (ISFM) for publication in *JFMS Open Reports*



Charalampos Attipa<sup>1,2</sup>, Kyriaki Neofytou<sup>3</sup>,  
Christos Yiapanis<sup>3</sup>, Pamela Martínez-Orellana<sup>4</sup>, Gad Baneth<sup>5</sup>,  
Yaarit Nachum-Biala<sup>5</sup>, Harriet Brooks-Brownlie<sup>1\*</sup>,  
Laia Solano-Gallego<sup>4</sup> and Séverine Tasker<sup>1</sup>

## Abstract

**Case summary** A 6-year-old female neutered domestic shorthair cat from Cyprus was presented with multiple ulcerated skin nodules. Cytology and histopathology of the lesions revealed granulomatous dermatitis with intracytoplasmic organisms, consistent with amastigotes of *Leishmania* species. Biochemistry identified a mild hyperproteinaemia. Blood extraction and PCR detected *Leishmania* species, *Hepatozoon* species and 'Candidatus Mycoplasma haemominutum' (CMhm) DNA. Subsequent sequencing identified *Hepatozoon felis*. Additionally, the rRNA internal transcribed spacer 1 locus of *Leishmania infantum* was partially sequenced and phylogeny showed it to cluster with species derived from dogs in Italy and Uzbekistan, and a human in France. Allopurinol treatment was administered for 6 months. Clinical signs resolved in the second month of treatment with no deterioration 8 months post-treatment cessation. Quantitative PCR and ELISA were used to monitor *L. infantum* blood DNA and antibody levels. The cat had high *L. infantum* DNA levels pretreatment that gradually declined during treatment but increased 8 months post-treatment cessation. Similarly, ELISA revealed high levels of antibodies pretreatment, which gradually declined during treatment and increased slightly 8 months post-treatment cessation. The cat remained PCR positive for CMhm and *Hepatozoon* species throughout the study. There was no clinical evidence of relapse 24 months post-treatment.

**Relevance and novel information** To our knowledge, this is the first clinical report of a cat with leishmaniosis with *H. felis* and CMhm coinfections. The high *L. infantum* DNA levels post-treatment cessation might indicate that although the lesions had resolved, prolonged or an alternative treatment could have been considered.

**Accepted:** 9 October 2017

<sup>1</sup>Molecular Diagnostic Unit, Diagnostic Laboratories, Langford Vets and Bristol Veterinary School, University of Bristol, Bristol, UK

<sup>2</sup>Pathobiology and Population Sciences, Royal Veterinary College, Hatfield, UK

<sup>3</sup>Cyvets Veterinary Centre, Paphos, Cyprus

<sup>4</sup>Departament de Medicina i Cirurgia Animals, Facultat de Veterinària, Universitat Autònoma de Barcelona, Spain

<sup>5</sup>Koret School of Veterinary Medicine, Hebrew University of Jerusalem, Rehovot, Israel

\*Current address: Bridge Pathology, Bristol, UK

### Corresponding author:

Charalampos Attipa DVM, Royal Veterinary College Diagnostic Laboratory Services, Hawkshead Lane, Hatfield, Hertfordshire, AL9 7TA, UK

Email: attipacy@gmail.com



Creative Commons Non Commercial CC BY-NC: This article is distributed under the terms of the Creative Commons

Attribution-NonCommercial 4.0 License (<http://www.creativecommons.org/licenses/by-nc/4.0/>) which permits non-commercial use, reproduction and distribution of the work without further permission provided the original work is attributed as specified on the SAGE and Open Access pages (<https://us.sagepub.com/en-us/nam/open-access-at-sage>).

## Introduction

*Leishmania infantum*, the causative agent of canine leishmaniosis in Europe and a zoonotic vector-borne pathogen, has been increasingly reported in cats in the Mediterranean basin, providing mounting evidence that cats may act as a secondary reservoir.<sup>1</sup> Experimental and case-control studies on feline leishmaniosis (FeL) are lacking, limiting our knowledge of this disease; thus epidemiological studies, case series and case descriptions are required to establish a better understanding of the clinicopathological presentations, treatment, monitoring and prevention of FeL.<sup>2</sup>

Herein, we describe the clinical, laboratory and molecular findings, as well as treatment and prolonged monitoring data, from an adult domestic shorthair cat from Cyprus diagnosed with leishmaniosis caused by *Leishmania infantum* and coinfections with *Hepatozoon felis* and 'Candidatus Mycoplasma haemominutum' (CMhm).

## Case description

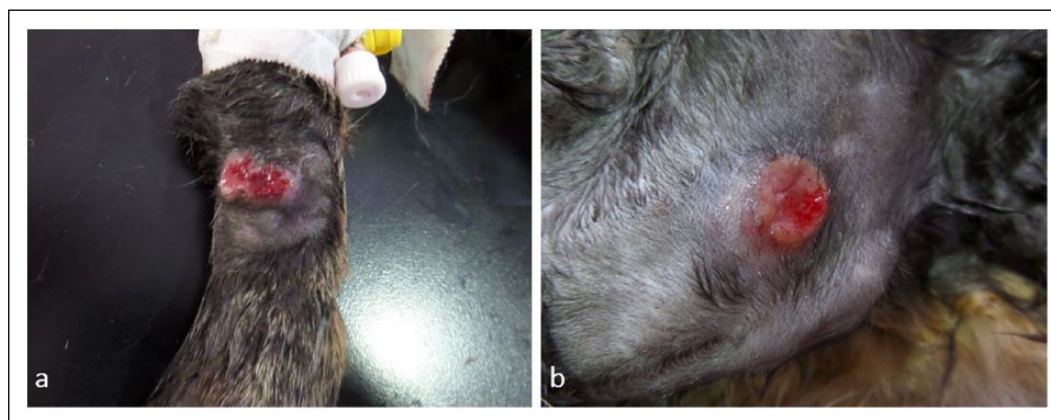
A 6-year-old female neutered domestic shorthair cat was presented at the end of September 2014 to Cylvets Veterinary Centre, Paphos, Cyprus, owing to multiple ulcerated skin nodules on the forelimbs noted by the owner 1 day before presentation when the cat had returned having been missing for 2 weeks. The cat lived mainly outdoors in a rural area, had no travel history, was fully vaccinated and had occasional fipronil spot-on (Effipro; Virbac) ectoparasiticide application.

At presentation, the cat's body condition score was 5/9 and the only abnormalities detected were three round, ulcerated skin nodules; two of them were on the dorsal aspect of each forelimb, above the carpus (Figure 1a) and the third was on the left scapula (Figure 1b). Owing to a recent diagnosis of cutaneous leprosy in a different cat from the same household, the lesion from the scapula was surgically excised for histopathological examination and imprint smears from one of the

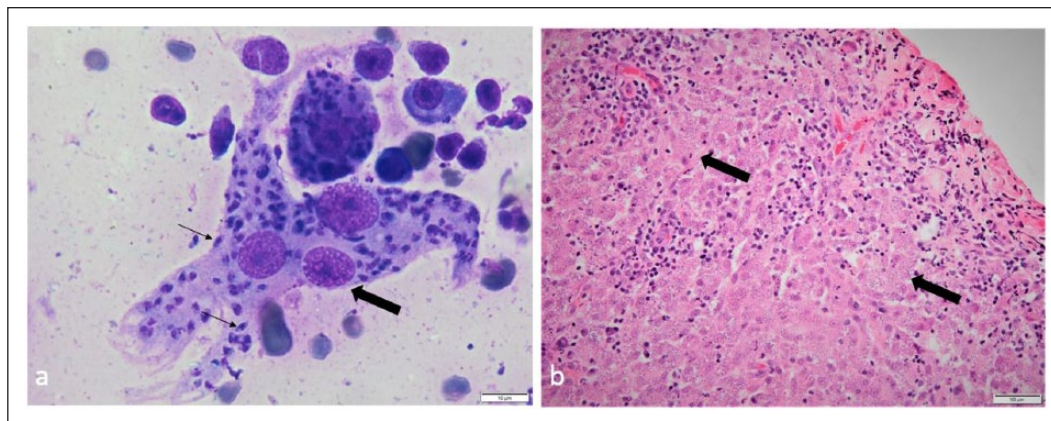
forelimb lesions were made for cytological examination. The latter revealed high numbers of macrophages, with an epithelioid appearance and occasional giant multinucleated macrophages, as well as low numbers of plasma cells and small lymphocytes. Numerous organisms consistent with *Leishmania* species amastigotes were noted in parasitophorous vacuoles of the macrophages and freely in the background (Figure 2a). Histopathological examination of the lesion (Figure 2b) revealed mild acanthosis and focal ulceration of the epidermis. Within the subjacent dermis, extending from the denuded surface to the deep dermis/panniculus, was an irregular, densely cellular area composed of macrophages, with low numbers of multinucleated forms. The macrophages contained numerous intracytoplasmic vacuoles (5–7 µm in diameter) within which were densely amphophilic round-to-oval organisms (approximately 1 µm diameter). The macrophages were mostly in random array; rarely groups of the cells were aggregated to form small granulomas. There were lighter admixtures of neutrophils, lymphocytes and plasma cells. The cytological and histopathological diagnosis was granulomatous dermatitis with intralesional intracytoplasmic amastigotes consistent with *Leishmania* species.

Blood samples were collected into EDTA and heparin and analysed by an automated haematology impedance analyser (Vet ABC; Scil) and by a VetScan VS2 chemistry analyser (Abaxis), respectively. Only mild hyperproteinaemia (84.0 g/l; reference interval 54–82 g/l) was present. Blood smear examination and urine analysis were unremarkable.

The cat was also enrolled into an epidemiology study,<sup>3</sup> thus surplus EDTA-blood and plasma available were submitted for testing for the presence of infectious, including vector-borne, organisms. The cat was PCR positive for *Hepatozoon* species using conventional PCR, as well as positive for *Leishmania* species and CMhm using quantitative PCR (qPCR). Subsequent sequencing identified *H felis* and *L infantum*.<sup>3</sup> Owing to the small size



**Figure 1** Ulcerated cutaneous skin nodules on the (a) left forelimb and (b) left scapula, month 0



**Figure 2** (a) Imprint smears from an ulcerated skin nodule revealed multinucleated macrophages (large arrow) with numerous intracellular organisms consistent with *Leishmania* species amastigotes (small arrows). Diff-Quik stain, scale bar = 10  $\mu$ m. (b) Histopathological examination of a section of the nodule removed from the left scapula showed marked granulomatous dermatitis with intracytoplasmic organisms consistent with *Leishmania* species amastigotes in the macrophages (arrows). Haematoxylin and eosin stain, scale bar = 50  $\mu$ m

of the amplicon generated by the initial *Leishmania* species PCR<sup>4</sup> an additional PCR was performed, targeting the rRNA ITS1 locus of *L infantum*,<sup>5</sup> followed by sequencing. The forward and reverse sequences of the *L infantum* were assembled and constructed into a consensus sequence, which was deposited in the GenBank database (MF140257). The DNA sequence was 100% identical to a partial 18S rRNA ITS1 sequence of *L infantum* (GenBank KX664454) over 258 bp, as found by BLAST analysis (<http://www.ncbi.nlm.nih.gov/BLAST>). Phylogeny (Figure 3) showed the *L infantum* from this Cypriot cat to cluster with species derived from dogs in Italy and Uzbekistan, a sandfly in Iran and a human in France. The cat was PCR negative for *Mycoplasma haemofelis*, 'Candidatus *Mycoplasma turicensis*' (CMt), *Bartonella henselae* and *Ehrlichia/Anaplasma* species, and seronegative for feline leukaemia virus antigen and feline immunodeficiency virus antibodies.

Treatment with allopurinol at 10 mg/kg PO q12h was started (month 0) and administered for 6 months. The cat was examined every 2 months during treatment and then 8 months post-treatment cessation (month 14), with blood samples collected each time for haematology and biochemistry analysis. An ELISA was used to monitor *L infantum*-specific antibodies in serum,<sup>6</sup> as well as qPCR<sup>4</sup> for calculating the *L infantum* DNA levels in the blood as previously described (Table 1).<sup>7</sup> The *L infantum* DNA level of the surgically excised skin nodule was high (approximately  $3.48 \times 10^{10}$  relative copy numbers). Additionally, PCR assays were repeated for CMhm and *Hepatozoon* species.

The clinical signs gradually improved by month 1 (Figure 4a) and resolved by month 2, with no clinical relapses evident at the completion of treatment (Figure 4b) nor up until the end of the follow-up period at month 14.

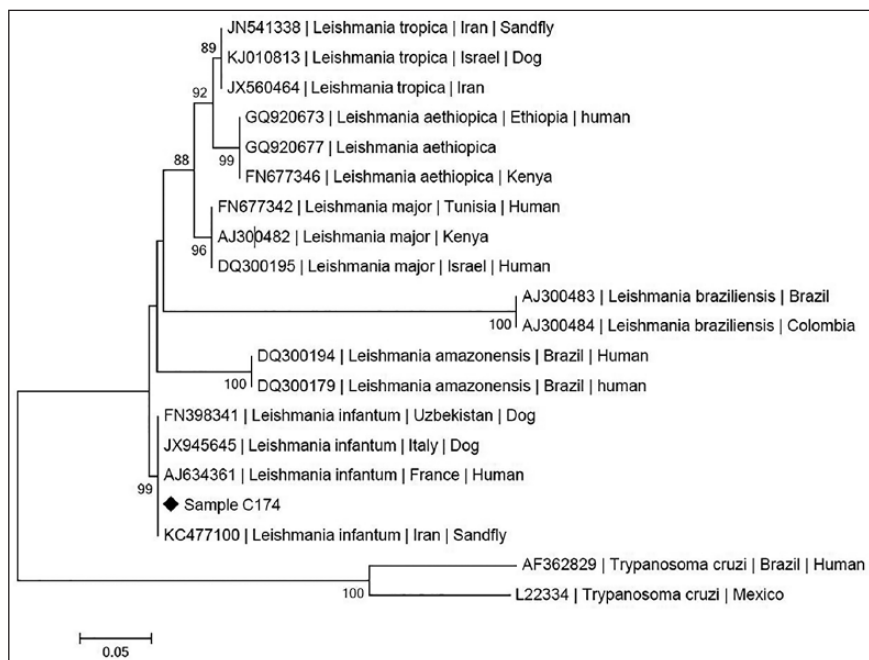
The cat had high *L infantum* DNA and antibody levels pretreatment at month 0. This DNA level had decreased by approximately 40-fold at month 2, and by approximately 5000-fold at month 6, compared with month 0. At month 14 the *L infantum* DNA level had approximately a 500-fold increase compared with month 6. The *L infantum* antibodies showed a more subtle gradual decrease, reaching a nadir at month 4, with approximately a three-fold decrease compared with month 0. From months 6–14 the antibodies remained at similar levels with approximately a two-fold elevation compared with the levels at month 4.

The cat remained PCR positive for CMhm and *Hepatozoon* species throughout the study and apart from the initial hyperproteinaemia, which resolved during month 2, no other haematological or biochemical abnormalities were detected. At month 30, while no PCR was performed, the cat remained clinically healthy with no evidence of clinical signs or relapse.

## Discussion

The first case of FeL was reported in 1912 in Algeria,<sup>8</sup> and it was not until the past two decades that case reports and epidemiological studies established a description of clinical FeL including skin or mucocutaneous lesions and lymphadenomegaly.<sup>1</sup> In contrast, fewer data are available regarding the treatment, monitoring and prognosis of FeL.

The LeishVet Group<sup>1</sup> and the Advisory Board on Cat Diseases Guidelines<sup>9</sup> both recommend allopurinol treatment (10–20 mg/kg q24h or q12h) for FeL, based on the extensive clinical use of this medication in previous cases. In contrast, meglumine antimoniate has only been described in a few cases of FeL.<sup>10,11</sup> Additionally, a combination of allopurinol and *N*-methyl-glucamine antimoniate in a cat with FeL due to *L infantum* was



**Figure 3** Maximum likelihood phylogenetic tree of *Leishmania* genera, based on rRNA ITS1 locus sequences and showing the position of the sequence derived from the *Leishmania* species found in the blood in the Cypriot cat (sample C174) with clinical leishmaniasis described in this report (MF140257). Species and strains are listed, followed by their GenBank accession numbers

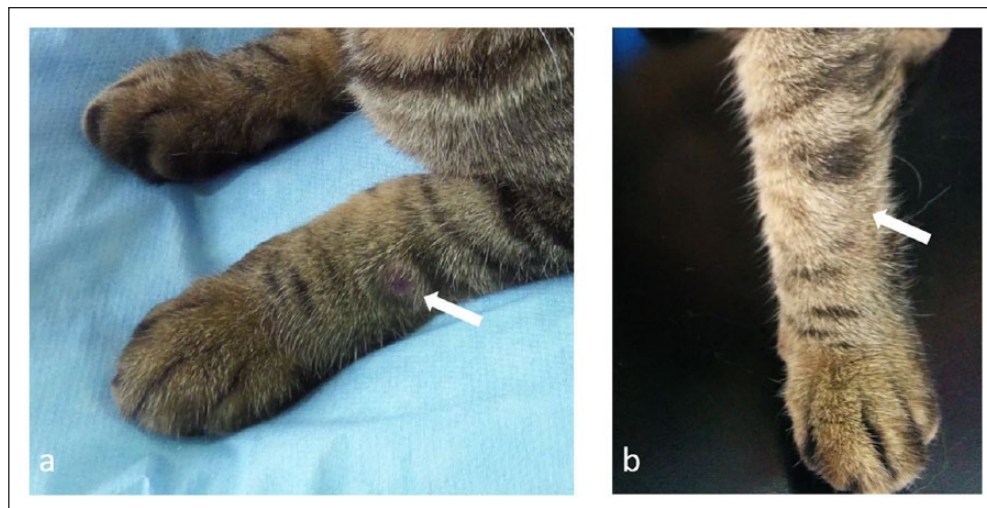
**Table 1** Serological and PCR results of *Leishmania infantum* in a cat with clinical leishmaniasis and coinfections with *Hepatozoon felis* and '*Candidatus Mycoplasma haemominutum*' during and after treatment with allopurinol at 10 mg/kg PO q12h for 6 months, which was started at month 0

<i>Leishmania infantum</i>	Month 0 (pretreatment)	Month 2 (clinical resolution of lesions)	Month 4	Month 6 (treatment cessation)	Month 14 (8 months post-treatment cessation)
DNA level per PCR assay (relative copy numbers)	663,600	17,300	500	130	64,600
ELISA units (EU), cut off point for negative result is 9.2 EU	163	124	57	99	107

reported to have led to successful clinical resolution and significant reduction of the parasitic load, suggesting that this therapeutic protocol could also be considered for FeL.<sup>12</sup>

The cat in this case had complete clinical resolution of the cutaneous lesions during the treatment period with no relapse by month 24 after completion of the 6 months of allopurinol treatment. However, the PCR results post-treatment showed that elimination of *L infantum* had not occurred, indicating progressive sub-clinical infection. Given the potential role of the cat as a secondary reservoir and the zoonotic nature of *L infantum*, an alternative treatment could have been implemented for this patient, such as a combination of allopurinol with meglumine antimoniate or *N*-methylglucamine antimoniate.

There are only a few case reports that provided prolonged follow-up for FeL,<sup>12-15</sup> and only in one case did this comprise measurement of *L infantum* DNA levels and serology.<sup>12</sup> In the current case, while the ELISA results followed a similar pattern to the DNA levels during treatment, they both failed to do the same during the monitoring period, in which the clinical signs resolved but parasitaemia persisted (Table 1). Persichetti et al reported in a recent study that although ELISA serology was better for diagnosing clinical FeL compared with the immunofluorescent antibody test (IFAT), the latter was more sensitive than ELISA to detect subclinical infection.<sup>16</sup> The same study also recommended Western blot as the preferable serological test for FeL since it yielded a higher sensitivity and specificity in comparison to ELISA and IFAT.



**Figure 4** Skin lesion (arrow) on the left forelimb (a) at month 1 and (b) at month 6 (treatment cessation)

The pathogens infecting this cat were recently found to have a PCR prevalence of 3.1% for *L infantum*, 58.0% for *Hepatozoon* species and 33.0% for CMhm in non-healthy Cypriot cats,<sup>3</sup> with *L infantum* and *Hepatozoon canis* also being reported in the canine population of this island.<sup>17</sup> Significant associations between *L infantum* infection and *H felis* and CMt infections in cats using multivariable logistic regression have been reported, suggesting impaired host immune response due to the multiple coinfections.<sup>3</sup> This could have been a component leading to the persistent *L infantum* parasitaemia in this cat in the face of the *Hepatozoon* species and CMhm coinfections.

## Conclusions

To the best of our knowledge, this is the first clinical report of FeL caused by *L infantum*, with *H felis* and CMhm coinfection. While allopurinol treatment led to a complete resolution of the clinical signs, it failed to eliminate the parasite, leading to persistent *L infantum* sub-clinical infection. Thus, more aggressive treatment could be considered in future cases, potentially with the combination of allopurinol with meglumine antimoniate or *N*-methyl-glucamine antimoniate, in order to achieve a more efficient control of *L infantum*.

**Acknowledgements** The authors would like to thank the veterinarian Dr Tryfon A Chochlios, from Cyvets Veterinary Centre, Paphos, Cyprus, for aiding in the collection of follow-up clinical records.

**Author note** The work described in this paper was presented at the 2017 ACVP/ASVCP Concurrent Annual Meeting in Vancouver as an oral presentation.

**Conflict of interest** The authors declared no potential conflicts of interest with respect to the research, authorship, and/or publication of this article.

**Funding** The authors received no specific grant from any funding agency in the public, commercial or not-for-profit sectors for the preparation of this case report.

## References

- Pennisi MG, Cardoso L, Baneth G, et al. **LeishVet update and recommendations on feline leishmaniosis.** *Parasit Vectors* 2015; 8: 302.
- Soares CS, Duarte SC and Sousa SR. **What do we know about feline leishmaniosis?** *J Feline Med Surg* 2016; 18: 435–442.
- Attipa C, Pappasouliotis K, Solano-Gallego L, et al. **Prevalence study and risk factor analysis of selected bacterial, protozoal and viral, including vector-borne, pathogens in cats from Cyprus.** *Parasit Vectors* 2017; 10: 130.
- Shaw SE, Langton DA and Hillman TJ. **Canine leishmaniosis in the United Kingdom: a zoonotic disease waiting for a vector?** *Vet Parasitol* 2009; 163: 281–285.
- Talmi-Frank D, Nasereddin A, Schnur LF, et al. **Detection and identification of old world *Leishmania* by high resolution melt analysis.** *PLOS Negl Trop Dis* 2010; 4: e581.
- Solano-Gallego L, Rodríguez-Cortés A, Iniesta L, et al. **Cross-sectional serosurvey of feline leishmaniasis in ecoregions around the Northwestern Mediterranean.** *Am J Trop Med Hyg* 2007; 76: 676–680.
- Porter E, Tasker S, Day MJ, et al. **Amino acid changes in the spike protein of feline coronavirus correlate with systemic spread of virus from the intestine and not with feline infectious peritonitis.** *Vet Res* 2014; 45: 49.
- Sergent E, Sergent E, Lombard J and Quilichini M. **La leishmaniose à Alger. Infection simultanée d'un enfant, d'un chien et d'un chat dans la même habitation.** *Bull Soc Pathol Exot* 1912; 5: 93–98.
- Pennisi MG, Hartmann K, Lloret A, et al. **Leishmaniosis in cats: ABCD guidelines on prevention and management.** *J Feline Med Surg* 2013; 15: 638–642.
- Costa-Durão J, Rebelo E, Peleteiro M, et al. **Primeiro caso de leishmaniose em gato doméstico (*Felis catus domesticus*) detectado em Portugal (Concelho de Sesimbra). Nota preliminar.** *Rev Port Cienc Vet* 1994; 89: 140–144.

- 11 Hervás J, Lara FC-MD, Sánchez-Isarria MA, et al. **Two cases of feline visceral and cutaneous leishmaniosis in Spain.** *J Feline Med Surg* 1999; 1: 101–105.
- 12 Basso MA, Marques C, Santos M, et al. **Successful treatment of feline leishmaniosis using a combination of allopurinol and N-methyl-glucamine antimoniate.** *JFMS Open Rep* 2016; 2: 205511691663000. DOI: 10.1177/2055116916630002.
- 13 Maroli M, Pennisi MG, Di Muccio T, et al. **Infection of sandflies by a cat naturally infected with *Leishmania infantum*.** *Vet Parasitol* 2007; 145: 357–360.
- 14 Pennisi MG, Venza M, Reale S, et al. **Case report of leishmaniasis in four cats.** *Vet Res Commun* 2004; 28: 363–366.
- 15 Richter M, Schaarschmidt K and Krudewig C. **Ocular signs, diagnosis and long-term treatment with allopurinol in a cat with leishmaniasis.** *Schweiz Arch Tierheilkd.* 2014; 156: 289–294.
- 16 Persichetti MF, Solano-Gallego L, Vullo A, et al. **Diagnostic performance of ELISA, IFAT and Western blot for the detection of anti-*Leishmania infantum* antibodies in cats using a Bayesian analysis without a gold standard.** *Parasit Vectors* 2017; 10: 119.
- 17 Attipa C, Hicks CA, Barker EN, et al. **Canine tick-borne pathogens in Cyprus and a unique canine case of multiple co-infections.** *Ticks Tick Borne Dis* 2017; 8: 341–346.