



Vitamin D toxicity of dietary origin in cats fed a natural complementary kitten food

Authors: Crossley, Victoria J, Bovens, Catherine PV, Pineda, Carmen, Hibbert, Angie, and Finch, Natalie C

Source: Journal of Feline Medicine and Surgery Open Reports, 3(2)

Published By: SAGE Publishing

URL: <https://doi.org/10.1177/2055116917743613>

BioOne Complete (complete.BioOne.org) is a full-text database of 200 subscribed and open-access titles in the biological, ecological, and environmental sciences published by nonprofit societies, associations, museums, institutions, and presses.

Your use of this PDF, the BioOne Complete website, and all posted and associated content indicates your acceptance of BioOne's Terms of Use, available at www.bioone.org/terms-of-use.

Usage of BioOne Complete content is strictly limited to personal, educational, and non - commercial use. Commercial inquiries or rights and permissions requests should be directed to the individual publisher as copyright holder.

BioOne sees sustainable scholarly publishing as an inherently collaborative enterprise connecting authors, nonprofit publishers, academic institutions, research libraries, and research funders in the common goal of maximizing access to critical research.



Vitamin D toxicity of dietary origin in cats fed a natural complementary kitten food

Victoria J Crossley^{1*}, Catherine PV Bovens^{2†},
Carmen Pineda³, Angie Hibbert⁴ and Natalie C Finch^{1‡}

Journal of Feline Medicine and Surgery Open Reports
1–9

© The Author(s) 2017

Reprints and permissions:

sagepub.co.uk/journalsPermissions.nav

DOI: 10.1177/2055116917743613

journals.sagepub.com/home/jfmsopenreports

This paper was handled and processed by the European Editorial Office (ISFM) for publication in *JFMS Open Reports*



Abstract

Case series summary This case series describes two young sibling cats and an additional unrelated cat, from two separate households, that developed hypercalcaemia associated with hypervitaminosis D. Excessive vitamin D concentrations were identified in a natural complementary tinned kitten food that was fed to all three cats as part of their diet. In one of the cases, there was clinical evidence of soft tissue mineralisation. The hypercalcaemia and soft tissue mineralisation resolved following withdrawal of the affected food and medical management of the hypercalcaemia.

Relevance and novel information This case series demonstrates the importance of obtaining a thorough dietary history in patients presenting with hypercalcaemia and the measurement of vitamin D metabolites when investigating such cases. Complementary foods may have the potential to induce nutritional toxicity even when fed with complete, nutritionally balanced diets.

Accepted: 30 October 2017

Introduction

The common causes of hypercalcaemia in cats are idiopathic hypercalcaemia,¹ chronic kidney disease (CKD) and neoplasia.² Other less common causes are primary hyperparathyroidism, granulomatous disease, hypervitaminosis D and hypoadrenocorticism.

Hypervitaminosis D refers to toxicity resulting from calcidiol, calcitriol, cholecalciferol (vitamin D₃) or ergocalciferol (vitamin D₂). Iatrogenic causes in cats include excessive intake of vitamin D via dietary supplementation or treatment with vitamin D₂, D₃ or vitamin D metabolites.³ Toxic sources of vitamin D include certain plants, such as Jessamine, that contain glycosides of calcitriol, some rodenticides containing cholecalciferol and topical ointments for management of psoriasis containing vitamin D analogues.³

In contrast to humans, cats do not synthesise vitamin D in their skin in response to sunlight.⁴ Therefore, cats are dependent on dietary intake to obtain vitamin D and this nutrient is often supplemented in pet foods. Vitamin D in food can be found in the form of cholecalciferol and ergocalciferol. In the liver cholecalciferol is hydrolysed to 25-hydroxycholecalciferol (calcidiol), which is the

major circulating form of vitamin D.³ In the kidney, 25-hydroxycholecalciferol is further hydroxylated to 1,25-dihydroxycholecalciferol (calcitriol), which is the biologically active form of vitamin D.³

Vitamin D influences calcium and phosphate absorption in the intestines and reabsorption in the kidneys. Therefore, excessive levels of vitamin D either from

¹School of Veterinary Sciences, University of Bristol, Langford, Bristol, UK

²Highcroft Veterinary Referrals, Bristol, UK

³Department of Animal Medicine and Surgery, University of Cordoba, Cordoba, Spain

⁴The Feline Centre, Langford Vets, University of Bristol, Bristol, UK

*Current address: Royal Veterinary College, Camden, London, UK

†Current address: Veterinary Referral Hospital, Hallam, Melbourne, Australia

‡Current address: Bristol Renal, University of Bristol, Bristol, UK

Corresponding author:

Natalie Finch BVSc, PhD, DipECVIM, Bristol Renal, University of Bristol, Dorothy Hodgkin Building, Bristol BS1 3NY, UK
Email: natalie.finch@bristol.ac.uk



Creative Commons Non Commercial CC BY-NC: This article is distributed under the terms of the Creative Commons

Attribution-NonCommercial 4.0 License (<http://www.creativecommons.org/licenses/by-nc/4.0/>) which permits non-commercial use, reproduction and distribution of the work without further permission provided the original work is attributed as specified on the SAGE and Open Access pages (<https://us.sagepub.com/en-us/nam/open-access-at-sage>).

exogenous or endogenous sources can result in hypercalcaemia. Hypervitaminosis D associated with ingestion of a complete commercial cat food containing excessive amounts of cholecalciferol has been previously reported.⁵

Case series description

Case 1

A 4-month-old female entire domestic shorthair cat presented to Highcroft Veterinary Referrals, Bristol, UK, with a 2 week history of mild lethargy, coughing, retching and vomiting. Melaena and pica were also described. A course of amoxicillin-clavulanate (Clavaseptin; Vetoquinol), fenbendazole (Panacur; MSD Animal Health) and a long-acting antibiotic injectable preparation (cefovecin; Convenia, Zoetis) had been administered prior to referral, to which the owner reported no response. There was no history of plant ingestion or toxin exposure including rodenticides or psoriasis ointments. The cat had no outdoor access. The cat was fed ad libitum complete dry kitten food supplemented with a natural complementary tinned kitten food produced by the same pet food manufacturer. In addition, the cat was given kitten milk. No other foods were fed.

On clinical examination, the cat was coughing and retching frequently and there was a positive tracheal pinch response. Pulmonary auscultation revealed diffuse mild wheezing. The cat was underconditioned (body condition score [BCS] 3/9, body weight 1.51 kg).

Haematology performed 5 days prior to referral revealed a microcytosis (mean corpuscular volume [MCV] 38.1 fl; reference interval [RI] 40–55 fl) that was considered related to chronic gastrointestinal bleeding given the melaena and pica; the packed cell volume (PCV) was normal (34%; RI 27–50%). Serum biochemistry performed 5 days prior to referral revealed increased urea (15.0 mmol/l; RI 6.0–10.0) and a marked total hypercalcaemia (4.68 mmol/l; RI 1.60–3.00 mmol/l). Serum phosphate was at the upper limit of the RI (2.56 mmol/l; RI 1.40–2.60 mmol/l) (see Table 1). Mild increases in alanine transferase (ALT) and alkaline phosphatase (ALP) activity and cholesterol were present (ALT 81U U/l [RI 0–20 IU/l]; ALKP 46 IU/l [RI 0–40 IU/l]; cholesterol 4.2 mmol/l [RI 1.9–3.9 mmol/l]). Blood ELISA testing for feline leukaemia virus antigen and feline immunodeficiency virus antibody was negative. In-house urinalysis revealed a specific gravity of 1.016. A urine dipstick showed trace protein, a pH of 5 and was otherwise unremarkable.

Abdominal ultrasonography revealed reduced renal corticomedullary definition bilaterally and a slightly hyperechoic gastric wall considered to be consistent with mineralisation. CT imaging of the thorax revealed circumferential mineralisation of the aortic root, aortic arch and brachiocephalic trunk (see Figure 1). There was

Table 1 Renal markers, calcium and phosphate concentrations at presentation and follow-up of a hypercalcaemic 4-month-old female entire domestic shorthair cat (case 1)

	5 days prior to referral	Day 0	Day 7	Day 8	Day 9	Day 10	Day 11	Day 12	Day 13	Day 14	Day 17	Day 31	RI
Urea (mmol/l)	15.0	–	13.5	–	–	–	–	–	–	8.4	–	–	6.0–10.0
Creatinine (μ mol/l)	137	–	88	–	–	–	–	–	–	44	–	–	60–170
Total calcium (mmol/l)	4.68	–	3.83	–	–	–	–	–	–	2.69	–	2.52	1.60–3.0
Ionised calcium (mmol/l)	–	–	2.02	1.87	1.79	1.85	1.92	1.56	1.43	1.33	1.32	1.30	1.10–1.40
Phosphate (mmol/l)	2.56	–	2.14	–	–	–	1.98	–	–	1.35	1.32	1.47	1.40–2.60
Calcium \times phosphate product (mmol ² /l ²)	11.98	–	8.20	–	–	–	–	–	–	3.63	–	3.70	<5.6
Treatment	–	D	IVFT, D, F, Pr	–	–	–	IVFT, D, F, Pr, P	–	–	D, F, Pr	Pr	–	–

RI = reference interval; D = doxycycline; IVFT = intravenous fluid therapy; F = furosemide; Pr = prednisolone; P = pamidronate

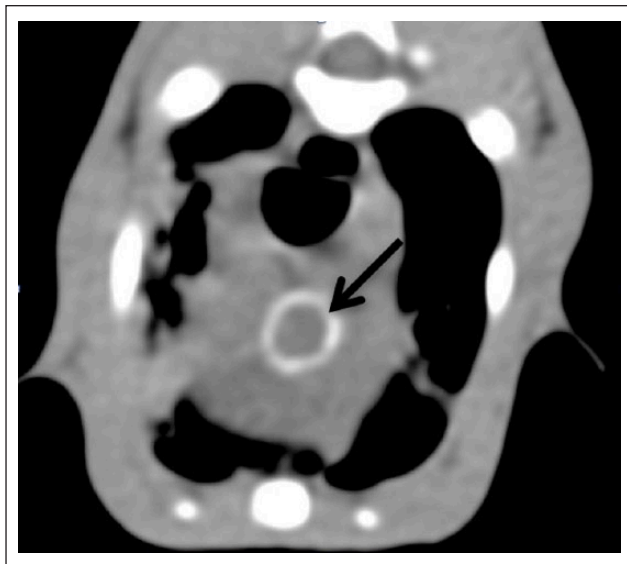


Figure 1 CT image of the thorax of a hypercalcaemic cat (case 1) revealed circumferential mineralisation of the aortic root (arrow)

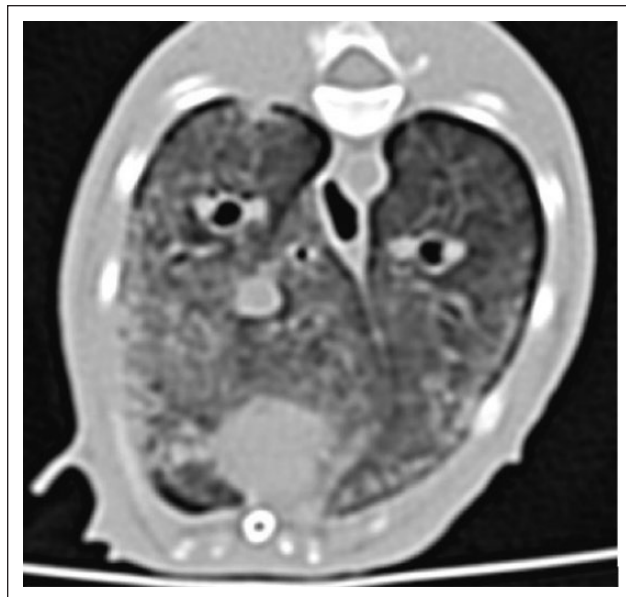


Figure 2 CT image of the thorax of a hypercalcaemic cat (case 1) revealed diffuse interstitial hyperattenuation of the pulmonary parenchyma

a diffuse interstitial hyperattenuation of the pulmonary parenchyma (see Figure 2) consistent with pulmonary mineralisation, pulmonary oedema, pulmonary fibrosis or inflammation. The nasopharynx, oral cavity, pharynx and larynx were unremarkable. Pharyngeal swabs for feline herpesvirus-1 and calicivirus PCRs were negative. The airways had a normal appearance on bronchoscopy. Echocardiography was unremarkable. Following these investigations and pending results the cat was discharged with a course of doxycycline (13 mg/kg q24h PO [Ronaxan 20 mg tablets; Merial]).

Cytology of bronchoalveolar lavage (BAL) samples revealed a highly cellular sample with a mixed inflammatory population (62% macrophages, 32% neutrophils and 6% eosinophils) and no visible microorganisms. Bacterial culture of BAL fluid (BALF) revealed a growth of contaminant only (non-lactose fermenting coliform). *Mycoplasma* species PCR of BALF was positive. *Bordetella bronchiseptica* PCR of the BALF was negative. Faecal analysis (Baermann's) was negative making lungworm infection unlikely.

Differential diagnoses at this stage included idiopathic hypercalcaemia, CKD and vitamin D toxicity. Granulomatous disease or neoplasia had initially been considered as potential causes given the presenting respiratory signs and pulmonary findings; however, these were considered unlikely given the test results. Primary hyperparathyroidism and hypoadrenocorticism were considered unlikely owing to lack of other supportive clinical findings. Furthermore, these would be very rare in cats.

The cat re-presented on day 7 and was reported to be brighter with reduced but persistent coughing and retching and resolution of vomiting and melaena. Serum

biochemistry was repeated and measurement of ionised calcium confirmed persistent hypercalcaemia (see Table 1). Body weight and condition score were stable (1.56 kg and 3/9, respectively).

Blood samples were submitted for parathyroid hormone (PTH), PTH-related protein (PTH-rP) and vitamin D metabolite analysis, prior to treatment for hypercalcaemia. PTH and PTH-rP were within the reported normal laboratory RIs (see Table 2), allowing exclusion of primary hyperparathyroidism and making neoplasia a less likely diagnosis. Both calcidiol and calcitriol concentrations were markedly increased (see Table 2). These findings were consistent with a diagnosis of hypervitaminosis D.

The cat was admitted to the hospital and intravenous (IV) fluid therapy (IVFT) was administered (0.9% NaCl, 2 ml/kg/h). In addition, IV furosemide (2 mg/kg q8h [Dimazon 50 mg/ml solution for injection; MSD]) and oral prednisolone (0.6 mg/kg q12h [Prednicare 1 mg tablets; Animalcare]) were initiated. Doxycycline was continued owing to the positive PCR for *Mycoplasma* species on the BAL sample. The diet was changed to an alternative complete kitten food only. The ionised hypercalcaemia persisted despite this therapy; therefore, on day 11 an IV infusion of pamidronate was administered over 4 h (total dose 1 mg diluted in 0.9% NaCl [Aredia 15 mg powder for reconstitution; Novartis Pharmaceuticals UK]). Subsequently IV furosemide was transitioned to oral furosemide (Frusol 40 mg/ml oral suspension; Rosemount Pharmaceuticals) at the same equivalent dose. The cat responded to the pamidronate with a steady decrease in ionised calcium concentration with

Table 2 Parathyroid hormone (PTH), PTH-related protein (PTH-rP) and vitamin D metabolite concentrations in a hypercalcaemic, 4-month-old female entire domestic shorthair cat (case 1)

	Case 1	RI
PTH	1.6	<4.2 pmol/l
PTH-rP	0.3	<0.5 pmol/l
1,25 Dihydroxyvitamin D (calcitriol)	>438	192–317 pmol/l
25-Hydroxyvitamin D (calcidiol)	2230	65–170 nmol/l
Ionised calcium	2.02	1.10–1.40 mmol/l

References intervals (RIs) for PTH, PTH-rp and calcidiol were provided by the diagnostic laboratory performing sample analysis for PTH, PTH-rP and calcidiol. The RI for calcitriol was not provided and was taken from a previous study,⁶ derived from healthy age-matched control cats

Table 3 Dietary analysis of all foods fed prior to referral to a hypercalcaemic 4-month-old female entire domestic shorthair cat (case 1)

	Vitamin D2 declared	Vitamin D2 measured	Vitamin D2 measured (DM basis)*	Vitamin D3 declared	Vitamin D3 measured	Vitamin D3 measured (DM basis)*	Combined vitamin D2 and D3 measured	Combined vitamin D2 and D3 measured (DM basis)*
Tinned kitten food (IU/kg)	None	9848	54,711	None	49,737	276,316	59,585	331,027
Dry kitten food (IU/kg)	None	616	670	1200	2105	2288	2721	2958
Kitten milk (IU/l)	None	8	58	220	84	612	92	670

See Table 8 for recommended concentrations

*Dry matter (DM) was calculated from the declared moisture content of the tinned food (82%), dry food (8%) and kitten milk (86.3%), and was not measured directly

return to normocalcaemia by day 14 (see Table 1). The cat was discharged on day 14 with doxycycline (13 mg/kg q24h PO), furosemide solution (1.3 mg/kg q12h PO) and prednisolone (0.6 mg/kg q12h PO). In addition, the owner was advised to make a dietary change at home to an alternative high-quality complete kitten food with no additional supplements or complementary foods.

On day 17, the owner reported complete resolution of all the presenting clinical signs. Clinical examination was unremarkable and weight gain had occurred (body weight 1.7 kg, BCS score 5/9). Blood testing confirmed normocalcaemia (ionised calcium). Doxycycline and furosemide were discontinued and prednisolone was tapered to 0.6 mg/kg q24h for a further week and then discontinued.

Repeat haematology on day 31 revealed a stable microcytosis (MCV 37.9 fl; RI 40–55 fl) with a normal PCV (29%; RI 27–50%). Repeat serum biochemistry showed normocalcaemia and no abnormalities (see Table 1). Repeat thoracic CT imaging revealed resolution of the pulmonary interstitial hyperattenuation and improvement in the arterial mineralisation. It was suspected that the pulmonary interstitial hyperattenuation was due to metastatic mineralisation with secondary

inflammatory infiltrate that had resolved with control of the hypercalcaemia. The *Mycoplasma* species infection may also have played a role.

To determine a cause for the hypervitaminosis D, dietary analysis of the foods fed was performed at an independent, external, commercial laboratory (Heartland Assays, Ames, IA, USA). Results are presented in Table 3 and confirmed the presence of a toxic amount of vitamin D in the complementary tinned kitten food.

Cases 2 and 3 (related siblings)

Two British Shorthair siblings (male case 2 and female case 3, both 5 months old and entire) presented to The Feline Centre, Langford Vets, University of Bristol, UK, with a 1 week history of lethargy and inappetence and a 4 day history of polydipsia and polyuria. The cats had initially presented to the referring veterinary practice 2 days previously, at which time serum biochemistry had documented a marked total hypercalcaemia (>4 mmol/l; RI 1.98–2.83 mmol/l) in both cats. In-house haematology and serum biochemistry had also demonstrated mild elevations in urea (case 2: 14.4 mmol/l; case 3: 16.2 mmol/l [RI 5.7–11.8 mmol/l]) and PCVs (case 2: 38.7%; case 3: 41.7% [RI 24.8–37.5%]), consistent with dehydration.

An abdominal ultrasound had been performed at the referring veterinary practice by a board-certified imaging specialist. Case 2 was documented to have prominent renal corticomedullary differentiation and a medullary rim sign bilaterally, which were considered to be clinically insignificant. Case 3 was found to have a large amount of ingesta in the stomach and gas in the intestines. The remainder of the examination was normal and there was no evidence of soft tissue mineralisation or uroliths.

At referral, a full clinical history was obtained. There was no history of ingestion or access to vitamin D containing plants or products. Dietary history revealed that both cats were fed a variety of complete wet and dry cat foods, supplemented by the same complementary natural tinned kitten food fed to case 1, and occasional treats. On physical examination, both cats were bright, alert and responsive, and were in good body condition (case 2 BCS 5/9, body weight 2.24 kg; case 3 BCS 5/9, body weight 1.86 kg). Physical examination of both cats was unremarkable, with the exception of a grade II/VI systolic heart murmur detected in case 2.

Venous blood gas and electrolyte analysis at admission confirmed ionised hypercalcaemia in both cats (see Tables 4 and 5). Haematology and biochemistry were not performed at admission as they had recently been performed at the referring vets. Urinalysis (following initiation of IVFT) revealed case 2 to have a urine specific gravity (USG) of 1.033, mild (1+) calcium oxalate crystalluria and a urine protein to creatinine (UPC) ratio of 0.14 (RI <0.4). Case 3 had a USG post-IVFT of 1.012, UPC of 0.22 and scant squamous epithelial cells, scant white blood cells and scant struvite crystals on sediment examination (small bladder size on admission prevented collection of samples before fluid therapy).

Thoracic and abdominal radiographs of both cats were unremarkable with no evidence of metastatic mineralisation. Additionally, echocardiographic examination was performed in case 2 and showed an incidental flow murmur, not considered to be of clinical significance.

PTH, vitamin D metabolites and calcitonin were measured in both cats (see Table 6). PTH-rP was not measured owing to limited suspicion of neoplasia considering the age and presentation of the cats and to insufficient sample volume. PTH, calcitriol, calcidiol and calcitonin were measured using previously validated assays.⁷⁻⁹ Calcitriol and calcidiol were increased in both cats confirming hypervitaminosis D. Vitamin D toxicity was suspected to be the underlying cause of this. Calcitonin concentration was undetectable in both cats.

The cats were initially managed for hypercalcaemia with IVFT (0.9% NaCl, 4 ml/kg/h); however, ionised calcium concentrations remained persistently elevated (see Tables 4 and 5). Therefore, prednisolone (2.5 mg/

Table 4 Calcium, phosphate and renal markers at presentation and follow-up in a 5-month-old male entire British Shorthair cat (case 2) treated for suspected hypervitaminosis D toxicity

Case 2	Day 1	Day 2	Day 3	Day 4	Day 5	Day 6	Day 8	Day 10	Day 15	Day 18	Day 22	Day 30	Day 46	Day 54	RI
Creatinine ($\mu\text{mol/l}$)			83				70	72	76		59	81			133-175
Urea (mmol/l)			7.0				8.4	9.4	9.8		7.6	7.6			6.5-10.5
Ionised calcium (mmol/l)	1.82	1.94	1.72	1.80	1.65	1.45	1.64	1.76	1.46	1.31	1.31	1.33	1.43	1.27	1.10-1.40
Total calcium (mmol/l)			3.92				3.52	3.94	3.39		2.78	2.97			2.30-2.50
Phosphate (mmol/l)			1.89				1.74	1.84	2.14		1.98	2.63			0.95-1.55
Calcium \times phosphate product (mmol^2/l^2)			7.41				6.12	7.25	7.25		5.50	7.81			<5.6
Treatment	IVFT	IVFT, F, Pr			F, Pr, Fy					Pr	Pr				

RI = reference interval; IVFT = intravenous fluid therapy; F = furosemide; Pr = prednisolone; Fy = Fybogel

Table 5 Calcium, phosphate and renal markers at presentation and follow-up in a 5-month-old female entire British Shorthair cat (case 3) treated for suspected hypervitaminosis D toxicity (case 3)

Case 3	Day 1	Day 2	Day 3	Day 4	Day 5	Day 6	Day 8	Day 15	Day 18	Day 22	Day 30	Day 46	Day 54	RI
Creatinine ($\mu\text{mol/l}$)			87			58			82	45				133–175
Urea (mmol/l)			8			7.1			10.0	6.7				6.5–10.5
Ionised calcium (mmol/l)	1.83	1.91	1.61	1.59	1.37	1.24	1.23	1.31	1.26	1.33	1.27	1.30	1.24	1.10–1.40
Total calcium (mmol/l)			3.41			2.76			2.85	2.82				2.30–2.50
Phosphate (mmol/l)			2.01			1.66			2.16	2.07				0.95–1.55
Calcium \times phosphate product (mmol^2/l^2)			6.85			4.58			6.16	5.84				<5.6
Treatment				IVFT	IVFT, F, Pr									

RI = reference interval; IVFT = intravenous fluid therapy; F = furosemide; Pr = prednisolone

cat q12h PO [Prednidale 5 mg; Dechra Pharmaceuticals]) and furosemide (5 mg/cat q12h PO; generic preparation) were incorporated into the management. Following this (day 5), the ionised calcium concentration in case 3 normalised and furosemide administration was discontinued and the prednisolone was gradually tapered and discontinued (see Table 5). In case 2, the hypercalcaemia persisted and additional management with psyllium husk (Fybogel powder [Reckitt Benckiser Healthcare]; 1/4 teaspoon q6h mixed with food PO) was prescribed in order to promote intestinal binding of calcium (see Table 4).

The cats were discharged on day 12. In case 2, medications prescribed as above were continued until normocalcaemia was achieved at day 18 when these were gradually tapered and discontinued (see Table 4). Case 3 was discharged without medication.

Cases 2 and 3 were fed the same complementary tinned kitten food as part of their diet as case 1. Dietary analysis of this complementary diet was performed. The complementary natural kitten food was submitted to an independent, external, commercial laboratory (ALS Food and Pharmaceutical, Ely, UK) for quantification of calcium, phosphorus, vitamin D and moisture levels. Results showed markedly excessive vitamin D levels (Table 7).

Discussion

This case series describes three cases of vitamin D toxicosis in young cats that presented with hypercalcaemia, in which a natural complementary tinned kitten food that contained excessive vitamin D concentrations was fed as part of the diet. In case 1, a dry complete food from the same manufacturer was also fed to the cat. The measured vitamin D content in this dry food was over twice the declared amount of added vitamin D and also above the legal limit for declared additives (see Tables 2 and 8). The tinned complementary food label stated that there were no additives; ingredients were listed as chicken breast (53%), rice and minerals. As there is no legal limit for the amount of naturally occurring vitamin D in cat foods, the nutritional maximum rather than legal limit should be considered when interpreting the dietary analysis of the tinned food. In all three cases, analysis of the tinned food confirmed vitamin D concentration to be between 11 and 13.5 times the upper nutritional maximum. As chicken breast/fillets are naturally low in vitamin D (0–216 IU/kg),¹⁰ this suggests either contamination of the ingredients used in the manufacturing process of the food or supplementation of additives not stated on the label. As both vitamin D₂ and vitamin D₃ were increased in the food analysis it suggests there was contamination or supplementation of both forms. It is likely that high levels of vitamin D₃ contributed to a greater extent to the hypervitaminosis D than high vitamin D₂

Table 6 Parathyroid hormone (PTH), vitamin D metabolite and calcitonin results in hypercalcaemic male (case 2) and female (case 3) 5-month-old British Shorthair cats

	Case 2	Case 3	RI
PTH (pmol/l)	<0.2	<0.2	0.3–4.0*
1,25 Dihydroxyvitamin D (calcitriol; pmol/l)	436.4	406.3	192–317†
25-Hydroxyvitamin D (calcidiol; nmol/l)	553.4	242.5	126–163†
Calcitonin (ng/l)	<0.9	<0.9	<0.9–3.2‡
Ionised calcium (mmol/l)	1.94	1.91	1.10–1.40

*Reference interval (RI) taken from Pineda et al⁷

†RI taken from Tomsa et al,⁶ which was derived in healthy age-matched control cats

‡RI taken from Pineda et al⁸

Table 7 Dietary analysis of the complementary natural tinned kitten food fed to two 5-month-old British Shorthair cats (case 2 and 3) as part of their diet

	Vitamin D3 (IU/kg)	Vitamin D2 (IU/kg)	Vitamin D2 and D3 combined (IU/kg)	Calcium (g/kg)	Phosphate (g/kg)	Calcium:phosphate ratio
Tinned kitten food (wet weight as fed)	53,500	14,500	68,000	0.058	0.835	0.069
Tinned kitten food (DM basis)*	318,325	86,275	404,600	0.345	4.968	0.069

See Table 8 for recommended concentrations

*Actual dry matter (DM) content (16.8%) determined in an independent external commercial laboratory (ALS Food and Pharmaceutical, Ely, UK)

Table 8 European pet food industry (FEDIAF) nutritional guidelines for complete and complementary pet foods¹²

	Minimum recommended (adults)	Minimum recommended (growth)	Maximum nutritional (adult)*	Maximum nutritional (growth)*	Legal limit†
Calcium (g/kg DM)	5.9	10.0	NA	NA	NA
Phosphate (g/kg DM)	5.0	8.4	NA	NA	NA
Calcium:phosphate ratio	1:1	1:1	2:1	1.5:1	NA
Vitamin D (IU/kg DM)‡	250	750	30000	30000	2270

*Maximum nutritional limit is the maximum level of nutrition in a complete pet food that, based on scientific data, has not been associated with adverse effects in healthy cats

†The legal limit (European Union regulation 1831/2003) applies to all life stages. It only applies when the vitamin is a declared additive. If the nutrient is derived exclusively from the feed materials, the legal maximum does not apply and instead the nutritional maximum should be taken into account

‡Vitamin D is combined ergocalciferol (vitamin D2) and cholecalciferol (vitamin D3) content

DM = dry matter; NA = not available

levels as cats utilise vitamin D3 with greater efficiency to maintain plasma 25-hydroxyvitamin D concentrations.¹¹ It is important to note that the food label should state the vitamin D concentration at the end of the shelf-life of the product and therefore higher values may be expected if analysed before this date. Despite this caveat, the levels in the food fed to the cats were still higher than the nutritional maximum.

The dietary calcium and phosphate concentration and calcium:phosphate ratios were very low when analysed in the tinned food (case 2 and 3). When considering the recommended requirements for a growing cat

(see Table 8), the calcium concentration of the diet was approximately 30 times below the requirement and the phosphate concentration approximately 1.7 times below the requirement. Low calcium content or altered calcium:phosphate ratio of the diet can be associated with nutritional secondary hyperparathyroidism, in which low calcium stimulates production of PTH from the parathyroid gland. In all three cases, PTH concentration was at the low end of the RI or below it and not suggestive of nutritional secondary hyperparathyroidism as expected in the case of vitamin D toxicosis. Nutritional secondary hyperparathyroidism generally develops

with chronic calcium deficiency and it is possible that, had the cats been fed the diet in the longer term, clinical evidence of nutritional secondary hyperparathyroidism may have developed if, indeed, the source of high vitamin D was due to an inadvertent one-off contamination as opposed to excessive supplementation. However, the development of nutritional secondary hyperparathyroidism seems unlikely in the presence of high vitamin D as plasma concentrations of calcium will be high and calcitriol has a negative influence on PTH production.

A parallel increase in calcium and phosphate concentration in patients with hypervitaminosis D might be expected. It is therefore interesting that only cases 2 and 3 were hyperphosphataemic (although the influence of age must be considered when interpreting this result) and highlights that hypervitaminosis D should be included as a differential diagnosis for cases with hypercalcaemia even if the serum phosphate is normal.

The clinical signs in case 1 could all be explained by the hypercalcaemia; the coughing and retching were likely due to pulmonary mineralisation, although the *Mycoplasma* species found on BAL PCR and mild airway inflammation may also have played a role; the pica and melaena were likely due to gastrointestinal bleeding from gastrointestinal wall mineralisation,¹³ and this would be consistent with the hyperechoic gastric wall identified on ultrasound examination. The lethargy, inappetence and polyuria/polydipsia in cases 2 and 3 were all likely secondary to the hypercalcaemia. Of interest was the finding that case 1 not only had the highest serum concentration of vitamin D metabolites and most likely ingested a greater amount of the food, but also presented with the more severe clinical signs.

As vitamin D is a fat-soluble vitamin, it will persist in the body for weeks to months following toxicity, with the decline in calcitriol concentration thought to be more rapid than for calcidiol. It was not possible to perform serial measurements of vitamin D in any of the cats; however, the relatively rapid resolution of clinical signs and return to normocalcaemia in all three cats following withdrawal of the suspected source of vitamin D (19 days for case 1, 18 days for case 2 and 5 days for case 3) and the absence of relapse of hypercalcaemia after treatment discontinuation suggests that either the clinical effects of the toxicity were not prolonged or that the supportive management was effective. Furthermore, the mineralisation present on the initial CT scan in case 1 had improved at repeat CT imaging (day 31 following initial presentation; data not shown). The time taken for complete resolution of the mineralisation could not be ascertained as further imaging was not performed.

Calcitonin concentrations were measured in case 2 and 3. Calcitonin is produced from C cells in the thyroid gland in response to hypercalcaemia and it inhibits osteoclastic activity, decreasing bone resorption. In cases of

hypercalcaemia, calcitonin concentration would be expected to be elevated with the effect of decreasing calcium concentrations; however, in cases 2 and 3 calcitonin was not increased. A previous study of cats in which hypercalcaemia was induced experimentally found a subset of cats that did not increase their calcitonin concentration in response to ionised hypercalcaemia, and these cats were termed non-responders.⁸ It is possible that cases 2 and 3 were also 'non-responders'. The underlying mechanism for this lack of increase in calcitonin concentration is unknown and may be related to mutations in the calcium-sensing receptor in the parathyroid gland. Further studies exploring calcitonin response in hypercalcaemic cats are warranted.

A limitation of this case study is that analysis of other foods fed in cases 2 and 3 was not performed owing to the extensive variability and high cost of analysis, and also suspicion related to the diet raised in case 1.

Conclusions

This case series highlights the importance of considering nutritional hypervitaminosis D as a differential diagnosis in cats with hypercalcaemia even if the serum phosphate is not elevated. Measurement of vitamin D metabolites is recommended in investigating such cases. In addition, it demonstrates the importance of obtaining a thorough dietary history and performing dietary analysis in cases of suspected vitamin D toxicity even when a single diet is not fed exclusively or when the diet is marketed as a natural, complementary product without added vitamin D.

Acknowledgements We thank Dr Manuel Pinilla from Vet CT Specialists for the CT interpretation of case 1.

Author note Some of these data were presented in poster format at the 2014 International Society of Feline Medicine Congress, Riga, Latvia, and in case presentation format at the Small Animal Medicine Society Winter Meeting 2014, Chester, UK.

Conflict of interest The authors declared no potential conflicts of interest with respect to the research, authorship, and/or publication of this article.

Funding The food analysis in cases 2 and 3 was funded by Langford Vets' clinical research fund. The 2013 International Renal Interest Society award made to N Finch funded the publication of this manuscript.

References

- 1 Midkiff AM, Chew DJ, Randolph JF, et al. **Idiopathic hypercalcaemia in cats.** *J Vet Intern Med* 2000; 14: 619–626.
- 2 Savary KC, Price GS and Vaden SL. **Hypercalcaemia in cats: a retrospective study of 71 cases (1991–1997).** *J Vet Intern Med* 2000; 14: 184–189.
- 3 Finch NC. **Hypercalcaemia in cats: the complexities of calcium regulation and associated clinical challenges.** *J Feline Med Surg* 2016; 18: 387–399.

- 4 Morris JG. **Ineffective vitamin D synthesis in cats is reversed by an inhibitor of 7-dehydrocholesterol-delta7-reductase.** *J Nutr* 1999; 129: 903–908.
- 5 Wehner A, Katzenberger J, Groth A, et al. **Vitamin D intoxication caused by ingestion of commercial cat food in three kittens.** *J Feline Med Surg* 2013; 15: 730–736.
- 6 Tomsa K, Glaus T, Hauser B, et al. **Nutritional secondary hyperparathyroidism in six cats.** *J Small Anim Pract* 1999; 40: 533–539.
- 7 Pineda C, Aguilera-Tejero E, Raya AI, et al. **Feline parathyroid hormone: validation of hormonal assays and dynamics of secretion.** *Domest Anim Endocrinol* 2012; 42: 256–264.
- 8 Pineda C, Aguilera-Tejero E, Raya AI, et al. **Assessment of calcitonin response to experimentally induced hypercalcemia in cats.** *Am J Vet Res* 2013; 74: 1514–1521.
- 9 Pineda C, Aguilera-Tejero E, Guerrero F, et al. **Mineral metabolism in growing cats: changes in the values of blood parameters with age.** *J Feline Med Surg* 2013; 15: 866–871.
- 10 Schmid A and Walther B. **Natural vitamin D content in animal products.** *Adv Nutr* 2013; 4: 453–462.
- 11 Morris JG. **Cats discriminate between cholecalciferol and ergocalciferol.** *J Anim Physiol Anim Nutr* 2002; 86: 229–238.
12. FEDIAF. Nutritional guidelines for complete and complementary pet foods. www.fediaf.org (2013).
- 13 McLeland SM, Lunn KF, Duncan CG, et al. **Relationship among serum creatinine, serum gastrin, calcium-phosphorus product, and uremic gastropathy in cats with chronic kidney disease.** *J Vet Intern Med* 2014; 28: 827–837.