

Severe oesophageal constriction due to an aberrant right subclavian artery with Kommerell's diverticulum in a cat

Authors: Suzuki, Ryohei, Mochizuki, Yohei, Yoshimatsu, Hiroki, Niina, Ayaka, Teshima, Takahiro, et al.

Source: Journal of Feline Medicine and Surgery Open Reports, 4(1)

Published By: SAGE Publishing

URL: <https://doi.org/10.1177/2055116918764589>

The BioOne Digital Library (<https://bioone.org/>) provides worldwide distribution for more than 580 journals and eBooks from BioOne's community of over 150 nonprofit societies, research institutions, and university presses in the biological, ecological, and environmental sciences. The BioOne Digital Library encompasses the flagship aggregation BioOne Complete (<https://bioone.org/subscribe>), the BioOne Complete Archive (<https://bioone.org/archive>), and the BioOne eBooks program offerings ESA eBook Collection (<https://bioone.org/esa-ebooks>) and CSIRO Publishing BioSelect Collection (<https://bioone.org/csiro-ebooks>).

Your use of this PDF, the BioOne Digital Library, and all posted and associated content indicates your acceptance of BioOne's Terms of Use, available at www.bioone.org/terms-of-use.

Usage of BioOne Digital Library content is strictly limited to personal, educational, and non-commercial use. Commercial inquiries or rights and permissions requests should be directed to the individual publisher as copyright holder.

BioOne is an innovative nonprofit that sees sustainable scholarly publishing as an inherently collaborative enterprise connecting authors, nonprofit publishers, academic institutions, research libraries, and research funders in the common goal of maximizing access to critical research.



Severe oesophageal constriction due to an aberrant right subclavian artery with Kommerell's diverticulum in a cat

Ryohei Suzuki¹, Yohei Mochizuki, Hiroki Yoshimatsu, Ayaka Niina, Takahiro Teshima, Hirotaka Matsumoto and Hidekazu Koyama

Journal of Feline Medicine and Surgery Open Reports
1–5

© The Author(s) 2018

Reprints and permissions:

sagepub.co.uk/journalsPermissions.nav

DOI: 10.1177/2055116918764589

journals.sagepub.com/home/jfmsopenreports

This paper was handled and processed by the European Editorial Office (ISFM) for publication in *JFMS Open Reports*



Abstract

Case summary A 6-month-old female cat with a history of chronic regurgitation presented with weight loss. CT angiography (CTA) showed severe constriction of the oesophagus due to an aberrant right subclavian artery and Kommerell's diverticulum. The cat was surgically treated and remained clinically normal. More than 1 year after surgery, the general condition of the cat was stable and body weight had increased.

Relevance and novel information This case report describes the clinical findings and surgical management of a cat diagnosed with severe oesophageal constriction caused by an aberrant right subclavian artery with Kommerell's diverticulum (markedly dilated origin of the aberrant right subclavian artery), which are rare vascular anomalies in veterinary medicine and specifically in cats. The Kommerell's diverticulum compressed the oesophagus and contributed to the severe oesophageal constriction in this case. Preoperative CTA was useful in the diagnosis and treatment planning.

Accepted: 19 February 2018

Introduction

Vascular ring anomalies (VRAs) are congenital malformations of the heart vessels and their branches, which cause constriction of the oesophagus and signs of oesophageal obstruction.^{1–3} They are common in dogs but rarely observed in cats.^{1–8} The most common type of VRA is a persistent right aortic arch with a left ductus arteriosus or ligamentum arteriosum.^{1–3,8} A presumptive diagnosis of a VRA is commonly made from the history of the patient and results of the clinical and radiographic examinations.^{1–5,8} However, clinical diagnosis is sometimes difficult in the case of rare and complex vascular anomalies.^{3,6–8} Furthermore, the treatment of choice for complex VRAs depends on an accurate anatomic diagnosis.^{8,9}

Recently, CT angiography (CTA) has become more widely available as a diagnostic modality and has increased the frequency and accuracy of diagnoses in veterinary medicine.⁸ This case report describes the clinical findings and surgical management of a cat examined by CTA and diagnosed with severe oesophageal

constriction caused by an aberrant right subclavian artery with Kommerell's diverticulum, which are rare vascular anomalies in cats.⁸

Case description

A 6-month-old female American Shorthair cat was presented for the investigation of vomiting and regurgitation following the ingestion of solid food. The cat had

Laboratory of Veterinary Internal Medicine, Division of Therapeutic Sciences 1, Department of Veterinary Clinical Medicine, Faculty of Veterinary Medicine, Nippon Veterinary and Life Science University, Tokyo, Japan

Corresponding author:

Ryohei Suzuki DVM, PhD, Laboratory of Veterinary Internal Medicine, Division of Therapeutic Sciences 1, Department of Veterinary Clinical Medicine, Faculty of Veterinary Medicine, Nippon Veterinary and Life Science University, 1-7-1 Kyonan-cho, Musashino-shi, Tokyo, 180-8602, Japan
Email: ryoheisuzuki0130@gmail.com



Creative Commons Non Commercial CC BY-NC: This article is distributed under the terms of the Creative Commons

Attribution-NonCommercial 4.0 License (<http://www.creativecommons.org/licenses/by-nc/4.0/>) which permits non-commercial use, reproduction and distribution of the work without further permission provided the original work is attributed as specified on the SAGE and Open Access pages (<https://us.sagepub.com/en-us/nam/open-access-at-sage>).

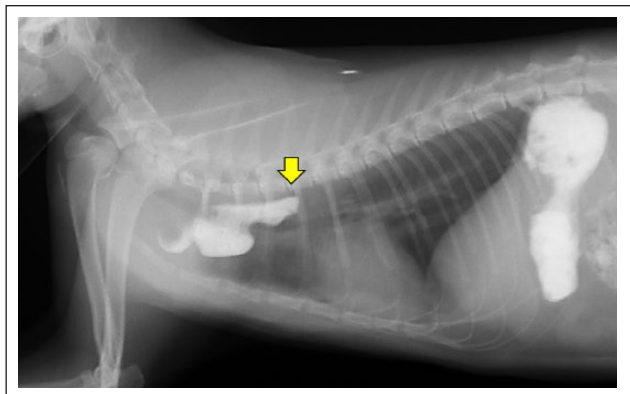


Figure 1 Positive contrast oesophagram (lateral view) of the cat. Abrupt attenuation of the pasted barium contrast column is observed at the cranial site of the heart base along with cranial oesophageal dilation (arrow)

been experiencing this problem since it had been acquired as a kitten, and the issue had been dealt with by providing meals with water or wet food.

Physical examination revealed poor growth (body weight 2.4 kg, body condition score 3/9),¹⁰ although the cat had a voracious appetite. Auscultation revealed normal heart and lung sounds. Thoracic radiography, including a positive contrast oesophagram (barium with wet food), was performed. The lateral view of the positive contrast oesophagram is shown in Figure 1. Radiographic findings included marked dilation of the oesophagus cranial to the heart base, and a VRA was suspected. However, the site of constriction of the oesophagus was not clearly identifiable on the radiograph, and it was concluded that the oesophageal constriction was too far cranial with respect to the heart base to have been associated with a classic persistent right aortic arch VRA.^{1–3} Other examinations, including complete blood cell count, serum biochemical analysis, electrocardiography, echocardiography, abdominal ultrasonography and non-invasive blood pressure measurements, revealed normal findings.

For the CT examination, the cat was induced by propofol (approximately 6 mg/kg, to effect, IV), maintained with 2% isoflurane mixed with 100% oxygen and mechanically ventilated. Electrocardiography-gated CTA (Iopamidol, 2 ml/kg, bolus tracking method) was performed with an 80-detector-row CT system (Aquilion Prime; Toshiba) in order to confirm and classify the suspected VRA, and to determine if surgical correction would be possible. Three-dimensional reconstruction images of CTA in the cat are shown in Figure 2. The aortic arch and proximal descending aorta were located to the left of the midline, which is a normal finding. However, the following vascular anomalies were observed: (1) the right

subclavian artery branched aberrantly from the proximal descending aorta (aberrant right subclavian artery); (2) the origin of the aberrant right subclavian artery from the aorta was markedly dilated (Kommerell's diverticulum; this is considered to be present when the diameter of the subclavian artery near its origin from the aortic arch is at least 1.5 times the diameter at its more distal end);¹¹ and (3) the left and right carotid artery directly branched from the aorta (bicarotid trunk). The site of constriction of the oesophagus was apparent at the level of the aberrant right subclavian artery with Kommerell's diverticulum. Any other malformations that could cause oesophageal constriction were not detected.

The cat was premedicated with midazolam (0.2 mg/kg IV) and morphine (0.3 mg/kg SC), induced by propofol (approximately 4 mg/kg, to effect, IV), maintained with 1–1.5% isoflurane mixed with 100% oxygen, and manually ventilated. A left lateral thoracotomy was performed at the level of the third intercostal space via standard procedures. The intra-operative view of the cat is shown in Figure 3. The aberrant right subclavian artery with Kommerell's diverticulum extended over the oesophagus from left to right, pressing it ventrally. Angiography (Iopamidol, 1 ml/kg) was performed with fluoroscopy to check the blood flow in the right subclavian artery peripheral to the right thoracic limb (Figure 4). The aberrant right subclavian artery was ligated using 3-0 non-absorbable polyester suture (Ethibond excel; Ethicon) and transected. Balloon dilation of the oesophagus was also performed. A gastrostomy tube was installed to ensure adequate nutrition postoperatively. Atropine sulphate (0.01 mg/kg, IV) was administered, as needed. Bupivacaine hydrochloride (1 mg/kg) was administered at the incision area and the surrounding intercostal muscles during the operation. After the operation, orbifloxacin (5 mg/kg q24h), famotidine (1 mg/kg q24h) and metoclopramide (0.2 mg/kg q12h) were administered for 7 days and postoperative pain was treated with meloxicam (0.1 mg/kg q24h) for 7 days after surgery. Wet food was gradually introduced, with the cat in an upright posture, on the day after surgery. To maintain the minimum calorie intake (resting energy requirement calorie), residual wet food and fresh water were administered, as needed, using a gastrostomy tube.

The cat recovered well after surgery and the gastrostomy tube was removed on day 14 postoperatively. Right thoracic limb function appeared normal. There was no evidence of reduced perfusion in the limb; the foot was warm and the pad colour appeared normal. At 3 months postoperatively, fluoroscopy with a positive contrast oesophagram (barium with wet food) was performed. Although mild dilation of the oesophagus was still observed, the

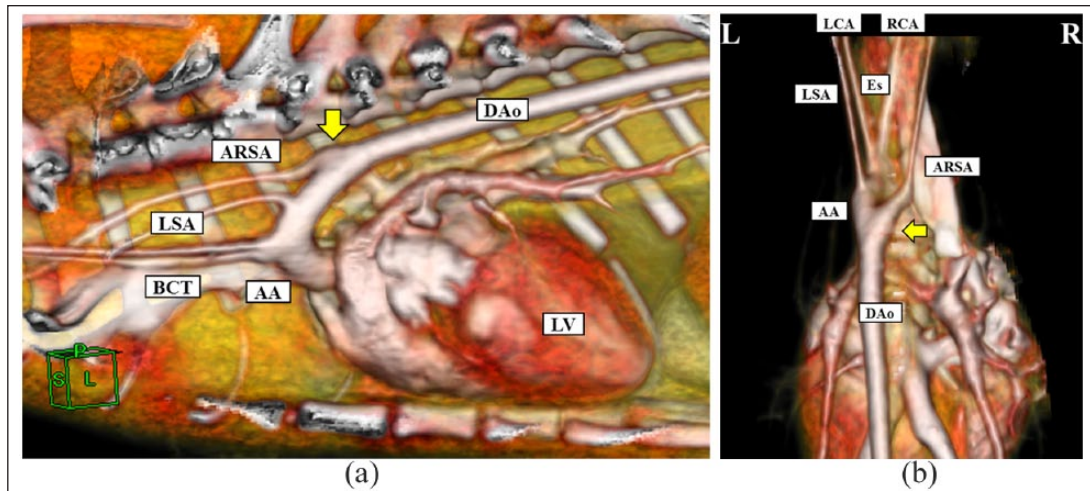


Figure 2 (a) Left lateral and (b) dorsoventral images of three-dimensional CT angiography reconstruction in the cat. Note the aberrant right subclavian artery and left and right carotid arteries directly branching from the descending aorta. The dilated origin of the aberrant right subclavian artery (Kommerell's diverticulum) is also an unusual finding. AA = aortic arch; ARSA = aberrant right subclavian artery; BCT = bicarotid trunk; DAo = descending aorta; Es = oesophagus; LCA = left carotid artery; LSA = left subclavian artery; LV = left ventricle; RCA = right carotid artery

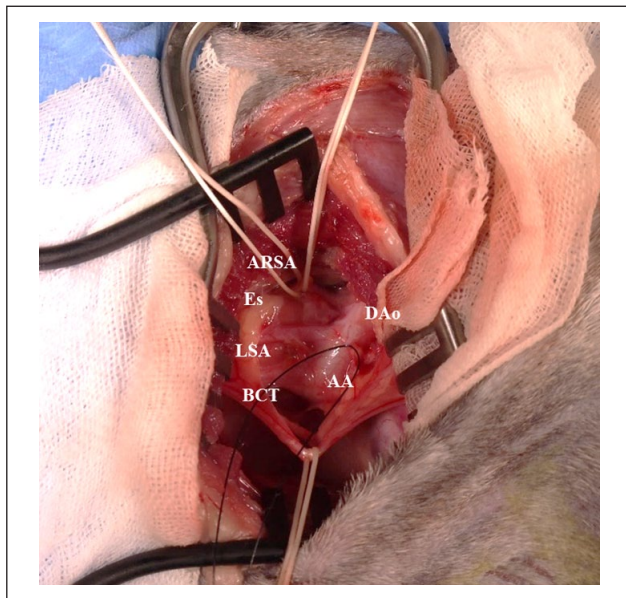


Figure 3 Intraoperative view of the cat showing a white silk thread passed around the aberrant right subclavian artery prior to its ligation and division. A black silk thread is shown around the left aortic arch. The dorsal and cranial aspects of the surgical field are to the top and left of the image, respectively. AA = aortic arch; ARSA = aberrant right subclavian artery; BCT = bicarotid trunk; DAo = descending aorta; Es = oesophagus; LSA = left subclavian artery

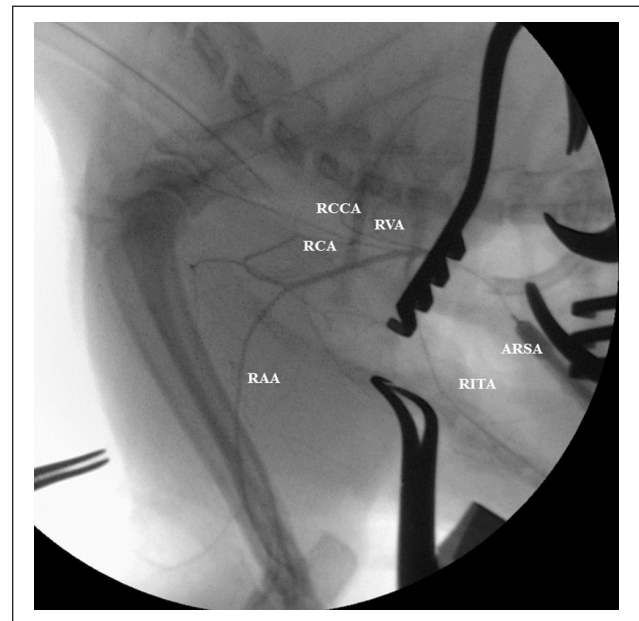


Figure 4 Intraoperative angiogram of the aberrant right subclavian artery in the cat. ARSA = aberrant right subclavian artery; RAA = right axillary artery; RCA = right carotid artery; RCCA = right costal carotid artery; RITA = right internal thoracic artery; RVA = right vertebral artery

constriction of the oesophagus had resolved and the passing time of barium was markedly shortened. More than 1 year after surgery, the general condition of the cat was stable (no regurgitation after ingestion of solid food) and the body weight was 2.8 kg (body condition score 5/9).¹⁰

Discussion

VRAs are congenital malformations of the arteries of the heart that entrap the intrathoracic oesophagus and cause oesophageal obstruction.¹⁻³ There are a number of VRAs associated with the persistent right aortic arch and a left ductus arteriosus or ligamentum arteriosum described in

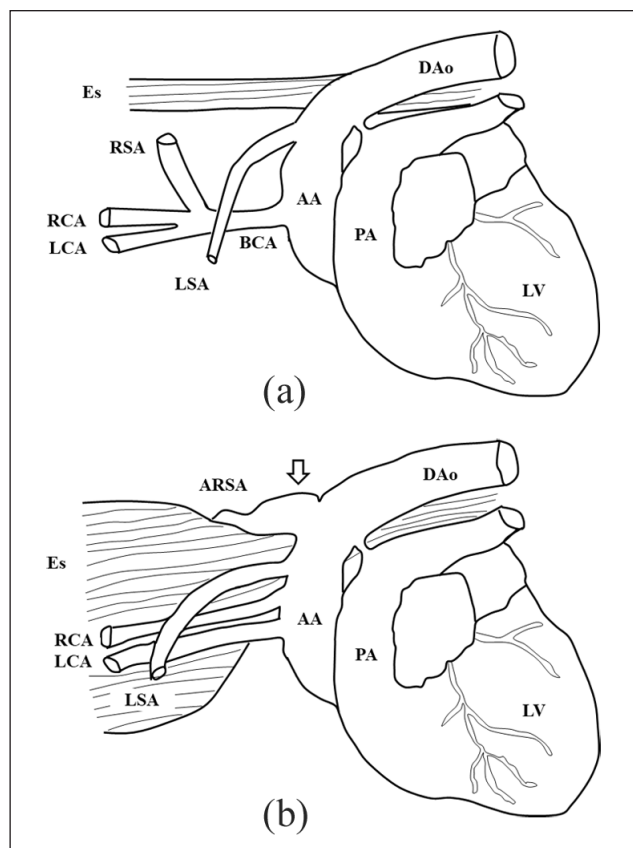


Figure 5 Diagrammatic scheme of the vascular structure for (a) a normal cat and (b) the abnormal structure of the presented patient. The dilated origin of the aberrant right subclavian artery (Kommerell's diverticulum) is an unusual finding. AA = aortic arch; ARSA = aberrant right subclavian artery; BCA = brachiocephalic artery; DAo = descending aorta; Es = oesophagus; LCA = left carotid artery; LSA = left subclavian artery; LV = left ventricle; PA = pulmonary artery; RCA = right carotid artery; RSA = right subclavian artery

veterinary medicine.^{1–5,8} However, other vascular anomalies that cause severe oesophagus constriction have not been examined as much in cats. In the case described here, the cat was diagnosed with severe oesophageal constriction caused by an aberrant right subclavian artery with Kommerell's diverticulum and a bicarotid trunk, which are rare vascular structures in cats.⁸ A diagrammatic scheme of the abnormal structure for the presented cat and the vascular structure for a normal cat are shown in Figure 5.

VRAs should be differentiated from other causes of regurgitation in young animals, such as congenital megaesophagus, oesophageal foreign body and cricopharyngeal dysplasia.¹ Thoracic radiography is a useful tool to diagnose a typical persistent right aortic arch in young dogs.³ However, accurate anatomic diagnosis and treatment planning for animals with rare and complex vascular anomalies are sometimes difficult.^{3,6–8} In this case, the

site of the oesophageal constriction, as visible on the positive contrast oesophagram, was considered too far cranial to have been associated with the persistent right aortic arch and left ligamentum arteriosum.^{1–3,5} In contrast, CTA proved to be valuable in that it confirmed the presence of a congenital malformation as the cause of the oesophageal constriction in this cat. This modality also allows accurate anatomic diagnosis of complex and rare vascular anomalies.¹² Furthermore, preoperative CTA can help in surgical treatment planning, ensuring minimal and appropriate surgery in affected animals.

A previous report on VRAs demonstrated that malformation of the subclavian artery alone did not lead to severe oesophageal constriction.⁸ Furthermore, in the case presented here, the aortic arch was located normally, ie, to the left of the midline, and did not show the typical circular vascular ring formation. However, the cat had severe oesophageal constriction because of an aberrant right subclavian artery. Kommerell's diverticulum is a dilation of the proximal portion of an aberrant subclavian artery near its origin from the aorta and is expected to be remnant of the left fourth aortic arch.¹³ In humans, Kommerell's diverticulum has been shown to compress the oesophagus in the absence of any other vascular anomaly.¹⁴ Although that anomaly was rarely reported in cats,^{7,8} a markedly dilated origin of the aberrant right subclavian artery (Kommerell's diverticulum) would have pressed the oesophagus more strongly,^{13–15} inducing the severe oesophageal constriction in this case.

In veterinary medicine, the treatment of choice for VRAs is surgical ligation and transection of the anomalous vessels.^{1–3,8} In contrast, human studies have demonstrated that resection of the aberrant artery and re-anastomosis with another artery is recommended to prevent reduced blood supply to the peripheral thoracic limb.^{14,15} In this case, we tried to anastomose the aberrant artery with the right internal thoracic artery. However, these arteries were too small to be re-anastomosed, and we abandoned the attempt. Although there was no evidence of reduced blood perfusion in the peripheral thoracic limb of the cat in this case, larger patients with greater blood supply to the aberrant subclavian artery may require re-anastomosis. Recently, thoracoscopic correction for a cat with persistent right aortic arch has been demonstrated.⁵ However, complex and rare vascular anomalies, as in this case, should be treated based on each patient's anatomical features and optimal surgical strategy is crucial for surgical treatment.⁹

In order to decrease the severity of oesophageal dilation and dysfunction, it is recommended that surgical intervention not be delayed following confirmation of a VRA in veterinary medicine.^{1,3,16,17} Furthermore, postoperative nutritional supplementation is critical for

recovery and adequate growth of patients.¹⁸ In the case reported here, a stable clinical condition and good growth after surgery could be attributed to the early surgical intervention and postoperative nutrition management using a gastrostomy tube.

Conclusions

This report describes rare vascular anomalies, including an aberrant right subclavian artery with Kommerell's diverticulum and a bicarotid trunk, as the cause of severe oesophageal constriction in a cat. Markedly dilated origin of the aberrant right subclavian artery (Kommerell's diverticulum), which is a rare finding in veterinary medicine, would have compressed the oesophagus and contributed to the severe oesophageal constriction in this case. Preoperative CTA was useful in the diagnosis and treatment planning.

Acknowledgements The authors thank Drs Maki Suzuki and Ami Fujie for their technical assistance.

Conflict of interest The authors declared no potential conflicts of interest with respect to the research, authorship, and/or publication of this article.

Funding The authors received no financial support for the research, authorship, and/or publication of this article.

ORCID iD Ryohei Suzuki  <https://orcid.org/0000-0001-9451-5854>

References

- Jergens EA. **Diseases of the esophagus.** In: Feldman CE and Ettinger JS (eds). *Textbook of veterinary internal medicine.* 7th ed. St Louis, MO: Saunders Elsevier, 2010, pp 1487–1499.
- Radlinsky GM. **Surgery of the digestive system.** In: Fossum WT (ed). *Small animal surgery.* 4th ed. St Louis, MO: Mosby Elsevier, 2013, pp 386–583.
- Buchanan JW. **Tracheal signs and associated vascular anomalies in dogs with persistent right aortic arch.** *J Vet Intern Med* 2004; 18: 510–514.
- Tidholm A, Ljungvall I, Michal J, et al. **Congenital heart defects in cats: a retrospective study of 162 cats (1996–2013).** *J Vet Cardiol* 2015; 17 Suppl 1: S215–S219.
- Plesman R, Johnson M, Rurak S, et al. **Thoracoscopic correction of a congenital persistent right aortic arch in a young cat.** *Can Vet J* 2011; 52: 1123–1128.
- White RN, Burton CA and Hale JS. **Vascular ring anomaly with coarctation of the aorta in a cat.** *J Small Anim Pract* 2003; 44: 330–334.
- Shannon D, Husnik R, Fletcher JM, et al. **Persistent right aortic arch with an aberrant left subclavian artery, Kommerell's diverticulum and bicarotid trunk in a 3-year-old cat.** *JFMS Open Rep* 2015; 1: DOI: 2055116915614590.
- Henjes CR, Nolte I and Wefstaedt P. **Multidetector-row computed tomography of thoracic aortic anomalies in dogs and cats: patent ductus arteriosus and vascular rings.** *BMC Vet Res* 2011; 7: 57.
- Sekine Y, Yamamoto S, Fujikawa T, et al. **Surgical strategy for Kommerell's diverticulum with aberrant subclavian artery.** *Asian Cardiovasc Thorac Ann* 2015; 23: 418–422.
- Laflamme DP. **Development and validation of a body condition score system for cats: a clinical tool.** *Feline Pract* 1997; 25: 13–18.
- Tanaka A, Milner R and Ota T. **Kommerell's diverticulum in the current era: a comprehensive review.** *Gen Thorac Cardiovasc Surg* 2015; 63: 245–259.
- Türkvatan A, Büyükbayraktar FG, Olçer T, et al. **Multidetector computed tomographic angiography of aberrant subclavian arteries.** *Vasc Med* 2009; 14: 5–11.
- Donnelly LF, Fleck RJ, Pacharn P, et al. **Aberrant subclavian arteries: cross-sectional imaging findings in infants and children referred for evaluation of extrinsic airway compression.** *AJR Am J Roentgenol* 2002; 178: 1269–1274.
- Backer CL, Hillman N, Mavroudis C, et al. **Resection of Kommerell's diverticulum and left subclavian artery transfer for recurrent symptoms after vascular ring division.** *Eur J Cardiothorac Surg* 2002; 22: 64–69.
- Yang MH, Weng ZC, Weng YG, et al. **A right-sided aortic arch with Kommerell's diverticulum of the aberrant left subclavian artery presenting with syncope.** *J Chin Med Assoc* 2009; 72: 275–277.
- Loughin CA and Marino DJ. **Delayed primary surgical treatment in a dog with a persistent right aortic arch.** *J Am Anim Hosp Assoc* 2008; 44: 258–261.
- Muldoon MM, Birchard SJ and Ellison GW. **Long-term results of surgical correction of persistent right aortic arch in dogs: 25 cases (1980–1995).** *J Am Vet Med Assoc* 1997; 210: 1761–1763.
- Jeffrey SC, Bataller N and Martin RA. **The post-surgical nutritional management of megaesophagus secondary to persistent right aortic arch in a kitten.** *Feline Pract* 1995; 23: 17–23.