



## **Nasal adenocarcinoma as a suspected secondary malignant neoplasm in a cat previously treated for nasal lymphoma**

Authors: Callanan, Gabrielle F, Curran, Kaitlin M, Parachini-Winter, Cyril, Bracha, Shay, Spagnoli, Sean, et al.

Source: Journal of Feline Medicine and Surgery Open Reports, 6(1)

Published By: SAGE Publishing

URL: <https://doi.org/10.1177/2055116920908351>

---

BioOne Complete ([complete.BioOne.org](https://complete.BioOne.org)) is a full-text database of 200 subscribed and open-access titles in the biological, ecological, and environmental sciences published by nonprofit societies, associations, museums, institutions, and presses.

Your use of this PDF, the BioOne Complete website, and all posted and associated content indicates your acceptance of BioOne's Terms of Use, available at [www.bioone.org/terms-of-use](https://www.bioone.org/terms-of-use).

Usage of BioOne Complete content is strictly limited to personal, educational, and non - commercial use. Commercial inquiries or rights and permissions requests should be directed to the individual publisher as copyright holder.

---

BioOne sees sustainable scholarly publishing as an inherently collaborative enterprise connecting authors, nonprofit publishers, academic institutions, research libraries, and research funders in the common goal of maximizing access to critical research.



# Nasal adenocarcinoma as a suspected secondary malignant neoplasm in a cat previously treated for nasal lymphoma

*Journal of Feline Medicine and Surgery Open Reports*  
1–8

© The Author(s) 2020

Article reuse guidelines:

sagepub.com/journals-permissions

DOI: 10.1177/2055116920908351

journals.sagepub.com/home/jfmsopenreports

This paper was handled and processed by the American Editorial Office (AAFP) for publication in *JFMS Open Reports*



Gabrielle F Callanan<sup>1</sup> , Kaitlin M Curran<sup>1</sup>, Cyril Parachini-Winter<sup>1</sup>, Shay Bracha<sup>1</sup>, Sean Spagnoli<sup>2</sup>, Duncan S Russell<sup>2</sup>, Susanne M Stieger-Vanegas<sup>1</sup>, Lynn Griffin<sup>3</sup> and Haley Leeper<sup>1</sup>

## Abstract

**Case summary** A case of nasal adenocarcinoma as a suspected secondary malignant neoplasm following definitive radiation therapy and multiagent chemotherapy for nasal lymphoma is described. An 11-year-old spayed female domestic shorthair cat was presented for a 3-week history of progressive facial swelling located over the nasal planum and extending to the medial canthus of the right eye. The cat was previously diagnosed with nasal lymphoma and treated with chemotherapy and definitive radiation 2.5 years prior. Although a definitive diagnosis could not be obtained via cytology, recurrent lymphoma was suspected based on the cat's history and recurrent clinical signs. A lymphoma-directed chemotherapy protocol was attempted, but no clinical response was achieved. The cat was euthanased owing to progressive clinical signs and a diagnosis of nasal adenocarcinoma was made on necropsy examination. Both the original diagnosis of nasal lymphoma and the secondary diagnosis of nasal adenocarcinoma were confirmed with immunohistochemistry.

**Relevance and novel information** Secondary malignant neoplasm following radiation therapy is infrequently reported in the veterinary literature. In the few reports that exist, most have described sarcoma development in the dog following radiation therapy. In the present report, we describe a cat with a suspected radiation-induced nasal adenocarcinoma that developed 2.5 years after definitive radiation treatment for nasal lymphoma.

**Keywords:** Nasal; lymphoma; adenocarcinoma; secondary malignant neoplasm; radiotherapy; chemotherapy

**Accepted:** 30 January 2020

## Introduction

Ionizing radiation is a recognized carcinogen by the World Health Organization, contributing to genetic instability and cancer risk via formation of single- and double-stranded DNA breaks in irradiated cells.<sup>1–3</sup> While radiation therapy has therapeutic benefit in the treatment of a variety of cancers, secondary malignant neoplasm (SMN) is an unfortunate late risk of therapy.

The incidence of radiation-induced neoplasia in human patients is estimated to be <1% to 2%; however, the incidence in veterinary patients is unknown.<sup>4</sup> Few documented reports of SMN exist for veterinary species, and the majority of reported cases describe sarcoma development following radiation therapy in

dogs.<sup>5–10</sup> Epithelial SMNs appear less common and infrequent reports exist in both human and veterinary

<sup>1</sup>Department of Clinical Sciences, Carlson College of Veterinary Medicine, Oregon State University, Corvallis, OR, USA

<sup>2</sup>Department of Biomedical Sciences, Carlson College of Veterinary Medicine, Oregon State University, Corvallis, OR, USA

<sup>3</sup>College of Veterinary Medicine and Biomedical Sciences, Colorado State University, Fort Collins, CO, USA

### Corresponding author:

Gabrielle F Callanan DVM, Department of Clinical Sciences, Carlson College of Veterinary Medicine, Oregon State University, 172 Magruder Hall, Corvallis, OR 97331, USA  
Email: gabrielle.callanan@oregonstate.edu



Creative Commons Non Commercial CC BY-NC: This article is distributed under the terms of the Creative Commons

Attribution-NonCommercial 4.0 License (<https://creativecommons.org/licenses/by-nc/4.0/>) which permits non-commercial use, reproduction and distribution of the work without further permission provided the original work is attributed as specified on the SAGE and Open Access pages (<https://us.sagepub.com/en-us/nam/open-access-at-sage>).

literature.<sup>10,11</sup> Very few cases of radiation-induced tumors have been reported in cats, and to our knowledge there are no confirmed reports of radiation-induced adenocarcinomas following external beam radiation described in this species. In the present report, we describe a case of nasal adenocarcinoma as a suspected SMN in a cat following definitive radiation and multi-agent chemotherapy for nasal lymphoma.

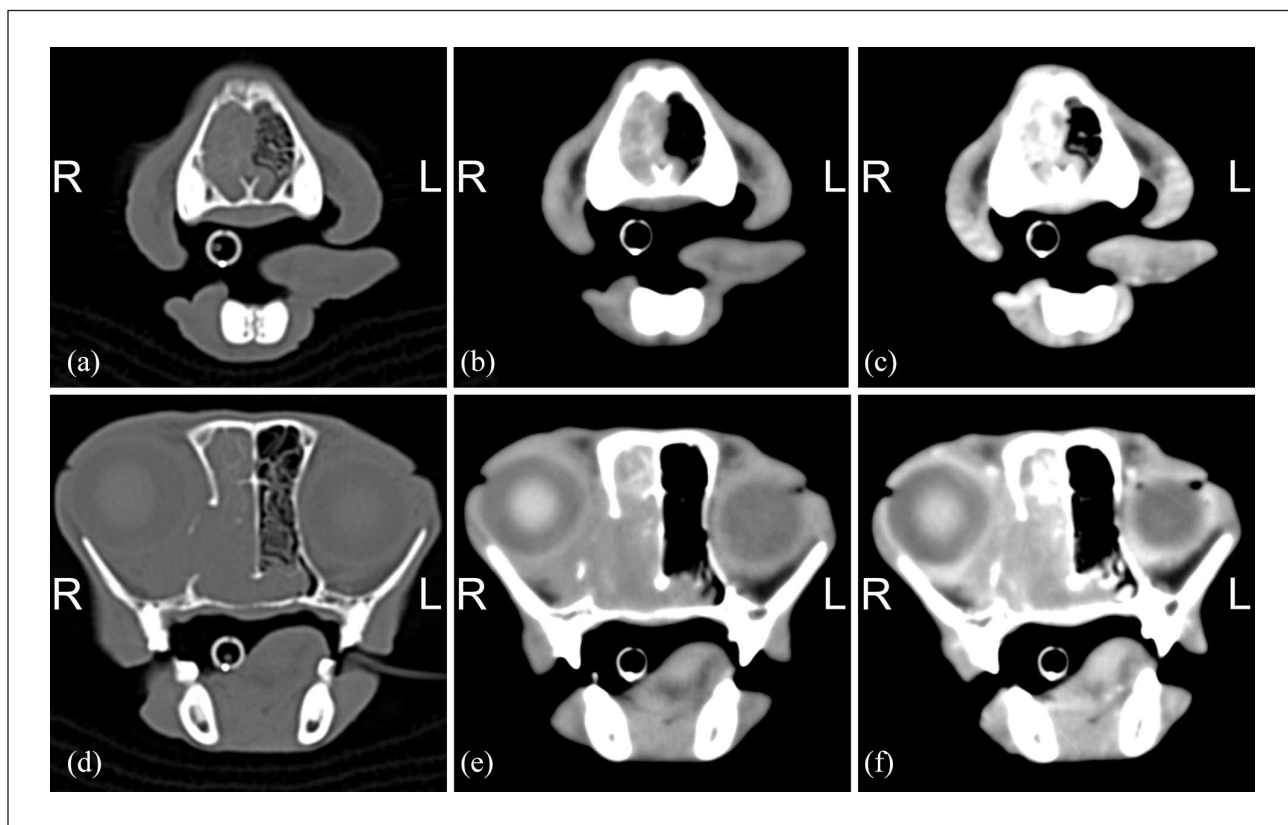
### Case description

An 11-year-old spayed female domestic shorthair cat was presented to Oregon State University Lois Bates Acheson Veterinary Teaching Hospital (OSU VTH) for evaluation of progressive facial swelling. The swelling had developed over 3 weeks and was located over the nasal planum and extended to the medial canthus of the right eye (OD). Previous medical history included diagnosis and treatment for nasal lymphoma 2.5 years prior. At that time, the cat was presented to OSU VTH for evaluation of

right-sided serous nasal discharge, sneezing and exophthalmos OD.

CT of the skull revealed a soft tissue-attenuating mass within the caudal right nasal cavity, extending from the roots of the upper canines to the nasopharynx and filling the right frontal sinus and retrobulbar space, causing exophthalmos OD (Figure 1). Lysis of the cribriform plate was detected without obvious intracranial extension by the mass. The mass was biopsied, and histopathology revealed monomorphic intermediate-sized lymphocytes, consistent with a diagnosis of lymphoma. Immunohistochemistry was not performed at the time of diagnosis. Additional staging, including abdominal and thoracic imaging and a bone marrow aspirate, was recommended but declined by the owner.

The cat's owner elected to move forward with definitive radiation therapy; however, owing to the patient's respiratory compromise from the tumor, chemotherapy was recommended prior to the initiation of radiation therapy. The patient was treated with a multi-drug protocol



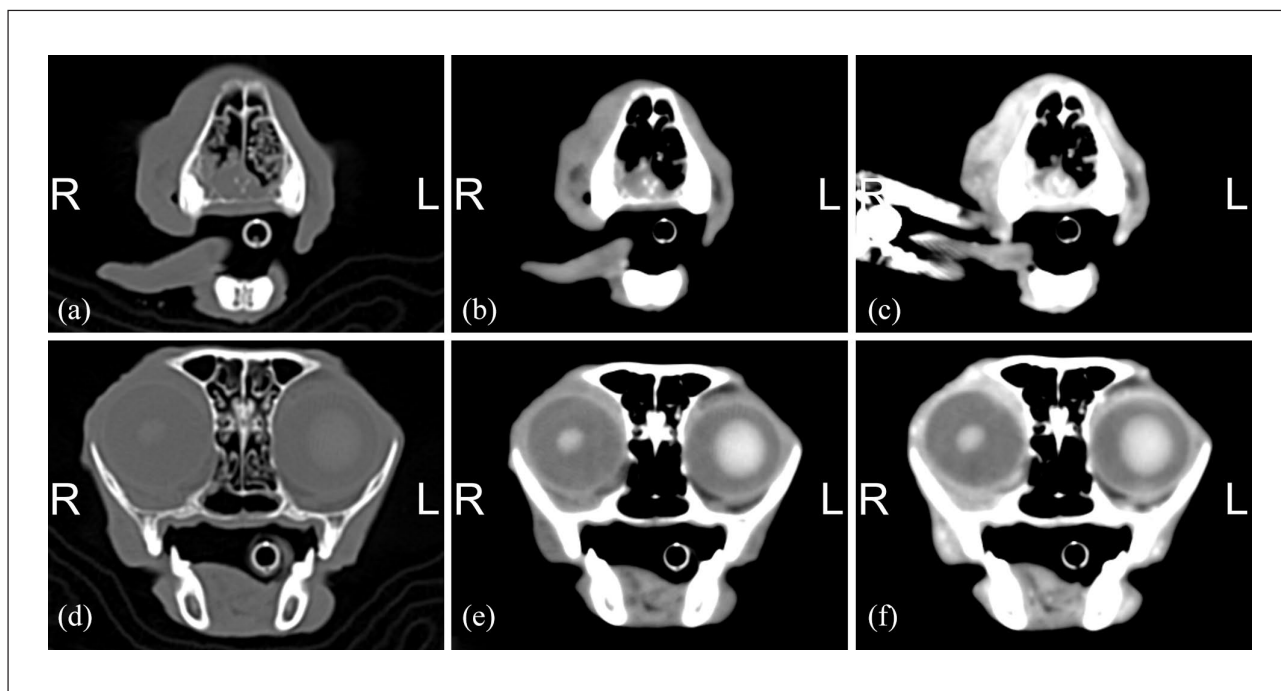
**Figure 1** Transverse CT images of the rostral aspect of the nose at (a–c) the level of the maxillary canine teeth and (d–f) the level of the orbit at initial presentation, with images (a) and (d) in a bone window (window width = 2700, window level = 350) and images (b) and (c) in a soft tissue window (window width = 320, window level = 30) setting. (e, f) Post-intravenous iodinated contrast agent administration in a soft tissue window setting. In the right nasal cavity, extending from (a–c) the maxillary canine teeth to the (d–f) rostral aspect of the nasopharynx and into the right frontal sinus is a large, moderately and heterogeneously contrast-enhancing soft tissue-attenuating mass, which causes moderate-to-severe lysis of the right-sided nasal turbinates and maxillary bone at the medial aspect of the right orbit. A moderate right-sided exophthalmos is noted. This right-sided severely destructive sinorhinopathy and mass was biopsied and diagnosed as lymphoma. R = right; L = left

with a typical cycle consisting of daily oral prednisolone (1mg/kg [PrednisTab; Lloyd]) for the duration of treatment, intravenous (IV) vincristine (0.45–0.5mg/m<sup>2</sup> [generic; Hospira]) on weeks 1 and 3, oral cyclophosphamide (200mg/m<sup>2</sup> [compounded; Northwest Compounding Pharmacy]) on week 2, IV cytosine arabinoside (100mg/m<sup>2</sup> [generic; Hospira]) on week 4 and no treatment on week 5 (COAP protocol).

Clinical signs resolved by week 6 of COAP therapy, after which further chemotherapy treatments were suspended until completion of the radiation therapy. Radiation therapy, consisting of 18 fractions of 3Gy, was delivered over 4 weeks (Monday–Friday) for a total dose of 54Gy. Further details of the radiation therapy plan were not available besides the prescription. The COAP protocol was resumed after completion of radiation therapy for a planned total of 19 weeks. Monthly physical examinations, as well as a recheck CT scan, were recommended following completion of therapy but were declined by the owner. The cat was reported to be symptom free until the onset of facial swelling approximately 2.5 years later, prompting veterinary evaluation.

At the time of re-presentation, additional abnormalities noted on physical examination included inspiratory stertor, decreased airflow from the right nostril, epiphora OD, elevated nictitating membrane of the left eye (OS), thin body condition, generalized muscle wasting and apparent pain on oral examination. No overt nasal discharge was noted and both eyes retracted normally. Initial diagnostic tests included a complete blood count (CBC), serum biochemical profile, urinalysis and CT of the skull.

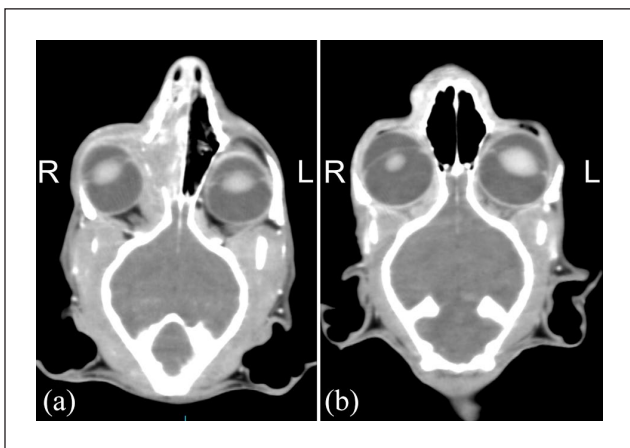
The CBC revealed a moderate leukocytosis (21,160 cells/ $\mu$ l: reference interval [RI] 5500–19,500 cells/ $\mu$ l) characterized by a mature neutrophilia (20,102 cells/ $\mu$ l: RI 2500–12,500 cells/ $\mu$ l), and a moderate microcytic, hypochromic non-regenerative anemia (packed cell volume [PCV] 21%: RI 30–45%). No clinically significant abnormalities were noted on serum biochemical profile and urinalysis. CT revealed a heterogeneously contrast-enhancing soft tissue mass extending from the right nostril into the ventrorostral aspect of the right nasal cavity. Extensive lysis of the incisive, nasal and maxillary bones, and multifocal lysis of the hard palate was apparent in the rostral aspect of the left and right nasal cavity (Figure 2).



**Figure 2** Transverse CT images of the rostral aspect of the nose at the (a–c) level of the maxillary canine teeth and (d–f) the level of the orbit approximately 2.5 years after initial presentation with images (a) and (d) in a bone window (window width = 2700, window level = 350) and (b) and (c) in a soft tissue window (window width = 320, window level = 30) setting. (e, f) Post-intravenous iodinated contrast agent administration in a soft tissue window setting. (a–c) The soft tissues along the right rostral aspect of the nose, predominately in the area of the nares and extending mildly into the most rostral aspect of the nasal cavity, are thickened and moderately heterogeneously contrast enhancing. Along the medial aspect of the right orbit, a small defect is noted in the right maxilla at the site of the previous destructive nasal mass 2.5 years prior; however, the previously noted right nasal cavity, nasopharyngeal and right retrobulbar mass is not identified in this study. The hyperattenuating aspect of the right lens is moderately decreased in size and irregular in margination, which was not noted in the initial CT and is thought to be secondary to radiation treatment. R = right; L = left

Compared with the initial CT evaluation 2.5 years prior, the margins of the right orbit appeared more continuous and well defined, the cribriform plate appeared intact, and the previously affected nasopharynx and right frontal sinus no longer contained a soft tissue mass (Figure 3). A percutaneous fine-needle aspirate of the new nasal mass was performed, and results of cytology were consistent with suppurative inflammation without an obvious underlying infectious etiology. Biopsy of the lesion for histopathological analysis, as well as abdominal and thoracic imaging were strongly recommended, but were declined by the owner. Lacking additional information, a presumptive diagnosis of relapsed nasal lymphoma was made based on patient history and recrudescence of similar clinical signs.

Treatment options for a presumed relapse of nasal lymphoma, including radiation therapy and chemotherapy, were discussed with the owner. Ultimately, it was elected to proceed with a similar COAP protocol as previously performed. Therapy included initial treatment with subcutaneous L-asparaginase (400 units/kg [compounded; KRS Global Compounding Pharmacy]), IV vincristine (0.45 mg/m<sup>2</sup> [generic; Hospira]) and oral cyclophosphamide (250 mg/m<sup>2</sup> [compounded; Northwest Compounding Pharmacy]).



**Figure 3** Dorsal CT images of the skull post-intravenous iodinated contrast agent administration in a soft tissue window setting (window width = 320, window level = 30). (a) At initial presentation, a heterogeneously contrast-enhancing mass (nasal lymphoma) is noted in the right nasal cavity extending into the right retrobulbar space. Lysis of the right maxillary bone along the medial aspect of the right orbit is noted. (b) At re-presentation, approximately 2.5 years after the initial presentation, a mild diffuse thickening and heterogeneous contrast enhancement of the soft tissues (suspected secondary malignant neoplasm, nasal adenocarcinoma) along the right aspect of the nose and face is noted. No mass is noted in the mid-to-caudal aspect of the right nasal cavity. The right eye is in a normal position. R = right; L = left

On presentation for the next scheduled treatment with vincristine (COAP week 3), the cat was reported to have a decreased appetite and activity level, and exhibited progressive facial swelling, hypersalivation and severe bilateral mucoid nasal discharge. Treatment with vincristine was postponed and additional diagnostics were pursued, including a CBC, serum biochemical profile, cryptococcal lateral flow antigen assay and CT of the skull.

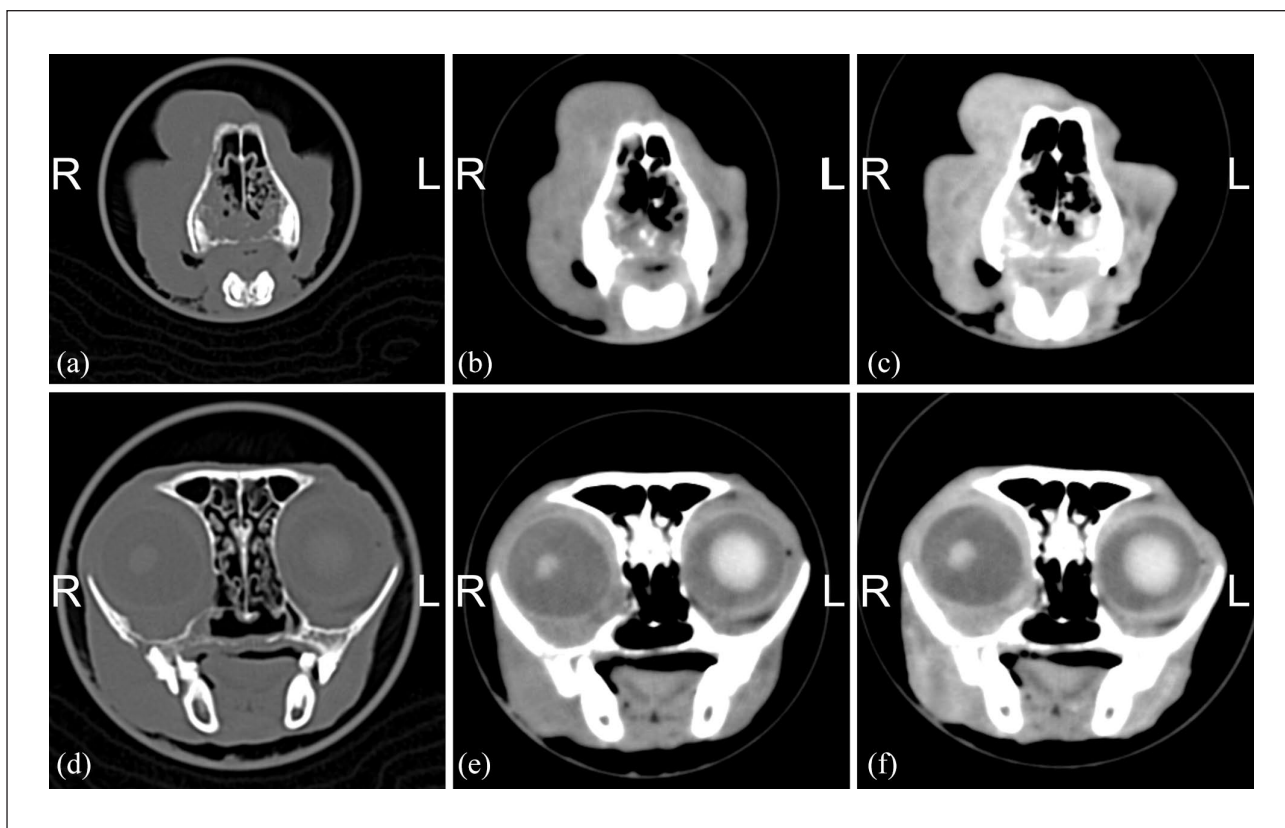
The CBC revealed a static moderate normocytic, normochromic non-regenerative anemia (PCV 22%; RI 30–45%) and a marked leukocytosis (55,930 cells/ $\mu$ l; RI 5500–19,500 cells/ $\mu$ l) characterized by a mature neutrophilia with mild toxicity (neutrophils 53,693 cells/ $\mu$ l; RI 2500–12,500 cells/ $\mu$ l). No clinically significant abnormalities were noted on serum biochemical profile. The cryptococcal lateral flow antigen assay was negative.

CT revealed progressive destructive rhinitis, enlargement of the previously documented nasal cavity mass and a progressive soft-tissue mass extending from the nasal cavity into the right orbit (Figure 4). Biopsy of the mass was again strongly encouraged but declined by the owner. The cat was hospitalized for supportive care with IV fluids, ampicillin/sulbactam (30 mg/kg IV q8h [Unasyn; Pfizer]), robenacoxib (2 mg/kg SC q24h [Onsior; Elanco]) and buprenorphine [0.02 mg/kg IV q8h [generic; Par Pharmaceutical]). Owing to the progression of clinical signs and a decline in quality of life, the owner elected humane euthanasia 4 days later.

Subsequent gross necropsy identified a firm swelling over the bridge of the nose. Upon incision of the underlying tissue, a solid, tan mass was apparent, which had effaced the right nasal bone and rostral right nasal turbinates. On histopathologic examination, the mass consisted of neoplastic cuboidal-to-polygonal epithelial cells containing round-to-ovoid nuclei and exhibiting moderate anisocytosis and anisokaryosis. Cuboidal cells were sometimes ciliated and arranged in nests and cords, forming tubules filled with mucinous material. There was no evidence of recrudescence of the previously diagnosed nasal lymphoma or evidence of neoplasia elsewhere in the body. Following necropsy, immunohistochemical staining of tissue sections from the original mass and new mass was performed with commercially available antibodies for pan T-lymphocyte marker CD3, B-cell antigen receptor CD79a and cytokeratin markers. Results confirmed the original diagnosis of nasal lymphoma and the final diagnosis of nasal adenocarcinoma (Figure 5).

## Discussion

Lymphoma is the most common nasal tumor in cats, followed by epithelial tumors, including adenocarcinoma and squamous cell carcinoma.<sup>12</sup> Radiation therapy is

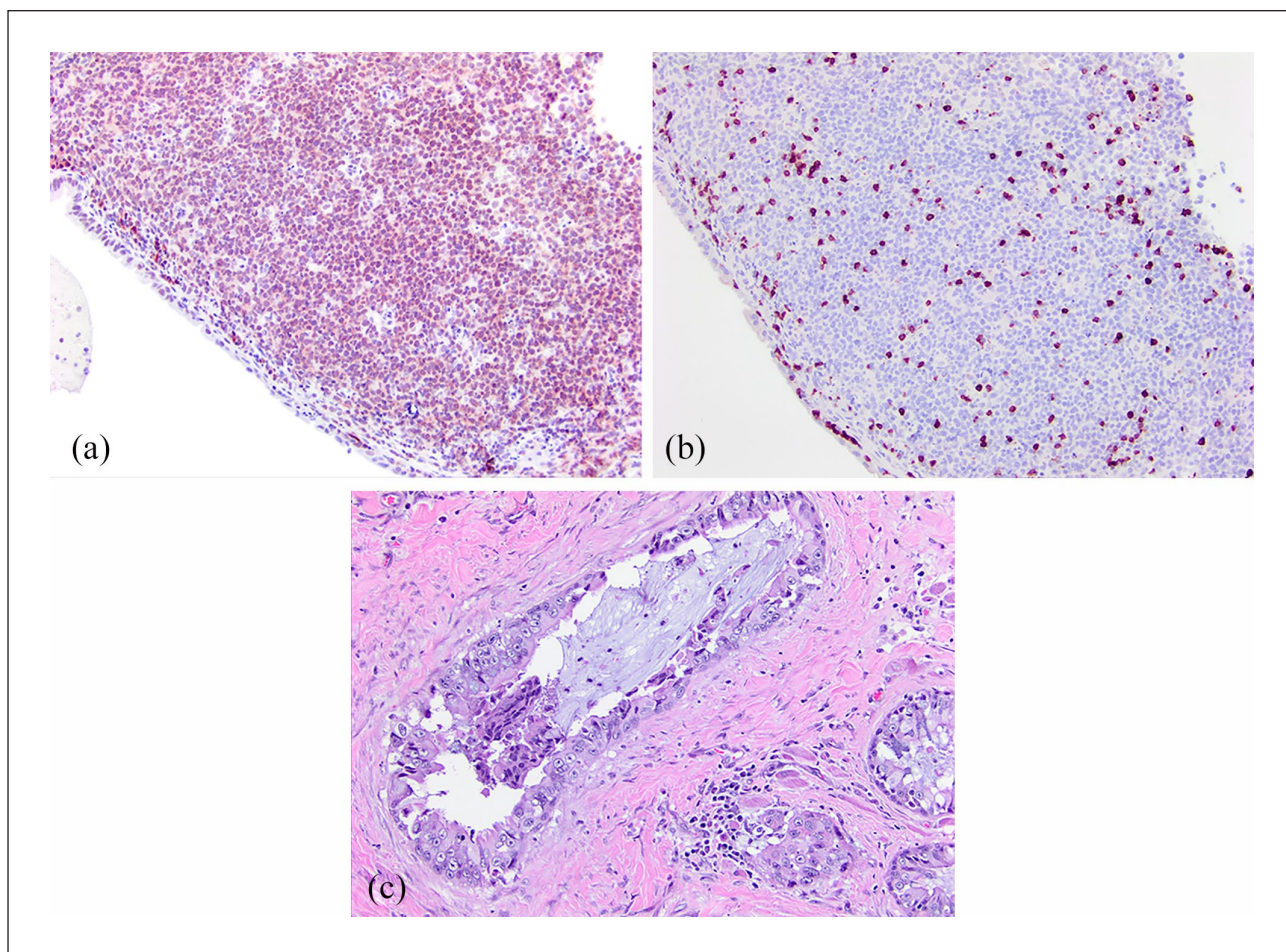


**Figure 4** Transverse CT images of the rostral aspect of the nose at the (a–c) level of the maxillary canine teeth and the (d–f) level of the orbit approximately 1 month after the second CT and re-presentation, with images (a) and (d) in a bone window (window width = 2700, window level = 350) and images (b) and (c) in a soft tissue window (window width = 320, window level = 30) setting. (e,f) Post-intravenous iodinated contrast agent administration in a soft tissue window setting. (a–c) Extending from the right nostril along the right lateral aspect of the face, there is moderately to severely progressive soft tissue thickening with heterogeneous contrast enhancement. Similar to mildly progressive compared with 1 month prior, soft tissue thickening is noted in the rostral aspect of the nasal cavity, mildly worse on right compared with the left side. (a,d) There is progressive lysis of the incisive, nasal, maxillary, palatine bones and right zygomatic process of the maxilla. (d,f) In the medial aspect of the right orbit, there is progressive, moderately heterogeneously contrast-enhancing soft tissue thickening that causes mild displacement of the right eye. The hyperattenuating aspect of the right lens is, similarly to the most recent CT, decreased in size and irregular in margination. R = right; L = left

generally regarded as the gold standard for treatment of nasal lymphoma and treated patients often enjoy long median survival times, with reports of 456 days with radiation alone and 174–955 days when combined with chemotherapy.<sup>13,14</sup> The cat in this report survived 1031 days following initial diagnosis of nasal lymphoma, consistent with other reports of extended survival times for nasal lymphoma treated with radiation and/or chemotherapy. While the therapeutic benefit of chemotherapy and radiation therapy for feline nasal lymphoma is generally well recognized, to our knowledge, the development of an adenocarcinoma as an SMN following treatment has not been previously documented in a cat.

Radiation-induced neoplasia is considered when the following criteria are met:<sup>15,16</sup> (1) tumor development within a previously irradiated field; (2) a latent period between previous irradiation and development of the

new tumor; (3) a different histopathologic diagnosis compared with the original irradiated tumor; and (4) documentation of previously normal tissue in the site of the new tumor development. This cat met the first three criteria for radiation-induced neoplasia and is suspected to have met the fourth criterion owing to complete resolution of clinical signs following therapy. However, imaging was not performed at the completion of radiation or chemotherapy to confirm normal tissue following treatment. Based on comparison of CT images, the nasal adenocarcinoma, located at the level of the right nostril and rostral to the previous mass, was not present at the time of initial lymphoma diagnosis. Additionally, the original diagnosis of nasal lymphoma and the secondary diagnosis of nasal adenocarcinoma were confirmed with immunohistochemistry, providing strength for the third criterion. The importance of using



**Figure 5** (a) Nasal lymphoma, CD79a immunohistochemistry ( $\times 200$ ). There is widespread CD79a immunoreactivity, indicating a B-cell phenotype. (b) Nasal lymphoma, CD3 immunohistochemistry ( $\times 200$ ). Small numbers of reactive CD3<sup>+</sup> cells (T cells) are present. (c) Nasal adenocarcinoma ( $\times 200$ ). Tumor cells are arranged into glandular profiles and solid nests, with mixed ciliated columnar and squamous morphologies

immunohistochemistry to correctly differentiate between feline nasal lymphoma and carcinoma was highlighted in a report by Nagata et al, in which 67% of original diagnoses disputed by pathologists were deemed incorrect following immunohistochemical staining.<sup>17</sup> Altogether, this case is most consistent with a radiation-induced neoplasia; however, other potential causes of a second malignancy include prior chemotherapy or chronic inflammation as a result of radiation or the previous tumor itself. Additionally, we cannot exclude the possibility that the second tumor arose spontaneously and was unrelated to prior treatment.

There is a paucity of information regarding SMN in cats, and current literature is limited to individual reports. In one report evaluating the late complications of hypofractionated radiation therapy in 65 cats with nasal tumors, one cat treated for nasal lymphoma was reported to have developed an osteochondroma of the maxilla 1267 days after the completion of therapy.<sup>18</sup>

While osteochondroma is considered a benign neoplasm, this case fits the current definition for radiation-induced neoplasia, which does not stipulate malignancy as part of the inclusion criteria.<sup>15,16</sup> No cats were reported to have developed an SMN at the previous irradiation site although the follow-up time in this study was not clear.<sup>18</sup> The development of a malignant neoplasm following hypofractionated radiation therapy for nasal lymphoma has been documented, including a recent case report describing the development of a radiation-induced sarcoma in a cat 69 months after radiotherapy.<sup>19</sup> In another report of 19 cats with nasal lymphoma treated with a combination of megavoltage radiation and chemotherapy, late side effects were reported to be rare, with no reports of radiation-induced neoplasia.<sup>13</sup> The median follow-up time in this study was 505 days and may not have been long enough to account for the prolonged latency period expected for secondary tumor formation. A recent report of 51 cats with nasal lymphoma treated

with radiation therapy described one cat that developed a nasal fibrosarcoma with lymph node metastasis 58 months after definitive radiation therapy.<sup>20</sup> Another report exists of a cat that underwent radiation therapy for treatment of a pituitary tumor and developed a pharyngeal squamous cell carcinoma in the radiation field 16 months after finishing radiotherapy. The normal tissue at this location was reported to have received a total dose between 27 and 49 Gy.<sup>21</sup>

More information exists regarding radiation-induced neoplasia in the dog, with most reports describing sarcoma development, particularly osteosarcoma and fibrosarcoma, although rare reports of epithelial SMN exist.<sup>5–10</sup> In a retrospective study of 119 dogs that received orthovoltage radiation to appendicular sites for the treatment of various tumor types, the authors reported 10 (8.4%) radiation-induced bone tumors with a median latency period of 4.6 years. All histologically confirmed tumors were sarcomas.<sup>5</sup> An older report of 39 dogs with acanthomatous epulis treated with orthovoltage radiation reported seven dogs (18%) that developed a second neoplasia at the site of the original tumor at a median time of 47 months after completion of radiation therapy. Interestingly, 5/7 were epithelial in origin (squamous cell carcinoma).<sup>9</sup> However, in a later report co-written by the same author, a retrospective study of 57 dogs irradiated for oral acanthomatous epulis, only two dogs (3.5%) developed SMNs, a sarcoma and an osteosarcoma, both of which occurred more than 5 years after radiation therapy. No secondary epithelial tumors were described in the more recent study and the authors concluded that the epithelial tumors described in the older report may not have been radiation-induced, but may represent an incorrect initial diagnosis or a radiation treatment failure.<sup>6</sup>

## Conclusion

To our knowledge, this is the first report to document an adenocarcinoma as a possible SMN in a cat following definitive radiation therapy for nasal lymphoma.

**Acknowledgements** The authors would like to thank Chelsey Lisiewski, Emily Moncrief and the OSU VTH intensive care unit staff for their expert patient care.

**Conflict of interest** The authors declared no potential conflicts of interest with respect to the research, authorship, and/or publication of this article.

**Funding** The authors received no financial support for the research, authorship, and/or publication of this article.

**Ethical approval** This work involved the use of non-experimental animals only (owned or unowned), and followed established internationally recognized high standards ('best practice') of individual veterinary clinical patient care. Ethical approval from a committee was not necessarily required.

**Informed consent** Informed consent (either verbal or written) was obtained from the owner or legal custodian of all

animal(s) described in this work for the procedure(s) undertaken. No animals or humans are identifiable within this publication, and therefore additional informed consent for publication was not required.

**ORCID iD** Gabrielle F Callanan  <https://orcid.org/0000-0001-9112-5084>

## References

- 1 World Health Organization. **Low doses of ionizing radiation increase risk of death from solid cancers.** International Agency for Research on Cancer. [https://www.iarc.fr/wp-content/uploads/2018/07/pr235\\_E.pdf](https://www.iarc.fr/wp-content/uploads/2018/07/pr235_E.pdf) (2015, accessed June 23, 2019).
- 2 UNSCEAR. **Effects of ionizing radiation.** Volume 2. Annex C. United Nations Office, Vienna. [https://www.unscear.org/docs/publications/2006/UNSCEAR\\_2006\\_Annex-C.pdf](https://www.unscear.org/docs/publications/2006/UNSCEAR_2006_Annex-C.pdf) (2006, accessed June 23, 2019).
- 3 Ward JF. **The yield of DNA double-strand breaks produced intracellularly by ionizing radiation: a review.** *Int J Radiat Biol* 1990; 57: 1141–1150.
- 4 Hall EJ and Wuu CS. **Radiation-induced second cancers: the impact of 3D-CRT and IMRT.** *Int J Radiat Biol Phys* 2003; 56: 83–88.
- 5 Hosoya K, Poulson JM and Azuma C. **Osteonecrosis and radiation induced bone tumors following orthovoltage radiation therapy in dogs.** *Vet Radiol Ultrasound* 2008; 49: 189–195.
- 6 McEntee MC, Page RL, Théon A, et al. **Malignant tumor formation in dogs previously irradiated for acanthomatous epulis.** *Vet Radiol Ultrasound* 2004; 45: 357–361.
- 7 Gillette SM, Gillette EL, Powers BE, et al. **Radiation-induced osteosarcoma in dogs after external beam or intraoperative radiation therapy.** *Cancer Res* 1990; 50: 54–57.
- 8 Thrall DE, Goldschmidt MH, Evans SM, et al. **Bone sarcoma following orthovoltage radiation in two dogs.** *Vet Rad* 1983; 24: 169–173.
- 9 Thrall DE. **Orthovoltage radiotherapy of acanthomatous epulides in 39 dogs.** *J Am Vet Med Assoc* 1984; 184: 826–829.
- 10 Théon AP, Rodriguez C and Madewell B. **Analysis of prognostic factors and patterns of failure in dogs with malignant oral tumors treated with megavoltage irradiation.** *J Am Vet Med Assoc* 1997; 210: 778–784.
- 11 Dörffel W, Riepenhausen M, Lüders H, et al. **Secondary malignancies following treatment for Hodgkin's lymphoma in childhood and adolescence.** *Dtsch Arztebl Int* 2015; 112: 320–327.
- 12 Mukaratirwa S, van der Linde-Sipman JS and Gruys E. **Feline nasal and paranasal sinus tumours: clinicopathological study, histomorphological description and diagnostic immunohistochemistry of 123 cases.** *J Feline Med Surg* 2001; 3: 235–245.
- 13 Sfiligoi G, Théon A and Kent M. **Response of nineteen cats with nasal lymphoma to radiation therapy and chemotherapy.** *Vet Radiol Ultrasound* 2007; 48: 388–393.
- 14 Haney SM, Beaver L, Turrel J, et al. **Survival analysis of 97 cats with nasal lymphoma: a multi-institutional retrospective study (1986–2006).** *J Vet Intern Med* 2009; 23: 287–294.
- 15 Cahan WG, Woodard H, Higinbotham NL, et al. **Sarcoma arising in irradiated bone: report of eleven cases.** *Cancer* 1948; 1: 3–29.



- 16 Arlen M, Higinbotham NL, Huvos AG, et al. **Radiation induced sarcoma of bone.** *Cancer* 1971; 28: 1087–1099.
- 17 Nagata K, Lamb M, Goldschmidt MH, et al. **The usefulness of immunohistochemistry to differentiate between nasal carcinoma and lymphoma in cats: 140 cases (1986–2000).** *Vet Comp Oncol* 2012; 12: 52–57.
- 18 Fujiwara-Igarashi A, Fujimori T, Oka M, et al. **Evaluation of outcomes and radiation complications in 65 cats with nasal tumours treated with palliative hypofractionated radiotherapy.** *Vet J* 2014; 202: 455–461.
- 19 Cook MR, Martinez MP, Fenger JM, et al. **Radiation-induced sarcoma in a cat following hypofractionated, palliative intent radiation therapy for large-cell lymphoma.** *JFMS Open Rep* 2019; 5. DOI: 10.1177/ 2055116919889159.
- 20 Meier VS, Beatrice L, Turek M, et al. **Outcome and failure patterns of localized sinonasal lymphoma in cats treated with first-line single-modality radiation therapy: a retrospective study.** *Vet Comp Oncol* 2019; 17: 528–536.
- 21 Mayer MN, Greco DS and LaRue SM. **Outcomes of pituitary tumor irradiation in cats.** *J Vet Intern Med* 2006; 20: 1151–1154.