

## **Second illness due to subsequent *Cytauxzoon felis* infection in a domestic cat**

Authors: Cohn, Leah A, Shaw, Dan, Shoemake, Catherine, and Birkenheuer, Adam J

Source: Journal of Feline Medicine and Surgery Open Reports, 6(1)

Published By: SAGE Publishing

URL: <https://doi.org/10.1177/2055116920908963>

---

The BioOne Digital Library (<https://bioone.org/>) provides worldwide distribution for more than 580 journals and eBooks from BioOne's community of over 150 nonprofit societies, research institutions, and university presses in the biological, ecological, and environmental sciences. The BioOne Digital Library encompasses the flagship aggregation BioOne Complete (<https://bioone.org/subscribe>), the BioOne Complete Archive (<https://bioone.org/archive>), and the BioOne eBooks program offerings ESA eBook Collection (<https://bioone.org/esa-ebooks>) and CSIRO Publishing BioSelect Collection (<https://bioone.org/csiro-ebooks>).

Your use of this PDF, the BioOne Digital Library, and all posted and associated content indicates your acceptance of BioOne's Terms of Use, available at [www.bioone.org/terms-of-use](http://www.bioone.org/terms-of-use).

Usage of BioOne Digital Library content is strictly limited to personal, educational, and non-commercial use. Commercial inquiries or rights and permissions requests should be directed to the individual publisher as copyright holder.

---

BioOne is an innovative nonprofit that sees sustainable scholarly publishing as an inherently collaborative enterprise connecting authors, nonprofit publishers, academic institutions, research libraries, and research funders in the common goal of maximizing access to critical research.



# Second illness due to subsequent *Cytauxzoon felis* infection in a domestic cat

Leah A Cohn<sup>1</sup> , Dan Shaw<sup>2</sup>, Catherine Shoemaker<sup>2</sup> and Adam J Birkenheuer<sup>3</sup>

Journal of Feline Medicine and Surgery Open Reports  
1–5

© The Author(s) 2020

Article reuse guidelines:

sagepub.com/journals-permissions

DOI: 10.1177/2055116920908963

journals.sagepub.com/home/jfmsopenreports

This paper was handled and processed by the American Editorial Office (AAFP) for publication in *JFMS Open Reports*



## Abstract

**Case summary** A castrated male domestic shorthair cat from a wooded area in Missouri had recovered from typical severe cytauxzoonosis at 4 years of age, after intensive in-hospital supportive care and administration of atovaquone and azithromycin. At 11 years of age, the same cat again experienced an acute febrile illness compatible with cytauxzoonosis. Intraerythrocytic piroplasms typical of *Cytauxzoon felis* were identified by cytology. The owners opted for euthanasia but allowed collection of splenic and hepatic tissue for histopathologic examination. Schizont-laden macrophages were identified in both tissue specimens, confirming active cytauxzoonosis at the time of the cat's death.

**Relevance and novel information** Although cats that have recovered from cytauxzoonosis can harbor red blood cell piroplasms for many years without apparent clinical illness, repeat illness owing to either disease recrudescence or repeat infection has never been documented. In fact, recovered cats have been thought to be resistant to reinfection and subsequent illness. This report describes a cat that had recovered from documented cytauxzoonosis 7 years previously and then developed a subsequent clinical illness typical of cytauxzoonosis, which was accompanied not only by intraerythrocytic piroplasms, but also by schizont-laden tissue macrophages pathognomonic of clinical cytauxzoonosis.

**Keywords:** Cytauxzoonosis; schizont; piroplasm; vector-borne disease

**Accepted:** 30 January 2020

## Introduction

*Cytauxzoon felis* is a hematozoan parasite of Felidae that leads to an often fatal infection in domestic cats. The dogma has been that cats which do recover from acute illness are resistant to repeat illness from either relapsed or repeat infection. This report describes a domestic cat that recovered from cytauxzoonosis after treatment with antiprotozoal therapy only, to develop a subsequent illness from cytauxzoonosis 7 years later.

## Case description

An 11-year-old castrated male domestic shorthair cat was presented to the emergency service of the University of Missouri Veterinary Health Center (MU-VHC) for anorexia, lethargy and an apparent seizure in May 2019. Approximately 1 week prior to presentation, the cat had a suspected altercation with an unidentified animal. The

owners cleaned a puncture wound to the neck and applied antibiotic ointment; the cat seemed relatively normal until 3 days prior to presentation.

<sup>1</sup>Department of Veterinary Medicine and Surgery, College of Veterinary Medicine, University of Missouri, Columbia, MO, USA

<sup>2</sup>Department of Pathobiology, College of Veterinary Medicine, University of Missouri, Columbia, MO, USA

<sup>3</sup>Vector Borne Disease Diagnostic Laboratory, Department of Clinical Science, College of Veterinary Medicine, North Carolina State University, Raleigh, NC, USA

### Corresponding author:

Leah A Cohn DVM, PhD, DACVIM (SAIM), Professor of Veterinary Medicine and Surgery, Department of Veterinary Medicine and Surgery, College of Veterinary Medicine, University of Missouri, 900 E Campus Dr, Columbia, MO 65211, USA  
Email: cohnla@missouri.edu



Creative Commons Non Commercial CC BY-NC: This article is distributed under the terms of the Creative Commons

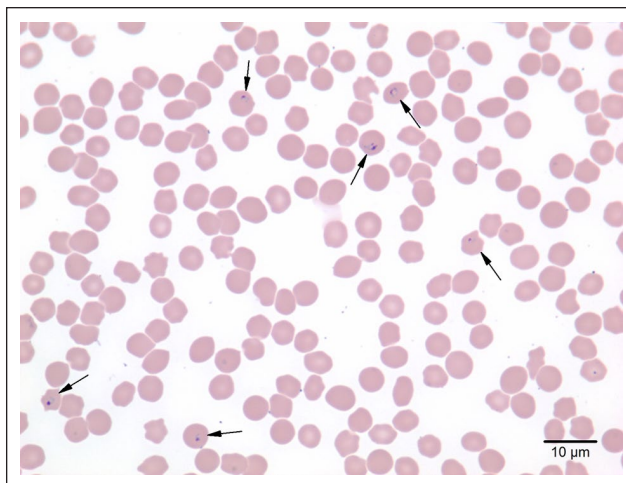
Attribution-NonCommercial 4.0 License (<https://creativecommons.org/licenses/by-nc/4.0/>) which permits non-commercial use, reproduction and distribution of the work without further permission provided the original work is attributed as specified on the SAGE and Open Access pages (<https://us.sagepub.com/en-us/nam/open-access-at-sage>).

Hyporexia prompted a visit to the primary care veterinarian, where there were no abnormalities on examination other than a temperature of 104°F (40°C). Point-of-care retroviral tests were negative, hematocrit was 40% and no parasites were identified on peripheral blood smear examination. The cat was discharged with pradofloxacin but re-presented the following day for complete anorexia and worsened lethargy. Fever was unchanged and mild icterus was now identified. A complete blood count (CBC) demonstrated a hematocrit of 31% with mild neutropenia ( $2.11 \times 10^3/\mu\text{l}$ ; reference interval [RI]  $2.5\text{--}12.5 \times 10^3/\mu\text{l}$ ) and platelet aggregates; no parasites were identified. Subcutaneous crystalloid fluids were administered, but the cat was not hospitalized. The following morning, the cat experienced what the owners described as a seizure, prompting the emergency visit to MU-VHC. The cat, which had survived cytauxzoonosis 7 years prior, lived on several wooded acres adjacent to Mark Twain National Forest in Cherryville, MO, USA, and was treated regularly with a combination product containing fipronil, etofenprox and (S)-methoprene (Frontline Tritak; Merial).

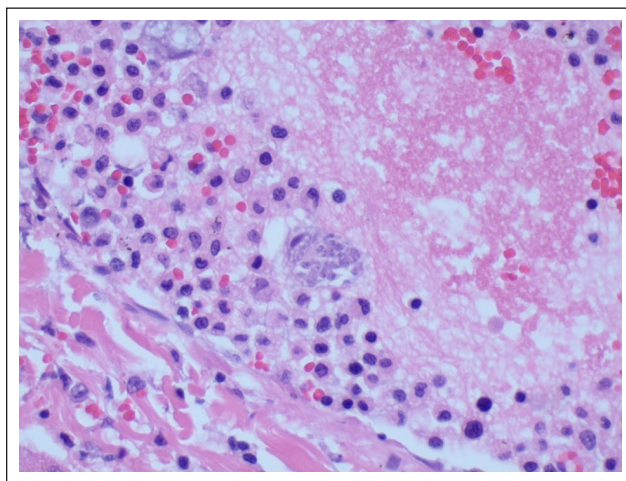
On presentation at MU-VHC, the cat's temperature was 104°F (40°C), pulse 180 beats per min, respiratory rate 24 breaths per min and was judged to be 6% dehydrated. There were no obvious wounds. Mucous membranes were pale and mildly icteric. Complete neurologic examination findings were not recorded, but the cat was reported to be dull and lethargic. Abnormalities on plasma chemistry profile included hyperglycemia (179 mg/dl; RI 80–155 mg/dl), hyponatremia (140 mEq/l; RI 148–154 mEq/l), hypochloremia (108 mEq/l; RI 112–123 mEq/l), hypokalemia (3.0 mEq/l; RI 3.1–4.6 mEq/l), hypocalcemia (8.4 mg/dl; RI 8.6–10.4 mg/dl) and hyperbilirubinemia (2.6 mg/dl; RI 0.1–0.2 mg/dl). Abnormalities on CBC included marked thrombocytopenia with few platelet clumps identified ( $10 \times 10^3/\mu\text{l}$ ; RI  $166\text{--}466 \times 10^3/\mu\text{l}$ ), neutropenia ( $1.82 \times 10^3/\mu\text{l}$ ; RI  $2.2\text{--}9.82 \times 10^3/\mu\text{l}$ ) and moderate numbers of intraerythrocytic signet ring-shaped inclusions compatible with *C felis* (Figure 1). Hematocrit was again 31%.

Based on a suspected diagnosis of cytauxzoonosis and the associated costs for treatment, the owners opted against specific therapy and took the cat home. After their cat experienced several additional seizures later that same day, they arranged for an at-home euthanasia. Based on our discussions about the unique nature of repeat cytauxzoonosis, the owners requested that the veterinarian performing euthanasia harvest a small sample of liver and spleen to be shipped in formalin to the MU Veterinary Medical Diagnostic Laboratory for confirmation of the suspected diagnosis.

On hematoxylin and eosin stain of prepared tissues, portal tracts were infiltrated by small numbers of lymphocytes, macrophages and plasma cells. Marked



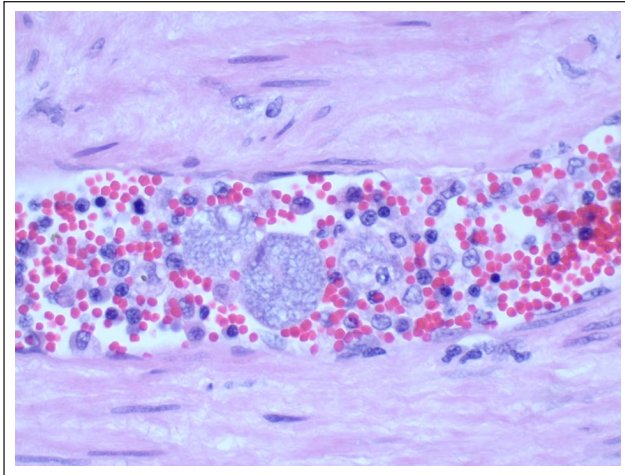
**Figure 1** Blood film from an 11-year-old castrated male domestic shorthair cat. Moderate numbers of erythrocytes contain 1–3  $\mu\text{m}$  signet ring-shaped piroplasms (arrows) consistent with *Cytauxzoon felis*. Wright-Giemsa stain  $\times 100$  objective



**Figure 2** Liver, hematoxylin and eosin stain at  $\times 400$  magnification. Mononuclear cells in a hepatic blood vessel contains merozoites of *Cytauxzoon felis*

lymphoid depletion of the splenic white pulp was noted. Mild extramedullary hematopoiesis was identified in the parenchyma of both the spleen and liver. Although modest in numbers, schizont structures typical of the protozoan *C felis* were recognized in hepatic arterioles and sinusoids, as well as in splenic sinusoids (Figures 2 and 3). Formalin-fixed paraffin-embedded tissues (from this case and a non-infected cat as a negative control) were sent to North Carolina State University for the molecular detection of *C felis*. Slides were heated to remove paraffin and total DNA was extracted. Partial *C felis* cytochrome oxidase C1, 18S rRNA and mitochondrial large ribosomal subunit-4 genes were amplified from the infected cat but





**Figure 3** Spleen hematoxylin and eosin stain at  $\times 400$  magnification. Mononuclear cells in a blood vessel of the spleen contain merozoites of *Cytauxzoon felis*

not the control (see supplementary material for methodologic detail).

In May of 2012, the same cat had been hospitalized at MU-VHC for treatment of acute cytauxzoonosis. Diagnosis was based on a typical presentation, including acute onset of anorexia and lethargy, high fever, pancytopenia, hyperbilirubinemia, hyperglycemia, panhypoproteinemias and multiple electrolyte abnormalities, as well as cytologic identification of numerous typical red blood cell (RBC) piroplasms. Engorged ticks were found on the cat at the time of diagnosis. Treatment included atovaquone and azithromycin, as well as intensive in-hospital supportive care, including multiple blood transfusions, thoracocentesis to relieve pleural effusion, and placement of an esophagostomy tube to facilitate feeding and medication administration. Despite a complicated clinical course, the cat was discharged after 9 days. It recovered completely, and a single CBC performed 2 weeks after hospital discharge failed to identify any parasites.

## Discussion

Cytauxzoonosis is an acute clinical illness caused by infection with the tick-transmitted hematoparasite pathogen, *C felis*.<sup>1</sup> The clinical illness is largely due to the schizogenous stage of infection when the tissue vasculature becomes occluded by mononuclear cells distended by replicating pathogens.<sup>2,3</sup> Recognition of schizonts in tissue macrophages is virtually pathognomonic of disease. Merozoites are released as the mononuclear cells rupture; piroplasms are formed when merozoites are taken up by erythrocytes. Erythrocytic piroplasms, which are not the primary cause of illness, may or may not be identifiable at the outset of illness.<sup>3</sup> Because RBC

piroplasms can persist indefinitely after recovery from illness, and in contrast to the identification of mononuclear schizonts, recognition of piroplasms demonstrates infection with *C felis* but does not confirm the illness cytauxzoonosis.<sup>4,5</sup>

The cat in this report was first diagnosed with cytauxzoonosis in 2012. The original diagnosis was based on a combination of typical, though non-specific, clinical signs (depression, anorexia, high fever, pallor and icterus), typical, though non-specific, laboratory abnormalities (pancytopenia, hyperbilirubinemia, hyperglycemia and electrolyte abnormalities) and demonstration of many intraerythrocytic piroplasms, and with the cat having documented tick infestation from an endemic area during May, the month of peak incidence.<sup>6</sup> Although the parasite was not confirmed to be *C felis* by molecular diagnostics, no other morphologically identical hematozoan parasites have been recognized in the USA.

The second illness, 7 years after the first, was similar in that it was a non-specific acute febrile disease accompanied by clinical signs and laboratory abnormalities typical of cytauxzoonosis. Parasites were not identified by the primary care veterinarian on the first day after onset of illness, but because illness corresponds to the schizogenous stage of infection that precedes the formation of piroplasms, as many as 50% of cats with cytauxzoonosis lack piroplasms at initial evaluation, but parasitized RBCs will become apparent over hours to days.<sup>1,3</sup> By the time the cat was evaluated at the MU-VHC, 36 h into the course of illness, numerous intraerythrocytic piroplasms were identified.

Neither the identification of piroplasms during the second illness nor the positive *C felis* PCR post mortem were considered adequate to confirm that the illness in 2019 was due to cytauxzoonosis, but the histopathologic findings were confirmatory. Cats recovered from acute infection may harbor piroplasms, usually at low numbers, indefinitely.<sup>4,7-9</sup> Even very few circulating piroplasms can result in a positive PCR reaction, thus confirming infection with *C felis* but not illness due to cytauxzoonosis.<sup>4,8,10</sup> Because piroplasms in RBCs cannot revert to schizonts in mononuclear cells, the recognition of schizonts in mononuclear cells on histologic examination of tissue from this cat confirmed active cytauxzoonosis at the time of its death.

Piroplasms were not identified by microscopy 2 weeks after hospital discharge in 2012, despite the fact that low-level piroplasm parasitemia is commonly identified in surviving cats long after infection.<sup>4,7-9</sup> We suspect the absence of visible piroplasms was likely related to treatment with atovaquone and azithromycin, a combination that has previously been demonstrated to result in a dramatically reduced parasite burden.<sup>11</sup> In a small study of naturally infected cats treated with atovaquone and azithromycin, piroplasms could not be identified

microscopically at 1, 6 or 8 weeks following treatment, and PCR in each cat was either negative or documented an extremely low parasite burden.<sup>11</sup> We cannot determine if the cat in this report maintained a low parasite burden after 2012 as only a single blood smear was performed between the first illness and the second, and PCR was never performed ante-mortem.

Recrudescence of illness after recovery from cytauxzoonosis has not been documented. The authors are aware of more than two dozen cats recovered from either naturally occurring or experimentally induced infection that have been followed for up to 8 years with no subsequent illness suggestive of cytauxzoonosis. Most clinical consequences of cytauxzoonosis are related to multiplication of schizonts within the mononuclear cells. Once schizogony is complete, it cannot begin again as a result of the same infection.<sup>12</sup> Despite low-level erythrocytic parasitemias being common in cats that recover from infection without atovaquone and azithromycin treatment, subsequent bouts of hemolysis after clinical recovery have not been documented.

Although second infections are theoretically possible, it has been largely believed that cats recovered from acute illness develop a protective immune response against *C felis*.<sup>13,14</sup> A small number of cats have proven resistant to experimental repeat infection.<sup>3,15,16</sup> Nevertheless, the authors have been contacted periodically by veterinarians presented with cats known to have survived prior infection that develop a similar illness from one to many years later. In at least several cases personally evaluated by the authors, an alternative explanation for the second febrile illness has been documented (eg, histoplasmosis, tularemia). Recently, a bobcat with chronic *C felis* infection was documented as being infected with a second strain of the pathogen, based on polymorphism at a nucleotide in internal transcribed spacer 1 (ITS1).<sup>17</sup> It seems plausible that the cat in the present report was reinfected with a somewhat different strain (ie, no heterologous immunity) in 2019 as compared with 2012, allowing for repeat clinical illness. It is also possible that protective immunity was present after acute infection for months or years, but eventually waned leading to renewed susceptibility. The cat in this report continued to roam outdoors in heavily wooded areas where tick exposure was likely. Although the owners regularly used a flea and tick control product, it was not of a type documented to prevent transmission of infection.<sup>18,19</sup>

## Conclusions

Repeat illness owing to cytauxzoonosis is possible. Cats that survive cytauxzoonosis should be rigorously protected from ticks, not only to prevent pathogen transmission to naive ticks that could then infect other Felidae,<sup>20,21</sup> but also to protect them from a potential second infection.

**Acknowledgements** The authors would like to thank Drs Melanie Swope and Connie Medling for their help in evaluation and sample collection from the cat in this study. We would like to also thank James Wilson, Brittany Thomas and Henry Marr for processing PCR samples.

**Supplementary material** The following file is available online: Supplementary methods and table.

**Conflict of interest** The authors declared no potential conflicts of interest with respect to the research, authorship, and/or publication of this article.

**Funding** The authors received no financial support for the research, authorship, and/or publication of this article.

**Ethical approval** This work involved the use of non-experimental animals only (including owned or unowned animals and data from prospective or retrospective studies). Established internationally recognised high standards ('best practice') of individual veterinary clinical patient care were followed. Ethical approval from a committee was therefore not necessarily required.

**Informed consent** Informed consent (either verbal or written) was obtained from the owner or legal custodian of all animal(s) described in this work for the procedure(s) undertaken. For any animals individually identifiable within this publication, informed consent for their use in the publication (verbal or written) was obtained from the people involved.

**ORCID iD** Leah A Cohn  <https://orcid.org/0000-0002-7785-2696>

## References

- Sherrill MK and Cohn LA. **Cytauxzoonosis: diagnosis and treatment of an emerging disease.** *J Feline Med Surg* 2015; 17: 940–948.
- Wagner JE, Ferris DH, Kier AB, et al. **Experimentally induced cytauxzoonosis-like disease in domestic cats.** *Vet Parasitol* 1980; 6: 305–311.
- Ferris DH. **A progress report on the status of a new disease of American cats: cytauxzoonosis.** *Comp Immun Microbiol Infect Dis* 1979; 1: 269–276.
- Meinkoth J, Kocan AA, Whitworth L, et al. **Cats surviving natural infection with *Cytauxzoon felis*: 18 cases (1997–1998).** *J Vet Intern Med* 2000; 14: 521–525.
- Lewis KM, Cohn LA, Marr HS, et al. **Diminazene diaceturate for treatment of chronic *Cytauxzoon felis* parasitemia in naturally infected cats.** *J Vet Intern Med* 2012; 26: 1490–1493.
- Reichard MV, Baum KA, Cadenhead SC, et al. **Temporal occurrence and environmental risk factors associated with cytauxzoonosis in domestic cats.** *Vet Parasitol* 2008; 152: 314–320.
- Lewis KM, Cohn LA, Downey M, et al. **Evaluation of *Cytauxzoon felis* infection status in captive-born wild felids housed in an area endemic for the pathogen.** *J Am Vet Med Assoc* 2012; 241: 1088–1092.

- 8 Brown HM, Latimer KS, Erikson LE, et al. **Detection of persistent *Cytauxzoon felis* infection by polymerase chain reaction in three asymptomatic domestic cats.** *J Vet Diag Invest* 2008; 20: 485–488.
- 9 Brown HM, Lockhart JM, Latimer KS, et al. **Identification and genetic characterization of *Cytauxzoon felis* in asymptomatic domestic cats and bobcats.** *Vet Parasitol* 2010; 172: 311–316.
- 10 Haber MD, Tucker MD, Marr HS, et al. **The detection of *Cytauxzoon felis* in apparently healthy free-roaming cats in the USA.** *Vet Parasitol* 2007; 146: 316–320.
- 11 Cohn LA, Birkenheuer AJ and Ratcliff E. **Comparison of two drug protocols for clearance of *Cytauxzoon felis* infections [abstract].** *J Vet Intern Med* 2008; 22: 704.
- 12 Jalovecka M, Hajdusek O and Sojka D. **The complexity of piroplasms life cycles.** *Front Cell Infect Microbiol* 2018; 8: 248. DOI: 10.3389/fcimb.2018.00248.
- 13 Schreeg ME, Marr HS, Tarigo JL, et al. **Identification of *Cytauxzoon felis* antigens via protein microarray and assessment of expression library immunization against cytauxzoonosis.** *Clin Proteomics* 2018; 15: 44. DOI: 10.1186/s12014-018-9218-9.
- 14 Tarigo JL, Scholl EH, Bird DM, et al. **A novel candidate vaccine for cytauxzoonosis inferred from comparative Apicomplexan genomics.** *PLoS One* 2013; 8: e71233. DOI: 10.1371/journal.pone.0071233.
- 15 Motzel SL and Wagner JE. **Treatment of experimentally induced cytauxzoonosis in cats with parvaquone and buparvaquone.** *Vet Parasitol* 1990; 35: 131–138.
- 16 Uilenberg G, Franssen FF and Perie NM. **Relationships between *Cytauxzoon felis* and African piroplasmids.** *Vet Parasitol* 1987; 26: 21–28.
- 17 Zieman EA, Nielsen CK and Jimenez FA. **Chronic *Cytauxzoon felis* infections in wild-caught bobcats (*Lynx rufus*).** *Vet Parasitol* 2018; 252: 67–69.
- 18 Reichard MV, Thomas JE, Arther RG, et al. **Efficacy of an Imidacloprid 10%/Flumethrin 4.5% collar (Seresto((R)), Bayer) for preventing the transmission of *Cytauxzoon felis* to domestic cats by *Amblyomma americanum*.** *Parasitol Res* 2013; 112 Suppl 1: 11–20.
- 19 Reichard MV, Rugg JJ, Thomas JE, et al. **Efficacy of a topical formulation of selamectin plus sarolaner against induced infestations of *Amblyomma americanum* on cats and prevention of *Cytauxzoon felis* transmission.** *Vet Parasitol* 2018; 270 Suppl 1: S31–S37.
- 20 Reichard MV, Meinkoth JH, Edwards AC, et al. **Transmission of *Cytauxzoon felis* to a domestic cat by *Amblyomma americanum*.** *Vet Parasitol* 2009; 161: 110–115.
- 21 Allen KE, Thomas JE, Wohltjen ML, et al. **Transmission of *Cytauxzoon felis* to domestic cats by *Amblyomma americanum* nymphs.** *Parasit Vectors* 2019; 12: 28. DOI: 10.1186/s13701-018-3276-8.