

Renal adenocarcinoma associated with hypertrophic osteopathy in a cat

Authors: Elhamiani Khatat, Sarah, Vallefuoco, Rosario, El Mrini, Meryem, Canonne-Guibert, Morgane, and Rosenberg, Dan

Source: Journal of Feline Medicine and Surgery Open Reports, 6(2)

Published By: SAGE Publishing


URL: <https://doi.org/10.1177/2055116920962433>

BioOne Complete (complete.BioOne.org) is a full-text database of 200 subscribed and open-access titles in the biological, ecological, and environmental sciences published by nonprofit societies, associations, museums, institutions, and presses.

Your use of this PDF, the BioOne Complete website, and all posted and associated content indicates your acceptance of BioOne's Terms of Use, available at www.bioone.org/terms-of-use.

Usage of BioOne Complete content is strictly limited to personal, educational, and non - commercial use. Commercial inquiries or rights and permissions requests should be directed to the individual publisher as copyright holder.

BioOne sees sustainable scholarly publishing as an inherently collaborative enterprise connecting authors, nonprofit publishers, academic institutions, research libraries, and research funders in the common goal of maximizing access to critical research.



Renal adenocarcinoma associated with hypertrophic osteopathy in a cat

Sarah Elhamiani Khatat¹, Rosario Vallefuoco²,
Meryem El Mrini³, Morgane Canonne-Guibert⁴
and Dan Rosenberg⁵

Journal of Feline Medicine and Surgery Open Reports
1–7

© The Author(s) 2020

Article reuse guidelines:

sagepub.com/journals-permissions

DOI: 10.1177/2055116920962433

journals.sagepub.com/home/jfmsopenreports

This paper was handled and processed
by the European Editorial Office (ISFM)
for publication in *JFMS Open Reports*



Abstract

Case summary A 10-year-old neutered male domestic shorthair cat was diagnosed with renal adenocarcinoma associated with hypertrophic osteopathy. The cat was referred for chronic ambulation difficulties. The physical examination showed a painful thickening of all four limbs, a right cranial abdominal mass and a conjunctival hyperaemia. Radiographic findings were consistent with extensive periosteal new bone formation involving not only the diaphyses of the fore- and hindlimbs, but also of the pelvis, tarsus and carpus. Abdominal ultrasonography and CT revealed a mass within the right kidney and a primary neoplasm was suspected. A ureteronephrectomy of the right kidney was performed and histopathology confirmed the diagnosis of renal adenocarcinoma. Although clinical improvement of the lameness occurred after surgery, no radiographic changes of hypertrophic osteopathy lesions were observed at the 9-month follow-up.

Relevance and novel information Feline cases of hypertrophic osteopathy are rarely reported in the literature and only a few of them were associated with abdominal neoplastic diseases. To our knowledge, this is the first case of renal adenocarcinoma associated with hypertrophic osteopathy in a cat.

Keywords: Hypertrophic osteopathy; renal adenocarcinoma; ureteronephrectomy

Accepted: 7 September 2020

Introduction

Hypertrophic osteopathy (HO) is characterised by periosteal bone proliferation involving the diaphyses of long bones and digits. The periosteal proliferation is mostly symmetrical but can be variable in appearance (nodular, speculated or palisade patterns). Clinically, HO is usually associated with painful and swollen limbs causing difficulty in ambulation or lameness.^{1–5} In some cases, inappetence or anorexia associated with weight loss are also described.^{1,4,6} HO is a rare syndrome already described in many species, including horses, cattle, wild animals, dogs, cats and humans.^{1–4,7–12} In dogs, it is usually associated with pulmonary or intrathoracic diseases, especially neoplasms, but granulomatous diseases (*Spirocerca lupi*), abscesses and endocarditis (bacterial, *Dirofilaria immitis*) are also described as inciting conditions.^{1–3,13,14} Some cases of canine HO have been associated with intra-abdominal neoplasms without any intrathoracic involvement.^{15–20} In

cats, only a few cases of HO have been previously published associated with intrathoracic, adrenal or renal

¹Department of Medicine, Surgery and Reproduction, Hassan II Institute of Agronomy and Veterinary Medicine, Rabat, Morocco

²Small Animal Surgery Department, Pride Veterinary Centre, Derby, UK

³Department of Animal Production, National Office of Sanitary Safety of Food Products, Rabat, Morocco

⁴Department of Small Animal Internal Medicine, University Hospital Center, National Veterinary School of Maisons-Alfort, University of Paris-Est Créteil, Val-de-Marne, France

⁵MICEN VET, Créteil, France

Corresponding author:

Sarah Elhamiani Khatat DVM, PhD, Department of Medicine, Surgery and Reproduction, Hassan II Institute of Agronomy and Veterinary Medicine, Madinat Al Irfane, BP 6202, Rabat – Instituts 10101, Morocco
Email: elhamianis@yahoo.fr



Creative Commons Non Commercial CC BY-NC: This article is distributed under the terms of the Creative Commons

Attribution-NonCommercial 4.0 License (<https://creativecommons.org/licenses/by-nc/4.0/>) which permits non-commercial use, reproduction and distribution of the work without further permission provided the original work is attributed as specified on the SAGE and Open Access pages (<https://us.sagepub.com/en-us/nam/open-access-at-sage>).

neoplastic diseases.^{1,3,6,7,21–26} This syndrome also has been described in association with megaesophagus, nutritional causes, congenital heart defect and with injection-site sarcoma in cats, and also idiopathic causes.^{2,4,5,27–30} Both prognosis and therapeutic management of HO depend on the underlying cause.⁷

Case description

A 10-year-old neutered male domestic shorthair cat (body weight 4.7 kg) was referred with several months' history of stiff and impaired gait and weight loss, which worsened in the month prior to admission. Nutraceuticals (Arthrosenior Chat; Laboratoires Clément Thékan) were previously prescribed by the referring veterinarian for suspected osteoarthritis of the hips. One capsule of the glucosamine–chondroitin supplement (glucosamine hydrochloride 50 mg, chondroitin sulfate 46 mg, ascorbic acid 15.6 mg) was administered q24h PO for 15 days without clinical improvement. The main abnormalities detected on physical and orthopaedic examination included hindlimb stiffness, reluctance to move and thickening of all four limbs (Figure 1). The range of motion of the stifles, hips, tarsi, carpi and elbows was also decreased, and manipulation of the long bones was painful. The cat also showed moderate bilateral

conjunctival hyperaemia. Abdominal palpation was not painful, but a firm mass was noted, in the right sublumbar fossa. The size of both kidneys was increased but asymmetrically, with the right kidney larger than the left one. Thoracic auscultation revealed a left-sided 3/6 apical systolic heart murmur.

Complete blood count abnormalities included mild leukocytosis (17.7×10^9 cells/l; reference interval [RI] 6.0–11.0 cells/l), neutrophilia (15.1×10^9 cells/l; RI 3.0–11.0 cells/l) and monocytosis (0.67×10^9 cells/l; RI 0.04–0.5 cells/l). Biochemistry parameters and the coagulation profile were within the RIs. Urine was collected via cystocentesis and urinalysis showed a specific gravity within the normal range (1.038), mild proteinuria and haematuria on dipstick, and no abnormalities on microscopic examination of the urinary sediment. Urine culture was negative 48 h after culture.

Radiographic examination of thoracic and pelvic limbs, abdomen and thorax was performed without sedation. Positioning of the cat was obtained with manual restraint, in accordance with the radiation safety regulations. Orthogonal radiographic views revealed extensive periosteal new bone formation involving the diaphysis of the radius, ulna, tibia and fibula, and metacarpal and metatarsal bones bilaterally but associated with soft tissue thickening of the extremities. There were also changes on the pelvis (ischium and ilium). The radiographic appearance of the periosteal proliferation was variable (brush-like on extremities, and thin and regular on long bones and pelvis) (Figure 2). Abdominal radiographs revealed an increased right kidney size (length 7.5–8 cm). Punctiform mineralisations were also observed in the projection area of the right kidney and were consistent with renal parenchymal calcification. Another calcification was identified dorsal to the bladder neck and ventral to the colon, consistent with a distal left ureterolith. No relevant radiographic abnormality was noted on thoracic radiographs; in particular, neither primary nor metastatic pulmonary tumours nor cardiomegaly were detected.

Abdominal ultrasound findings included moderately increased size (4.8 cm) of the left kidney with an irregular and hyperechoic edge, thickened cortical layer and decreased delimitation of the corticomedullary junction. Moderate pyelectasia was also noted without ureteral dilatation. A ureterolith was also observed in the distal part of the left ureter, as well as intraluminal hyperechoic particles in the bladder. The normal anatomical structure of the right kidney was lost as a result of an intraparenchymal, irregular heterogeneous and hypoechoic mass (6 × 4 cm) with irregular edges, almost totally effacing the normal architecture, compressing the renal pelvis and sparing only the caudal pole. An echocardiogram was performed to explore the left-sided apical systolic heart murmur and showed degenerative mitral valve disease without atrial enlargement.

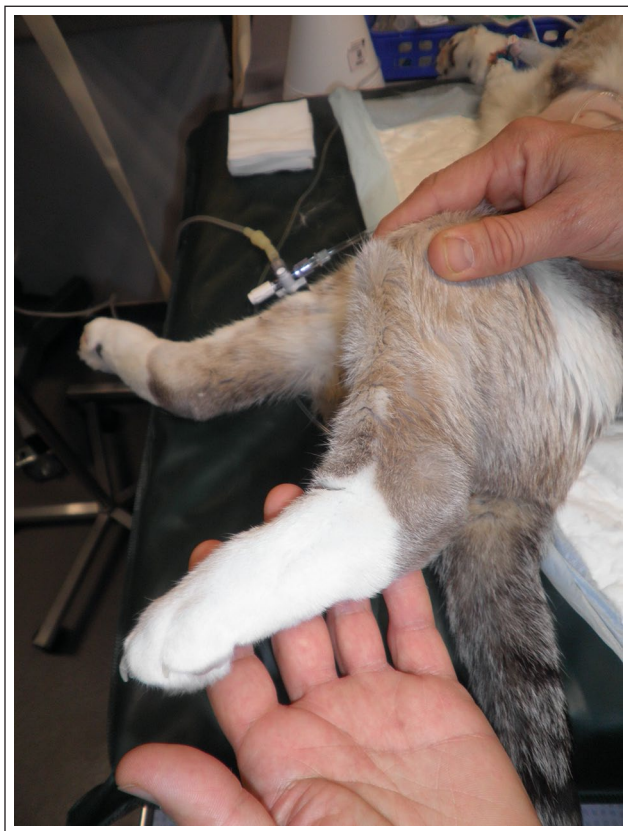

Figure 1 Thickening of the left hindlimb

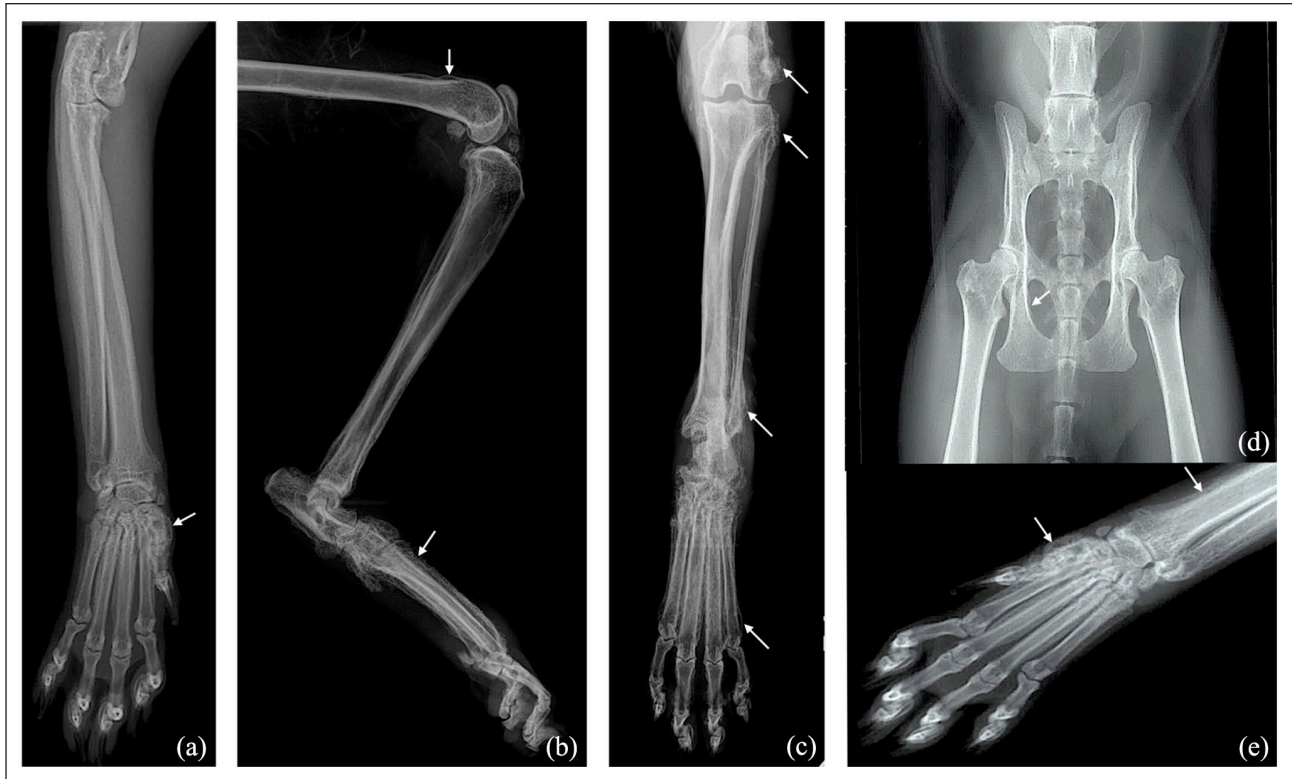

Figure 2 (a,b) Orthogonal radiographic views of the left hindlimb from the distal part of the femur to the extremity: note the thin and regular periosteal proliferation (arrows) on the diaphysis of the tibia and fibula, and palisade periosteal proliferation on the tarsal and metatarsal bones associated with severe thickening of the soft tissue. (c) Cranio-caudal radiographic view of the right forelimb from the elbow to the extremity: note the thin and regular periosteal proliferation (arrows) on the diaphysis of the radius and ulna and palisade periosteal proliferation on the metacarpal bones. (d) Ventro-dorsal radiographic view of the pelvis: note the smooth periosteal proliferation (arrow) on the lateral cortex of the right and left ilium and ischium, and on the medial cortex of the proximal right and left femurs. (e) Cranio-caudal radiographic view of the right carpus and metacarpal and phalangeal bones: note the palisade periosteal proliferation (arrows) on the metacarpal bones

A full body CT examination was performed under general anaesthesia to increase the sensitivity of detection of primary and metastatic tumours³¹ and to better define the renal lesion. The cat was premedicated with midazolam (Hypnovel; Roche) 0.2mg/kg IV and butorphanol (Torbugesic; Zoetis) 0.2mg/kg IV. General anaesthesia was induced with propofol (Rapinivet; Intervet) 5mg/kg IV to effect and maintained with isoflurane (Vetflurane; Virbac) administered with 100% oxygen. The CT examination confirmed subtotal invasion of the renal parenchyma by a tumour that displayed closed contact with the vena cava without invading it or the right adrenal gland (Figure 3). The CT scan also confirmed the presence of a ureterolith of 2.5mm in diameter located cranially to the left ureterovesical junction without signs of obstruction. There was no evidence of pulmonary metastasis, but a mild enlargement of the suprasternal lymph node was noted.

Ultrasound-guided biopsies of the right kidney mass using a Tru-Cut (18G needle) was performed on the following day under generalised anaesthesia with a standardised protocol combining diazepam (Valium;

Labora-toire Roche) 0.2mg/kg IV, propofol (Rapinivet; Intervet) 5mg/kg IV and isoflurane (Vetflurane; Virbac) administered in 100% oxygen. Fluid therapy (NaCl 0.9% [B Braun; Virbac]) and analgesia with morphine (Morphine Chlorhydrate; Renaudin) 0.3mg/kg IV q4h were provided. The patient was hospitalised during the day to be monitored for postbiopsy complications and an abdominal ultrasound was performed before discharge to rule out abdominal haemorrhage. Histological diagnosis was renal adenocarcinoma.

Surgical excision of the right renal tumour was then planned. Premedication was performed with methadone (Mephenon; Sterop) 0.2mg/kg IV and diazepam (Valium; Laboratoire Roche) 0.2mg/kg IV. General anaesthesia was induced with propofol (Rapinivet; Virbac) 5mg/kg IV to effect and maintained with sevoflurane (Sevoflurane Baxter; Baxter) administered in 100% oxygen. Intraoperative constant rate infusion (CRI) of fentanyl (Fentanul Mylan; Laboratoires Mylan) 2µg/kg/h and ketamine (Imalgene; Boehringer Ingelheim) 0.15mg/kg/h was administered for analgesia. The abdomen was approached through a midline celiotomy. Exploration of

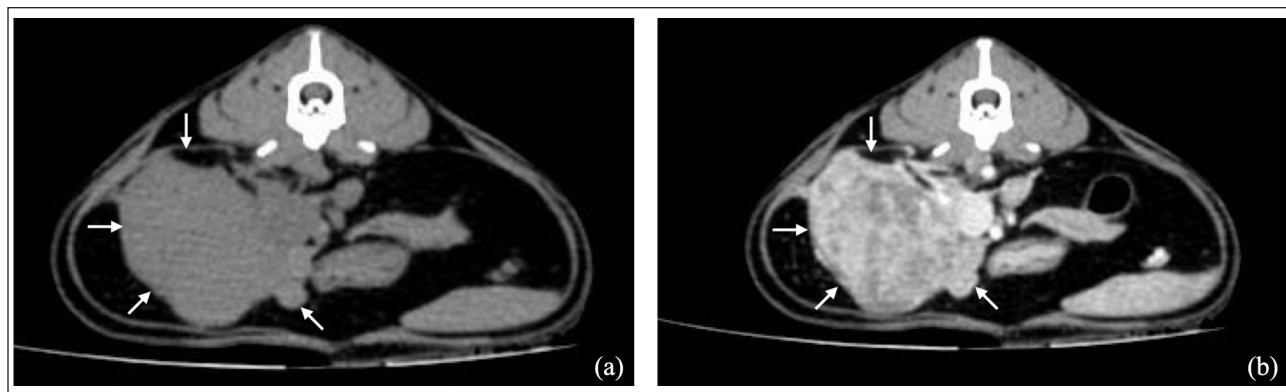


Figure 3 Transverse CT image of the abdomen in soft tissue window (a) before and (b) after intravenous contrast medium injection showing a large right renal mass distorting the normal anatomy of the kidney (arrows), with irregular shape, heterogeneous contrast enhancement and mass effect on the caudal vena cava

the abdominal cavity confirmed a voluminous mass deforming the right kidney, displaying a close contact and indistinguishable anatomical boundaries with the right adrenal gland and deviating the caudal vena cava towards the left. An en-bloc right ureteronephrectomy and right adrenalectomy was performed. The ligatures were placed around renal and phrenic-abdominal veins and arteries before setting up haemostatic clips on collateral vessels. A simple circumferential ligature (PDS 2.0) transfixing the bladder wall was placed in the most distal part of the right ureter leaving the smallest ureteral stump possible (Figure 4). The left ureter was not dilated and a gentle palpation was applied on the ureterolith in order to advance this into the bladder. All excised tissue was submitted to histological examination. This revealed a multilobulated neoplasm circumscribed by connective tissue forming a

capsule compatible with a renal adenocarcinoma associated with mild necrosis and rare lymphoplasmocytic infiltrates. No vascular embolism of neoplastic cells or ipsilateral adrenal gland infiltration were observed.

The cat recovered uneventfully from the anaesthesia and surgery, and intravenous fluid and analgesia were provided postoperatively. CRI of fentanyl (Fentanyl Mylan; Laboratoires Mylan) 2 µg/kg/h and ketamine (Imalgene; Boehringer Ingelheim) 0.15 mg/kg/h was continued 3 h after surgery and then replaced with morphine (Morphine Chlorhydrate Aguettant; Laboratoire Aguettant) 0.3 mg/kg q4h SC tapered to 0.1 mg/kg q4h SC on the following day. Renal parameters (urea, creatinine), packed cell volume, total proteins and serum albumin concentrations were monitored during the hospitalisation period. Transient anaemia

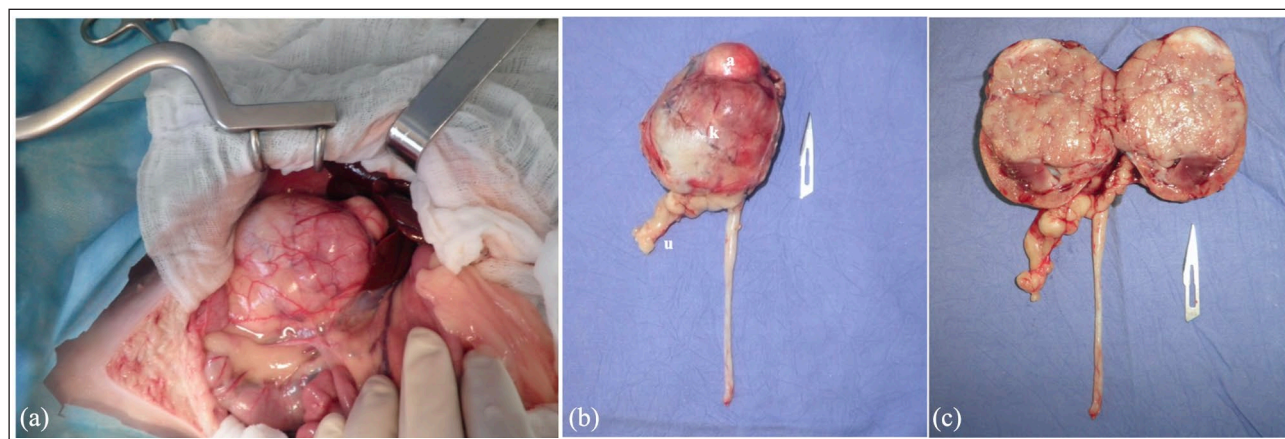


Figure 4 (a) Intraoperative image of the right renal mass before the surgical resection. (b) The en bloc excised renal mass and ureter (u) after the surgery: note the indistinguishable anatomical boundaries between the kidney (k) and adrenal gland (a). (c) The renal mass is sectioned along the long axis from the cranial to the caudal pole and from the lateral to the medial border: note the subtotal invasion of the renal parenchyma by the tumour, the remaining normal renal parenchyma and the absence of renal pelvis. The sectioned right adrenal gland is located on the craniomedial border of the kidney: there is no macroscopic invasion by the tumour

(erythrocytes 3.39×10^{12} cells/l [RI $6.54\text{--}12.20 \times 10^{12}$ cells/l]; haematocrit 15.4% [RI 30.3–52.3%]; haemoglobin 5.7g/l [RI 9.8–16.2g/l]) and hypoproteinaemia (48g/l; RI 57–89 g/l) were detected. They were thought to most likely be due to haemodilution or blood loss during the surgery as they showed complete resolution after a few days. Renal parameters remained within the normal RIs. Abdominal ultrasound was performed 3 days after surgery and no relevant abnormality was detected.

The cat was discharged 5 days postoperatively and was monitored at 2 weeks and 1, 2, 4, 5 and 9 months after surgery to follow renal function and the evolution of bone lesions. Clinical improvement was evident 2 weeks after surgery with an increase in physical activity and appetite. Conjunctival hyperaemia was also noted to have resolved. The thickening of all four limbs was decreased on palpation, and the lameness resolved at the 2- and 4-month follow-ups, respectively. Urinalysis performed at each postoperative assessment remained within the normal range and urine culture was still negative 1 month after surgery. Abdominal ultrasound was performed 1 month postoperatively and findings were similar to the immediate postoperative examination. Serum biochemistry, including urea, creatinine, albumin and total protein concentration, was performed at the 1-, 2- and 5-month follow-ups and was within the RIs. Persistent radiographic changes consistent with hypertrophic osteopathy were identified on radiographic survey of all four limbs performed at each follow-up. The cat was lost to follow-up after this time.

Discussion

Only 20 feline cases of HO are reported in the literature.^{1,2,4–7,21–30} Among them, nine were associated with neoplastic diseases, including intrathoracic neoplasia ($n = 5$),^{6,21,23–26} injection site sarcoma ($n = 1$),²⁷ adrenocortical carcinoma without pulmonary metastasis ($n = 1$)¹ and renal adenoma ($n = 2$).^{7,22} Only two previously reported feline cases were associated with renal tumours, and both were benign (papillary and tubular adenomas) without thoracic involvement.^{7,22}

The case reported here is therefore the first described feline case of HO associated with a malignant renal neoplasia. Primary renal tumours are rare in cats according to a retrospective study carried out in the USA between 1992 and 1998.³² During this period, only 19 cases have been diagnosed and the most frequent tumours were carcinomas (11 papillary and two tubulo-papillary types). None of these cases was associated with HO.³²

HO is a syndrome clinically characterised by pain and swelling of the limbs, and difficulty in ambulation or lameness; anorexia or decreased appetite associated with weight loss can also be observed.^{1–5} The case described here showed all of the above mentioned clinical and orthopaedic abnormalities.

The pathogenesis of periosteal proliferation is still not completely understood and seems to be multifactorial as suggested by several publications on human and canine HO.^{19,33} Hyperperfusion of appendicular tissue secondary to arterial vasodilatation and overgrowth of vascular connective tissue in the extremities is suspected to be the main mechanism leading to bone spicule formation.^{34–36} In humans, several humoral factors seemed to be incriminated in the pathogenesis, including vascular endothelial growth factor (VEGF), platelet-derived growth factor (PDGF) and inflammatory cytokines.^{36–38} It has been hypothesised that increased blood concentrations of VEGF and/or PDGF could induce fibrovascular proliferation, oedema and possible new periosteal bone formation.³⁹ Increased blood concentration of these two factors in human patients with HO secondary to lung tumours was detected in comparison with patients having pulmonary tumour without HO.³⁷ The production of humoral factors in human patients with paraneoplastic HO without intrathoracic lesions is also considered a likely hypothesis.⁴⁰ However, the neurogenic hypothesis suggests the presence of nervous reflex originating from the thoracic part of the vagus nerve causing stimulation of the blood circulation of the limbs.^{33,35,41} HO associated with extrapulmonary lesions is thought to follow the distribution of nasopharyngeal and vagus nerves that carry fibres innervating vascular tissues, which further strengthens the neuromuscular reflex theory.⁴² Finally, increased growth hormone, tissue hypoxia and circulating toxic products for synovial membranes and periosteum released from primary lesion are also possible mechanisms incriminated in the genesis of HO.^{35,36,43}

Another noticeable clinical sign observed in this case was the bilateral conjunctival hyperaemia. Ocular modifications have been described in two previous feline case reports with HO secondary to neoplasia.^{1,6} One case presented similar conjunctival hyperaemia with mucopurulent ocular discharge.⁶ The other feline case had vascular modifications in the posterior segment.¹ In both cases, as well in the present case, the ocular modifications resolved spontaneously after surgical removal of the tumour. The pathogenesis of ocular modification associated with HO remains unclear and speculative.^{1,6} It has been suggested that ocular signs could be secondary to systemic vasoactive modifications incriminated in the pathogenesis of HO or could represent a paraneoplastic syndrome.⁶ Two studies on canine HO including 30 dogs each have reported conjunctival hyperaemia and ocular discharge in 33% and 66%, respectively.^{44,45} However, conjunctival hyperaemia remains a non-specific ocular sign and could be related to other pathological conditions. In the cat described here, specific tests to rule out infectious or non-infectious conditions should have been performed. Thus, association remains speculative.

When a unilateral ureteronephrectomy is performed, it is crucial to be sure that the remaining kidney will be capable of sustaining the patient's life.⁴⁶ In our specific case a left ureterolith was present, but no further surgical procedure was elected for this. Because of the subtotal neoplastic invasion of the right kidney, it was assumed that the left kidney was functional, and preoperative normal serum creatinine concentration and urinalysis were not supportive of a major left kidney disease. Further, the left ureter patency was indirectly confirmed during the CT examination. Usual filtration and excretion of the intravenous contrast medium by the left kidney and through the left ureter lead the authors to speculate that the left ureterolith was not obstructive. Postoperative ultrasound and serum biochemistry assessments confirmed the dislodgement of the ureterolith in the bladder and the normal function of the remaining left kidney.

Both prognosis and therapeutic management of HO depend on the underlying cause.⁷ In several studies, curative treatment of underlying causes led to complete regression of this syndrome. Indeed, surgical removal of tumours, modification of food or management of the megaesophagus led to complete regression of HO in 15 weeks to 24 months.^{1,4-6} The cat in the present report displayed orthopaedic clinical improvement after surgical excision of the renal carcinoma while radiographic lesions of HO were still present 9 months after the surgery. The persistence of radiographic lesions could be due to a short-term follow-up or, perhaps, to other additional underlying causes or unidentified metastasis. These hypotheses are considered less likely by the authors owing to the overall clinical improvement of the cat. Several case reports have described a complete regression of paraneoplastic HO between 12 and 24 months after surgical removal of the underlying neoplasia in dogs.^{13,18-20} In two of these cases, HO was secondary to a renal carcinoma.^{18,19} However, of four recent feline cases of HO associated with malignant neoplastic disease, one was euthanased,²⁷ one died 2 months after the surgical removal of the tumour secondary to disseminated metastasis,²¹ and two had significant radiographic improvement of the HO 4 and 6 months after the surgery.^{1,6} It is therefore difficult to draw a definite conclusion about the radiographic evolution in the cat and the limited number of cases make the comparison even more challenging.

Conclusions

To our knowledge, this is the first case of renal adenocarcinoma associated with HO in a cat. Despite complete surgical excision and absence of macroscopic metastasis, persistence of the radiographic lesions was noted until the 9-month follow-up. Further radiographic follow-up would have been interesting in this case to monitor the

evolution of the periosteal bone proliferation. This case is also the third description of feline HO possibly associated with ocular abnormalities and the second case of conjunctival hyperaemia. A possible relationship between the two entities remains to be investigated.

Acknowledgements We would like to thank the students, veterinarians and nurses who contributed to the diagnosis and treatment of the cat described in this case report.

Conflict of interest The authors declared no potential conflicts of interest with respect to the research, authorship, and/or publication of this article.

Funding The authors received no financial support for the research, authorship, and/or publication of this article.

Ethical approval This work involved the use of non-experimental animals only (including owned or unowned animals and data from prospective or retrospective studies). Established internationally recognised high standards ('best practice') of individual veterinary clinical patient care were followed. Ethical approval from a committee was therefore not necessarily required.

Informed consent Informed consent (either verbal or written) was obtained from the owner or legal custodian of animal(s) described in this work (either experimental or non-experimental animals) for the procedure(s) undertaken (either prospective or retrospective studies). No animals or humans are identifiable within this publication, and therefore additional informed consent for publication was not required.

References

- 1 Becker TJ, Perry RL and Watson GL. **Regression of hypertrophic osteopathy in a cat after surgical excision of an adrenocortical carcinoma.** *J Am Anim Hosp Assoc* 1999; 35: 499–505.
- 2 de Melo Ocarino N, Fukushima FB, de Matos Gomes A, et al. **Idiopathic hypertrophic osteopathy in a cat.** *J Feline Med Surg* 2007; 8: 345–348.
- 3 Chiang YC1, Liu CH, Ho SY, et al. **Hypertrophic osteopathy associated with disseminated metastases of renal cell carcinoma in the dog: a case report.** *J Vet Med Sci* 2007; 69: 209–212.
- 4 Huang CH, Jeng CR, Lin CT, et al. **Feline hypertrophic osteopathy: a collection of seven cases in Taiwan.** *J Am Anim Hosp Assoc* 2010; 46: 346–352.
- 5 Mills J. **Hypertrophic osteopathy and megaesophagus in a cat.** *Vet Comp Orthop Traumatol* 2010; 23: 218–222.
- 6 Grierson JM, Burton CA and Brearley MJ. **Hypertrophic osteopathy secondary to pulmonary sarcoma in a cat.** *Vet Comp Oncol* 2003; 1: 227–231.
- 7 Johnson RL and Lenz SD. **Hypertrophic osteopathy associated with a renal adenoma in a cat.** *J Vet Diag Invest* 2011; 23: 171–175.
- 8 Mair TS, Dyson SJ, Fraser JA, et al. **Hypertrophic osteopathy (Marie's disease) in Equidae: a review of twenty-four cases.** *Equine Vet J* 1996; 28: 256–262.

- 9 Merritt AM, Dodd DC, Reid CF, et al. **Hypertrophic pulmonary osteopathy in a steer.** *J Am Vet Med Assoc* 1971; 159: 443–448.
- 10 von Bamberger E. **Veränderungen der röhrenknochen bei bronchiektasie.** *Wien Klin Wochenschr* 1889; 226–240.
- 11 von Bamberger E. **Über knochenveränderungen bei chronischen lungen- und herz-krankheiten.** *Z Klin Med* 1991; 18: 19.
- 12 Marie P. **De l'osteo-arthropathie hypertrophiante pneumonique.** *Rev Med Paris* 1890; 10: 1–36.
- 13 Hara Y, Tagawa M, Ejima H, et al. **Regression of hypertrophic osteopathy following removal of intrathoracic neoplasia derived from vagus nerve in a dog.** *J Vet Med Sci* 1995; 57: 133–135.
- 14 Anderson TP, Walker MC and Goring RL. **Cardiogenic hypertrophic osteopathy in a dog with a right-to-left shunting patent ductus arteriosus.** *J Am Vet Med Assoc* 2004; 224: 1464–1466.
- 15 Halliwell WH and Ackerman N. **Botryoid rhabdomyosarcoma of the urinary bladder and hypertrophic osteoarthropathy in a young dog.** *J Am Vet Med Assoc* 1974; 165: 911–913.
- 16 Caywood DD, Osborne CA, Stevens JB, et al. **Hypertrophic osteoarthropathy associated with an atypical nephroblastoma in a dog.** *J Am Anim Hosp Assoc* 1980; 16: 855–865.
- 17 Rendano VT and Slauson DO. **Hypertrophic osteopathy in a dog with prostatic adenocarcinoma and without thoracic metastasis.** *J Am Anim Hosp Assoc* 1982; 18: 905–909.
- 18 Peeters D, Clercx C, Thiry A, et al. **Resolution of paraneoplastic leukocytosis and hypertrophic osteopathy after resection of a renal transitional cell carcinoma producing granulocyte-macrophage colony-stimulating factor in a young Bull Terrier.** *J Vet Intern Med* 2001; 15: 407–411.
- 19 Grillo TP, Brandão CVS, Mamprim MJ, et al. **Hypertrophic osteopathy associated with renal pelvis transitional cell carcinoma in a dog.** *Can Vet J* 2007; 48: 745–747.
- 20 Randall VD, Souza C, Vanderhart D, et al. **Hypertrophic osteopathy associated with hepatocellular carcinoma in a dog.** *Can Vet J* 2015; 56: 741–744.
- 21 Gram WD, Wheaton LG, Snyder PW, et al. **Feline hypertrophic osteopathy associated with pulmonary carcinoma.** *J Am Anim Hosp Assoc* 1990; 26: 425–428.
- 22 Nafe LA, Herron AJ and Burk RL. **Hypertrophic osteopathy in a cat associated with renal papillary adenoma.** *J Am Anim Hosp Assoc* 1981; 17: 659–662.
- 23 Richards CD. **Hypertrophic osteoarthropathy in a cat.** *Feline Pract* 1977; 7: 41–43.
- 24 Roberg J. **Hypertrophic pulmonary osteoarthropathy.** *Feline Pract* 1977; 7: 18–22.
- 25 Carr SH. **Secondary hypertrophic pulmonary osteoarthropathy in a cat.** *Feline Pract* 1971; 1: 25–26.
- 26 Rohr S. **Pulmonary origin feline hypertrophic osteopathy.** *Point Vet* 2003; 34: 62–64.
- 27 Salgüero R, Demetriou J, Constantino-Casas F, et al. **Hypertrophic osteopathy in a cat with a concurrent injection-site sarcoma.** *JFMS Open Rep* 2015; 1: DOI.10.1177/2055116915593968.
- 28 Foster SF. **Idiopathic hypertrophic osteopathy in a cat.** *J Feline Med Surg* 2007; 9: 172–173.
- 29 de Castro Guizelini C, Mattei RR, Pupin RC, et al. **Osteopatia hipertrófica idiopática em um gato.** *Acta Sc Vet* 2019; 47 Suppl 1: 373.
- 30 de Soussa FAB, Bianchi MV, Taunde PA, et al. **Hypertrophic osteopathy in a cat with cardiac interventricular septal defect.** *J Vet Sci* 2019; 20: e52. DOI: 10.4142/jvs.2019.20.e52.
- 31 Armbrust LJ, Biller DS, Bamford A, et al. **Comparison of three-view thoracic radiography and computed tomography for detection of pulmonary nodules in dogs with neoplasia.** *J Am Vet Med Assoc* 2012; 240: 1088–1094.
- 32 Henry CJ, Turnquist SE, Smith A, et al. **Primary renal tumours in cats: 19 cases (1992–1998).** *J Feline Med Surg* 1999; 1: 165–170.
- 33 Watson AD and Porges WL. **Regression of hypertrophic osteopathy in a dog following unilateral intrathoracic vagotomy.** *Vet Rec* 1973; 93: 240–243.
- 34 Ginsburg. **Observation on the peripheral circulation of hypertrophic pulmonary osteopathy.** *Q J Med* 1958; 107: 335–352.
- 35 Lenehan TM and Fetter AW. **Hypertrophic osteopathy.** In: Newton CD and Nunamaker DM (eds). *Textbook of small animal orthopedics*. Philadelphia, PA: Lippincott William & Wilkins, 1985, pp 603–609.
- 36 Dickinson CJ and Martin JF. **Megakaryocytes and platelet clumps as the cause of finger clubbing.** *Lancet* 1987; 2: 1434–1435.
- 37 Silveira LH, Martinez-Lanvin M, Pineda C, et al. **Vascular endothelial growth factor and hypertrophic osteopathy.** *Clin Exp Rheumatol* 2000; 18: 57–62.
- 38 Shih WJ. **Pulmonary hypertrophic osteoarthropathy and its resolution.** *Semin Nucl Med* 2004; 34: 159–163.
- 39 Atkinson S and Fox SB. **Vascular endothelial growth factor (VEGF)-A and platelet-derived growth factor (PDGF) play a central role in the pathogenesis of digital clubbing.** *J Pathol* 2004; 203: 721–728.
- 40 Manuel ML. **Exploring the cause of the most ancient clinical sign of medicine: finger clubbing.** *Semin Arthritis Rheum* 2007; 36: 380–385.
- 41 Flavell G. **Reversal of pulmonary hypertrophic osteopathy by vagotomy.** *Lancet* 1956; 270: 260–262.
- 42 Cetinkaya CA, Yardimci B and Yardimci C. **Hypertrophic osteopathy in a dog associated with intra-thoracic lesions: a case report and a review.** *Vet Med-Czech* 2011; 56: 595–601.
- 43 Greenberg PB, Beck C, Martin TJ, et al. **Synthesis and release of human growth hormone from lung carcinoma in cell culture.** *Lancet* 1972; 12: 350–352.
- 44 Withers SS, Johnson EG, Culp WTN, et al. **Paraneoplastic hypertrophic osteopathy in 30 dogs.** *Vet Comp Oncol* 2015; 13: 157–165.
- 45 Salvusarenko M, Peeri D, Bibring U, et al. **Hypertrophic osteopathy: a retrospective case control study of 30 dogs.** *Isr J Vet Med* 2015; 68: 209–217.
- 46 Toboas KM and Tillson DM. **Kidneys.** In: Jonhston SA and Tobias KM (eds). *Veterinary surgery small animals*. 2nd ed. St Louis, MO: Elsevier, 2018, pp 2184–2201.