



Nasopharyngeal cryptococcosis in a cat: interlaboratory variation in cryptococcal antigen assay test results

Authors: McEwan, Stephanie A, and Sykes, Jane E

Source: Journal of Feline Medicine and Surgery Open Reports, 8(1)

Published By: SAGE Publishing

URL: <https://doi.org/10.1177/20551169221074624>

BioOne Complete (complete.BioOne.org) is a full-text database of 200 subscribed and open-access titles in the biological, ecological, and environmental sciences published by nonprofit societies, associations, museums, institutions, and presses.

Your use of this PDF, the BioOne Complete website, and all posted and associated content indicates your acceptance of BioOne's Terms of Use, available at www.bioone.org/terms-of-use.

Usage of BioOne Complete content is strictly limited to personal, educational, and non - commercial use. Commercial inquiries or rights and permissions requests should be directed to the individual publisher as copyright holder.

BioOne sees sustainable scholarly publishing as an inherently collaborative enterprise connecting authors, nonprofit publishers, academic institutions, research libraries, and research funders in the common goal of maximizing access to critical research.



Nasopharyngeal cryptococcosis in a cat: interlaboratory variation in cryptococcal antigen assay test results

Journal of Feline Medicine and Surgery Open Reports
1–8

© The Author(s) 2022

Article reuse guidelines:

sagepub.com/journals-permissions

DOI: 10.1177/20551169221074624

journals.sagepub.com/home/jfmsopenreports

This paper was handled and processed by the American Editorial Office (AAFP) for publication in *JFMS Open Reports*



Stephanie A McEwan¹ and Jane E Sykes²

Abstract

Case summary An indoor-only 6-year-old spayed female domestic cat was evaluated for a history of stertorous respiration. Skull radiographs revealed increased soft tissue density within the caudal aspect of the left nasal cavity. CT and rhinoscopy revealed a mass lesion in the choana, plus a smaller lesion, nearly completely occluding flow through the nasal passages. Rhinoscopy was used to collect a biopsy specimen from a fleshy, tan–yellow mass visualized in the caudal nasopharynx. Histopathology was diagnostic for *Cryptococcus* species infection and systemic antifungal therapy with fluconazole was initiated. Following a series of discordant results, serum samples were submitted to a veterinary diagnostic laboratory that utilized a cryptococcal antigen latex agglutination system with pretreatment of serum with pronase. Twenty-three months after the initial diagnosis, the cat's serum cryptococcal antigen titer declined to 1:5 and the cat has responded well to continuing treatment.

Relevance and novel information This case illustrates challenges associated with discordant test results for cryptococcal antigen among laboratories. Discordancies may be due to differences in assay design, or the underlying disease state itself, or whether serum is pre-treated with pronase; with some tests relying on the training and experience of the operator if the cryptococcal antigen detection test requires a subjective interpretation. It also resolves some confusion in the literature related to the assay types available and terminology used to describe them, and emphasizes the importance of considering cryptococcosis as an important differential for cats with upper respiratory signs, without nasal discharge, even if the cat is kept exclusively indoors.

Keywords: Cryptococcal antigen latex agglutination system; cryptococcosis; diagnostic tests; fluconazole; LCAT; lateral flow assay; point-of-care systems; pronase; stertor

Accepted: 28 December 2021

Case description

An indoor-only 6-year-old spayed female domestic cat was admitted to a local veterinary emergency clinic with a 4-month history of stertor and apparent upper respiratory distress in the absence of nasal discharge. Skull radiographs revealed ill-defined soft tissue opacity within the caudal aspect of the left nasal cavity. Contrast-enhanced CT followed by rhinoscopy was recommended as part of the diagnostic work-up. Thoracic radiographs were unremarkable. A respiratory PCR panel for upper respiratory tract viral and bacterial pathogens was negative (IDEXX Feline Upper Respiratory Disease RealPCR Panel).

On physical examination, there was no ocular or nasal discharge, or nasal deformity, but diminished airflow

¹Departments of Medicine and Surgery, Biological Science and Psychological Science, University of California, Irvine, CA, USA
²Department of Medicine and Epidemiology, School of Veterinary Medicine, University of California-Davis, Davis, CA, USA

Corresponding author:

Stephanie A McEwan PhD, Departments of Medicine and Surgery, Biological Science and Psychological Science, University of California, 4201 SBSG Building, Irvine, CA 92697-7085, USA
Email: smcewan@uci.edu



Creative Commons Non Commercial CC BY-NC: This article is distributed under the terms of the Creative Commons

Attribution-NonCommercial 4.0 License (<https://creativecommons.org/licenses/by-nc/4.0/>) which permits non-commercial use, reproduction and distribution of the work without further permission provided the original work is attributed as specified on the SAGE and Open Access pages (<https://us.sagepub.com/en-us/nam/open-access-at-sage>).

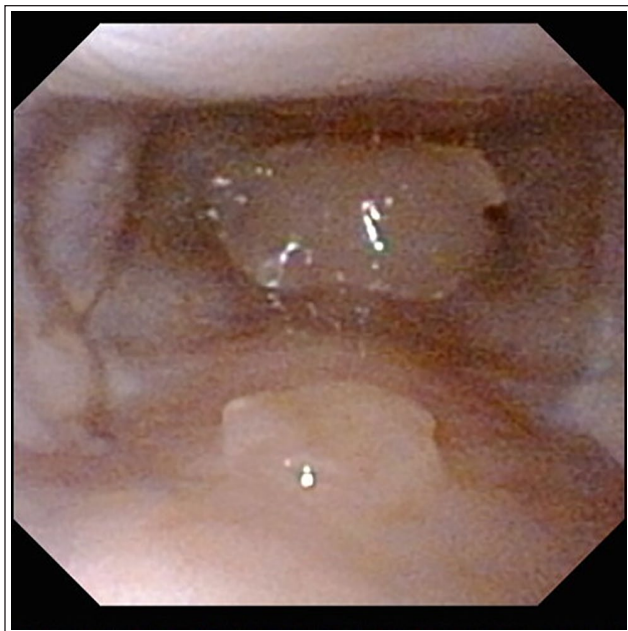

Figure 1 Before debulking, a large cryptococcal granuloma was noted arising from the floor of the nasopharynx, on the anterior-most aspect of the soft palate. Dorsal to the larger lesion was a smaller, similar appearing lesion, likely also a fungal granuloma. In these retroflexed endoscopic views, ventral is at the top of the image and the left side of the patient is the right side of the image

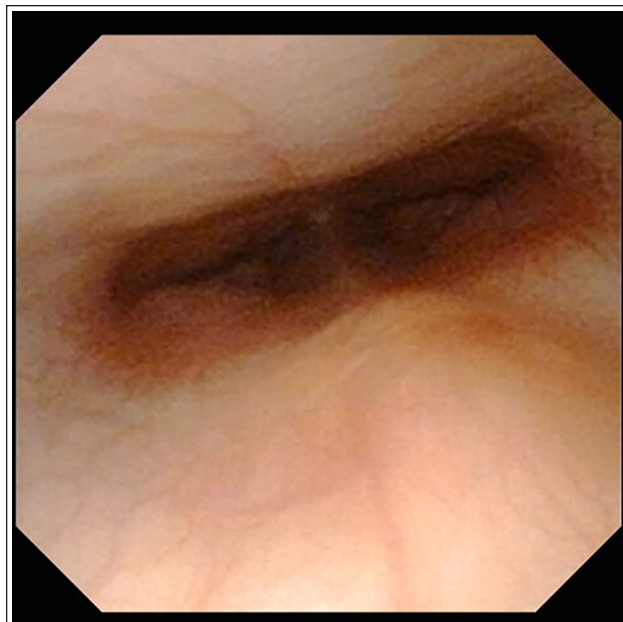


Figure 2 Post-debulking image showing the anterior choana after the debulking and saline lavage, now showing a clear caudal nasal passage

through both nostrils was noted. Tests for feline leukemia virus antigen and feline immunodeficiency virus antibody were negative (IDEXX FeLV RealPCR Test/IDEXX FIV RealPCR Test).

CT of the head revealed an approximately 1 cm well-defined mass filling the lumen of the caudal nasopharyngeal canal and the rostral nasopharynx. Rostral to this, there was a 2 mm soft tissue nodule on the ventral aspect of the nasopharyngeal cavity. Rhinoscopy revealed a 2 cm soft pale yellow-to-pinkish gelatinous mass in the choana, plus a smaller lesion caudal to the first lesion on the floor of the nasopharynx.

Before debulking, a large cryptococcal granuloma was noted, arising from the floor of the nasopharynx, on the anterior-most aspect of the soft palate; dorsal to the larger lesion was a smaller, similar-looking lesion, likely also a fungal granuloma (Figure 1). Post-debulking, there was a clear caudal nasal passage (Figure 2). Histopathology of a biopsy collected from the lesion revealed severe pyogranulomatous rhinitis with intralésional fungi organisms consistent with *Cryptococcus* species (Figure 3). Throughout the inflammatory lesion there were numerous fungal organisms consisting of a small central round body surrounded by a thick clear capsule. Some of these fungal organisms were within macrophages. Some fibroplasia was also present.

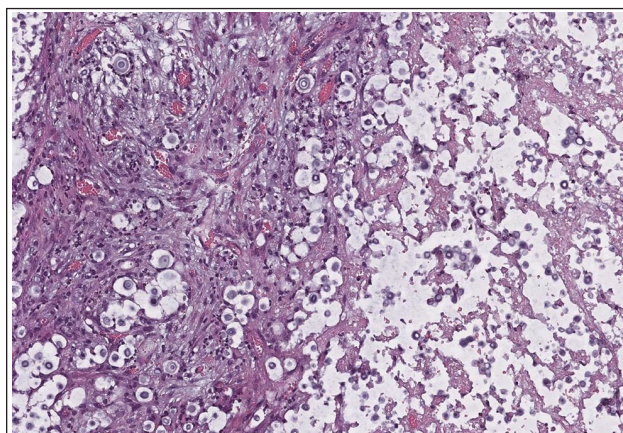


Figure 3 Histopathology of a biopsy collected from the lesion revealed severe pyogranulomatous rhinitis with intralésional fungi organisms consistent with *Cryptococcus* species. Throughout the inflammatory lesion there are numerous fungal organisms consisting of a small central round body surrounded by a thick clear capsule. Some of these fungal organisms are within macrophages. Some fibroplasia was also present

Following excision of the cryptococcal mass, all respiratory signs resolved. Advanced imaging ruled out gross pathology in the central nervous system (CNS) and thorax, and the cat was clinically well, which was a positive prognostic indicator. Treatment with fluconazole was initiated for 5 months (50 mg q12h PO).

Table 1 Serum cryptococcal antigen test results (in chronological order)

Test date	Enzyme immunoassay (Meridian Premier® Cryptococcal Antigen)	Latex-cryptococcal antigen test (IMMY LCAT): first series of LCAT results	Cryptococcal antigen latex agglutination system (Meridian CALAS®)	Latex-cryptococcal antigen test (IMMY LCAT): second series of LCAT results	Cryptococcal antigen lateral flow assay (IMMY CrAg LFA)
Hospital admission 19 September	Negative				
13 November	Negative				
6 February	Negative				
17 April	Negative	1:512			
22 April	Negative				
29 April		1:256	1:32		
20 May		1:256	1:8		
1 July			1:16	1:32	
29 September				1:64	
30 October				1:64	
27 January				1:16	
4 May				1:4	
10 August				0	1:5

Discordant test results

Two months after initial CT and rhinoscopy, no recurrence of clinical signs was observed and a cryptococcal antigen titer was negative, using enzyme immunoassay (EIA: Meridian Premier Cryptococcal Antigen; Meridian Bioscience). Three months later, a second rhinoscopy was performed, with swab specimen collection from the nasopharynx for cytology. No evidence of *Cryptococcus* species organisms was identified at that time, EIA remained negative and the cat appeared clinically normal.

The cat received 7 months of fluconazole treatment, and based on the results of five consecutive assays, the serum cryptococcal antigen titer was reported to be negative 7 months after the initial presentation. At that time, a repeat rhinoscopy was performed and no evidence of cryptococcal disease was visually observed in the nasopharynx of the cat.

Based on five serial negative cryptococcal antigen detection tests for 7 months, the cat was considered to be disease-free after 7 months of treatment. However, before discontinuing antifungal drug therapy, one EIA-negative serum sample was submitted to another laboratory (IDEXX Laboratories) for serum latex-cryptococcal antigen testing (IMMY LCAT), which reported a positive titer (1:512). Owing to these discordant results, a serum sample was split and submitted to a veterinary laboratory specializing in fungal disease diagnosis (Mira Vista Veterinary Diagnostics). Mira Vista uses the cryptococcal antigen latex agglutination system (Meridian Bioscience CALAS) and reported a positive test result (1:32).

Alerted by these discordant test results, a split serum sample was subsequently submitted to Mira Vista and to the University of California – Davis (UC Davis Veterinary Diagnostic Laboratory). UC Davis Veterinary Diagnostic Laboratory uses serum latex-cryptococcal antigen testing (IMMY LCAT) and the cryptococcal antigen lateral flow assay (IMMY CrAg LFA) as the reference standard. Both Mira Vista and UC Davis Veterinary Diagnostic Laboratory reported positive cryptococcal antigen titers for the cat, using Meridian CALAS, IMMY LCAT and IMMY CrAg LFA (Table 1).

Eight months after the initial presentation, CT was repeated because of reappearance of signs (head flicking and lip licking) that were originally observed when the cat was first diagnosed with cryptococcosis. The CT was unremarkable, and the cat's plasma fluconazole concentration was in the therapeutic range (31.84 mcg/ml; testing performed at University of Texas Health Science Center at San Antonio, Department of Pathology and Laboratory Medicine, Fungus Testing Laboratory). Based on these findings, serial monitoring of serum cryptococcal antigen titer as determined using LCAT continued every 3 months and showed a progressive decline in titer (1:512 to 0) 23 months after initiation of antifungal treatment. When the titer reached zero, the IMMY CrAg LFA was performed, which was weakly positive (1:5 using quantitative methodology). With the exception of temporary inappetence in the first week of fluconazole therapy, no adverse effects were reported during therapy. At all times, the cat appeared clinically normal. Regular monitoring has been scheduled and continuation of treatment is in place.

Discussion

Cryptococcosis is the most common systemic fungal disease in cats worldwide.¹⁻³ Feline cryptococcosis is caused by *Cryptococcus neoformans*–*Cryptococcus gattii* species complex with multiple genotypes and various subtypes.^{1,2,4} In cats, dogs and people, *C neoformans* and organisms that belong to the *C gattii* species complex, cause the majority of the disease.^{1,2} Published studies and case reports of feline cryptococcosis are globally abundant, mainly in the western USA, Canada, Australia and South America.^{2,3,5-17} Up to 25% of cases have been reported in cats with no outdoor access, presumably through contact with contaminated soil (eg, on shoes carried indoors) or aerosolized environmental basidiospores.^{16,18} The most common sites affected by cryptococcal infection in cats are the nasal cavity, skin, lymph nodes, brain, meninges and eyes.^{1,3,16} Inhalation of *Cryptococcus* spores through the nasal cavity is suspected to be the primary site for infection, although the exact route by which domestic cats become infected is not fully known.^{1,3,10,16,19} Nasal infection in cats can manifest as a polyp-like mass or nasal deformity, and results in chronic unilateral or bilateral upper respiratory signs (sneezing, nasal discharge), although infection can be subclinical.^{3,14,16} Once the respiratory system is infected, the organism can spread throughout the body via the bloodstream.¹ After an incubation period that is considered highly variable (months to years), the infection may invade local tissue (eg, optic nerve to eye) or disseminate hematogenously to other sites (eg, heart, liver and thyroid).^{2,3,16} Widespread dissemination is more common in purebred dogs than in cats, possibly as a result of genetic immunodeficiency. This report reinforces the importance of considering cryptococcosis as a differential diagnosis for nasopharyngeal and oropharyngeal masses. Cryptococcosis is an important differential in cats with stertor and accompanying signs of upper respiratory discomfort (head shaking, lip licking).^{1,10,20} In the present case, CT and rhinoscopy of the nasal cavity was useful to rule-in fungal disease, and fungal infection was confirmed following cytological identification of the lesions located in the nasopharynx and oropharynx.²¹

Cytology is a minimally invasive way of diagnosing cryptococcosis because the number of yeasts in the nasal discharge specimen or aspirated lesion are normally high and the organism has distinctive morphology using light microscopy.^{1,21} In the present case, severe pyogranulomatous rhinitis with massive intralesional fungi organisms compatible with *Cryptococcus* species was diagnosed (with the most prevalent pathogen in cats in southern California being *C gattii* molecular type VGIII/*Cryptococcus bacillisporus*).¹⁶

Within the past few decades, diagnostic tools for invasive fungal infections have continuously improved, and

cultural methods, antigen testing and molecular tests are now widely used.²² The capsular polysaccharide antigens of *Cryptococcus* species can be detected using various commercially manufactured test kits, and guidelines for reporting of test results vary by manufacturer. The detection of cryptococcal antigen in serum and cerebrospinal fluid (CSF) by latex agglutination and EIA are rapid and have been documented to be both sensitive and specific.^{1,23}

Reliable diagnosis is of utmost importance to determine optimal treatment durations.²⁴ Rapid confirmation or exclusion of the diagnosis of cryptococcosis allows clinicians to adjust diagnostic and therapeutic strategies, and has the potential to hasten the diagnosis and reduce costs of investigation for many patients.²⁵

Some serological tests that detect cryptococcal antigen in serum are highly sensitive, ranging between 90% and 100%, with a specificity ranging between 97% and 100%.^{3,8,13} Cats with cryptococcosis often have markedly increased antigen titers, although false negatives can occur with localized disease (nasal, ocular) and a negative result does not preclude diagnosis of cryptococcosis, particularly if only a single specimen has been tested and the patient shows clinical signs consistent with cryptococcosis.^{2,3,16,26} Thus, in a cat with lower antigen titers ($\leq 1:200$), additional diagnostic tests are recommended to confirm the diagnosis.^{3,27} During treatment, serial monitoring of serum cryptococcal antigen titers helps with monitoring a cat's response to therapy; progressive disease is generally accompanied by increasing antigen titers.^{26,28} A favorable prognosis is associated with a decrease in antigen titer of at least one order of magnitude at the end of 2 months of treatment.²⁹

The traditional LCAT measures circulating polysaccharide antigen (glucuronoxylomannan) in plasma or serum, and provides evidence of invasive cryptococcosis with both high sensitivity and specificity.^{25,26} The accuracy of the procedure is dependent on preincubation of serum with pronase (typically included as part of the test kit) and heat inactivation to remove interfering factors capable of causing false results, including rheumatoid factor, which can result in false-positive agglutination, and opsonizing antibodies, which can trap cryptococcal antigen.^{25,26} Although the LCAT is well accepted and validated as a diagnostic tool in veterinary laboratories, the procedure itself is time-consuming and expensive, and requires a trained technician and access to special laboratory equipment.^{2,25}

To overcome the limitations of latex agglutination (LA) testing for cryptococcal antigen screening, some reference laboratories in the USA perform EIAs, which allow for automation and a more objective interpretation of results. The EIA kit requires no specimen preparation beyond centrifugation; and, unlike some other cryptococcal antigen assays, it does not require preincubation

of serum with pronase. EIA-reactive samples can then be tested by the LA test to determine an endpoint titer in order to monitor a patient's response to therapy.³⁰

There has been some confusion in the veterinary literature related to the proper use of acronyms, trade names, trademarks, nomenclature and abbreviations, when referring either to the traditional latex cryptococcal antigen agglutination test or to cryptococcal antigen latex agglutination system tests.

Meridian Bioscience owns a trademark on the abbreviated name of 'CALAS' for the detection of *C neoformans* antigen in serum or CSF, which is registered with the United States Patent and Trademark Office. As a result, the acronym of 'CALAS' should be identified with the 'Meridian Bioscience cryptococcal antigen latex agglutination system' for the detection of *C neoformans* antigen in serum or CSF.

IMMY manufactures, markets and distributes only one LCAT and IMMY has never had any other version of this test available. IMMY refers to this test as the 'IMMY LCAT'.

The traditional cryptococcal antigen latex agglutination system test is a quantitative serologic test to detect *Cryptococcus* species polysaccharide capsule antigen that is sensitive and specific for the diagnosis of cryptococcosis in cats.^{2,16,26,31} The IMMY LCAT and Meridian CALAS (93–100% and 95%, respectively) have been reported to be more sensitive than EIA (55.6%) for the detection of cryptococcal antigen in human serum samples.^{32–34} This may be the result of the differences in the capture of antibodies used by different assays.³²

The sensitivity and specificity for the IMMY LCAT in human medicine have been reported to be 97–100% and 93–100%, respectively.³⁴ The IMMY LCAT has previously been established as an accurate diagnostic instrument in dogs and cats, with a sensitivity of 95–98% and specificity of 100%, respectively, when compared with diagnosis by fungal culture or microscopic identification of *Cryptococcus* species organisms in tissue fluids or biopsy specimens.^{1,2,16,26} It is considered to be among the most accurate diagnostic assays for the diagnosis of cryptococcal infections in animals and humans.^{2,16,26,32,35} Because of the established high sensitivity and specificity of the IMMY LCAT, the results of an IMMY LCAT assay for cats generally can be relied upon in a clinical setting.^{1,2,16,22,26}

In addition to the IMMY LCAT and the EIA, other rapid antigen detection assays have been developed for cats, including immunochromatographic lateral flow assays (LFAs) and point-of-care (POC) cryptococcal antigen tests. POC cryptococcal antigen assays can provide veterinarians with a rapid, patient-side diagnosis, requiring <15 mins to obtain results, with minimal requirements for technical expertise, when compared with the traditional laboratory-based latex agglutination

tests.^{2,25} LFAs are rapid, requiring <15 mins to obtain the results, can be performed at POC and have good agreement with the IMMY LCAT in humans.^{2,32} Some studies also have shown improved sensitivity of LFA POC cryptococcal antigen tests on sera collected from cats and dogs when compared with the IMMY LCAT.² The sensitivities and specificities for the cryptococcal antigen LFA in veterinary medicine (IMMY CrAg LFA) and CryptoPS (Biosynex) have been reported to be 92% and 80%, and 93.2% and 94.9%, respectively.^{2,25} Although the diagnosis of cryptococcosis in cats with positive POC test results should be confirmed using additional testing, use of POC assays may lead to earlier diagnosis and treatment of cats with cryptococcosis, as an alternative to the traditional cryptococcal antigen testing assays. The LFA has great potential for use in veterinary medicine as a POC or field screening tool to quickly establish whether cryptococcosis can be excluded as a diagnostic possibility in animals presenting with suspicious clinical signs, including sinonasal disease, CNS disease or pneumonia.²⁵ The LFA also offers semi-quantitative results based on line intensity patterns (1+ to 5+), which in one human study correlated with antigen titers of 1:10 (interquartile range [IQR] 1:5–1:20) for 1+, 1:40 (IQR 1:20–1:80) for 2+, 1:640 (IQR 1:160–1:2560) for 3+ and 1:5120 (IQR 1:2560–1:30720) for 4+.³⁶

In this case, the IMMY LCAT and Meridian CALAS were performed according to the manufacturers' protocols and included a pronase step. The IMMY CrAg LFA was performed according to the manufacturer's protocol and does not require a pronase step. In some instances, pretreatment of serum with pronase has been reported to reduce the number of false-negative test results by eliminating non-specific interference.³⁷ Pronase, a proteolytic enzyme, degrades antibodies and other proteins that bind to and thereby mask the antigen, with the subsequent release of polysaccharide, resulting in a higher titer.³⁷ The value of pronase in eliminating false-negative results for serum samples has been demonstrated previously.^{8,26,34,37,38} Studies have shown increases in serum antigen titers in human patients, following treatment of serum with pronase, with 57–81% of samples showing higher titers after treatment with pronase and often by many dilutions.³⁷ In the present case, the sensitivity of test kits that included pronase treatment of serum (IMMY LCAT and Meridian CALAS) were considerably higher than the kits that did not pretreat the cat's serum with pronase. However, in this case, and for the cat's first 7 months of antifungal therapy, there is no way of knowing whether any serum cryptococcal antigen titers reported using the automated EIA platform were true false-negatives because additional diagnostic testing was not ordered at that time to confirm the series of false-negative results. In addition, it is worth cautioning that a negative test does not exclude

the possibility of cryptococcal infection; and false-negative reactions may be attributed to other interfering factors (eg, post-zone phenomenon, also known as the 'hook' effect, the presence of immunocomplexes preventing release of glucuronoxylomannan antigen) or in cats with localized disease.^{2,3,16,26,39,40} In the case presented herein, the manufacturer of the Meridian Premier Cryptococcal Antigen EIA test kit initiated an urgent voluntary medical device recall of three test kit lots between 17 December 2018 through 30 April 2020 (United States Food and Drug Administration Class 2 Device Recall: PREMIER Cryptococcal Antigen enzyme immunoassay [Recall number. Z-0732-2019], lot numbers: 602096K089, 602096K090, 602096K091).

In the FDA Recall Notice, the manufacturer reported 'an enzyme reagent included in the kit is not maintaining stability through claimed product expiration, resulting in the potential for false-negative results when tested with patient specimens and the positive control'. When contacted for further details, the laboratory that performed the initial EIA confirmed the EIA test kits used for the cat's serum specimens were not included in the FDA recall notice. False-negative cryptococcal antigen results, as with any test, are possible, and may be more of a reflection of the disease state itself. No serologic test is likely to be 100% reliable and there continues to be a requirement to further investigate suspicious cases that test negative with any assay.²⁵

No prospective control studies exist on the treatment of feline cryptococcosis, and all data are based on retrospective studies and case reports.^{1,10} Fluconazole is generally accepted as a first-line therapy for feline cryptococcosis because of its ability to achieve high tissue concentrations in the brain and eye, which are often involved in nasal cryptococcosis.^{1,3,11,12,18} Fluconazole also has a low incidence of adverse effects.^{11,18} Azole monotherapy, using itraconazole or ketoconazole, and amphotericin B-containing protocols (for CNS involvement or disseminated diseases) have all been used to treat cats, although adverse effects are more common.^{1,10,18} Antifungal therapy is often required for months to years.^{8,13,41} Therapy should be continued until the serum antigen titer test becomes negative, or ideally at least two negative tests 1–3 months apart are obtained, although a negative titer does not preclude reinfection or relapse.^{1,39} The prognosis for cats diagnosed with nasal cryptococcosis is generally favorable.^{12,14,18}

Inadequate therapy is indicated by stationary or rising titers on subsequent, sequential specimens.²⁶ However, in some treated patients, titers remain positive at low levels for extended periods during which the viable organism itself can no longer be demonstrated.²⁶ In some cases, and following cessation of antifungal medication, the residual titer may decline further suggesting that cryptococcal antigen arose from non-viable organisms in those cases.²⁶ A lag in decline of detectable

cryptococcal antigen is not uncommon and may reflect the continued elimination of unviable organisms and capsular material from infected tissues and macrophages.²⁶ In the present case, regular monitoring has been scheduled and continuation of treatment is in place.

Conclusions

Cryptococcus species infection is a life-threatening fungal pathogen of animals and humans. It should be included as an important differential for cats presenting with nasal disease. Cats might not have a classic presentation associated with cryptococcal infection (eg, nasal discharge and nasal bridge distortion). Therefore, veterinarians should be aware that an atypical presentation (head flicking and lip licking) with stertor may reflect localized or systemic *Cryptococcus* species infection in an otherwise apparently healthy cat.

A critical strategy in reducing the morbidity and mortality from feline cryptococcal disease is early diagnosis and prompt antifungal treatment. The availability of lower-cost POC assays for the detection of cryptococcosis, with higher sensitivity and specificity, may facilitate earlier diagnosis and management of cryptococcosis, although a false-negative can occur in cats presenting with localized disease. This report emphasizes the importance of selecting sensitive assays for detection of cryptococcal antigen to mitigate testing variabilities and discrepancies associated with different assays. It may be useful for a patient's serum to be interpreted by the same laboratory (and ideally by the same operator) for continuity of testing because subjective interpretation of test results can differ widely depending on various factors, including test kit selection and operator differences. In the present case, had the cat's veterinarian relied on the negative test results reported during the first 7 months of treatment, and without the performance of additional diagnostic tests, the cat's antifungal treatment may have been terminated prematurely, leading to a potentially negative outcome, and even death. For these reasons, it is worth cautioning that additional studies are required to determine whether other mechanisms may also have contributed to the false-negative results in this case.

Acknowledgements Thank you to Dr Tracey Rossi DVM, DipACVIM (SAIM) and Dr Julie Stegeman DVM, DipACVIM (SAIM) for the medical management of the patient.

Conflict of interest The authors declared no potential conflicts of interest with respect to the research, authorship, and/or publication of this article.

Funding The authors received no financial support for the research, authorship, and/or publication of this article.

Ethical approval The work described in this manuscript involved the use of non-experimental (owned or unowned) animals. Established internationally recognized high standards

(‘best practice’) of veterinary clinical care for the individual patient were always followed and/or this work involved the use of cadavers. Ethical approval from a committee was therefore not specifically required for publication in *JFMS Open Reports*. Although not required, where ethical approval was still obtained, it is stated in the manuscript.

Informed consent Informed consent (verbal or written) was obtained from the owner or legal custodian of all animal(s) described in this work (experimental or non-experimental animals, including cadavers) for all procedure(s) undertaken (prospective or retrospective studies). For any animals or people individually identifiable within this publication, informed consent for their use in the publication (verbal or written) was obtained from the people involved.

ORCID iD Stephanie A McEwan  <https://orcid.org/0000-0001-5812-6878>

References

- Pennisi MG, Hartmann K, Lloret A, et al. **Cryptococcosis in cats: ABCD guidelines on prevention and management.** *J Feline Med Surg* 2013; 15: 611–618.
- Reagan KL, McHardy I, Thompson GR, III, et al. **Evaluation of the clinical performance of 2 point-of-care cryptococcal antigen tests in dogs and cats.** *J Vet Intern Med* 2019; 33: 2082–2089.
- Trivedi SR, Malik R, Meyer W, et al. **Feline cryptococcosis. impact of current research on clinical management.** *J Feline Med Surg* 2011; 13: 163–172.
- Danesi P, Falcaro C, Schmertmann L, et al. **Cryptococcus in wildlife and free-living mammals.** *J Fungi* 2021; 7: 29. DOI: 10.3390/jof7010029.
- Duncan C, Stephen C and Campbell J. **Clinical characteristics and predictors of mortality for *Cryptococcus gattii* infection in dogs and cats of southwestern British Columbia.** *Can Vet J* 2006; 47: 993–998.
- Flatland B, Greene RT and Lappin MR. **Clinical and serological evaluation of cats with cryptococcosis.** *J Am Vet Med Assoc* 1996; 209: 1110–1113.
- Gerds-Gorgan S and Dayrel-Hart B. **Feline cryptococcosis, a retrospective study evaluation.** *J Am Anim Hosp Assoc* 1997; 33: 118–122.
- Gray LD and Roberts GD. **Experience with the use of pronase to eliminate interference factors in the latex agglutination test for cryptococcal antigen.** *J Clin Microbiol* 1988; 26: 2450–2451.
- Kluger EK, Karaoglu HK, Krockenberger MB, et al. **Recrudescence cryptococcosis, caused by *Cryptococcus gattii* (molecular type VGII), over a 13-year period in a Birman cat.** *Med Mycol* 2006; 44: 561–566.
- Livet V, Javard R, Alexander K, et al. **Cryptococcal nasopharyngeal polypoid mass in a cat.** *JFMS Open Rep* 2015; 1. DOI: 10.1177/2055116915597238.
- Malik R, Wigney DI, Muir DB, et al. **Cryptococcosis in cats: clinical and mycological assessment of 29 cases and evaluation of treatment using orally administered fluconazole.** *J Med Vet Mycol* 1992; 30: 133–144.
- McGill S, Malik R, Saul N, et al. **Cryptococcosis in domestic animals in Western Australia: a retrospective study from 1995–2006.** *Med Mycol* 2009; 47: 625–639.
- O’Brien CR, Krockenberger MB, Martin P, et al. **Long-term outcome of therapy for 59 cats and 11 dogs with cryptococcosis.** *Aust Vet J* 2006; 84: 384–392.
- O’Brien CR, Krockenberger MB, Wigney DI, et al. **Retrospective study of feline and canine cryptococcosis in Australia from 1981 to 2001: 195 cases.** *Med Mycol* 2004; 42: 449–460.
- Sykes JE, Sturges BK, Cannon MS, et al. **Clinical signs, imaging features, neuropathology and outcome in cats and dogs with CNS cryptococcosis from California.** *J Vet Intern Med* 2010; 24: 1427–1438.
- Trivedi SR, Sykes JE, Cannon MS, et al. **Clinical features and epidemiology of cryptococcosis in cats and dogs in California: 93 cases (1988–2010).** *J Am Vet Med Assoc* 2011; 239: 357–369.
- Wilkinson GT. **Feline cryptococcosis: a review and seven case reports.** *J Small Anim Pract* 1979; 20: 749–768.
- Almendros A, Muguero DH, Hill FI, et al. **First case of feline cryptococcosis in Hong Kong, caused by *Cryptococcus neoformans*.** *Med Mycol Case Rep* 2020; 19: 8–11.
- Reed N and Gunn-Moore D. **Nasopharyngeal disease in cats: 1 diagnostic investigation.** *J Feline Med Surg* 2012; 14: 306–315.
- Ellis DH and Pfeiffer TJ. **Natural habitat of *Cryptococcus neoformans var gattii*.** *J Clin Microbiol* 1990; 28: 1642–1644.
- Malik R, Martin P, Wigney DI, et al. **Nasopharyngeal cryptococcosis.** *Aust Vet J* 1997; 75: 483–488.
- Prattes J, Heldt S, Eigl S, et al. **Point of care testing for the diagnosis of fungal infections: are we there yet?** *Curr Fungal Infect Rep* 2016; 10: 43–50.
- Dolan CT. **Specificity of the latex-cryptococcal antigen test.** *Am J Clin Pathol* 1972; 58: 358–364.
- Tintelnot K, Hagen F, Han CO, et al. **Pitfalls in serological diagnosis of *Cryptococcus gattii* infections.** *Med Mycol* 2015; 53: 874–879.
- Krockenberger MB, Marschner C, Martin P, et al. **Comparing immunochromatography with latex antigen agglutination testing for the diagnosis of cryptococcosis in cats, dog and koalas.** *Med Mycol* 2020; 58: 39–46.
- Malik R, McPetrie R, Wigney D, et al. **A latex cryptococcal antigen agglutination test for diagnosis and monitoring of therapy for cryptococcosis.** *Aust Vet J* 1996; 74: 358–364.
- Grau S and Luque S. **Antifungal drug monitoring: when, how, and why.** *Enferm Infec Microbiol Clin* 2015; 33: 295–297.
- Wolf A. **Fungal diseases of the nasal cavity of the dog and the cat.** *Vet Clin North Am Small Anim Pract* 1992; 22: 1119–1132.
- Jacobs GJ, Medleau L, Calvert C, et al. **Cryptococcal infection in cats: factors influencing treatment outcome, and results of sequential serum antigen titers in 35 cats.** *Vet Intern Med* 1997; 11: 14.
- Hansen J, Slechta ES, Gates-Hollingsworth MA, et al. **Large-scale evaluation of the immuno-mycological lateral flow and enzyme-linked immunoassays for detection of cryptococcal antigen in serum and cerebrospinal fluid.** *Clin Vaccine Immunol* 2013; 20: 552–555.
- Medleau L, Marks MA, Brown J, et al. **Clinical evaluation of a cryptococcal antigen latex agglutination test for diagnosis of cryptococcosis in cats.** *J Am Vet Med Assoc* 1990; 196: 1470–1473.

- 32 Binnicker MJ, Jespersen DJ, Bestrom JE, et al. **Comparison of four assays for the detection of cryptococcal antigen.** *Clin Vaccine Immunol* 2012; 19: 1988–1990.
- 33 Tang MW, Clemons KV, Katzenstein DA, et al. **The cryptococcal antigen lateral flow assay: a point-of-care diagnostic at an opportune time.** *Crit Rev Microbiol* 2016; 42: 634–642.
- 34 Tanner DC, Weinstein MP, Fedorciw B, et al. **Comparison of commercial kits for detection of cryptococcal antigen.** *J Clin Microbiol* 1994; 32: 1680–1684.
- 35 Jarvis JN, Percival A, Bauman S, et al. **Evaluation of a novel point-of-care cryptococcal antigen test on serum, plasma, and urine from patients with HIV-associated cryptococcal meningitis.** *Clin Infect Dis* 2011; 53: 1019–1023.
- 36 Jarvis JN, Tenforde MW, Lechiile K, et al. **Evaluation of a novel semiquantitative cryptococcal antigen lateral flow assay in patients with advanced HIV disease.** *J Clin Microbiol* 2020; 58: 1–11.
- 37 Hamilton JR, Noble A and Denning DW. **Performance of *Cryptococcus* antigen latex agglutination kits on serum and cerebrospinal fluid specimens of AIDS patients before and after pronase treatment.** *J Clin Microbiol* 1991; 29: 333–339.
- 38 Temstet A, Roux P, Poirot JL, et al. **Evaluation of a monoclonal antibody-based latex agglutination test for diagnosis of cryptococcosis: comparison with two tests using polyclonal antibodies.** *J Clin Microbiol* 1992; 30: 2544–2550.
- 39 Lester SJ, Malik R, Bartlett KH, et al. **Cryptococcosis: update and emergence of *Cryptococcus gattii*.** *Vet Clin Pathol* 2011; 40: 4–17.
- 40 Yadava SK and Fazili T. **Postzone phenomenon resulting in a false-negative cerebral spinal fluid cryptococcal antigen lateral flow assay.** *AIDS* 2019; 33: 1099–1100.
- 41 Duncan C, Stephen C, Lester S, et al. **Follow-up study of dogs and cats with asymptomatic *Cryptococcus gattii* infection or nasal colonization.** *Med Mycol* 2005; 43: 663–666.