



## **Cutaneous xanthoma causing hypercalcaemia in a cat**

Authors: Ma, Doris, Romine, Jessica F, and Hardcastle, Michael

Source: Journal of Feline Medicine and Surgery Open Reports, 8(1)

Published By: SAGE Publishing

URL: <https://doi.org/10.1177/20551169221082050>

---

BioOne Complete ([complete.BioOne.org](https://complete.BioOne.org)) is a full-text database of 200 subscribed and open-access titles in the biological, ecological, and environmental sciences published by nonprofit societies, associations, museums, institutions, and presses.

Your use of this PDF, the BioOne Complete website, and all posted and associated content indicates your acceptance of BioOne's Terms of Use, available at [www.bioone.org/terms-of-use](https://www.bioone.org/terms-of-use).

Usage of BioOne Complete content is strictly limited to personal, educational, and non - commercial use. Commercial inquiries or rights and permissions requests should be directed to the individual publisher as copyright holder.

---

BioOne sees sustainable scholarly publishing as an inherently collaborative enterprise connecting authors, nonprofit publishers, academic institutions, research libraries, and research funders in the common goal of maximizing access to critical research.



# Cutaneous xanthoma causing hypercalcaemia in a cat

Doris Ma<sup>1</sup> , Jessica F Romine<sup>1</sup>   
 and Michael Hardcastle<sup>2</sup>

*Journal of Feline Medicine and Surgery Open Reports*  
 1–6

© The Author(s) 2022

Article reuse guidelines:

sagepub.com/journals-permissions

DOI: 10.1177/20551169221082050

journals.sagepub.com/home/jfmsopenreports

This paper was handled and processed by the European Editorial Office (ISFM) for publication in *JFMS Open Reports*



## Abstract

**Case summary** A 5-year-old male neutered cat weighing 3.56 kg presented owing to the development of two masses over the dorsal cervical and cranial thoracic areas, as well as weight loss, inappetence and vomiting. Diagnostic tests revealed a grossly lipaemic sample with hypercholesterolaemia (440 mg/dl; reference interval [RI] 90.0–205.0), hypercalcaemia (>16.0 mg/dl [RI 8.0–11.8]) and urine specific gravity 1.022 (RI  $\geq$ 1.035). When re-presented 9 months later, fasted blood analyses revealed elevated ionised calcium (1.87 mmol/l [RI 1.11–1.38]), persistently elevated total calcium, normal phosphate and persistent minimally concentrated urine with calcium oxalate dihydrate crystals. Ultrasound-guided fine-needle aspiration of the masses produced blood-tinged purulent fluid with negative culture results. Excisional biopsies of both masses were undertaken, and histopathology was consistent with cutaneous xanthoma. No organisms were identified with special staining, and deep-tissue culture did not grow bacteria or fungi. Postoperatively, repeat fasted biochemical analysis revealed persistent hypercholesterolaemia with normal triglycerides, and normalisation of ionised and total calcium levels. Based on these findings, a diagnosis of cutaneous xanthoma causing hypercalcaemia due to primary dyslipidaemia was made. The cat was reported to be significantly improved in comfort and energy levels postoperatively and a transition to a fat-restricted diet was instituted. Eight months after xanthoma removal no recurrence was reported.

**Relevance and novel information** To our knowledge, this is the first report of cutaneous xanthoma and associated granulomatous inflammation causing hypercalcaemia due to dyslipidaemia in a cat. Familial hypercholesterolaemia is an example of a primary condition that could cause dyslipidaemia in cats, and further studies are warranted to better describe the genetic characteristics. Xanthoma formation and the resultant granulomatous inflammation should be considered in cases of hypercalcaemia.

**Keywords:** Ionised hypercalcaemia; total hypercalcaemia; cutaneous xanthoma; familial hypercholesterolaemia; elevated ionised calcium; elevated total calcium; elevated cholesterol; congenital hypercholesterolaemia; primary dyslipidaemia

**Accepted:** 31 January 2022

## Case description

A 5-year-old male neutered domestic longhair cat weighing 3.56 kg was presented to its primary veterinarian for the development of mass effects in the left dorsal cervical and cranial thoracic areas, which had appeared 4 months and 1 week prior to presentation, respectively. Serum biochemical analysis revealed lipaemia with hypercholesterolaemia (440 mg/dl; reference interval [RI] 90.0–205.0) (see Table S1 in the supplementary material). Weight loss of 600 g was the only clinical sign at that time. The cat re-presented 7 months later for mass enlargement and further weight loss of 150 g.

Fine-needle aspirates were obtained from the masses, and a cytological diagnosis of chronic granulomatous

<sup>1</sup>Department of Internal Medicine, Animal Referral Centre, Auckland, New Zealand

<sup>2</sup>Department of Anatomic Pathology, Gribbles Veterinary Pathology New Zealand, Auckland, New Zealand

### Corresponding author:

Doris Ma BVSc, Department of Internal Medicine, Animal Referral Centre, 224, Albany Highway, Schnapper Rock, Auckland 0632, New Zealand

Email: dorisma0203@gmail.com



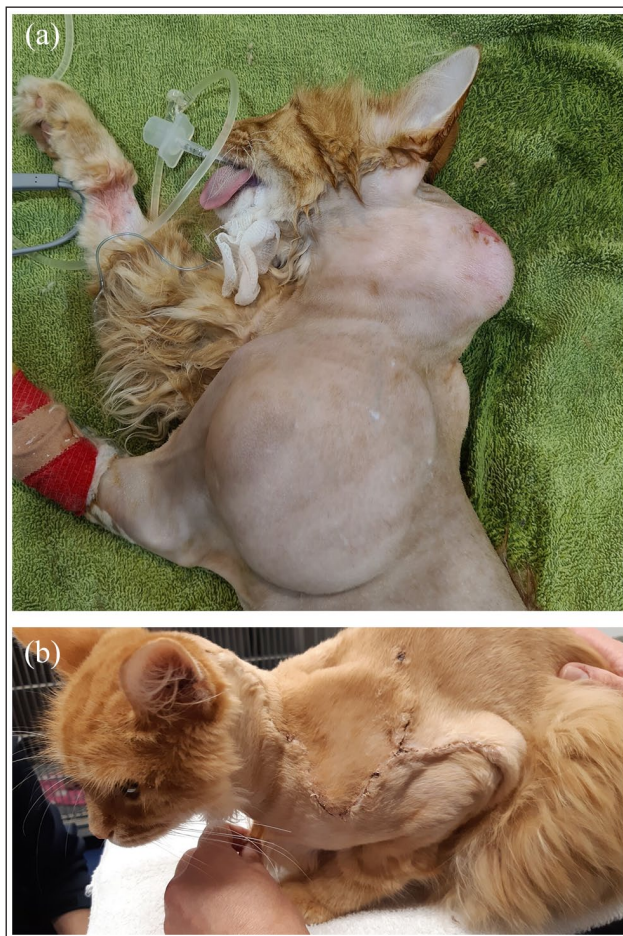
Creative Commons Non Commercial CC BY-NC: This article is distributed under the terms of the Creative Commons

Attribution-NonCommercial 4.0 License (<https://creativecommons.org/licenses/by-nc/4.0/>) which permits non-commercial use, reproduction and distribution of the work without further permission provided the original work is attributed as specified on the SAGE and Open Access pages (<https://us.sagepub.com/en-us/nam/open-access-at-sage>).

inflammation was made. No treatments were instigated. Over the next 2 months, the cat developed inappetence and vomiting, with further mass enlargement and weight loss of 150 g. Haematological testing at the second presentation to the primary veterinarian revealed immature neutrophilia ( $0.9 \times 10^9/l$  [RI 0–0.3]) and lymphopenia ( $1.4 \times 10^9/l$  [RI 1.5–7.0]). Urinalysis revealed a urine specific gravity (USG) of 1.022 (RI  $\geq 1.035$ ). Serum biochemical testing revealed total hypercalcaemia ( $>16.0 \text{ mg/dl}$  [RI 8.0–11.8]) (see Table S1 in the supplementary material). Cholesterol and triglyceride (TG) levels were not assessed at that appointment. The cat was administered saline (0.9% NaCl) subcutaneously (SC), vitamin B12 (250  $\mu\text{g}$  SC) and maropitant (1 mg/kg SC).

The cat was referred to the internal medicine service at a referral veterinary hospital 1 week later. There was reduced body condition. The dorsal cervical mass (6  $\times$  8 cm) was haired, fluctuant and soft. The cranial thoracic mass (5  $\times$  11 cm) was haired, fluctuant and firm (see Figure 1). Blood gas and electrolyte analysis revealed ionised hypercalcaemia (1.87 mmol/l [RI 1.11–1.38]) (see Table S1 in the supplementary material), metabolic alkalosis (pH 7.44 [RI 7.210–7.410]) and elevated bicarbonate (26.3 mmol/l [RI 16–23]) with a low-normal chloride (119 mmol/l [RI 117–127]) and high-normal sodium (154 mmol/l [RI 149–157]). Fasting serum biochemical analysis revealed total hypercalcaemia (3.71 mmol/l [RI 2.22–2.67]; see Table S1 in the supplementary material), hypoalbuminaemia (28 g/l [RI 33–43]) and normal phosphate (1.73 mmol/l [RI 1.07–2.22]). Urine was collected via cystocentesis; urinalysis revealed a USG of 1.017 (RI  $\geq 1.035$ ) and presumed iatrogenic blood contamination. The sediment revealed calcium oxalate dihydrate crystals.

A board-certified internist experienced in ultrasonography performed ultrasounds of the abdomen and masses. The liver and spleen were normal in size, shape and echogenicity. The gallbladder was moderately distended, without distension of the common bile duct, and contained small amounts of gravity-dependent sediment. The kidneys were normal in size (left 4.6 cm and right 3.9 cm in length) and shape. The adrenal glands were normal in size (left 0.45 cm and right 0.42 cm at their respective caudal poles) and shape. The pancreas was mildly thickened (body 12.1 mm and pancreatic duct 2.0 mm in width), consistent with historical or chronic pancreatitis. The gastrointestinal tract was normal in thickness and layering. The jejunal and ileocolic lymph nodes were of normal size but were mildly hypoechoic and prominent. There was no abdominal free fluid. The cranial thoracic mass contained hypoechoic and thickened tissue consistent with cellulitis and oedema. Fine-needle aspiration (FNA) with a 22 G needle was non-productive. The dorsal cervical mass contained echogenic material. FNA yielded 60 ml of blood-tinged

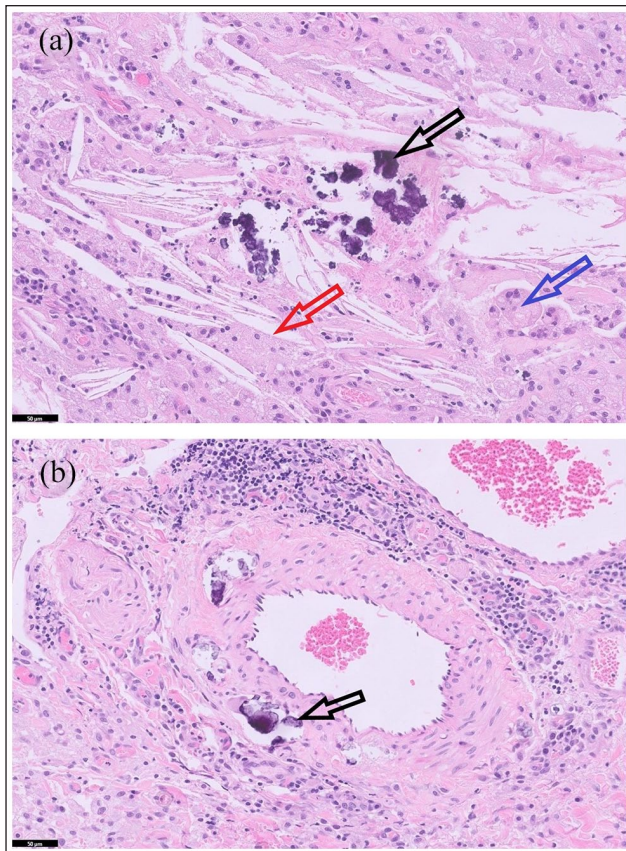


**Figure 1** Gross appearance of the cutaneous xanthomas (a) preoperatively and (b) 2 weeks postoperatively

purulent fluid, which was submitted for fungal and bacterial culture and sensitivity. There was no growth after 4 weeks of incubation.

One week later, the masses were excised by a board-certified surgeon. The dorsal cervical mass was friable with a ‘cottage cheese’ consistency. It did not shell out easily but ruptured and exuded creamy purulent material upon incision. The cranial thoracic mass shelled out easily and appeared uniformly white in cross section with cobbled, cream-coloured fibrous tissue peripherally. A Jackson Pratt drain and 100 ml grenade (MILA International) were placed. A constant rate infusion (CRI) of fentanyl was administered for perioperative pain relief and was continued postoperatively. After surgery, the cat was inappetent for 24 h during which maropitant (1 mg/kg IV) was administered. A 12.5  $\mu\text{g/h}$  transdermal fentanyl patch was placed and was active for 72 h. The fentanyl CRI was titrated down with appropriate pain scoring every 4 h, and only discontinued when the fentanyl patch became active and the cat was comfortable. Amoxicillin–clavulanic acid at 12.64 mg/kg was administered orally q12 h for 7 days and 0.02 mg/kg





**Figure 2** (a) Photomicrograph of a section of the cutaneous xanthomas containing a clump of mineralised necrotic debris (black arrow) with cholesterol crystals (red arrow) surrounded by variably multinucleated macrophages (blue arrow), neutrophils, lymphocytes and plasma cells. (b) Photomicrograph of a section of the cutaneous xanthomas containing an arteriole with multifocal mural mineralisation (arrow), surrounded by neutrophils, lymphocytes, plasma cells and macrophages

buprenorphine was administered transmucosally q8h for 4 days. Intraoperative local analgesia and postoperative non-steroidal anti-inflammatory drugs could have been added to the pain management plan. Drain production was measured. The average volume reduced from 0.91 ml/kg/h to 0.26 ml/kg/h over 3 days. The fluid remained serosanguineous. On day 3, the drain was removed, and the cat was discharged with improved appetite. At home, the cat was confined to a crate with only short periods of supervised mild activity. Exercise restriction was continued for 3 weeks postoperatively, to ensure complete healing of the surgical site.

Histopathological diagnosis of cutaneous xanthoma was made from both masses (see Figure 2). The predominant inflammatory cells were highly vacuolated, occasionally multinucleated macrophages arranged in sheets or nests, sometimes enveloping cholesterol crystals. There were fewer neutrophils, eosinophils, lymphocytes

and plasma cells, which occasionally clustered around vessels. There were foci of necrosis that were sometimes lightly mineralised. Few arterioles exhibited multifocal mural mineralisation. Gram, Fite's acid fast and periodic acid-Schiff staining did not reveal pathogens. There were no fungi, or aerobic or anaerobic bacteria cultured or isolated after 4 weeks of incubation.

The cat was re-presented 14 days postoperatively for suture removal and repeat biochemical analysis. There were no clinical abnormalities at home and the owner reported significant improvement in demeanour and appetite. Fasting biochemical analysis revealed elevated cholesterol (25.3 mmol/l [RI 2.4–7.1]), normal TGs (0.37 mmol/l [RI 0.11–1.42]) and normal ionised calcium (1.36 mmol/l [RI 1.11–1.38]) (see Table S1 in the supplementary material). The cat was suspected to have cutaneous xanthomas causing hypercalcaemia as a result of primary dyslipidaemia. Dietary therapy with a low-fat diet was recommended at the recheck 14 days postoperatively. However, the cat demonstrated highly selective food preferences and was only completely transitioned onto a strict lower-fat diet (Hill's Prescription Diet w/d; Royal Canin Ultra-Light) 4 months later. After 4 months of strict dietary therapy, there was no recurrence of xanthomas or other clinical signs reported. Biochemical testing revealed persistent hypercholesterolaemia, although the levels were significantly lower (12.08 mmol/l [RI 1.68–5.81]; see Table S1 in the supplementary material). Ionised calcium was normal (1.24 mmol/l [RI 1.11–1.38]; see Table S1 in the supplementary material), as were creatinine (189  $\mu$ mol/l [RI 71–212]) and blood urea nitrogen (11.8 mmol/l [RI 5.7–12.9]). Urine analysis obtained via cystocentesis revealed a USG of 1.028 (RI  $\geq$ 1.035), pH 7.0 and a quiet sediment. Recommendations were made to continue on this diet while monitoring for xanthoma reformation, recurrence of clinical signs and serum cholesterol concentrations every 6 months. Lipid-lowering drugs may be considered if hypercholesterolaemia persists.

## Discussion

To our knowledge, this is the first report of cutaneous xanthomas causing hypercalcaemia due to primary dyslipidaemia, and, more specifically, hypercholesterolaemia, in a cat. Cutaneous xanthomas are benign granulomatous skin or subcutis lesions. They are usually associated with fasting hyperlipidaemia, and the elevation in TGs and/or cholesterol. Hyperlipidaemia results from abnormal lipid synthesis, metabolism or transportation.<sup>1</sup> Xanthomas are formed when motion, friction, heat and inflammation cause extravasation of lipids from capillaries into tissue. Macrophages phagocytose lipids, resulting in aggregations of characteristic foam cells and extracellular cholesterol deposition.<sup>2,3</sup> Foam cells may also arise from in situ lipid production by macrophages.

Lipids can signal additional macrophages into existing xanthomas.<sup>3</sup> In cats, cutaneous xanthomas may present as papules, plaques or nodules that are pale yellow to pink in colour and can be intact or ulcerated.<sup>4</sup> They often appear in the periauricular and periorbital regions<sup>4</sup> but have appeared inguinally<sup>2</sup> and at sites of previous trauma.<sup>5</sup> A commonly reported site is where spinal nerves emerged through vertebral foramina, as vessels here are easily stretched or compressed by adjacent vertebrae during movement. Other common sites are over bony prominences, including the sciatic nerve over the greater ischiatic notch. Xanthoma development here places pressure on the nerves, resulting in peripheral neuropathies. Thus, frequently observed clinical signs include Horner's syndrome, and sciatic, tibial and radial nerve paralysis.<sup>6</sup> Xanthomas may also be systemic, involving the adrenal glands, colon,<sup>7</sup> liver, spleen, mesentery, kidney, heart, tendons and skeletal muscle.<sup>6</sup> Ocular pathologies are common manifestations of hyperlipidaemia, including lipaemia retinalis and lipid-filled aqueous humour.<sup>1</sup> In contrast, this cat had no ocular abnormalities, and only exhibited the cutaneous form, with no peripheral neuropathy. There were no gastrointestinal signs that necessitated exploratory laparotomy, precluding the diagnosis of systemic xanthomas.

Xanthomas have also been described in dogs, horses, amphibians, reptiles and commonly in birds and humans.<sup>8-13</sup> Conditions causing secondary hyperlipidaemia predispose to xanthoma formation and include diabetes mellitus, as well as the administration of exogenous progestins<sup>14</sup> and glucocorticoids.<sup>15</sup> However, there has been one report of a normolipaemic cat with idiopathic cutaneous xanthoma.<sup>3</sup> More specifically, hypercholesterolaemia can be caused by pancreatitis, hypoadrenocorticism, cholestasis and nephrotic syndrome.<sup>13</sup> The cat of this report was most likely affected by primary dyslipidaemia because abdominal ultrasonography, blood and urine analyses excluded the abovementioned conditions. Familial hypercholesterolaemia (FH) is an example of a primary condition that can cause primary dyslipidaemia, and was suspected in this cat given the elevated serum cholesterol with normal serum TG concentrations. The mild ultrasonographic changes of the pancreas, gallbladder and abdominal lymph nodes, with mild hypoalbuminaemia, could be explained by a separate chronic low-grade pancreatitis, inflammatory bowel disease or triaditis, but are considered less likely as the gastrointestinal signs all resolved with removal of the masses and normalisation of calcium. Hypoalbuminaemia could be caused by reduced intake and granulomatous inflammation causing an acute phase reaction response, and also resolved with xanthoma removal. The elevated bicarbonate, metabolic alkalosis with low-normal chloride and high-normal sodium could be explained by vomiting and loss of acid-rich gastric secretions.

Hypercalcaemia was observed in this cat, which has not been reported in any species with xanthomas. Hypercalcaemia can be explained by the presence of granulomatous disease. Calcium homeostasis is tightly controlled and increases with parathyroid hormone (PTH) and active vitamin D. In granulomatous disease, macrophages contain 1-alpha-hydroxylase, which activates vitamin D without homeostatic control, thereby causing hypercalcaemia.<sup>16</sup> Chronic kidney disease (CKD), primary and secondary hyperparathyroidism, hypoadrenocorticism, hypercalcaemia of malignancy, hypervitaminosis D and idiopathic hypercalcaemia are other differential diagnoses of hypercalcaemia.

CKD, and therefore renal secondary hyperparathyroidism, were excluded in the cat of this report on the basis of abdominal ultrasonography, and biochemical and urine analyses. Initial USG revealed minimally concentrated urine and presence of calcium oxalate dihydrate crystals on sediment, both of which were most likely secondary to hypercalcaemia. Abdominal ultrasonography revealed kidneys that were normal in size and shape bilaterally. Eight months postoperatively, there was no azotaemia on biochemical analysis. Urinalysis revealed a persistently low USG, although it had increased from initial testing. Despite this, the resolution of hypercalcaemia made CKD unlikely. Hypervitaminosis D was unlikely given there was no history of vitamin D intoxication from the diet or other sources. Hypoadrenocorticism was considered unlikely as adrenal gland size was normal on ultrasound and there were no electrolyte derangements or haematological changes consistent with hypocortisolaemia. However, 'atypical' hypoadrenocorticism could still be possible, and an adrenocorticotrophic hormone stimulation test would have been useful as a screening test had the calcium remained elevated. The remaining differential diagnoses mentioned above were considered less likely based on calcium normalisation following xanthoma removal in combination with abdominal ultrasonography, and blood and urine analyses.

A limitation of this report is the lack of further diagnostic tests, which would be necessary to definitively exclude other causes of hypercalcaemia. For example, thoracic radiography could have been performed prior to xanthoma removal to exclude the presence of tumours inducing hypercalcaemia of malignancy. Additionally, measuring serum PTH (which would be suppressed) and active vitamin D (which would be inappropriately increased) could have confirmed that the xanthomas were the source of hypercalcaemia.<sup>16</sup> PTH measurement is currently not available in New Zealand.

Only hypercholesterolaemia was evident without hypertriglyceridaemia in this cat. Of the four lipoproteins described, cholesterol makes up most of the lipids in low-density lipoproteins (LDL) and high-density

lipoproteins (HDL); TG make up most of the lipids in chylomicrons (CM) and very-low-density lipoproteins. Therefore, increased LDL and HDL leads to hypercholesterolaemia, while increased CM and TG leads to hypertriglyceridaemia. Lipoproteins travel through the bloodstream to the target organ and, with activation by apolipoproteins, are degraded by lipoprotein lipase found on vascular endothelium.

FH has not been reported to cause xanthoma formation in cats. However, xanthoma formation induced by FH has been described in humans and is distinguished by increased serum LDL leading to cholesterol deposition in tissues, atherosclerosis and coronary disease.<sup>17</sup> This condition is caused by mutations in the gene encoding either the LDL receptor, apolipoprotein B; protein LDLRAP1 needed for LDL hepatic internalisation; or proprotein convertase PCSK9, which reduces LDL uptake.<sup>17</sup> It would be beneficial to define the lipoprotein(s) elevated in this cat to further characterise its disease. Lipoproteins can be differentiated using ultracentrifugation or agarose gel electrophoresis as they differ in densities and electrophoretic mobility.<sup>2,18</sup> This cat initially had lipaemia indicating concurrent hypertriglyceridaemia, but TG levels were normal on subsequent fasted biochemical analyses. This could be explained by an exaggerated postprandial TG elevation in patients with FH vs normal individuals. This has not been studied in cats but is well described in humans. For example, CM and TG require the same receptors as LDL for catabolism.<sup>19</sup>

Studies on the medical treatment of feline cutaneous xanthoma are limited. Lipid-lowering drugs used in humans are not licensed in cats and there is only anecdotal evidence of their efficacy.<sup>20</sup> The drug classes used for humans are HMG-CoA reductase inhibitors (statins), bile acid sequestrants, nicotinic acid or niacin, fibric acid derivatives and cholesterol absorption inhibitors.<sup>21</sup> In animals, fish oils have also been administered with success.<sup>20</sup> However, because of this limited evidence, instigating dietary therapy is most important. A fatty meal will cause hypertriglyceridaemia,<sup>6</sup> and it is suspected that familial hyperlipidaemia is amplified by fatty dietary supplements.<sup>1</sup> Therefore, feeding a low-fat, high-fibre diet will help in reducing concentrations of plasma lipids.<sup>6</sup> After several months of strict dietary therapy in this cat, fasted cholesterol levels were markedly reduced. However, hypercholesterolaemia persisted, raising concerns for recurrence of xanthoma formation and hypercalcaemia. Further studies on lipid-lowering treatment in cats are warranted given the increasing reports of familial hyperlipidaemia in the cat population.

## Conclusions

This case report describes a cat that presented for the development of two masses, weight loss, inappetence and

vomiting. Diagnostic tests revealed hyperlipidaemia and hypercalcaemia. Calcium normalised following surgical resection of the masses. The cat was diagnosed with primary dyslipidaemia due to a condition such as FH and the masses were diagnosed as cutaneous xanthoma due to primary dyslipidaemia, which caused hypercalcaemia secondary to granulomatous inflammation. The cat's cholesterol levels remained elevated after transition to a lower-fat diet, but xanthoma reformation was not observed 8 months postoperatively at last contact. Ongoing monitoring of cholesterol was recommended. Cutaneous xanthoma causing hypercalcaemia, and FH itself, have not been reported in cats. Further studies of FH in cats are warranted to better describe the genetic characteristics of the disease. Cutaneous or systemic xanthomas should be considered in cases of hypercalcaemia.

**Acknowledgements** We would like to thank Dr Cecilia Barr for her diagnostic work-up and attentive care in managing this patient before her referral.


**Conflict of interest** The authors declared no potential conflicts of interest with respect to the research, authorship, and/or publication of this article.

**Funding** The authors received no financial support for the research, authorship, and/or publication of this article.

**Ethical approval** The work described in this manuscript involved the use of non-experimental (owned or unowned) animals. Established internationally recognised high standards ('best practice') of veterinary clinical care for the individual patient were always followed and/or this work involved the use of cadavers. Ethical approval from a committee was therefore not specifically required for publication in *JFMS Open Reports*. Although not required, where ethical approval was still obtained, it is stated in the manuscript.

**Informed consent** Informed consent (verbal or written) was obtained from the owner or legal custodian of all animal(s) described in this work (experimental or non-experimental animals, including cadavers) for all procedure(s) undertaken (prospective or retrospective studies). For any animals or people individually identifiable within this publication, informed consent (verbal or written) for their use in the publication was obtained from the people involved.

**ORCID iD** Doris Ma  <https://orcid.org/0000-0002-9508-9540>

Jessica F Romine  <https://orcid.org/0000-0002-7306-4115>

**Supplementary material** The following file is available online:

Table S1: Changes in serum cholesterol, triglyceride and calcium concentrations over the course of the cat's disease and after treatment.



## References

- 1 Vogelnest L. **Cutaneous xanthomas with concurrent demodicosis and dermatophytosis in a cat.** *Aust Vet J* 2001; 79: 470–475.
- 2 Wisselink MA, Koeman JP, Wensing T, et al. **Hyperlipoproteinaemia associated with atherosclerosis and cutaneous xanthomatosis in a cat.** *Vet Q* 1994; 16: 199–202.
- 3 Ravens P, Vogelnest L and Piripi S. **Unique presentation of normolipaeamic cutaneous xanthoma in a cat.** *Aust Vet J* 2013; 91: 460–463.
- 4 Santoro D, Prisco M and Ciaramella P. **Cutaneous sterile granulomas/pyogranulomas, leishmaniasis and mycobacterial infections.** *J Small Anim Pract* 2008; 49: 552–561.
- 5 Vogelnest LJ. **Skin as a marker of general feline health: cutaneous manifestations of systemic disease.** *J Feline Med Surg* 2017; 19: 948–960.
- 6 Jones BR. **Inherited hyperchylomicronaemia in the cat.** *J Small Anim Pract* 1993; 34: 493–499.
- 7 Chanut F, Colle MA, Deschamps JY, et al. **Systemic xanthomatosis associated with hyperchylomicronaemia in a cat.** *J Vet Med A Physiol Pathol Clin Med* 2005; 52: 272–274.
- 8 Massachusetts Society for the Prevention of Cruelty to Animals. **Xanthoma: the other fatty skin mass.** [https://www.mspca.org/angell\\_services/xanthoma-the-other-fatty-skin-mass/](https://www.mspca.org/angell_services/xanthoma-the-other-fatty-skin-mass/) (accessed 25 August, 2021)
- 9 Hoekstra K, Nichols C, Garnett M, et al. **Dietary cholesterol-induced xanthomatosis in atherosclerosis-susceptible Japanese quail (*Coturnix japonica*).** *J Comp Pathol* 1998; 119: 419–427.
- 10 van Ree JH, Gijbels MJ, van den Broek WJ, et al. **Atypical xanthomatosis in apolipoprotein E-deficient mice after cholesterol feeding.** *Atherosclerosis* 1995; 112: 237–243.
- 11 Gumbrell RC. **A case of multiple xanthomatosis and diabetes mellitus in a dog.** *N Z Vet J* 1972; 20: 240–242.
- 12 Chastain C and Graham C. **Xanthomatosis secondary to diabetes mellitus in a dog.** *J Am Vet Med Assoc* 1978; 172: 1209–1211.
- 13 Banajee KH, Orandle MS, Ratterree W, et al. **Idiopathic solitary cutaneous xanthoma in a dog.** *Vet Clin Pathol* 2011; 40: 95–98.
- 14 Ghaffari MS. **Iatrogenic hyperlipidemia associated with lipid-laden aqueous humor in a cat following administration of megestrol acetate.** *Turk J Vet Anim Sci* 2008; 32: 399–401.
- 15 Jones BR, Wallace A, Hancock W, et al. **Cutaneous xanthomata associated with diabetes mellitus in a cat.** *J Small Anim Pract* 1985; 26: 33–41.
- 16 Negri AL, Rosa Diez G, Del Valle E, et al. **Hypercalcemia secondary to granulomatous disease caused by the injection of methacrylate: a case series.** *Clin Cases Miner Bone Metab* 2014; 11: 44–48.
- 17 Soutar AK and Naoumova RP. **Mechanisms of disease: genetic causes of familial hypercholesterolemia.** *Nat Clin Pract Cardiovasc Med* 2007; 4: 214–225.
- 18 Bauer JE. **Lipoprotein-mediated transport of dietary and synthesized lipids and lipid abnormalities of dogs and cats.** *J Am Vet Med Assoc* 2004; 224: 668–675.
- 19 Kolovou GD, Anagnostopoulou KK, Damaskos DS, et al. **Gender influence on postprandial lipemia in heterozygotes for familial hypercholesterolemia.** *Ann Clin Lab Sci* 2007; 37: 335–342.
- 20 Jones BR. **Hyperlipidaemia in dogs and cats.** Proceedings of the World Small Animal Veterinary Association World Congress; 24–27 October 2003; Bangkok, Thailand. <https://www.vin.com/apputil/content/defaultadv1.aspx?pId=8768&meta=generic&catId=18823&id=3850075> (2003, accessed 22 February 2022).
- 21 Lin Y, Mousa SS, Elshourbagy N, et al. **Current status and future directions in lipid management: emphasizing low-density lipoproteins, high-density lipoproteins, and triglycerides as targets for therapy.** *Vasc Health Risk Manag* 2010; 6: 73–85.