



## **Negative pressure wound therapy over two ipsilateral external skeletal fixators for management of high grade open fractures in a cat**

Authors: Karpozilou, Athina, Frykfors von Hekkel, Anna, and Phillips, Andrew

Source: Journal of Feline Medicine and Surgery Open Reports, 8(1)

Published By: SAGE Publishing

URL: <https://doi.org/10.1177/20551169221092654>

---

BioOne Complete ([complete.BioOne.org](https://complete.BioOne.org)) is a full-text database of 200 subscribed and open-access titles in the biological, ecological, and environmental sciences published by nonprofit societies, associations, museums, institutions, and presses.

Your use of this PDF, the BioOne Complete website, and all posted and associated content indicates your acceptance of BioOne's Terms of Use, available at [www.bioone.org/terms-of-use](https://www.bioone.org/terms-of-use).

Usage of BioOne Complete content is strictly limited to personal, educational, and non - commercial use. Commercial inquiries or rights and permissions requests should be directed to the individual publisher as copyright holder.

---

BioOne sees sustainable scholarly publishing as an inherently collaborative enterprise connecting authors, nonprofit publishers, academic institutions, research libraries, and research funders in the common goal of maximizing access to critical research.



# Negative pressure wound therapy over two ipsilateral external skeletal fixators for management of high grade open fractures in a cat

*Journal of Feline Medicine and Surgery Open Reports*  
1–8

© The Author(s) 2022

Article reuse guidelines:

sagepub.com/journals-permissions

DOI: 10.1177/20551169221092654

journals.sagepub.com/home/jfmsopenreports

This paper was handled and processed

by the European Editorial Office (ISFM)

for publication in *JFMS Open Reports*



Athina Karpozilou<sup>1,2</sup> , Anna Frykfors von Hekkel<sup>3</sup>   
and Andrew Phillips<sup>1,3</sup>

## Abstract

**Case summary** A 7-month-old female neutered Bengal cat was referred to the Queen Mother Hospital for Animals following unknown trauma. Clinical and radiographic examination revealed a grade IIIB open, comminuted, mid-diaphyseal fracture of the left tibia and fibula, and grade IIIB open mid-diaphyseal fractures of the left metatarsals II–V. The fractures were stabilised with tibial and metatarsal external skeletal fixators. The open wounds were initially debrided surgically using conventional dressings, resulting in a small amount of circumferential granulation tissue formation by 10 days postoperatively. Following this 10-day period of conventional wound management, negative pressure wound therapy (NPWT) was applied over the external skeletal fixators and wounds. After 8 days of NPWT complete granulation tissue coverage was achieved in the tibial wound, and only small areas of two metatarsals remained exposed. The tibial wound was left to heal by second intention; a free meshed skin graft was applied to the pedal wound. Twenty weeks postoperatively, all wounds had completely healed and revision surgery with internal fixation was performed to treat a non-union of the tibia. Thirty weeks after the initial surgery, radiographic union of the tibia and metatarsals II–IV was confirmed.

**Relevance and novel information** This is the first report of NPWT application over external fixation for the management of wounds associated with open fractures in veterinary medicine. This case was presented to introduce a novel, well-tolerated and simple technique for the management of tissue loss over an open fracture immobilised with external fixation.

**Keywords:** NPWT; wound healing; external skeletal fixation; open fracture; vacuum-assisted closure; trauma

**Accepted:** 21 March 2022

## Introduction

Open fractures are a combination of soft tissue and orthopaedic injuries resulting in environmental contamination of bone.<sup>1</sup> Open fractures are classified into three types, according to the modified Gustilo-Anderson classification scheme.<sup>1,2</sup> In type I open fractures, the soft tissue wound is <1 cm long, usually a moderately clean puncture created from the inside out. In type II open fractures, the wound is >1 cm long, without excessive soft tissue damage, typically created from the outside. Type III open fractures encompass extensive soft tissue damage and significant contamination, and typically the fracture is comminuted and unstable. The variable prognosis of type III open fractures led to

further subclassification.<sup>1,3</sup> Type IIIA is characterised by adequate soft tissue coverage of the fractured bone, despite high energy trauma, or extensive laceration or skin flaps, type IIIB by extensive soft tissue injury with periosteal stripping and osseous exposure, and type IIIC by arterial injury requiring repair.

<sup>1</sup>Eastcott Veterinary Referrals, Swindon, UK

<sup>2</sup>Southern Counties Veterinary Specialists, Ringwood, UK

<sup>3</sup>Royal Veterinary College, Queen Mother Hospital, Hatfield, UK

### Corresponding author:

Athina Karpozilou DVM, MRCVS, Eastcott Veterinary Referrals, Edison Park, off Hindle Way, Dorcan Way, Swindon SN3 3FR, UK  
Email: athinakarp@yahoo.gr



Creative Commons Non Commercial CC BY-NC: This article is distributed under the terms of the Creative Commons

Attribution-NonCommercial 4.0 License (<https://creativecommons.org/licenses/by-nc/4.0/>) which permits non-commercial use, reproduction and distribution of the work without further permission provided the original work is attributed as specified on the SAGE and Open Access pages (<https://us.sagepub.com/en-us/nam/open-access-at-sage>).

Negative pressure wound therapy (NPWT) was first described in feline veterinary medicine by Owen et al in 2009.<sup>4</sup> The technique entails applying open cell foam to a wound, then sealing the area with an adhesive drape to allow sub-atmospheric pressure to be created over the wound.<sup>5</sup> NPWT has been shown to promote granulation tissue formation, encourage neovascularisation and decrease bacterial counts when used with appropriate sub-atmospheric pressure, namely  $-125$  mmHg.<sup>5,6</sup>

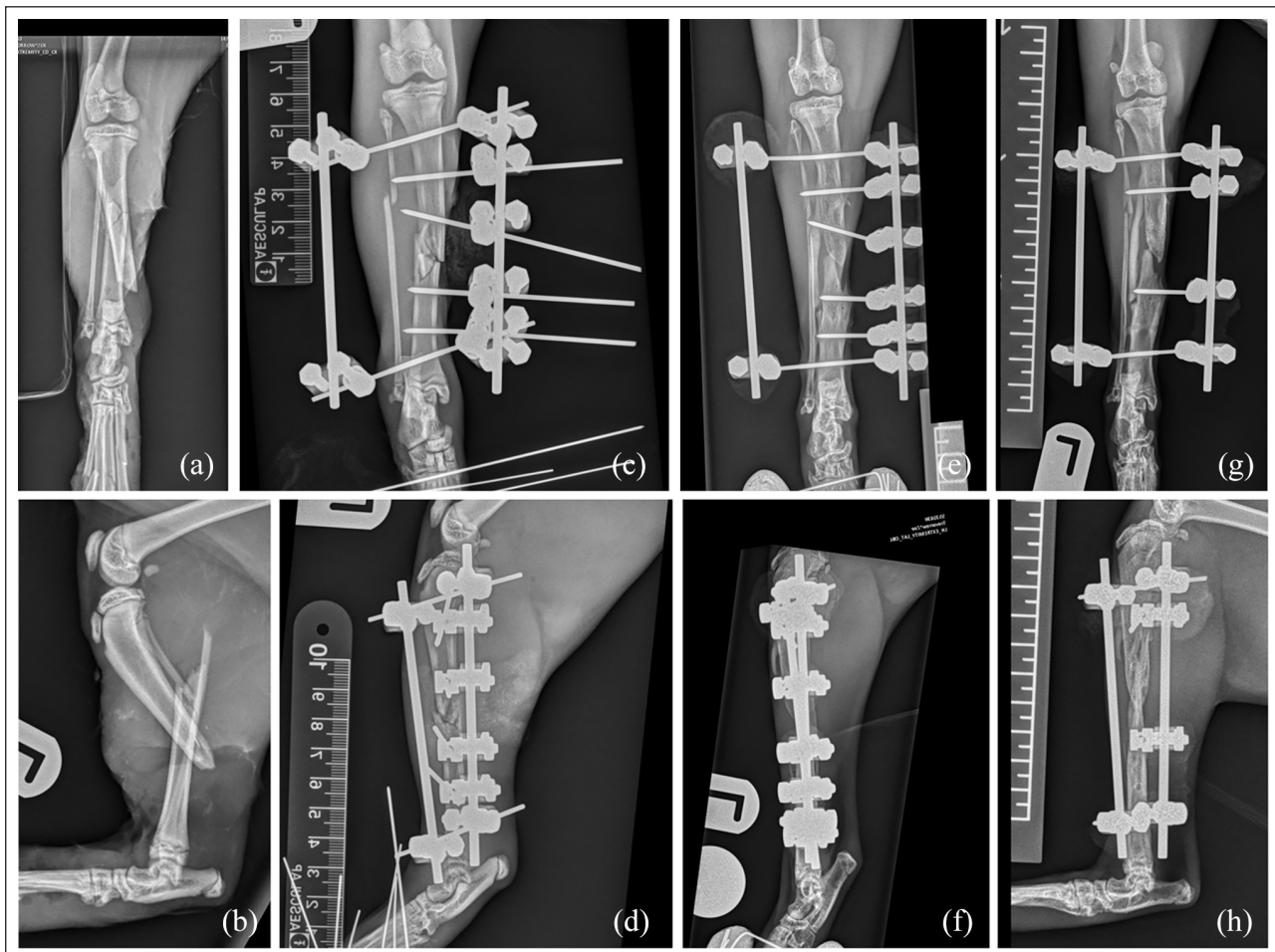
This is the first case report to describe surgical stabilisation of grade IIIB open fractures with external skeletal fixation followed by NPWT application over the ESFs for management of extensive wounds.

### Case description

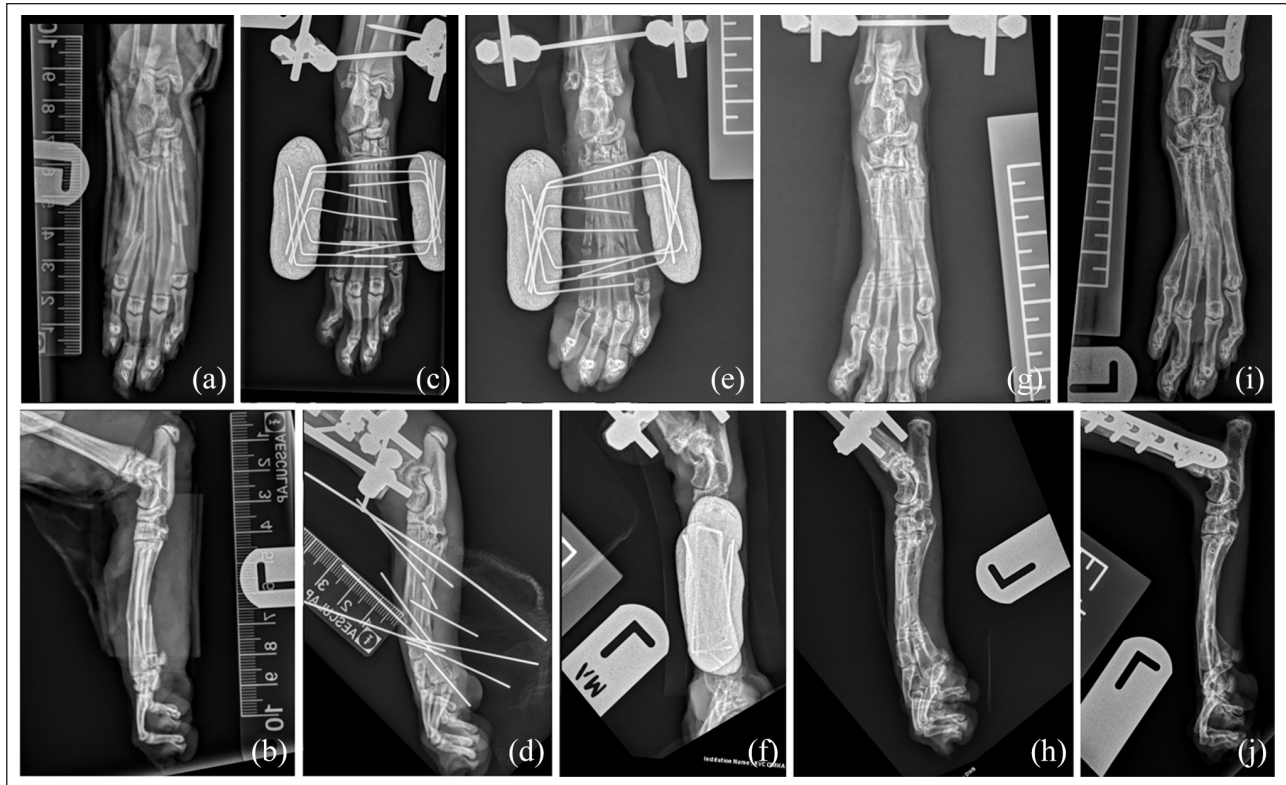
A 7-month-old female neutered Bengal cat was referred to the Queen Mother Hospital for Animals following unknown trauma that had occurred the same day. Clinical examination revealed non-weightbearing left pelvic limb lameness secondary to two grade IIIB open fractures. A left, comminuted, mid-diaphyseal tibial fracture was present, with a  $35 \times 23$  mm soft tissue defect on the medial aspect of the crus, resulting in exposure and contamination of the fracture site. Ipsilateral

mid-diaphyseal fractures of metatarsals II–V were also present, with a  $60 \times 30$  mm wound on the dorsolateral pes. Nociception and vascularity were intact. The remainder of the examination was unremarkable.

The cat was initially treated with methadone ( $0.2$  mg/kg IV q4h [Synthadon; Animalcare]), amoxicillin–clavulanate ( $20$  mg/kg IV q8h [Augmentin; GlaxoSmithKline]) and intravenous fluid therapy ( $2$  ml/kg/h [Hartmanns; Dechra]). The wounds were lavaged using  $6$  l sterile saline (Hartmanns; Dechra). Bacteriology samples were then taken to identify residual contamination, and sterile dressings (Primapore; Smith & Nephew) were applied. Venous blood gas analysis was unremarkable aside from mild respiratory acidosis, hyperkalaemia (potassium  $5.0$  mmol/l, reference interval [RI]  $3.6$ – $4.6$ ), hypercalcaemia (calcium  $1.41$  mmol/l; RI  $1.13$ – $1.33$ ) and hyperglycaemia (glucose  $11.9$  mmol/l; RI  $4.7$ – $7.3$ ). Thoracic radiographs revealed a small-volume pneumothorax, which was treated conservatively. Pelvic limb radiographs confirmed left tibial and metatarsal fractures as previously described and a mid-diaphyseal fibular fracture (Figure 1a,b; Figure 2a,b). Abdominal and thoracic-focused assessment with ultrasonography for trauma was performed and was unremarkable.



**Figure 1** The tibial and fibula fracture: (a,b) on presentation; (c,d) immediately after initial surgical stabilisation with a modified type 2 external skeletal fixator; (e,f) 16 weeks postoperatively; and (g,h) 20 weeks postoperatively



**Figure 2** The metatarsal fractures: (a,b) on presentation; (c,d) immediately after initial surgical stabilisation with a modified type 2 freeform external skeletal fixator (ESF); (e,f) 6 weeks postoperatively; (g,h) 16 weeks postoperatively, after removal of the metatarsal ESF; and (i,j) 30 weeks postoperatively

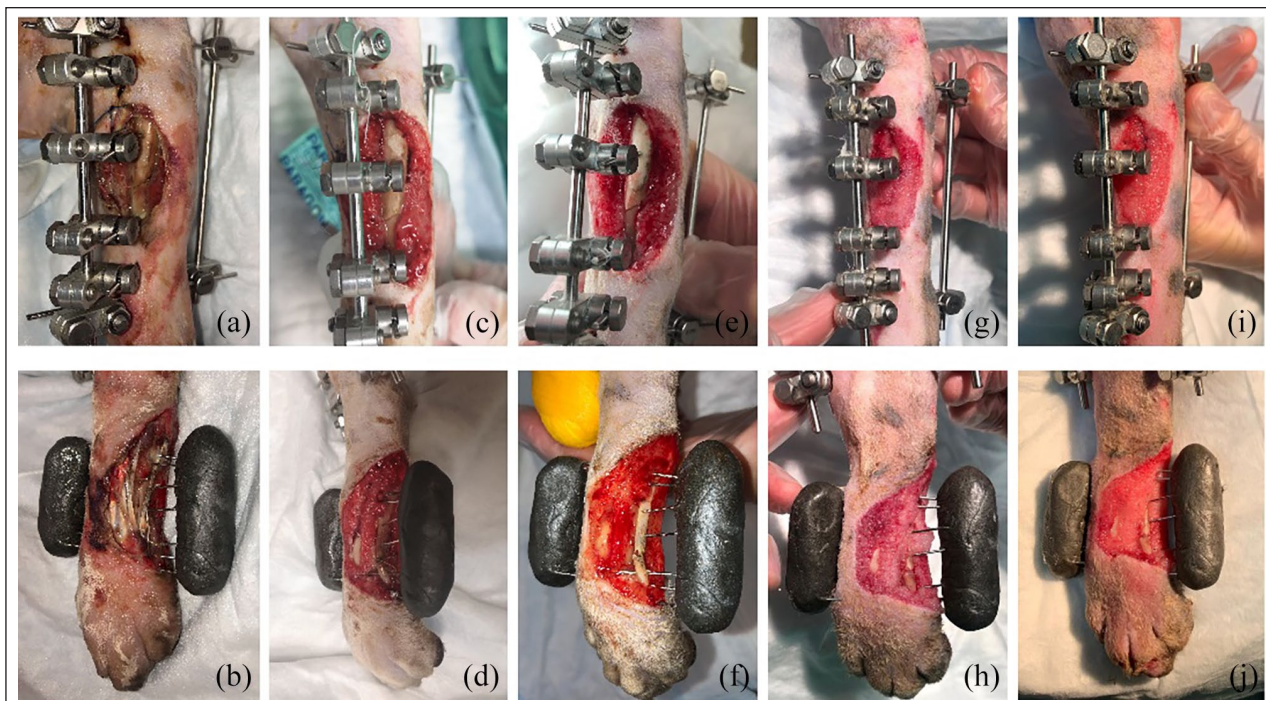
Fracture repair was pursued under general anaesthesia (GA) 36 h after presentation. Anaesthetic protocol included methadone (0.2 mg/kg IV [Synthadon; Animalcare]) and medetomidine (0.005 mg/kg IV [Sedator; Dechra]), ketamine (0.5 mg/kg IV [Anesketin; Dechra]) and alfaxalone (1.8 mg/kg IV [Alfaxan; Jurox]) coinduction. A bupivacaine (2 mg/kg, up to a total volume of 0.8 ml per site [Marcaïn 0.5%; Aspen]) femoral and sciatic nerve block was performed to achieve circumferential locoregional anaesthesia of the crus and pes. The tibial fracture was stabilised with a modified bilateral uniplanar (modified type 2) ESF (Figure 1c,d; Figure 3a,c,e,g,i). The metatarsal fractures were stabilised with a modified type 2 freeform ESF (Figure 2c,d; Figure 3b,d,f,h,j). The wounds were surgically debrided and lavaged, bacteriology samples were taken and wet-to-dry dressings were placed. Microbial culture following surgical debridement and lavage isolated *Bacillus* species, *Acinetobacter* species and a third, unidentified isolate; a course of amoxicillin–clavulanate (20 mg/kg q12h [Kesium; Ceva]) and pradofloxacin (5.5 mg/kg q24h [Veraflox; Bayer]) was required to ensure susceptibility of all isolates. Antibiotics were discontinued when all wounds were covered with granulation tissue.

Ongoing open wound management consisted of daily surgical layered debridement and replacement of

wet-to-dry dressings, which were changed to a foam dressing (Allevyn; Smith&Nephew) with hydrocolloid gel (Intrasite; Smith&Nephew) when no devitalised tissue remained. After 10 days of wound management, both wounds had a small amount of healthy granulation tissue circumferentially in the periphery of the wound, but there was minimal evidence of wound contracture or epithelialisation and large areas of tibial and metatarsal bone remained exposed (Figure 3e,f).

Ten days postoperatively, forage of the exposed tibial diaphysis, partial apposition of the cranial and caudal musculature within the tibial wound, and placement of NPWT was performed under GA using the same aforementioned protocol. Under aseptic conditions the ESF bars and pins were padded with cohesive bandage (VetWrap; 3M). Black polyurethane foam (400–600 µm pore size) was applied to the cranial and caudal aspect of the limb, including the wounds and incorporating both ESFs, from the pes to the level of the proximal tibia. The construct was sealed with adhesive polyurethane film (Opsite; Smith&Nephew). Continuous negative pressure (–125 mmHg) was applied. The dressing was replaced at 48–84 h intervals (Figure 4), totalling 8 days of NPWT.

At cessation of NPWT, the tibial wound was completely covered by healthy granulation tissue (35 × 15 mm;



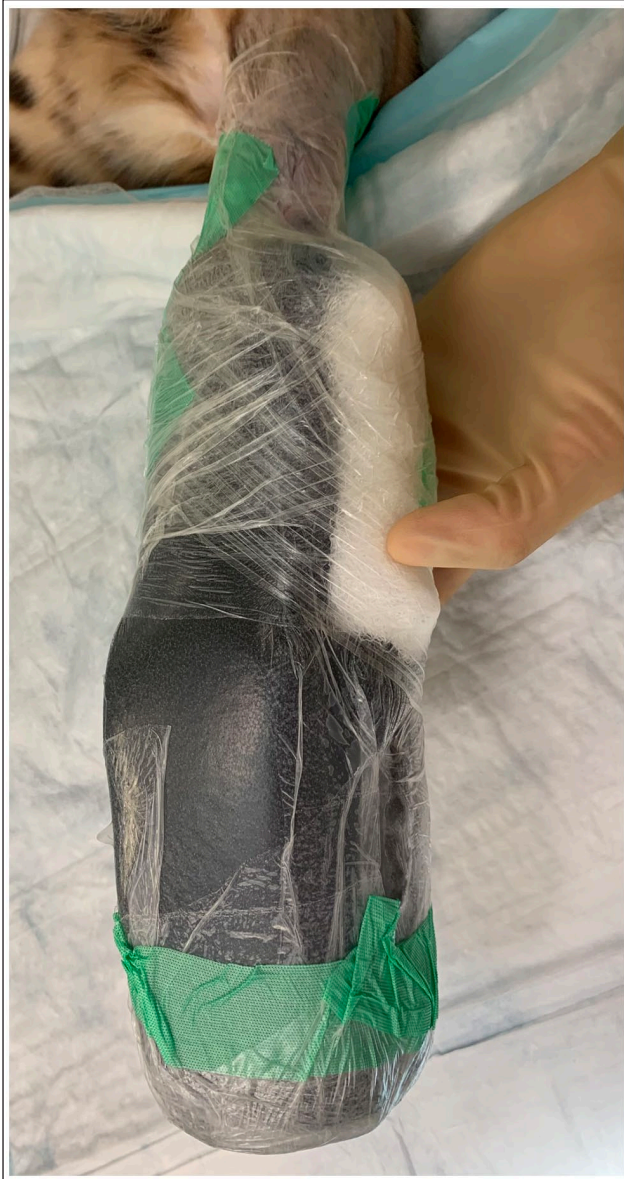**Figure 3** The tibial and pes wounds: (a,b) immediately after surgical stabilisation, wound debridement and lavage with sterile saline. The metatarsal fracture was stabilised with a freeform external skeletal fixator where putty was used instead of connecting bars. (c,d) After 7 days of conventional dressings (consisting of wet-to-dry dressings, which were switched to hydrocolloid gel and polyurethane foam as soon as all devitalised tissue was removed); (e,f) after 10 days of conventional dressing, prior to application of negative pressure wound therapy (NPWT); (g,h) after 6 days of NPWT; and (i,j) after 8 days of NPWT, cessation of NPWT

Figure 3i). This wound was left open to heal by second intention. Healthy granulation tissue was present throughout the pes wound (55 × 30 mm), although a small portion of metatarsals III and V remained exposed (2 × 8 mm and 3 × 16 mm, respectively; Figure 3j). Hydrogel (Intrasite gel; Smith&Nephew) and foam (Allevyn; Smith&Nephew) dressing was applied over this wound, and was replaced twice within 11 days. At that stage, granulation tissue covered the entirety of the wound, while the size of the wound remained unchanged. A free meshed skin graft from the left flank was used for closure. The graft was covered with paraffin gauze (Jelonet; Smith&Nephew) and polyurethane foam (Allevyn; Smith&Nephew). The dressing was changed three times in 14 days.

Six weeks after admission, a weightbearing left pelvic limb lameness was present (4/10), with reduced tarsal range of motion, attributed to prolonged immobilisation. The graft donor site wound and the tibial wound were fully healed and there was 100% graft take (Figure 5). The cat was discharged with instructions to continue crate rest, with short periods of controlled exercise (5 mins, 3–5 times daily, increasing by 5 mins each fortnight), as well as continued monitoring of the skin graft site and ESFs.

The cat was re-examined 16 weeks after the initial surgery. A 4/10 left pelvic limb lameness remained. Radiographs revealed delayed union of the tibial fracture (Figure 1e,f), functional malunions of metatarsals II–IV and an atrophic non-union of metatarsal V. After the cat was anaesthetised with the same protocol as previously described, the metatarsal ESF was removed (Figure 2g,h) and two loose pins from the tibial ESF were removed. A Jamshidi needle biopsy sample from the distal tibial fragment and a pin tip from the metatarsal ESF were submitted for microbial culture, which were both negative.

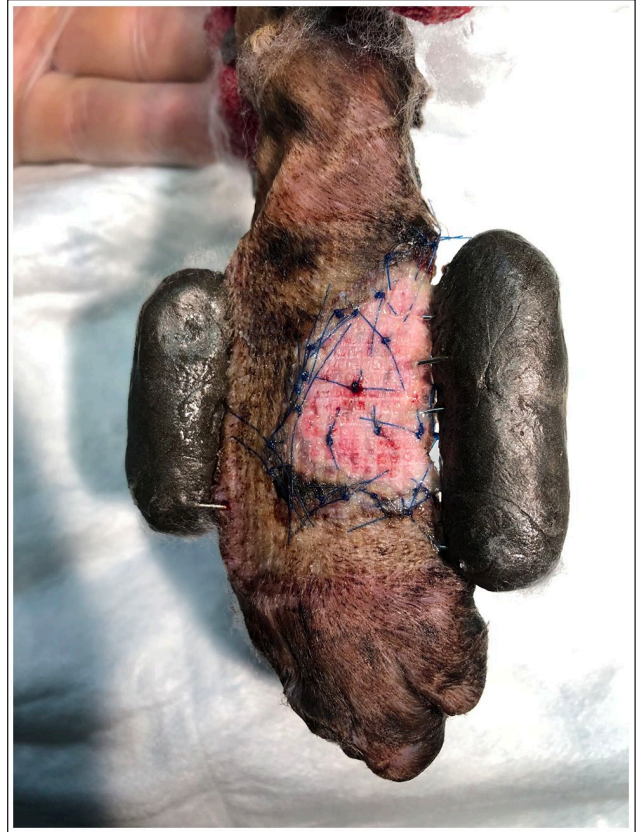Twenty weeks postoperatively, repeat radiographs of the tibia confirmed non-union of the tibia; thus, revision surgery was performed (Figure 1g,h). The tibial ESF was removed. Autologous bone graft was harvested from the left ilial wing. Following transverse osteotomies of the tibial and fibular fracture margins to reopen the medullary canals and allow a transverse surface for compression, the graft was applied to the fracture site and the tibia was stabilised with a medially positioned 2.7 mm locking compression plate (LCP; Synthes) placed in load (Figure 6a,b). Histopathology (for completeness) of the osteotomised fracture margins revealed immature callus and bone remodelling, and culture was negative.



**Figure 4** Negative pressure wound therapy in situ at day 10 postoperatively. The black polyurethane foam was applied over the cranial and caudal aspect of the limb to cover both wounds. The external skeletal fixator bars and pins were padded (the lateral bar with a white dressing). From the pes to the level of the proximal tibia was sealed with adhesive polyurethane film, the leading edge of this polyurethane film was green, the majority was the visible colourless film applied over the limb

The cat was discharged 5 days postoperatively with meloxicam (0.05 mg/kg q24h PO [Metacam; Boehringer Ingelheim]), restricted exercise and a physiotherapy plan.

Re-examination of the cat 10 weeks after internal fixation (30 weeks after trauma) showed a 3/10 left pelvic limb lameness. Both tarsus and stifle had full range of motion. Radiographs revealed radiographic union of



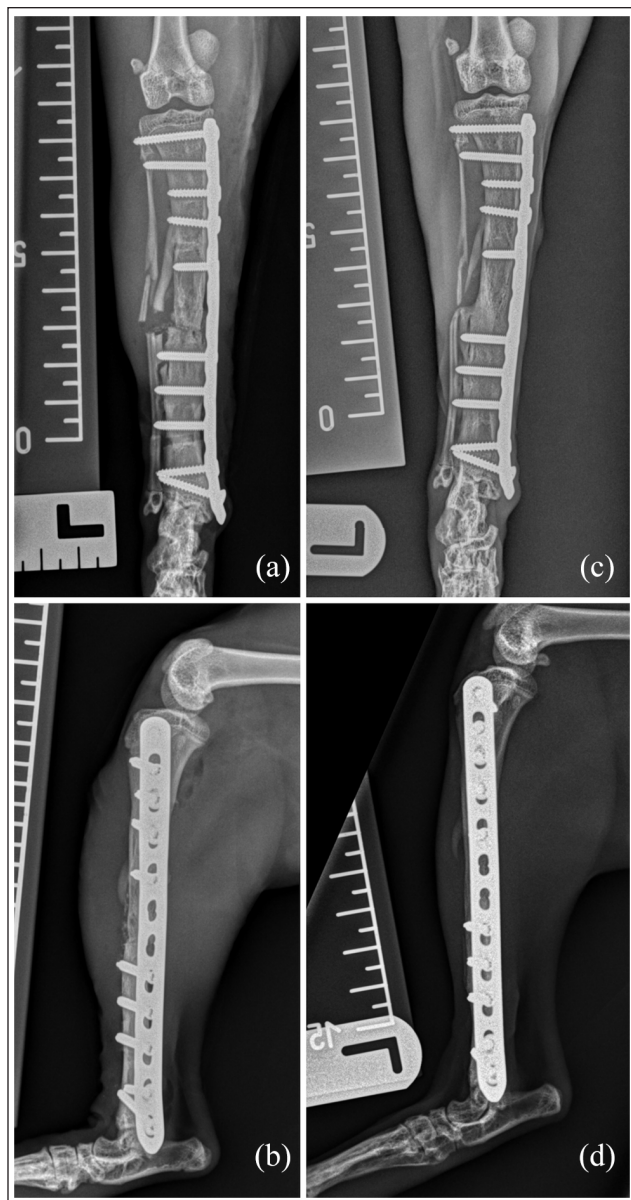
**Figure 5** Complete take of the free meshed skin graft applied to the pes wound, 10 days post-skin graft procedure, 6 weeks post-injury

the tibial fracture; the radiographic appearance of the pes was unchanged from the previous description (Figure 6c,d; Figure 2i,j). Gradual return to normal exercise was recommended.

## Discussion

This case report describes the application of NPWT over external skeletal fixation for open fracture management. This innovative technique to manage tissue damage in high-grade open fractures can be considered to aid the management of such cases, which often represent significant clinical challenges.

The combination of external skeletal fixation with NPWT coincided with a marked increase in granulation tissue production (presumably by stimulating the proliferation of granulation tissue and accelerating the maturation of the existing granulation tissue, and subjectively improving the vascularity of the granulation tissue), resulting in a marked reduction in the size of the open wounds and potentially contributed to the resolution of infection in a challenging situation.<sup>7</sup> This contrasts with the minimal progression of the granulation tissue bed while conventional dressings were being



**Figure 6** The tibial fracture: (a,b) immediately after revision surgery with internal fixation (20 weeks post-initial surgery) and (c,d) 10 weeks post-revision surgery, 30 weeks post-initial surgery. The radiographically apparent patella luxation was not clinically appreciable in the conscious cat

used. After 8 days of NPWT, granulation tissue covered the entirety of the tibial wound and the majority of the pes wound. Complete granulation tissue coverage of these large, traumatically created wounds was achieved after 18 days, which compares favourably with an experimental feline study, which found that granulation tissue coverage of a 2 × 2 cm surgically created wound took a median of 18 days when using non-adhesive, semi-occlusive dressings.<sup>8</sup> Given the known delay in feline granulation tissue formation, it is possible that the improvement seen from day 10 onwards would have

happened regardless (ie, with continued use of conventional dressings and without use of NPWT); however, the dramatic improvement in wound health and volume of granulation tissue formation over a short time period support a positive effect of NPWT.<sup>7,8</sup> It has been documented that NPWT can increase the granulation rate between 60% and 200%.<sup>7</sup> In this case, NPWT may also have contributed to early coverage of the bones, which is essential for bone viability and allowed skin graft application to the pes wound. While not used in this case, NPWT has also been shown to facilitate graft 'take', especially in three-dimensional wounds.<sup>7</sup>

Due to the amount of necrotic tissue present, application of NPWT at presentation would have been inappropriate; however, NPWT could have been applied sooner than 10 days postoperatively.<sup>7</sup> More conventional wound management was pursued initially due to a lack of supporting veterinary literature for the use of NPWT with external skeletal fixation and what transpired to be unfounded concerns of difficulty in maintaining negative pressure over both ESFs. Indeed, the NPWT could have been continued for longer over the pes wounds, potentially further expediting wound closure. The decision to return to conventional dressing was due to a combination of factors, including cost, the ability to apply a less substantial dressing to improve mobility and the tolerance of conscious dressing changes at this stage.

Open fracture management remains controversial. A surgical approach distant to the wound is often used in complex or open fractures to avoid jeopardising already compromised soft tissue and 'extraosseous' blood supply, which is crucial for healing.<sup>9</sup> An ESF, for example, also negates the need for internal implants in the face of gross contamination, which, in this instance, was deemed most appropriate. Complications associated with open fracture healing, particularly in the feline tibia, have been documented.<sup>10</sup> Several predisposing factors for non-union were present in this case, specifically the fracture being open, comminuted and contaminated.<sup>10</sup> Furthermore, tibial diaphyseal fractures stabilised with an ESF have been reported to result in higher complication rates than those treated with open reduction and internal fixation, although there may be a degree of selection bias in these cases.<sup>10,11</sup>

Given the severity of osseous and soft tissue injuries, amputation at presentation was considered and offered. In this context, salvaging a fully functional limb in the long term is considered an excellent outcome, despite the major complication of the tibial non-union. It is our hypothesis that using external skeletal fixation and specifically NPWT contributed to the maintenance and improvement of the 'extraosseous' blood supply and accelerated the granulation tissue coverage, improving the wounds and supporting bone viability. Numerous human studies

support this technique for high-grade open fracture management.<sup>12–18</sup> In many human cases the NPWT dressing was placed underneath the ESF; however, spatial constraints prohibit this in felines. The technique applied in this case has also been described in a human case report, where it was reported to achieve significant granulation tissue formation in 8 days with no complications.<sup>19</sup>

In addition to inherent limitations associated with case reports, the large number of variables associated with wounds and their management, lack of a control in this instance and the impossibility to standardise clinical wounds make drawing comparisons difficult. Furthermore, there are availability and upfront cost issues associated with NPWT. Further research is required to investigate the potential benefit of NPWT in these situations and to refine treatment recommendations.

## Conclusions

The application of NPWT over a ESF is a feasible, simple, highly practical and well-tolerated technique that can be used for management of soft tissue loss in high-grade open fractures in cats. This technique aided the management of significant soft tissue injuries, potentially accelerated granulation tissue formation, resolution of infection and hastened bone coverage leading to a good overall outcome. The combination of NPWT and external skeletal fixation has been used for the management of high-grade open fractures in human surgery; more research is required to quantify outcomes and make management recommendations for its use in feline fracture management.

**Acknowledgements** The authors are grateful for the dedication of the Queen Mother Hospital for Animals nursing team, and to Richard Meeson and Jayson Tuan for clinical contributions to the case.

**Conflict of interest** The authors declared no potential conflicts of interest with respect to the research, authorship, and/or publication of this article.

**Funding** The authors received no financial support for the research, authorship, and/or publication of this article.


**Ethical approval** The work described in this manuscript involved the use of non-experimental (owned or unowned) animals. Established internationally recognised high standards ('best practice') of veterinary clinical care for the *individual* patient were always followed and/or this work involved the use of cadavers. Ethical approval from a committee was therefore not specifically required for publication in *JFMS Open Reports*. Although not required, where ethical approval was still obtained, it is stated in the manuscript.

**Informed consent** Informed consent (verbal or written) was obtained from the owner or legal custodian of all animal(s) described in this work (experimental or non-experimental

animals, including cadavers) for all procedure(s) undertaken (prospective or retrospective studies). No animals or people are identifiable within this publication, and therefore additional informed consent for publication was not required.

**ORCID iD** Athina Karpozilou  <https://orcid.org/0000-0001-5356-6073>

Anna Frykfors von Hekkel  <https://orcid.org/0000-0003-4521-7361>

Andrew Phillips  <https://orcid.org/0000-0001-8584-1033>

## References

- 1 Tobias KM and Johnston SA. **Veterinary surgery small animal**. In: Millard RP and Towle HA (eds). Open fractures. St Louis, MO: Saunders Elsevier, 2012, pp 572–575.
- 2 Gustilo RB, Merkow RL and Templeman D. **The management of open fractures**. *J Bone Joint Surg Am* 1990; 72: 299–304.
- 3 Gustilo RB, Mendoza RM and Williams DN. **Problems in the management of type III (severe) open fractures: a new classification of type III open fractures**. *J Trauma* 1984; 24: 742–746.
- 4 Owen L, Hotston-Moore A and Holt P. **Vacuum-assisted wound closure following urine-induced skin and thigh muscle necrosis in a cat**. *Vet Comp Orthop Traumatol* 2009; 22: 417–421.
- 5 Morykwas MJ, Argenta LC, Shelton-Brown EI, et al. **Vacuum-assisted closure: a new method for wound control and treatment: animal studies and basic foundation**. *Ann Plast Surg* 1997; 38: 553–562.
- 6 Morykwas MJ, Falser BJ, Pearce DJ, et al. **Effects of varying levels of subatmospheric pressure on the rate of granulation tissue formation in experimental wounds in swine**. *Ann Plast Surg* 2001; 47: 547–551.
- 7 Nolff MC. **Filling the vacuum: role of negative pressure wound therapy in open wound management in cats**. *J Feline Med Surg* 2021; 23: 823–883.
- 8 Bohling MW, Henderson RA, Swaim SF, et al. **Cutaneous wound healing in the cat: a macroscopic description and comparison with cutaneous wound healing in the dog**. *Vet Surg* 2004; 33: 579–587.
- 9 Corr S. **Complex and open fractures: a straightforward approach to management in the cat**. *J Feline Med Surg* 2012; 14: 55–64.
- 10 Nolte DM, Fusco JV and Peterson ME **Incidence of and predisposing factors for nonunion of fractures involving the appendicular skeleton in cats: 18 cases (1998–2002)**. *J Am Vet Med Assoc* 2005; 226: 77–82.
- 11 Perry KL and Bruce M. **Impact of fixation method on post-operative complication rates following surgical stabilization of diaphyseal tibial fractures in cats**. *Vet Comp Orthop Traumatol* 2015; 28: 109–115.
- 12 Sun D, Ju W, Wang T, et al. **Vacuum sealing drainage therapy in the presence of an external fixation device: a case report**. *Medicine* 2016; 95: e5444. DOI: 10.1097/MD.0000000005444.
- 13 Caputo G, Marchetti A, Governa M, et al. **A novel inexpensive technique to seal negative pressure wound therapy on external fixation devices**. *J Orthop Trauma* 2019; 33: e24–e26.



- 14 Bulla A, Farace F, Uzel AP, et al. **Negative pressure wound therapy and external fixation device: a simple way to seal the dressing.** *J Orthop Trauma* 2014; 28: e176–e177.
- 15 Bao T, Fang H, Xu F, et al. **Papineau technique combined with vacuum-assisted closure for open tibial fractures: clinical outcomes at five years.** *Int Orthop* 2017; 41: 2389–2396.
- 16 Babiak I. **Open tibial fractures grade IIIC treated successfully with external fixation, negative-pressure wound therapy and recombinant human bone morphogenetic protein 7.** *Int Wound J* 2014; 11: 476–482.
- 17 Liu L, Tan G, Luan F, et al. **The use of external fixation combined with vacuum sealing drainage to treat open comminuted fractures of tibia in the Wenchuan earthquake.** *Int Orthop* 2012; 36: 1441–1447.
- 18 Angelis S, Apostolopoulos A, Kosmas L, et al. **The use of vacuum closure-assisted device in the management of compound lower limb fractures with massive soft tissue damage.** *Cureus* 2019; 11: e5104. DOI: 10.7759/cureus.5104.
- 19 Ozer K and Smith W. **A simple technique for applying vacuum-assisted closure therapy over the circular type external fixation device.** *Ann Plast Surg* 2006; 56: 693–694.