



## Fluoxetine-induced urinary retention in a cat

Authors: DiCiccio, Victoria K, and McClosky, Megan E

Source: Journal of Feline Medicine and Surgery Open Reports, 8(2)

Published By: SAGE Publishing

URL: <https://doi.org/10.1177/20551169221112065>

---

BioOne Complete ([complete.BioOne.org](https://complete.BioOne.org)) is a full-text database of 200 subscribed and open-access titles in the biological, ecological, and environmental sciences published by nonprofit societies, associations, museums, institutions, and presses.

Your use of this PDF, the BioOne Complete website, and all posted and associated content indicates your acceptance of BioOne's Terms of Use, available at [www.bioone.org/terms-of-use](https://www.bioone.org/terms-of-use).

Usage of BioOne Complete content is strictly limited to personal, educational, and non - commercial use. Commercial inquiries or rights and permissions requests should be directed to the individual publisher as copyright holder.

---

BioOne sees sustainable scholarly publishing as an inherently collaborative enterprise connecting authors, nonprofit publishers, academic institutions, research libraries, and research funders in the common goal of maximizing access to critical research.



# Fluoxetine-induced urinary retention in a cat

Victoria K DiCiccio and Megan E McClosky

*Journal of Feline Medicine and Surgery Open Reports*  
1–5

© The Author(s) 2022

Article reuse guidelines:

sagepub.com/journals-permissions

DOI: 10.1177/20551169221112065

journals.sagepub.com/home/jfmsopenreports

This paper was handled and processed by the American Editorial Office (AAFP) for publication in *JFMS Open Reports*



## Abstract

**Case summary** A 2-year-old neutered male domestic shorthair cat presented for a history of several weeks of infrequent urination and hyporexia progressing to anorexia. The cat had been normal prior to being placed on fluoxetine to treat inter-cat aggression, after which it began to display weight loss, hyporexia and abnormal urination habits. The cat had been seen by various veterinary hospitals previously and treated for suspected feline lower urinary tract disease. When the patient still had urinary retention despite perineal urethrostomy surgery, it was presented for ongoing care. Contrast urethrograms showed a mild questionable proximal ureteral narrowing, but other diagnostics were unremarkable. The patient was trialed on various medications, including alpha-antagonists, cholinergics, non-steroidal anti-inflammatory drugs and different analgesics with no improvement, but would reproducibly urinate only following administration of midazolam intravenously. Ultimately, the cat began urinating normally following the discontinuation of fluoxetine. The cat was urinating normally upon discharge, and when it presented for another complaint several months later, its weight, appetite and urination habits were normal.

**Relevance and novel information** Fluoxetine is a commonly utilized medication in behavioral medicine. Despite its common use and reports of urinary retention secondary to this medication in humans, this potential side effect is not reported in various veterinary pharmacologic textbooks or the veterinary literature. To our knowledge, this is the first report in veterinary medicine to describe urinary retention suspected to be secondary to prolonged administration of fluoxetine at an excessive dose.

**Keywords:** Urinary retention; fluoxetine; serotonin selective reuptake inhibitor; FLUTD

**Accepted:** 18 June 2022

## Introduction

Urinary retention (UR) is the inability to completely empty the bladder and is a frequently encountered problem in human and veterinary medicine. UR can be caused by various diseases, including obstruction (ie, calculi, stricture and neoplasia), infectious or inflammatory disease, neurologic disease, and iatrogenic or pharmacologic causes.<sup>1</sup> Medications leading to UR in humans include anticholinergics, antihistamines, analgesics, benzodiazepines, calcium channel antagonists, antidepressants, antipsychotics, sympathomimetics and muscle relaxants.<sup>1</sup> In veterinary medicine, the more commonly implicated drugs are sympathomimetics and analgesics (ie, opioids), with limited reports of other medication-induced UR. This article summarizes a case of UR suspected to be secondary to prolonged use of fluoxetine at an excessive dose.

## Case description

A 2-year-old neutered male domestic shorthair cat weighing 4.6 kg presented to the University of Pennsylvania (PennVet) Emergency Service for a history of several weeks of infrequent urination and hyporexia progressing to anorexia. The cat had been healthy several months prior, aside from displaying inter-cat aggression in the

Department of Clinical Sciences and Advanced Medicine, School of Veterinary Medicine, University of Pennsylvania, Philadelphia, PA, USA

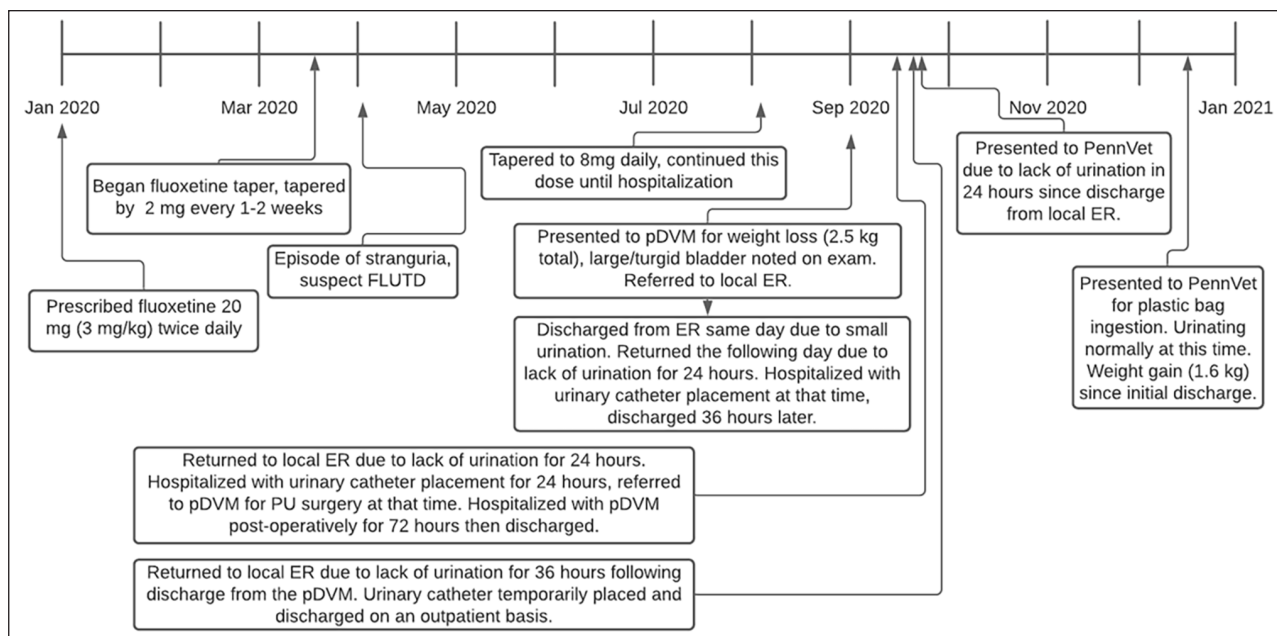
### Corresponding author:

Victoria K DiCiccio DVM, Department of Clinical Sciences and Advanced Medicine, School of Veterinary Medicine, University of Pennsylvania, 2068 MJR-VHUP, 3900 Delancey St, Philadelphia, PA 19104-6009, USA  
Email: tdici@upenn.edu

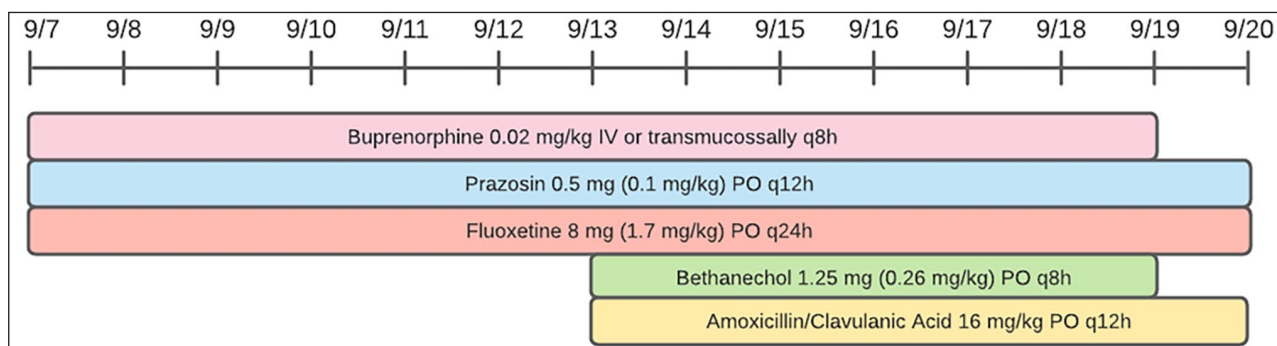


Creative Commons Non Commercial CC BY-NC: This article is distributed under the terms of the Creative Commons

Attribution-NonCommercial 4.0 License (<https://creativecommons.org/licenses/by-nc/4.0/>) which permits non-commercial use, reproduction and distribution of the work without further permission provided the original work is attributed as specified on the SAGE and Open Access pages (<https://us.sagepub.com/en-us/nam/open-access-at-sage>).



**Figure 1** Outlines of the timeline of events for the patient, starting with initial presentation to the primary care veterinarian (pDVM). ER = emergency room; FLUTD = feline lower urinary tract disease



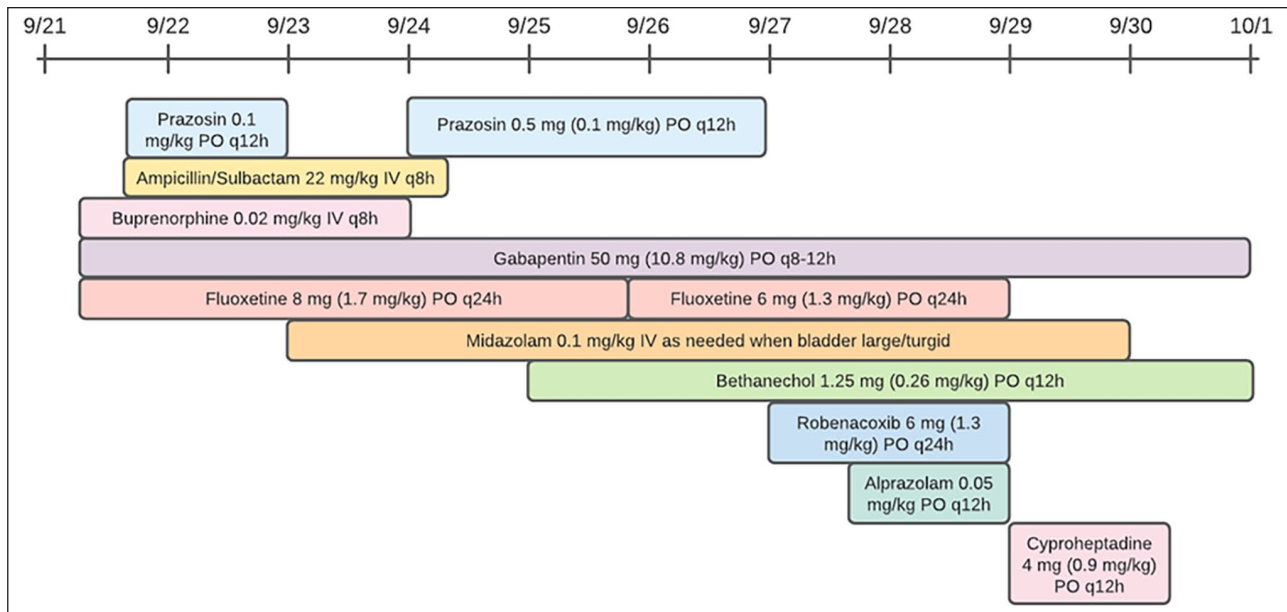
**Figure 2** Outline of the prescribed treatments and duration of administration of medications prior to presentation to the University of Pennsylvania

home. At that time, the primary care veterinarian (pDVM) prescribed fluoxetine 20 mg (3 mg/kg q12h [Prozac; Eli Lilly]), a dose far exceeding the recommended 2–5 mg/cat q24h. After the addition of fluoxetine, the cat began to display intermittent hyporexia and severe weight loss. The fluoxetine was tapered to 8 mg (1.7 mg/kg q24h) over the following several months, which it was receiving until presentation to our hospital.

The cat initially displayed urinary signs several months prior, when it was seen straining non-productively outside of the litter box. The cat was treated with a short course of an unknown analgesic for suspected feline lower urinary tract disease (FLUTD), after which the cat displayed no lower urinary signs. Approximately 3 weeks prior to presentation at PennVet, the cat presented to the pDVM for evaluation of weight loss and

hyporexia. On examination, the cat's bladder was large, turgid and inexpressible, and the cat was referred to another hospital at that time. Figure 1 shows a timeline of events following this evaluation in which the cat re-presented to the pDVM and emergency hospital multiple times for infrequent urination. Each time, a urinary catheter was placed with minimal resistance and the cat was treated for potential FLUTD (Figure 2). Eventually, perineal urethrostomy (PU) surgery was performed. When no improvement was noted, the cat was presented for a second opinion at PennVet.

On initial examination (September 2021), the cat was diffusely muscle wasted with a muscle condition score of 2/3, and was tense and reactive on caudal abdominal palpation. The PU site appeared to be healing appropriately with an appropriate stoma size. The urinary bladder was enlarged, firm and inexpressible. The cat had a



**Figure 3** Outline of the prescribed medications and duration of administration of medications while hospitalized at the University of Pennsylvania

normal neurologic examination, and the remainder of the physical examination was unremarkable. A 5F red rubber catheter was easily passed through the PU site.

To investigate the cause of the cat's urine retention, baseline diagnostics were performed, which included a complete blood count (CBC), chemistry panel, urinalysis, urine culture, abdominal ultrasound (AUS) and abdominal radiographs. CBC revealed a mild anemia (27%) but was otherwise unremarkable. A biochemistry panel revealed no clinically significant abnormalities. Urinalysis performed on a sample collected at the time of urinary catheter placement revealed a urine specific gravity of 1.032 and 1+ protein but otherwise inactive sediment. Urine aerobic culture had no growth. AUS revealed mild degenerative renal changes, a normal urinary bladder with a small amount of intraluminal gas and mild gastrointestinal changes, including mild mesenteric lymphadenopathy and a hyperechoic mucosal band. Mild splenomegaly was noted, suspected to be secondary to sedation. A single lateral abdominal radiograph showed moderate colonic fecal distension but was otherwise unremarkable, with no radiopaque calculi noted. A gastrointestinal panel was submitted to further investigate the weight loss, which revealed a cobalamin level >1000 ng/l but was otherwise normal.

The cat was hospitalized for 11 days with various medical management strategies, outlined in Figure 3. Initial treatments included intravenous (IV) fluids (plasmalyte 2 ml/kg/h), ampicillin (22 mg/kg IV q8h), prazosin (0.5 mg PO q12h), buprenorphine (0.02 mg/kg IV q8h), gabapentin (50 mg PO q12h [Neurontin; Pfizer]) and fluoxetine (8 mg PO q24h). A contrast cystourethrogram revealed a questionable focal narrowing

at the cranial aspect of the urethra thought to represent a segmental urethrospasm or urethral wall thickening (ie, urethritis), though the changes were mild and not present in all views. Following the urethrogram, an indwelling urinary catheter was placed and bethanechol (1.25 mg PO q12h) was restarted for potential detrusor atony. Robenacoxib (6 mg PO q24h [Onsior; Elanco US]) was started for potential urethritis.

The cat had no voluntary urination following urinary catheter removal 24 h later and was noted to have a distended, painful bladder. It received midazolam (0.1 mg/kg IV [Versed 1 mg/ml injectable solution; Pfizer]) and voided a large volume of urine shortly after. This pattern of urination continued, and the cat would urinate only after receiving IV midazolam but would otherwise have prolonged UR. No additional clinical signs of stranguria or pollakiuria were noted during hospitalization.

The cat was transitioned to oral alprazolam (Xanax; Pfizer) to mimic the skeletal muscle relaxant effects of midazolam, though no voluntary voiding occurred while receiving that medication. On day 8 of hospitalization, fluoxetine, robenacoxib and alprazolam were discontinued. The cat was maintained on gabapentin (50 mg PO q12h) and bethanechol (1.25 mg PO q12h). Cyproheptadine (4 mg PO q12h [Periactin; Tiofarma]) was initiated to antagonize the serotonergic effects of fluoxetine. Twenty-four hours later, the patient began voiding its bladder voluntarily so the cyproheptadine and bethanechol were discontinued. The cat continued to void appropriately and was discharged from the hospital. The cat presented for foreign body ingestion several months later, at which time the cat's weight, appetite and urination habits were normal.

## Discussion

Fluoxetine is a selective serotonin reuptake inhibitor (SSRI) commonly used for various behavioral disorders, including anxiety, aggression, compulsive disorders, inappropriate elimination and phobias.<sup>2,3</sup> SSRIs increase serotonin concentrations by blocking reuptake at the synaptic junction. In veterinary patients, there are a variety of reported adverse effects, including lethargy, vomiting, diarrhea, weight loss, decreased appetite, restlessness and behavioral changes.<sup>2,3</sup> In humans, the commonly reported adverse effects are anxiety, nervousness, insomnia, anorexia, diarrhea, seizures and hepatotoxicity.<sup>4</sup> UR is a rarely reported adverse effect in humans, particularly when combined with other antidepressants or antipsychotics, such as haloperidol, venlafaxine and risperidone.<sup>4</sup>

Serotonin may increase urine storage by activating the sympathetic nervous system and inhibiting the parasympathetic nervous system.<sup>5</sup> It is thought that SSRIs may increase external urethral sphincter (EUS) activity by inhibiting serotonin reuptake around the motor neurons of Onuf's nucleus, the site of origin of the pudendal nerve in the sacral spinal cord.<sup>5</sup> For this reason, it is possible that this patient responded only to midazolam owing to the skeletal muscle relaxant effects and relaxation of the EUS.

There is a solitary report of suspected antidepressant-induced UR in a feline patient.<sup>6</sup> In this report, the cat had been receiving clomipramine for suspected psychogenic alopecia and subsequently presented for stranguria. Following discontinuation of the medication, the cat's urination normalized over the following several days. Clomipramine (Clomicalm; Elanco US) is a tricyclic antidepressant (TCA), which acts to decrease the turnover of norepinephrine (noradrenaline) and serotonin in the brain.<sup>6</sup> Clomipramine and other TCAs have varying degrees of anticholinergic effects, which likely account for the observed side effects.<sup>6</sup> When fluoxetine is used in combination with other drugs such as TCAs, it is thought that UR is due to heightened anticholinergic effects secondary to inhibition of cytochrome P450 (CYP) enzymes by fluoxetine.<sup>7</sup>

This cat was prescribed a dose of fluoxetine that far exceeded the recommended dosing range. While the dose was reduced over the months preceding presentation to our hospital, the dose it continued to receive was still inappropriate. Many of the cat's other clinical signs, such as weight loss and hyporexia, may be attributed to the high fluoxetine dose. It is also likely that chronic administration of excessive doses of fluoxetine exacerbated the adverse effects of the drug, which may be why urine retention could have been noted with this dose and duration of treatment when it is not seen with more appropriate dosing.

Drug interactions between the fluoxetine and various other medications are likely, given the inhibition of CYP enzymes by fluoxetine. It is possible that concurrent use of fluoxetine and buprenorphine could have enhanced UR secondary to opioid use owing to inhibition of CYP 3A4, the primary enzyme responsible for buprenorphine metabolism. However, this does not appear to be the sole cause of the urine retention as the clinical signs preceded use of the drug and remained present after discontinuation of the opioid medication. Additionally, it is likely that the lack of response to oral alprazolam has a similar etiology, as the drug is metabolized from the parent drug into active metabolites by the CYP enzymes. This was not noted with use of midazolam, as it is administered in its active form.

Cyproheptadine, an antihistamine with potent anti-serotonin activity, was started, to antagonize the serotonergic effects of fluoxetine. While this may have helped to improve this cat's urine retention, given the short duration of administration, the treatment success was likely attributable to a multimodal approach. Likely treatment success involved a combination of IV fluid administration, fluoxetine withdrawal, gabapentin administration as an analgesic and to temper the effects of fluoxetine withdrawal, and bethanechol for ongoing detrusor atony. However, by the time of discharge, all medications had been discontinued and the cat continued to urinate with normal frequency and appearance.

This case is complex, and we cannot definitively prove association between the fluoxetine and UR. This patient had multiple predisposing factors that could have precipitated a stress-induced illness like FLUTD, such as being an indoor-only cat in a household with inter-cat conflict. The cat initially displayed stranguria and pollakiuria several months prior to presentation that resolved with time and analgesics, which could be compatible with a diagnosis of FLUTD. Given the history of suspected FLUTD and environmental stressors, it is possible that a component of FLUTD or stress-induced illness could have precipitated this complex syndrome. The lack of improvement with traditional FLUTD management could have been associated with drug interactions as discussed previously. However, a component of FLUTD and mechanical urethral obstruction appears to be less likely given the lack of lower urinary signs, normal urine sediment examinations, lack of resistance on urinary catheterization and lack of improvement following PU surgery. Though a functional urethral obstruction is a diagnosis of exclusion, the lack of other findings on a thorough diagnostic work-up and response to discontinuation of the drug are suggestive of a functional urethral obstruction likely secondary to excessive doses of fluoxetine administered over a prolonged period of time.

## Conclusions

To our knowledge, this is the first report of suspected fluoxetine-induced UR in veterinary medicine. Although this side effect is uncommonly encountered in human medicine and not reported in veterinary medicine, it should be considered in the differential diagnoses for patients presenting with a suspected functional urethral obstruction or UR, especially if fluoxetine has been administered at higher than recommended doses.

**Conflict of interest** The authors declared no potential conflicts of interest with respect to the research, authorship, and/or publication of this article.

**Funding** The authors received no financial support for the research, authorship, and/or publication of this article.

**Ethical approval** The work described in this manuscript involved the use of non-experimental (owned or unowned) animals. Established internationally recognised high standards ('best practice') of veterinary clinical care for the individual patient were always followed and/or this work involved the use of cadavers. Ethical approval from a committee was therefore not specifically required for publication in *JFMS Open Reports*. Although not required, where ethical approval was still obtained, it is stated in the manuscript.

**Informed consent** Informed consent (verbal or written) was obtained from the owner or legal custodian of all animal(s)

described in this work (experimental or non-experimental) animals, including cadavers) for all procedure(s) undertaken (prospective or retrospective studies). No animals or people are identifiable within this publication, and therefore additional informed consent for publication was not required.

## References

- 1 Billet M and Windsor TA. **Urinary retention.** *Emerg Med Clin North Am* 2019; 37: 649–660.
- 2 Hart B, Cliff K, Tynes V, et al. **Control of urine marking by use of long-term treatment with fluoxetine or clomipramine in cats.** *J Am Vet Med Assoc* 2005; 226: 378–382.
- 3 Kaur G, Voith VL and Schmidt PL. **The use of fluoxetine by veterinarians in dogs and cats: a preliminary survey.** *Vet Rec Open* 2016; 3: e000146. DOI: 10.1136/vetreco-2015-000146.
- 4 Benazzi F. **Urinary retention with fluoxetine-haloperidol combination in a young patient.** *Can J Psychiatry* 1996; 41: 606–607.
- 5 Karadag M, Gokcen C and Bayar H. **Urinary retention in an adolescent patient caused by fluoxetine alone.** *J Child Adolesc Psychopharmacol* 2015; 25: 658.
- 6 Pfeiffer E, Guy N and Cribb A. **Clomipramine-induced urinary retention in a cat.** *Can Vet J* 1999; 40: 265–267.
- 7 Walker NF, Brinchmann K and Batura D. **Linking the evidence between urinary retention and antipsychotic or antidepressant drugs: a systematic review.** *Neurourol Urodyn* 2016; 35: 866–874.