



## **Use of doxorubicin chemotherapy following debulking surgery in the treatment of a cat with mesenteric hemangiosarcoma**

Authors: Simon, Kerry L, Cook, Matthew R, Husbands, Brian D, Long, Mackenzie E, Hokamp, Jessica A, et al.

Source: Journal of Feline Medicine and Surgery Open Reports, 8(2)

Published By: SAGE Publishing

URL: <https://doi.org/10.1177/20551169221121900>

---

BioOne Complete ([complete.BioOne.org](https://complete.BioOne.org)) is a full-text database of 200 subscribed and open-access titles in the biological, ecological, and environmental sciences published by nonprofit societies, associations, museums, institutions, and presses.

Your use of this PDF, the BioOne Complete website, and all posted and associated content indicates your acceptance of BioOne's Terms of Use, available at [www.bioone.org/terms-of-use](https://www.bioone.org/terms-of-use).

Usage of BioOne Complete content is strictly limited to personal, educational, and non - commercial use. Commercial inquiries or rights and permissions requests should be directed to the individual publisher as copyright holder.

---

BioOne sees sustainable scholarly publishing as an inherently collaborative enterprise connecting authors, nonprofit publishers, academic institutions, research libraries, and research funders in the common goal of maximizing access to critical research.



# Use of doxorubicin chemotherapy following debulking surgery in the treatment of a cat with mesenteric hemangiosarcoma

*Journal of Feline Medicine and Surgery Open Reports*  
1–6

© The Author(s) 2022

Article reuse guidelines:

sagepub.com/journals-permissions

DOI: 10.1177/20551169221121900

journals.sagepub.com/home/jfmsopenreports

This paper was handled and processed by the American Editorial Office (AAFP) for publication in *JFMS Open Reports*



Kerry L Simon<sup>1</sup>, Matthew R Cook<sup>1</sup>, Brian D Husbands<sup>1</sup>, Mackenzie E Long<sup>1</sup>, Jessica A Hokamp<sup>2</sup>, Timothy H Helms<sup>2</sup>, Heather R Shive<sup>2</sup>, Sarah Lumbrezer Johnson<sup>1</sup>, Eric Hostnik<sup>1</sup> and Laura E Selmic<sup>1</sup>

## Abstract

**Case summary** A 7-year-old male castrated domestic shorthair cat presented with a 5-day history of inappetence. A mid-abdominal mass was palpated and, on exploratory laparotomy, a cystic mass arising from the root of the mesentery was observed. The mass was drained, debulked and omentalized. Histopathologic examination and immunohistochemistry supported a diagnosis of hemangiosarcoma. Adjuvant doxorubicin was started and, prior to the third of five doses of doxorubicin, repeat abdominal ultrasound showed complete response of the primary tumor. Continued monitoring 240 days following histopathologic diagnosis revealed suspected metastasis to local lymph nodes, though the primary tumor remained absent on abdominal ultrasound. A second course of five doses of doxorubicin chemotherapy was completed. Serial abdominal ultrasounds demonstrated stable disease in the locoregional lymph nodes with no visible recurrence of the primary tumor. The cat presented 430 days following diagnosis with lethargy and inappetence. Abdominal ultrasound revealed suspected metastatic mesenteric and ileocolic lymphadenopathy, hepatic metastasis and peritoneal effusion, and the owner elected for humane euthanasia. Necropsy findings and negative immunohistochemical staining for lymphatic vessel endothelial receptor-1 were consistent with a metastatic mesenteric hemangiosarcoma.

**Relevance and novel information** Hemangiosarcoma is an uncommon malignancy in cats, and few cases describing treatment have been reported. To our knowledge, this is the first report to describe the use of debulking surgery and adjuvant doxorubicin chemotherapy in the treatment of mesenteric hemangiosarcoma resulting in extended survival in a cat. Multimodal therapy can be considered for the management of cats with mesenteric hemangiosarcoma.

**Keywords:** Hemangiosarcoma; doxorubicin; visceral hemangiosarcoma; mesenteric hemangiosarcoma

**Accepted:** 7 August 2022

## Case description

A 7-year-old male castrated domestic shorthair cat weighing 5.1 kg presented to The Ohio State University Emergency Service with a 5-day history of inappetence. On physical examination, a firm, mid-abdominal mass was palpated. The cat exhibited mild discomfort upon abdominal palpation. Complete blood count (CBC) (ADVIA 2120i Hematology System; Siemens) and serum biochemistry (COBAS 6000 c501 Chemistry Analyzer; Roche) were clinically unremarkable.

<sup>1</sup>Department of Veterinary Clinical Sciences, College of Veterinary Medicine, The Ohio State University, Columbus, OH, USA

<sup>2</sup>Department of Veterinary Biosciences, The Ohio State University, Columbus, OH, USA

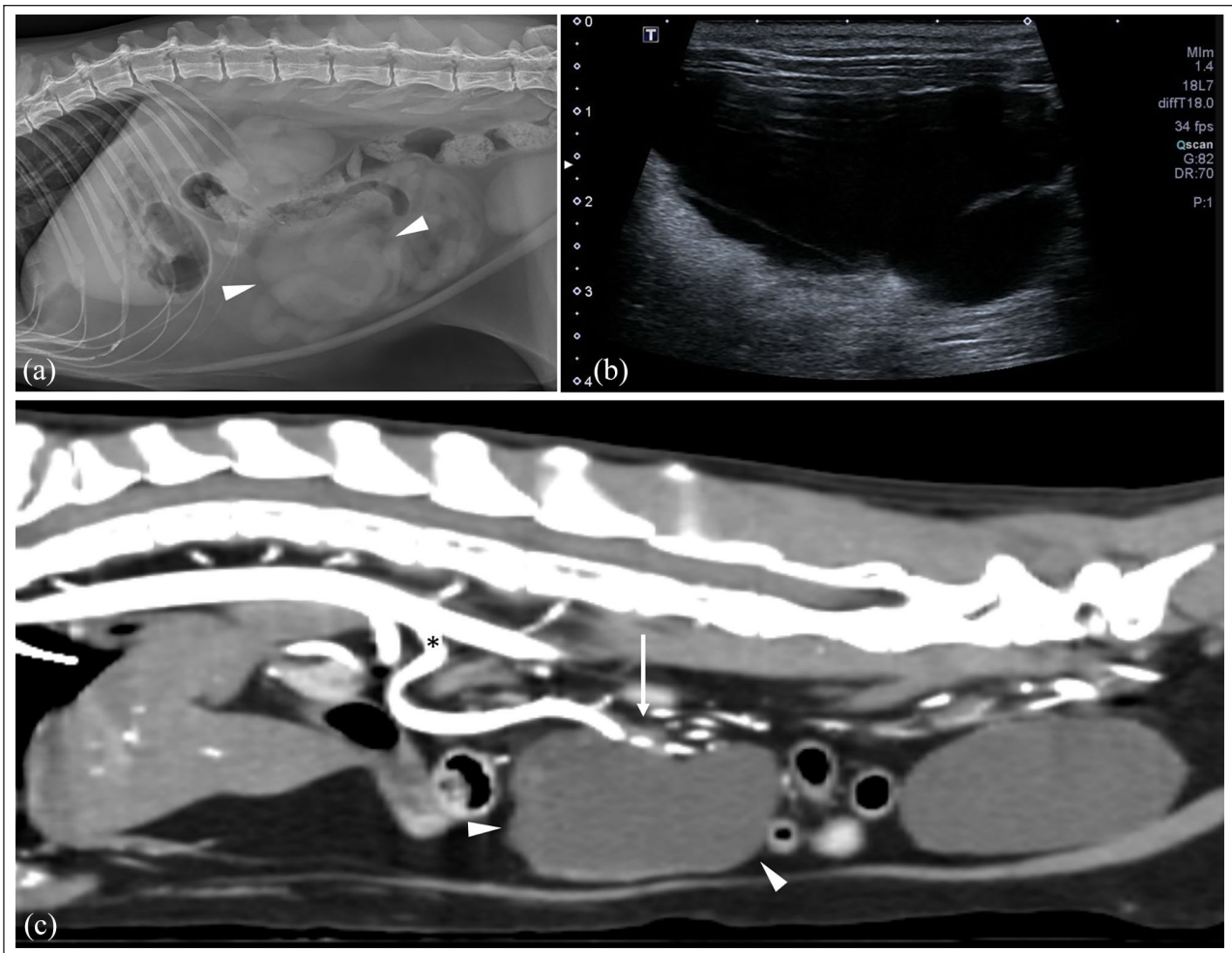
### Corresponding author:

Laura E Selmic BVetMed (Hons), MPH, DECVS, DACVS-SA, Department of Veterinary Clinical Sciences, College of Veterinary Medicine, The Ohio State University, 601 Vernon L Tharp St, Columbus, OH 43210, USA  
Email: Selmic.1@osu.edu



Creative Commons Non Commercial CC BY-NC: This article is distributed under the terms of the Creative Commons

Attribution-NonCommercial 4.0 License (<https://creativecommons.org/licenses/by-nc/4.0/>) which permits non-commercial use, reproduction and distribution of the work without further permission provided the original work is attributed as specified on the SAGE and Open Access pages (<https://us.sagepub.com/en-us/nam/open-access-at-sage>).



**Figure 1** Preoperative imaging. (a) Abdominal radiographs show a rounded mid-abdominal soft tissue mass (arrowheads). (b) Abdominal ultrasound showed a cystic, lobular, mid-abdominal mass with central hyperechoic septations. There was dependent echogenic material within the lumen that was mobile during ultrasound imaging. (c) Sagittal multiplanar reformation arterial phase post-contrast CT image of the soft tissue attenuating, peripherally contrast enhancing, cystic mid-abdominal mass (arrowheads). Note the cranial mesenteric artery (\*) and the association of the branching mesenteric arteries within the margins of the mass (arrow). Soft tissue window width and window level 400/40; the acquired slice thickness was 1.25 mm with a 120kVp

Abdominal radiographs were performed and a rounded, soft tissue mass was seen in the mid-right ventral abdomen (Figure 1a). Thoracic radiographs were performed and were clinically unremarkable. An abdominal ultrasound (Aplio a550; Canon Medical Systems) was performed and a cystic, lobular, mid-abdominal mass was identified (Figure 1b). The mass was surrounded by hyperechoic mesentery and fat, and was adjacent to several loops of small intestine. Small ovoid hypoechoic structures were observed deep to the cystic mass, likely representing jejunal lymph nodes.

A sedated CT scan (GE Light Speed, dual source totaling 128-detector) of the abdomen was performed with contrast (Iohexol 2 ml/kg IV [Omnipaque; GE Healthcare]). A 4.7 × 5.7 × 2.8 cm, cystic, irregularly marginated, homogeneous, soft tissue-attenuating mass was observed in

the central abdomen (Figure 1c). Fluid was obtained from the mass via ultrasound-guided fine-needle aspiration. Cytologic evaluation revealed a highly proteinaceous (6.0 g/dl) fluid with low-to-moderate cellularity (4380 nucleated cells/μl) and evidence of recent hemorrhage.

An exploratory laparotomy was performed, revealing an 8 cm in diameter, thin-walled, broad-based, lobulated, cystic mass arising from the root of the mesentery. The base of the mass was firmly attached to the mesenteric root and was intimately associated with the cranial mesenteric artery. No other structural abnormalities within the abdomen were noted. Owing to close association of the mass with the cranial mesenteric artery, en bloc resection was not performed. The mass was drained, debulked and omentalized. Ampicillin with sulbactam (30 mg/kg IV [Unasyn; Pfizer]) was given at induction

and every 90 mins intraoperatively. The cat recovered uneventfully and was discharged approximately 24h postoperatively.

Histopathologic evaluation of the mass revealed neoplastic endothelial cells and abundant inflammatory cells, including nodular aggregates of lymphocytes and hemosiderin-laden macrophages within the neoplasm, accompanied by mature adipose tissue and fibrous connective tissue. The neoplastic endothelial cells were observed to wrap around trabeculae filled with eosinophilic extracellular fibrillar matrix (collagen), forming channels and clefts. The neoplastic cells had one ovoid nucleus, 1–2 prominent nucleoli with stippled chromatin, a moderate amount of eosinophilic cytoplasm and distinct cell borders. Red blood cells (RBCs) and inflammatory cells were rarely present within the channels. Anisokaryosis and anisocytosis were both marked, and the mitotic count was 2 per  $10 \times 400$  fields. Additionally, multifocal areas of hemorrhage, fibrin and coagulative-to-liquefactive necrosis were also present. Immunohistochemistry (IHC) was performed, and ~90% of the neoplastic cells demonstrated strong cytoplasmic labeling for CD31 (Figure 2) and factor VIII. Based on the minimal-to-absent RBCs within the channels formed by the neoplastic cells and the preliminary IHC results, an initial diagnosis of lymphangiosarcoma was favored. The absence of lymphatic vessel endothelial receptor-1 (LYVE-1) IHC expression with positive tumor IHC labeling with antibodies against CD31 and factor VIII were consistent with a diagnosis of hemangiosarcoma.

Twenty-nine days following surgery the cat was re-evaluated. After discussion of the treatment options for management of the residual gross disease, injectable chemotherapy (doxorubicin hydrochloride 1 mg/kg IV q3weeks for five treatments [Doxorubicin; Novaplus]) was started. Maropitant citrate (1 mg/kg IV [Cerenia; Zoetis]) was administered with each chemotherapy treatment as the cat reportedly had occasional vomiting. Prior to the third treatment, 71 days postoperatively, thoracic radiographs were repeated and were unremarkable. A repeat abdominal ultrasound was performed and the previously observed cranial mesenteric mass had completely resolved. Suspected persistent focal peritonitis and steatitis with scant peritoneal effusion was observed and the spleen appeared mildly enlarged (13 mm thick). The cat completed the doxorubicin protocol as intended without any adverse events. Repeat staging was performed 145 days after histopathologic diagnosis. Thoracic radiographs were unremarkable. An abdominal ultrasound was performed and no evidence of recurrence was observed. The spleen was similarly enlarged. A mildly enlarged (4.2 mm wide) lymph node was observed at the ileocolic junction and aspirated; however, the sample was hypocellular. The persistent focal peritonitis or steatitis and scant peritoneal effusion


was also observed in the cranial abdomen. The jejunal lymph nodes within this region remained normal in size (up to 2.4 mm wide).

The cat presented for repeat staging 240 days after the histopathologic diagnosis. Thoracic radiographs were clinically unremarkable. On abdominal ultrasound, multiple heterogenous, enlarged jejunal lymph nodes were observed, measuring up to 10 mm wide. The previously enlarged ileocolic lymph node had progressed to 5.6 mm wide. The primary mass continued to be unobservable on ultrasound. A jejunal lymph node was aspirated and cytologic evaluation was consistent with a sarcoma with concurrent macrophagic inflammation and chronic hemorrhage. There were insufficient lymphocytes present to confirm aspiration of lymphoid tissue, suggesting possible effacement of the lymph node with neoplastic cells.

Doxorubicin chemotherapy (1 mg/kg IV q3weeks [Doxorubicin; Novaplus]) was restarted 247 days after histopathologic diagnosis for an additional five intended doses. A CBC performed at the time of the cat's second doxorubicin treatment revealed a moderate non-regenerative anemia (hematocrit [HCT] 22%; reference interval [RI] 27–45%) and mild thrombocytopenia (117 k/ $\mu$ l; RI 128–444). Prior to the third doxorubicin treatment and 269 days after the histopathologic diagnosis, repeat staging was performed. Thoracic radiographs were unremarkable. Abdominal ultrasound showed static jejunal and ileocolic lymphadenopathy. Serum biochemistry showed azotemia (blood urea nitrogen [BUN] 37 mg/dl [RI 18–39] and creatinine 1.6 mg/dl [RI 0.7–2.0]). Plasma protein was 7.5 g/dl (RI 5.6–8.3) and the urine specific gravity (USG) was 1.045. Two hundred and eighty-nine days after histopathologic diagnosis and prior to the fourth doxorubicin treatment, a CBC continued to indicate a stable, non-regenerative anemia (HCT 24%) and mild thrombocytopenia (107 k/ $\mu$ l; RI 128–444).

Repeat staging was performed prior to the fifth doxorubicin treatment, 331 days after histopathologic diagnosis. CBC showed a persistent but stable non-regenerative anemia (HCT 24%; RI 27–45%) and thrombocytopenia (88 k/ $\mu$ l; RI 128–444). Serum biochemistry showed azotemia (BUN 44 mg/dl [RI 18–39]; creatinine 1.7 mg/dl [RI 0.7–2.0], potassium 3.3 mEq/l [RI 3.4–5.4]). Plasma protein was 7.0 g/dl (RI 5.6–8.3) and the USG was 1.046. Thoracic radiographs were unremarkable and abdominal ultrasound revealed the metastatic jejunal and ileocolic lymphadenopathy was static in size. The owner elected to forego additional therapy or monitoring.

Four hundred and thirty days following the histopathologic diagnosis, the cat presented with decreased appetite, excessive grooming and vomiting. CBC demonstrated severe anemia (HCT 10%; RI 27–45), mild lymphopenia (0.56 k/ $\mu$ l; RI 0.60–5.70) and thrombocytopenia

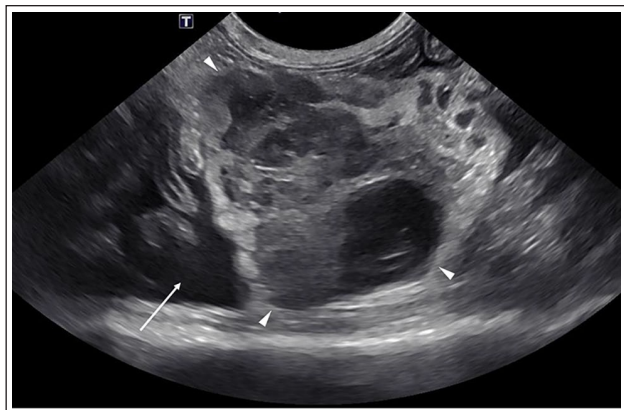


**Figure 2** Histopathologic evaluation of the primary tumor, including hematoxylin and eosin (HE), CD31 and lymphatic vessel endothelial receptor-1 (LYVE-1) immunohistochemistry. Row 1 = hemangiosarcoma, well-differentiated region HE/CD31/LYVE-1. Row 2 = hemangiosarcoma, poorly differentiated region HE/CD31/LYVE-1. Row 3 = rarely, there were small regions within the sarcoma showing strong LYVE-1 immunoreactivity that was clearly within sarcoma cells. There was an abrupt transition to LYVE-1-negative cells, although all cells in the area are CD31<sup>+</sup>. Row 4 = internal controls for this case HE/CD31/LYVE-1. A = artery, L = lymphatic vessel, Aa = arteriole

(96 k/ $\mu$ l; RI 128–444). Serum biochemistry revealed azotemia (BUN 93 mg/dl [RI 18–39], creatinine 2.1 mg/dl [RI 0.7–2.0]). Abdominal ultrasound showed a large, multi-cavitated mass (approximately 3.6 cm in diameter) in the caudal abdomen (Figure 3). The mesenteric lymph nodes and ileocolic junction lymph node remained hypoechoic, heterogeneous and rounded, and a large

volume of peritoneal effusion was present. The liver was effaced with round to amorphous and coalescing, well defined hypoechoic to anechoic structures.

Based on the presence of marked progressive disease, the cat was euthanized at home 432 days following the histopathologic diagnosis. Necropsy revealed a large mass that expanded into the mesentery and effaced the



**Figure 3** Abdominal ultrasound image of the recurrent heteroechoic mass in the caudal abdomen (arrowheads) with an adjacent hyperechoic mesentery. Note the large amount of echogenic peritoneal effusion (arrow) surrounding the mass, with surrounding segments of small intestine

majority of the mesenteric lymph nodes. Numerous masses were present through all lobes of the liver and a mass in the spleen was noted. Positive labeling for CD31 and the absence of LYVE-1 labeling by IHC confirmed both the primary mesenteric mass and multifocal liver masses as hemangiosarcoma.

## Discussion

Visceral hemangiosarcoma is a rare and aggressive tumor in cats. A retrospective study of 26 cats with visceral hemangiosarcoma found that 71% of the cats were euthanized within 1 day of diagnosis. Of the remaining cats, the median survival time was 77 days (range 23–296).<sup>1</sup> The cat in this report was euthanized 432 days after histopathologic diagnosis, which is the longest reported survival time of a cat with mesenteric hemangiosarcoma and a relatively long survival among cats with visceral hemangiosarcoma.<sup>1–4</sup> The current literature describes two cats with splenic hemangiosarcoma without metastatic lesions and with survival times over 20 months that over 42 months following splenectomy without adjuvant chemotherapy; both were lost to follow-up.<sup>5,6</sup>

Unlike canine visceral hemangiosarcoma, there is no standard-of-care treatment for feline visceral hemangiosarcoma. There are few reports in the literature of cats with visceral hemangiosarcoma receiving chemotherapy, particularly in the gross disease setting. The only prior report of a cat with mesenteric hemangiosarcoma that underwent incomplete surgical excision and adjuvant chemotherapy (carboplatin, dosage and frequency not reported) survived 60 days following diagnosis.<sup>2</sup> One cat received doxorubicin following a complete surgical excision of a colonic hemangiosarcoma and survived 150 days following diagnosis and another cat with metastatic hemangiosarcoma (primary tumor site

unknown) received vincristine and survived 77 days.<sup>2,4</sup> A retrospective study described three cats that received doxorubicin chemotherapy following visceral hemangiosarcoma diagnosis; however, the primary tumor sites, surgical excision and exact survival times were not reported.<sup>1</sup> Of these three cats, two survived longer than 100 days but less than 296 days. Another retrospective study described a cat with visceral hemangiosarcoma that received doxorubicin chemotherapy; however, the cat died of respiratory arrest on the day of treatment.<sup>4</sup> In the majority of the reports with visceral hemangiosarcoma the details of the primary tumor sites, chemotherapy regimens and protocol, and exact survival times are unknown.

A recent case report described the use of metronomic chemotherapy using oral cyclophosphamide in the treatment of visceral hemangiosarcoma.<sup>7</sup> At the time of identification of a mid-abdominal mass adjacent to the mesenteric vessels and diagnosis of hemangiosarcoma, there was evidence of a mild anemia and possible metastasis to the regional lymph nodes. The cat did well for 10 months until it presented with acute-onset anorexia, weakness, tachycardia, tachypnea and an abdominal fluid wave, and was euthanized 6 days later. Our case describes a doxorubicin chemotherapy protocol and prolonged survival time in a cat with mesenteric hemangiosarcoma in the gross disease setting. Surgical excision followed by chemotherapy (doxorubicin) is the treatment of choice in dogs with visceral hemangiosarcoma.<sup>8</sup> More research is needed regarding the utility and role of chemotherapy for the treatment of feline visceral hemangiosarcoma.

This is the longest survival time reported for a cat with mesenteric hemangiosarcoma. The primary tumor showed a durable, complete response to the doxorubicin therapy on abdominal ultrasound with eventual metastasis to the lymph nodes and liver, as well as suspected metastasis to the spleen. The case highlights the utility of adjunctive doxorubicin therapy following surgically debulking in the treatment of cats with visceral hemangiosarcoma.

## Conclusions

Doxorubicin chemotherapy following debulking surgery of a visceral hemangiosarcoma was well tolerated and the cat's clinical signs improved. The primary mesenteric mass, despite evidence of metastasis, was still not visible on abdominal ultrasound 331 days following diagnosis. The cat did well clinically for over 14 months, which is longer than previously reported survival times in cats with mesenteric hemangiosarcoma.

**Acknowledgements** We would like to acknowledge the help and support provided by all the faculty and staff at The Ohio State University Veterinary Medical Center with the care and treatment of the cat discussed in this report. We would also

like to thank the Anatomic Pathology Service the University of California at Davis for performing the LYVE-1 IHC staining.

**Conflict of interest** The authors declared no potential conflicts of interest with respect to the research, authorship, and/or publication of this article.

**Funding** This work was supported by the Office of Research Infrastructure Programs, National Institutes of Health [K01OD021419].

**Ethical approval** The work described in this manuscript involved the use of non-experimental (owned or unowned) animals. Established internationally recognized high standards ('best practice') of veterinary clinical care for the individual patient were always followed and/or this work involved the use of cadavers. Ethical approval from a committee was therefore not specifically required for publication in *JFMS Open Reports*. Although not required, where ethical approval was still obtained it is stated in the manuscript.

**Informed consent** Informed consent (verbal or written) was obtained from the owner or legal custodian of all animal(s) described in this work (experimental or non-experimental animals, including cadavers) for all procedure(s) undertaken (prospective or retrospective studies). No animals or people are identifiable within this publication, and therefore additional informed consent for publication was not required.

**ORCID ID** Laura E Selmic  <https://orcid.org/0000-0001-6695-6273>

## References

- 1 Culp WTN, Drobatz KJ, Glassman MM, et al. **Feline visceral hemangiosarcoma.** *J Vet Intern Med* 2008; 22: 148–152.
- 2 Johannes CM, Henry CJ, Turnquist SE, et al. **Hemangiosarcoma in cats: 53 cases (1992–2002).** *J Am Vet Med Assoc* 2007; 231: 1851–1856.
- 3 Scavelli TD, Patnaik AK, Mehlhaff CJ, et al. **Hemangiosarcoma in the cat: retrospective evaluation of 31 surgical cases.** *J Am Vet Med Assoc* 1985; 187: 817–819.
- 4 Kraje AC, Mears EA, Hahn KA, et al. **Unusual metastatic behavior and clinicopathologic findings in eight cats with cutaneous or visceral hemangiosarcoma.** *J Am Vet Med Assoc* 1999; 214: 670–672.
- 5 Seo KW, Hong H, An SA, et al. **Secondary inappropriate polycythemia with splenic hemangiosarcoma in a young adult cat.** *Can Vet J* 2018; 59: 1230.
- 6 Gordon SS, McClaran JK, Bergman PJ, et al. **Outcomes following splenectomy in cats.** *J Feline Med Surg* 2010; 12: 256–261.
- 7 Cheng KY, Krockenberger M and Bennett P. **Use of metronomic chemotherapy in the management of a cat with abdominal hemangiosarcoma.** *JFMS Open Rep* 2018; 4. DOI: 10.1177/2055116918793455.
- 8 Chun R. **Feline and canine hemangiosarcoma.** *Compend Contin Educ Pract Vet* 1999; 21: 622–629.