

Long-term survival of a cat with a metastatic gastrointestinal stromal tumor

Authors: Civa, Patrick Antônio Sonaglio, Fonseca-Alves, Carlos Eduardo, and Dos Anjos, Denner Santos

Source: Journal of Feline Medicine and Surgery Open Reports, 10(1)

Published By: SAGE Publishing

URL: <https://doi.org/10.1177/20551169241247442>

The BioOne Digital Library (<https://bioone.org/>) provides worldwide distribution for more than 580 journals and eBooks from BioOne's community of over 150 nonprofit societies, research institutions, and university presses in the biological, ecological, and environmental sciences. The BioOne Digital Library encompasses the flagship aggregation BioOne Complete (<https://bioone.org/subscribe>), the BioOne Complete Archive (<https://bioone.org/archive>), and the BioOne eBooks program offerings ESA eBook Collection (<https://bioone.org/esa-ebooks>) and CSIRO Publishing BioSelect Collection (<https://bioone.org/csiro-ebooks>).

Your use of this PDF, the BioOne Digital Library, and all posted and associated content indicates your acceptance of BioOne's Terms of Use, available at www.bioone.org/terms-of-use.

Usage of BioOne Digital Library content is strictly limited to personal, educational, and non-commercial use. Commercial inquiries or rights and permissions requests should be directed to the individual publisher as copyright holder.

BioOne is an innovative nonprofit that sees sustainable scholarly publishing as an inherently collaborative enterprise connecting authors, nonprofit publishers, academic institutions, research libraries, and research funders in the common goal of maximizing access to critical research.



Long-term survival of a cat with a metastatic gastrointestinal stromal tumor

Patrick Antônio Sonaglio Civa¹,
 Carlos Eduardo Fonseca-Alves^{2,3}
 and Denner Santos Dos Anjos³

Journal of Feline Medicine and Surgery Open Reports
 1–6

© The Author(s) 2024

Article reuse guidelines:

sagepub.com/journals-permissions

DOI: 10.1177/20551169241247442

journals.sagepub.com/home/jfmsopenreports

This paper was handled and processed
 by the American Editorial Office (AAFP) for
 publication in *JFMS Open Reports*



Abstract

Case summary An 8-year-old spayed female mixed-breed cat presented with a 2-year history of recurrent vomiting and hyporexia. Physical examination revealed a palpable mass in the mesogastric abdominal region without discomfort upon touch. Abdominal ultrasonography revealed an intramural mass in the small intestine (duodenum) that caused a decrease in the segment lumen. A complete blood count revealed leukocytosis with marked neutrophilia, eosinophilia and mild hypoalbuminemia. Enterectomy was performed with 3cm margins and end-to-end anastomosis at the duodenal site of the mass. Histology revealed neoplastic elongated spindle cells that were poorly confined, originating within the muscle layers and that had a mitotic index of 2/10 high-power field (hpf) (at 400×), human epidermal growth factor receptor-type 2 (HER-2) supporting the diagnosis of low-grade sarcoma. Immunohistochemical analysis was positive for KIT, confirming a gastrointestinal stromal tumor (GIST) with a Ki67 level of 15%. Furthermore, multikinase profile biomarkers revealed that the neoplastic cells expressed HER-2 (65%), epidermal growth factor receptor-1 (50%), vascular endothelial growth factor receptor 2 (35%), platelet-derived growth factor receptor beta (15%) and c-KIT (15%). Six months after the original surgery, CT revealed presumptive hepatic, splenic and peritoneal metastases. Toseranib phosphate was prescribed at a dose of 2.75mg/kg and progressive disease was observed at 8 weeks of follow-up.

Relevance and novel information To the best of our knowledge, this is the first case report to characterize the proliferation biomarker profile of a feline GIST in veterinary oncology. However, despite KIT expression in this tumor, the target drug did not inhibit tumor proliferation, providing new insights into this rare tumor in the feline species.

Keywords: Biomarkers; gastrointestinal stromal tumor; intestinal tumor; receptor tyrosine kinases

Accepted: 30 March 2024

Introduction

Gastrointestinal stromal tumors (GISTs) originate from Cajal interstitial cells, which regulate gastrointestinal contractions.^{1–3} Differentiating GISTs from other gastrointestinal sarcomas is challenging because imaging examinations, morphological analyses and hematoxylin-eosin staining are insufficient for conclusive diagnosis.^{4–6} Most GISTs are differentiated based on KIT protein (CD117) immunoreactivity.⁷ In humans, approximately 80–95% of GISTs express KIT protein.¹ However, the chloride channel DOG-1 has been deemed decisive for GIST diagnosis in dogs, regardless of KIT expression.^{1,5}

KIT acts as a tyrosine kinase receptor in the differentiation, proliferation and migration of various cell types, including Cajal cells.⁴ The importance of distinguishing

between leiomyosarcomas and GIST lies in the choice of treatment, considering that KIT-positive GISTs may be treated with toceranib phosphate.¹

¹Medicalvet Veterinary Clinic, Chapecó, Brazil

²Institute of Health Sciences, Universidade Paulista (UNIP), Bauru, Brazil

³Department of Veterinary Surgery and Animal Reproduction, Universidade Estadual Paulista (UNESP), Botucatu, Brazil

Corresponding author:

Denner Santos Dos Anjos DVM, PhD, Department of Veterinary Surgery and Animal Reproduction, Universidade Estadual Paulista (UNESP), Via de Acesso Professor Paulo Donato Castellane S/N, Botucatu, 14884-900, Brazil
 Email: denner.anjosoncology@gmail.com



Creative Commons Non Commercial CC BY-NC: This article is distributed under the terms of the Creative Commons

Attribution-NonCommercial 4.0 License (<https://creativecommons.org/licenses/by-nc/4.0/>) which permits non-commercial use, reproduction and distribution of the work without further permission provided the original work is attributed as specified on the SAGE and Open Access pages (<https://us.sagepub.com/en-us/nam/open-access-at-sage>).

Proliferation biomarkers are important tools used in veterinary oncology to evaluate the behavior of tumor cells and disease prognosis.⁸ Recently, *in vitro* human epidermal growth factor receptor-type 2 (HER-2) expression in feline mammary tumors has been shown to be a potential therapeutic target because of its role in cell growth and association with tumor cell proliferation.⁸

Little information is available in the veterinary literature regarding feline GISTs.^{9,10} Two reports have described the occurrence of feline GISTs in the stomach and jejunum with different biological behaviors.^{9,10} To the best of our knowledge, this is the first report of long-term survival in a feline with metastatic GIST and a multikinase profile.

Case summary

An 8-year-old 2.7kg spayed female mixed-breed cat presented with a 2-year history of recurrent vomiting and hyporexia. The body condition score was 4/9, and on physical examination, a palpable mass in the mesogastric abdominal region without discomfort was noted. Other clinical parameters (heart rate, respiratory rate, rectal temperature, pulse rate and mucous membranes) were unremarkable.

A complete blood count (Bio-2900 Vet; Alara) revealed leukocytosis of 27,300/mm³ (reference interval [RI] 5500–19,000) with intense neutrophilia (21.840/mm³, RI 3000–13,000) and eosinophilia (1.911/mm³, RI 60–850). The biochemical (Bio-2900 Vet; Alara) profile revealed hypoalbuminemia (2.0g/dl; RI 2.1–3.3). The feline leukemia virus (FeLV) antigen test was negative, as was the feline immunodeficiency virus (FIV) antibody test. Abdominal ultrasonography revealed an intramural mass in the small intestine (duodenum) measuring approximately 5.19 cm × 3.57 cm (Figure 1), mild splenomegaly and a uniform liver pattern. The thoracic radiographs were unremarkable. Based on the ultrasonographic findings, physical examination and blood profile, enterectomy was performed, and 3 cm margins and end-to-end anastomosis were performed at the duodenal site (Figure 2). No enlarged lymph nodes, spleen or hepatic nodules were observed. The patient was discharged after 24 h of hospitalization with medications. Cephalexin was prescribed at a dose of 25 mg/kg PO q12h for 7 days, meloxicam at a dose of 0.1 mg/kg PO q24h for 5 days, tramadol chloridate at a dose of 2 mg/kg PO q12h for 5 days and dipyrone (metamizole) at a dose of 25 mg/kg PO q24h for 5 days. A follow-up examination 10 days postoperatively revealed good body condition. Vomiting and hyporexia were not reported by the owners.

Histologic findings revealed the proliferation of neoplastic elongated cells within the muscle layers. The mass was nodular, expansive and infiltrative; the borders were poorly defined, and no fibrous encapsulation

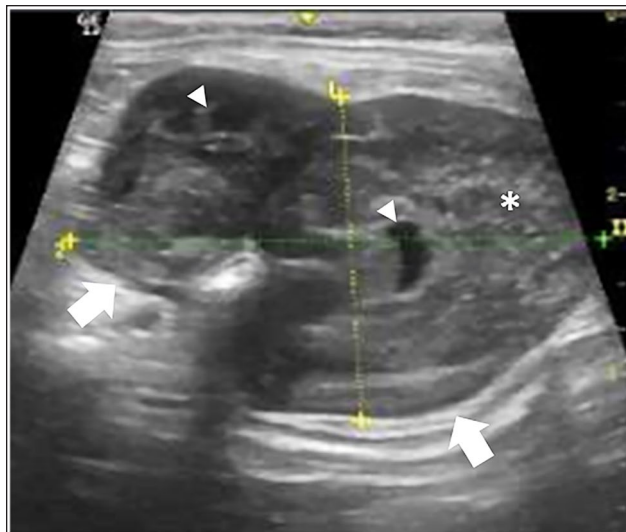


Figure 1 Tumor formation originating from the small intestine (duodenum). Abdominal ultrasound revealed intramural formation with a mass effect in the small intestine (duodenum), rounded shape and irregular surface (arrows), mixed echogenicity and heterogeneous echotexture (asterisk), interspersed with smaller hypoechoic amorphous areas, tending toward anechoic (arrowheads), with an approximate size of 5.19 cm × 3.57 cm

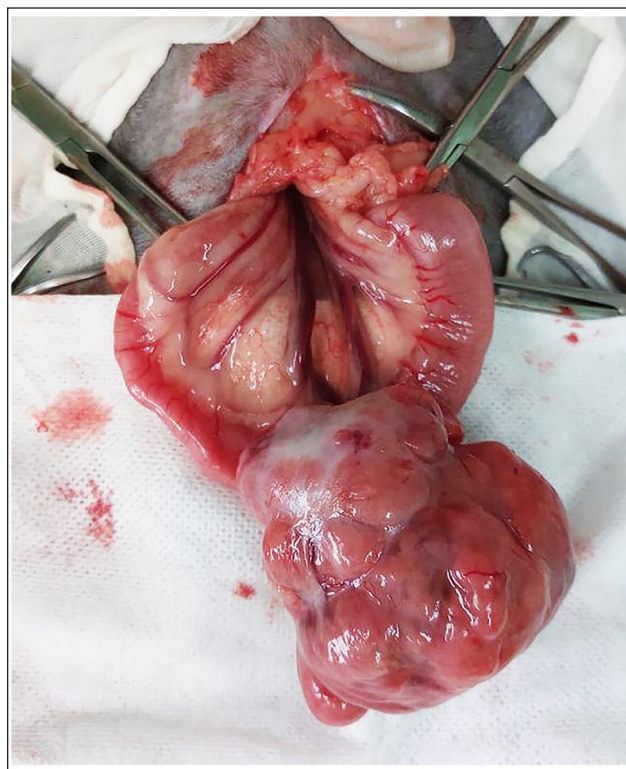


Figure 2 Intraoperative photograph of the gastrointestinal stromal tumor (GIST). Gross features of the GIST in the jejunum. The neoplastic tissue measured 54 mm × 50 mm × 43 mm, exhibiting a slightly firm consistency mass ranging from regular to compact and multinodular aspect with a whitish coloration

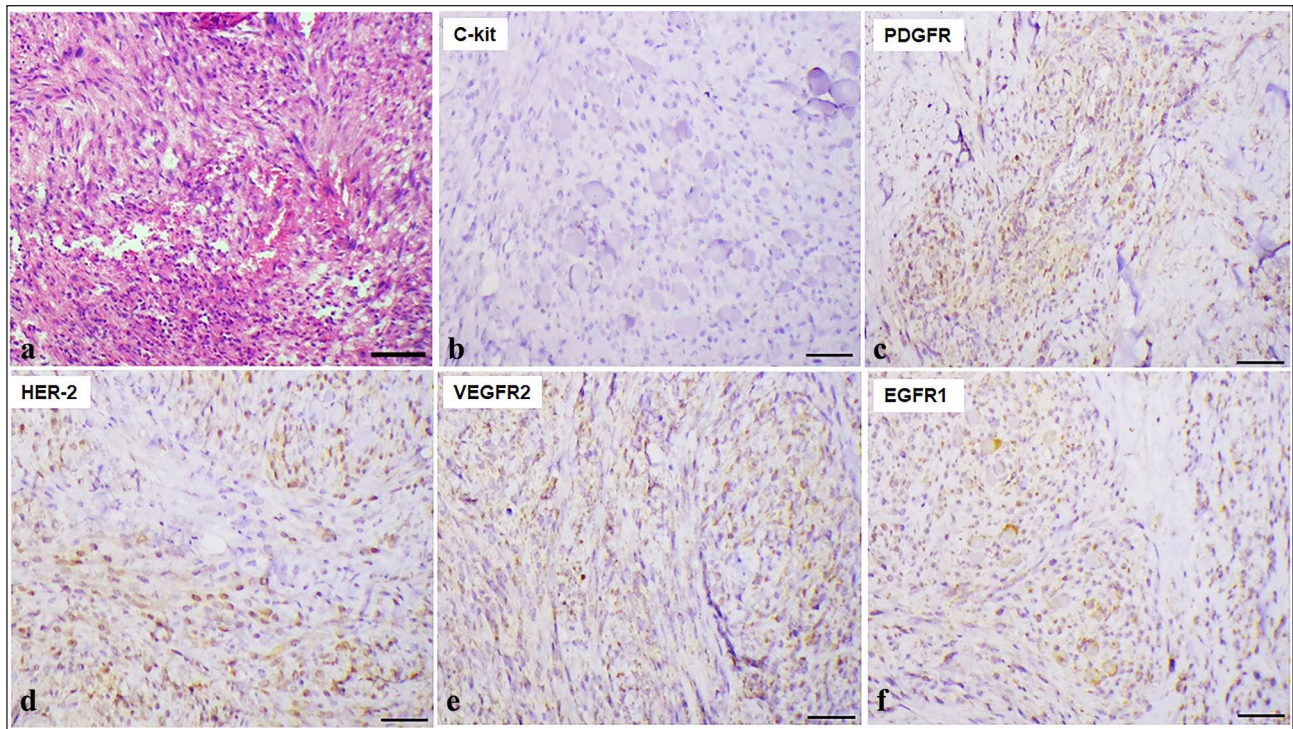


Figure 3 Photomicrograph of the histologic and immunohistochemical sections of the intestinal mass at 200× magnification. (a) Histopathological analysis showing proliferation of mesenchymal cells with moderate cellular pleomorphism, hemorrhage areas and infiltration of inflammatory cells. (b) Immunohistochemical analysis reveals low c-KIT (CD117) (15%) expression. (c–f) Immunohistochemical analysis reveals overexpression of human epidermal growth factor receptor-type 2 (65%) and epidermal growth factor receptor-1 (50%), and reduced expression of vascular endothelial growth factor receptor 2 (35%) and platelet-derived growth factor receptor beta (15%)

was evident. The mitotic index was 2/10 per high-power field (hpf) (400×) (Figure 3a).

The preliminary diagnosis was low-grade sarcoma (GIST, leiomyosarcoma or fibrosarcoma). Immunohistochemical (IHC) tests for KIT protein, S100, 1A4, Desmin and HHF35 revealed positive expression only for KIT, which confirms the diagnosis of GIST. The proliferation index (Ki67) was positive in approximately 15% of neoplastic cells. A multikinase profile obtained by IHC was used to test the first collected tissue sample to evaluate proliferation biomarkers (Figure 3b–f). There was overexpression of HER-2 (65%) and epidermal growth factor receptor-1 (EGFR-1) (50%), with reduced expression of vascular endothelial growth factor receptor 2 (VEGFR-2) (35%) and platelet-derived growth factor receptor beta (PDGFR-beta) (15%), which indicates possible target drugs.

Based on the histologic and immunohistochemical analyses, adjuvant treatment was indicated; however, for personal reasons, the owner declined. Therefore, a recheck every 3 months was recommended for imaging examinations. The first follow-up showed that the patient was in good clinical condition without metastatic lesions

on ultrasonography; 150 days later, the owner reported that the patient started vomiting, accompanied by loss of appetite. The patient was lethargic with mild abdominal discomfort on abdominal palpation. Ultrasonography revealed diffuse nodular hepatic, mesenteric and splenic alterations, suggestive of metastasis. Abdominal CT revealed multifocal nodular aggregates in the spleen and liver with nodular areas in the left abdominal region lateral to the colon interspersed with peritoneal fat. Multifocal lymphadenopathy was evident in the hepatic, gastric and pancreaticoduodenal regions (Figure 4). The owner declined a core needle biopsy or aspiration of the masses to confirm that these lesions were metastatic.

The CT scan supported a progression of the primary tumor, but without further diagnostics, the possibility of inflammatory or other neoplastic conditions could not be excluded. However, considering the time of progression and follow-up of the patient, progression of the primary tumor is more likely than inflammation or other tumor development.

Based on the tumor expression of the KIT protein, and HER-2, two possible target drugs were considered: toceranib phosphate and lapatinib, which are tyrosine kinase

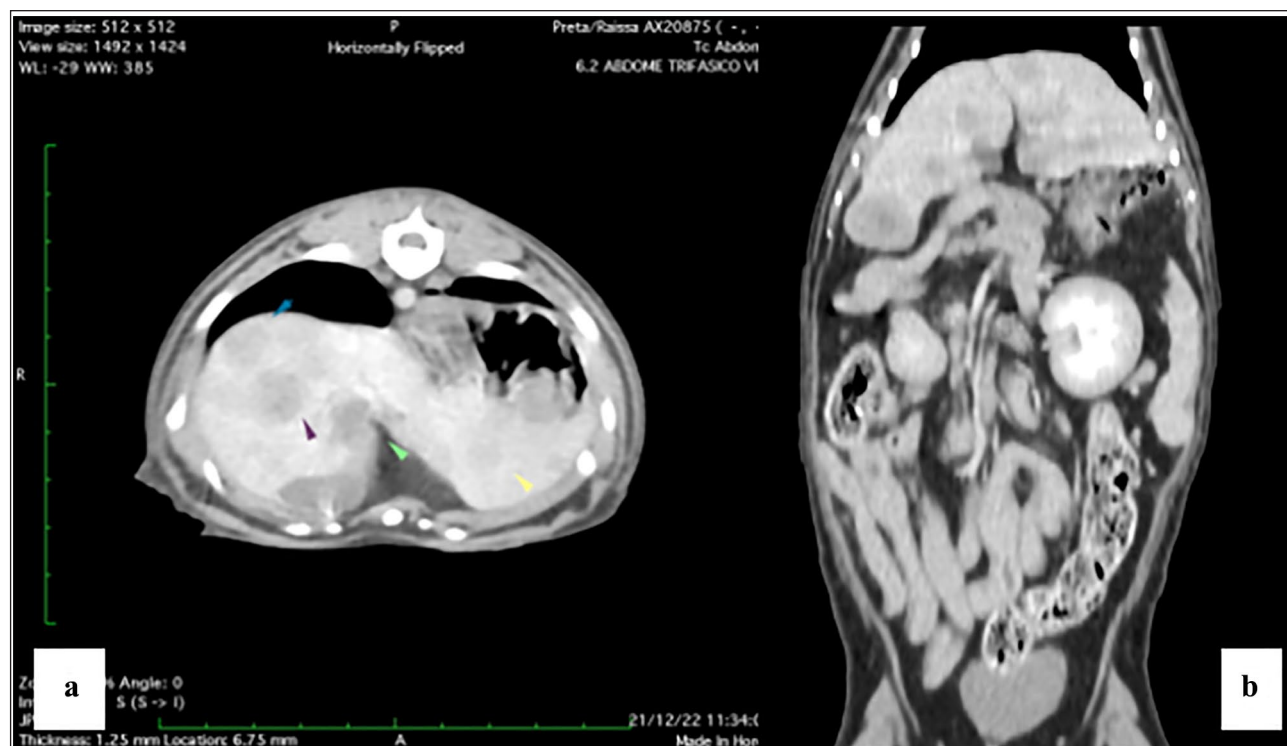


Figure 4 Abdominal CT scan in feline gastrointestinal stromal tumor showing presumptive abdominal metastasis. (a) Liver with increased dimensions, irregular contours and rounded margins. In different postcontrast phases, multiple circumscribed areas with nodular appearance and hypoenhancement were diffusely interspersed within the parenchyma, some of them with partially defined boundaries, measuring 0.5–2.0 cm at their largest axis; (b) diffuse metastases in the abdominal cavity, with greater significance in the liver, spleen, mesentery and lymph nodes (hepatic, gastric and pancreatoduodenal)

inhibitors (TKIs). Based on the absence of a therapeutic dose for lapatinib in cats, we recommended the use of toceranib phosphate (Palladia) at a dose of 2.75 mg on a 3-day-per-week schedule (Monday, Wednesday and Friday), which was started 40 days later for financial reasons. In the feline literature, off-label use has been described as being well tolerated by a variety of tumors, and the majority of toxicities are limited to mild gastrointestinal or myelosuppressive effects (grade 1 or 2).^{11,12} No adverse effects were observed during the study period.

Based on the Response Evaluation Criteria in Solid Tumors (RECIST),¹³ progressive disease (PD) was observed at 8 weeks of evaluation through abdominal ultrasound, in which nodules in the liver were enlarged (2.0 cm vs 2.70 cm). Toceranib was discontinued (70 days of use) and the patient received palliative care. At the time of writing, the patient was still alive with persistent hyporexia. Survival time was 485 days (since the original diagnosis).

Discussion

GISTs can occur anywhere in the gastrointestinal tract as observed in humans, dogs, horses, Spanish ibexes, ferrets, rats and non-human primates.¹⁴ The large intestine is the most common site of occurrence, followed by the

stomach and the small intestine.¹⁵ In the present case, the GIST was located in the small intestine (duodenum), similar to a case report in the literature.¹¹

Clinical signs in animals with GISTs can vary depending on the tumor location, size and staging. Clinical signs may be vague, such as weight loss, vomiting, diarrhea or constipation, abdominal pain and anorexia.¹ The reported patient presented with vomiting, hyporexia and abdominal discomfort. At this stage, only hypoalbuminemia was present (2.0 g/dl), indicating loss (intestine/renal), reduced delivery of metabolites due to hyporexia, decreased production (liver) or a negative acute-phase inflammatory response that was downregulated by proinflammatory cytokine release.

The main sites of metastasis in humans and dogs are the liver and peritoneum; pulmonary metastasis is uncommon.^{14,16} In the literature, there are two published cases of feline GISTs that metastasized to the liver,^{9,10} as observed in this report. However, in addition to hepatic metastasis, we observed splenic and peritoneal metastases because of the alterations observed on the CT scan.

Approximately 35% of humans with GISTs have a survival time of over 5 years; in cases of distant metastasis, the average survival time decreases to 19 months.¹⁷ In dogs, the survival time is 12 months after surgical resection.³

In humans, the prognostic factors for metastasis include tumor diameter and mitotic index.¹⁷ Currently, there are no defined prognostic factors for cats. Compared with humans, mitotic index (two figures of mitosis in 10 fields at 400×) and tumor size (5.4 cm in the largest diameter) are intermediate risk factors for metastasis.¹⁸

In humans, in addition to tumor size, Ki67 >5% is an independent risk factor for poor prognosis in GIST.¹⁹ Ki67 is a nucleoprotein marker of cell proliferation that is overexpressed in tumor cells and is used for cancer prognosis. A recent meta-analysis of Ki67 in human GISTs²⁰ suggested that its overexpression may be a useful marker for the recurrence risk of GISTs. In the present case, Ki67 overexpression was observed in neoplastic cells, suggesting a poor prognosis. Besides the lack of information in the literature regarding feline GISTs and the unavailability of Ki67 cut-offs for them, we could extrapolate this overexpression to be used for the population, since the patient developed distant metastases within a short period after surgery.

Despite the high Ki67 value, this patient exhibited a long survival time, which suggests that further information is required with stromal tumors to identify prognostic factors. One potential explanation for this outcome is that other favorable prognostic factors, such as the specific molecular characteristics of the tumor or the patient's immune response, play a role in positive outcomes.

The most common mutations in GISTs are located in exon 11 of *KIT* in dogs and cats.^{4,12,21} TKIs have become applicable as a treatment modality for unresectable tumors for their inhibition of c-KIT signaling. VEGFR and PDGFR^{1,22} can provide clinical benefits to patients. Interestingly, a recent report on a cat with GIST reported stable disease (30 days) after TKI administration. In addition, the report showed a lack of mutations in all exons of the *KIT* and *PDGFRA* genes, and cytoplasmic staining for KIT by IHC.²³ In our report, we also observed KIT cytoplasmic expression; however, the patient showed PD. Another report also showed a weak diffuse granular cytoplasmic reaction for KIT protein, but a longer survival time (18 months) with TKI administration.⁹ Further evaluation of mutational analysis and IHC patterns is required for individualized treatment in cats.

In addition to the expression of these three genes, the multikinase profile showed significant overexpression of HER-2, a gene that plays an important role in the regulation and differentiation of the cell cycle.²⁴ Lapatinib, a dual inhibitor of EGFR1 and HER-2, is currently used to treat urothelial carcinomas in dogs.²⁴ Recently, an in vitro study showed promising results for the use of lapatinib for the treatment of feline mammary carcinoma.²⁵ Given the overexpression of HER-2 and EGFR1, further studies on the use of lapatinib as a therapeutic option in cats

present an opportunity to discover more about this rare metastatic disease.

Conclusions

GISTs are rare in cats, and their clinical behavior remains poorly understood, owing to a lack of related literature. The use of TKIs based on the overexpression of HER-2 may be an attractive strategy for tumor control of feline metastatic GISTs.

Conflict of interest The authors declared no potential conflicts of interest with respect to the research, authorship, and/or publication of this article.

Funding The authors received no financial support for the research, authorship, and/or publication of this article.

Ethical approval The work described in this manuscript involves the use of non-experimental (owned or unowned) animals. Established internationally recognized high standards ('best practice') of veterinary clinical care for the individual patient were always followed and/or this work involved the use of cadavers. Ethical approval from a committee was therefore not specifically required for publication in *JFMS Open Reports*. Although not required, where ethical approval was still obtained, it is stated in the manuscript.

Informed consent Informed consent (verbal or written) was obtained from the owner or legal custodian of all animals(s) described in this work (experimental or non-experimental animals, including cadavers) for all procedures(s) undertaken (prospective or retrospective studies). For any animals or people individually identifiable within this publication, informed consent (verbal or written) for their use in the publication was obtained from the people involved.

ORCID iD Carlos Eduardo Fonseca-Alves  <https://orcid.org/0000-0002-6702-6139>

Denner Santos Dos Anjos  <https://orcid.org/0000-0003-1804-475X>

References

- Berger EP, Johannes CM, Jergens AE, et al. **Retrospective evaluation of toceranib phosphate (Palladia) use in the treatment of gastrointestinal stromal tumors of dogs.** *J Vet Intern Med* 2018; 32: 2045–2053.
- Katz SC and Ronald PD. **Gastrointestinal stromal tumors and leiomyosarcomas.** *J Surg Oncol* 2008; 97: 350–359.
- Streuker CJ, Huizinga JD, Driman DK, et al. **Interstitial cells of Cajal in health and disease, part II: ICC and gastrointestinal stromal tumors.** *Histopathology* 2007; 50: 190–202.
- Morini M, Gentilini F, Pietra M, et al. **Cytological, immunohistochemical and mutational analysis of a gastric gastrointestinal stromal cell tumour in a cat.** *J Comp Pathol* 2011; 145: 152–157.
- Dailey DD, Ehrhart EJ, Duval DL, et al. **DOG1 is a sensitive and specific immunohistochemical marker for diagnosis**

- of canine gastrointestinal stromal tumors. *J Vet Diagn Invest* 2015; 27: 268–277.
- 6 Fernandez R and Chon E. Comparison of two melphalan protocols and evaluation of outcome and prognostic factors in multiple myeloma in dogs. *J Vet Intern Med* 2018; 32: 1060–1069.
 - 7 Debiec-Rychter M, Wasag B, Stul M, et al. Gastrointestinal stromal tumours (GISTs) negative for KIT (CD117 antigen) immunoreactivity. *J Pathol* 2004; 202: 430–438.
 - 8 Gameiro A, Urbano AC and Ferreira F. Emerging biomarkers and targeted therapies in feline mammary carcinoma. *Vet Sci* 2021; 8. DOI: 10.3390/vetsci8080164.
 - 9 McGregor O, Moore A and Yeomans S. Management of a feline gastric stromal cell tumour with toceranib phosphate: a case study. *Aust Vet J* 2020; 98: 181–184.
 - 10 Suwa A and Shimoda T. Intestinal gastrointestinal stromal tumor in a cat. *J Vet Med Sci* 2017; 79: 562–566.
 - 11 Blackwood L and Harper A. Toxicity and response in cats with neoplasia treated with toceranib phosphate. *J Feline Med Surg* 2017; 19: 619–623.
 - 12 Berger EP, Johannes CM, Post GS, et al. Retrospective evaluation of toceranib phosphate (Palladia) use in cats with mast cell neoplasia. *J Feline Med Surg* 2018; 20: 95–102.
 - 13 Eisenhauer E, Therasse P, Bogaerts J, et al. New response evaluation criteria in solid tumours: revised RECIST guideline (version 1.1). *Eur J Cancer* 2009; 45: 228–247.
 - 14 Frost D, Lasota J and Miettinen M. Gastrointestinal stromal tumors and leiomyomas in the dog: a histopathologic, immunohistochemical, and molecular genetic study of 50 cases. *Vet Pathol* 2003; 40: 42–54.
 - 15 Gillespie V, Baer K, Farrelly J, et al. Canine gastrointestinal stromal tumors: immunohistochemical expression of CD34 and examination of prognostic indicators including proliferation makers Ki67 and AgNOR. *Vet Pathol* 2011; 48: 283–291.
 - 16 Suresh Babu MC, Chaudhuri T, Govind Babu K, et al. Metastatic gastrointestinal stromal tumour: a regional cancer center experience of 44 cases. *South Asian J Cancer* 2017; 6: 118–121.
 - 17 DeMatteo RP, Lewis JJ, Leung D, et al. Two hundred gastrointestinal stromal tumors. *Ann Surg* 2000; 231: 51.
 - 18 Joensuu H. Risk stratification of patients diagnosed with gastrointestinal stromal tumor. *Hum Pathol* 2008; 39: 1411–1419.
 - 19 Nilsson B, Bümming P, Meis-Kindblom JM, et al. Gastrointestinal stromal tumors: the incidence, prevalence, clinical course, and prognostication in the preimatinib mesylate era—a population-based study in western Sweden. *Cancer* 2005; 103: 821–829.
 - 20 Li J, Wang AR, Chen XD, et al. Ki67 for evaluating the prognosis of gastrointestinal stromal tumors: a systematic review and meta-analysis. *Oncol Lett* 2022; 23: 189. DOI: 10.3892/ol.2022.13309.
 - 21 Gregory-Bryson E, Bartlett E, Kiupel M, et al. Canine and human gastrointestinal stromal tumors display similar mutations in c-KIT exon 11. *BMC Cancer* 2010; 10. DOI: 10.1186/1471-2407-10-559.
 - 22 London CA, Hannah AL, Zadovoskaya R, et al. Phase I dose-escalating study of SU11654, a small molecule receptor tyrosine kinase inhibitor in dogs with spontaneous malignancies. *Clin Cancer Res* 2003; 9: 2755–2768.
 - 23 Fujii Y, Iwasaki R, Ikeda S, et al. Gastrointestinal stromal tumour lacking mutations in the KIT and PDGFRA genes in a cat. *J Small Anim Pract* 2022; 63: 239–243.
 - 24 Maeda S, Sakai K, Kaji K, et al. Lapatinib as first-line treatment for muscle-invasive urothelial carcinoma in dogs. *Sci Rep* 2022; 12: 4. DOI: 10.1038/s41598-021-04229-0.
 - 25 Gameiro A, Almeida F, Nascimento C, et al. Tyrosine kinase inhibitors are promising therapeutic tools for cats with HER2-positive mammary carcinoma. *Pharmaceutics* 2021; 13. DOI: 10.3390/pharmaceutics13030346.