



## **USE OF SOLENSIA (FRUNEVETMAB) IN NONDOMESTIC FELIDS (PANTHERA TIGRIS, LYNX RUFUS, PANTHERA UNCIA) GUIDED BY PROTEIN SEQUENCE ANALYSIS**

Authors: Richard, Rebecca, de Camargo, Maristela Martins, and Bruyette, David

Source: Journal of Zoo and Wildlife Medicine, 55(3) : 780-787

Published By: American Association of Zoo Veterinarians

URL: <https://doi.org/10.1638/2023-0122>

---

BioOne Complete ([complete.BioOne.org](https://complete.BioOne.org)) is a full-text database of 200 subscribed and open-access titles in the biological, ecological, and environmental sciences published by nonprofit societies, associations, museums, institutions, and presses.

Your use of this PDF, the BioOne Complete website, and all posted and associated content indicates your acceptance of BioOne's Terms of Use, available at [www.bioone.org/terms-of-use](https://www.bioone.org/terms-of-use).

Usage of BioOne Complete content is strictly limited to personal, educational, and non - commercial use. Commercial inquiries or rights and permissions requests should be directed to the individual publisher as copyright holder.

---

BioOne sees sustainable scholarly publishing as an inherently collaborative enterprise connecting authors, nonprofit publishers, academic institutions, research libraries, and research funders in the common goal of maximizing access to critical research.

# USE OF SOLENSIA (FRUNEVETMAB) IN NONDOMESTIC FELIDS (*PANTHERA TIGRIS*, *LYNX RUFUS*, *PANTHERA UNCIA*) GUIDED BY PROTEIN SEQUENCE ANALYSIS

Rebecca Richard, DVM, Maristela Martins de Camargo, DVM, PhD, and David Bruyette, DVM, DACVIM

**Abstract:** Osteoarthritis and degenerative joint disease affect many species of nondomestic felid and negatively impact quality of life in managed care settings. Previously, pain management options were limited because of the frequency of comorbidities such as renal disease and common difficulty encountered in medication administration. Solensia™ (frunevetmab) is a felinized monoclonal antibody that binds to nerve growth factor in arthritic joints, thereby inhibiting pain response cascades, and produces marked improvement in clinical signs and quality of life in domestic cats diagnosed with osteoarthritis. Protein sequence analysis was performed to inform the application of frunevetmab in four individuals from three nondomestic felid species (*Panthera tigris*, *Lynx rufus*, and *Panthera uncia*) diagnosed with degenerative joint disease to predict safety, contraindications, and likely response to treatment. Patients were then treated utilizing doses extrapolated from domestic cats and following manufacturer guidelines for administration, and clinical response was evaluated over a minimum 2-mon period. Significant improvement was noted in clinical signs in all four animals, resulting in marked improvement in mobility, lameness, activity level, demeanor, and overall quality of life. Frunevetmab presents an excellent adjunctive therapeutic alternative for nondomestic felids suffering from degenerative joint disease and may complement or decrease the need for other conventional therapeutic regimens.

## INTRODUCTION

Degenerative joint disease (DJD) and osteoarthritis (OA) are routinely encountered in nondomestic felids as well as in domestic cats; some estimates suggest that up to 93% of cats have radiographic evidence of DJD/OA, with 40% or more of those animals demonstrating clinical signs associated with pain.<sup>4</sup> With chronic OA, the cumulative effects of pain, central nervous system sensitization, and impairment of activity may contribute to heightened stress and changes in demeanor and mentation that may negatively impact quality of life in domestic animals and managed exotic species.<sup>1</sup> Solensia™ (frunevetmab injection, 7 mg/ml, Zoetis Pharmaceuticals Inc, Kalamazoo, MI 49007, USA) is a recently FDA-approved felinized monoclonal antibody (mAb) that binds to nerve growth factor (NGF) produced in arthritic joints, thereby inhibiting pain cascades. Frunevetmab has been broadly and successfully used in domestic cats with OA, but

thus far no controlled trial has tested this mAb in other feline species.

## CASE REPORTS

### Case 1

An 18-yr-old intact male white Bengal tiger (*Panthera tigris*) housed at a sanctuary in Nevada had chronic, severe, progressive multilimb OA. Congenital marked conformational deficits contributed to clinical signs including marked bilateral muscle atrophy in the hind quarters; a pronounced, consistent 3+/5 right forelimb lameness; and progressive inability to utilize enclosure furniture or engage in play behavior and voluntary enrichment. The tiger had been treated with gabapentin (gabapentin 800-mg tablets, Bluepoint Laboratories/Cencora Inc, Conshohocken, PA, USA 19428; 4.5 mg/kg PO q12h), gradually increasing doses up to 800 mg, and tramadol (tramadol hydrochloride 50-mg tablets, Amneal Pharmaceuticals, Bridgewater, NJ 08807, USA; 1 mg/kg PO q12h), and was eventually placed on a course of prednisone (prednisone 50-mg tablet, Hikma Labs Inc, Columbus, OH 43228, USA; 1.5 mg/kg PO q12h) in conjunction with famotidine (famotidine tablet 40 mg, Bluepoint Laboratories/Cencora Inc; 0.25 mg/kg PO q12h). Some transient improvement was noted after institution of steroid therapy, but the animal continued to exhibit decreased mobility and reluctance to climb in and out of its feeding area and transport cage, and the front leg lameness remained

---

From Wildlife Veterinary Services, Predator Healing Project, 30606 La Sonora Drive, Malibu, CA 90265 (Richard); University of São Paulo, Av. Prof. Lineu Prestes 1730, São Paulo, Brazil, 05508-900 (Martins de Camargo); and Anivive Life Sciences, 3777 Worsham Way, Ste 200, Long Beach, CA 90808 (Bruyette). Correspondence should be directed to Dr. Richard (zoovet2001@gmail.com).

Note: This article contains supplemental material found in the online version only.

pronounced. Quality-of-life discussions were conducted with facility staff and daily quality-of-life logs were instituted.

Winter temperatures in this environment can be severe; consequent curatorial concern around the animal's ability to comfortably survive the oncoming environmental challenges led to discussion of either end-of-life care or empirical treatment with frunevetmab. After discussion of the novel status of the medication and off-label use in this species, curatorial staff agreed to treat the animal based on the similarities determined by protein sequencing analysis and the success of the medication in treating OA in domestic cats.

Dosing was based on the standard dose for domestic cats of 1 mg/kg given subcutaneously, or 147 mg total for this individual. The volume of medication to be administered was 21 ml of the 7 mg/ml formulation from Zoetis, to be divided into two doses given simultaneously at two separate sites caudal to the shoulder and at the flank in volumes of 10 and 11 ml respectively. Additionally, a second dose administered at 28 d per the manufacturer protocol for domestic cats was planned prior to assessment of the full clinical effect. To enable administration of the drug without the need for general anesthesia, the animal was trained to load into a modified squeeze crate voluntarily. No reaction to injection from the animal was noted. Staff were instructed to collect video of the animal on the day of injection and at 2-wk intervals thereafter. Additionally, daily quantitative logs (mobility, lameness, weakness, ease of standing, jumping, appetite, side effects) were to be maintained. Until such time as clinical response could be fully evaluated, no changes were to be made to the animal's regular treatment protocol.

On Day 3 following initial treatment, notable dramatic improvement was captured on video by staff (Supplemental Video 1). Marked improvement in lameness was observed, and the animal was able to jump with greater ease into and out of its feeding station. Within the first 2 wk, it was observed playing with a jolly ball and beginning to trot along fence lines. This behavior had not been noted in over a year from this individual. The animal also voluntarily began swimming again, a behavior not observed in approximately 2 yr. No side effects were noted. Staff and the veterinary care team agreed that a subjective approximately 60%–70% improvement in comfort and activity was noted over the first 28-day period based on daily quality-of-life logging parameters and review of video footage as well as clinical assessment.

The second dose was administered at 28 d using the same procedure. No adverse effects were noted. No marked changes were noted subsequent to the second dose. Over a 5-mon period the animal developed some mildly improved muscle mass in the hind legs. Additionally, after five injections, the animal was weaned off prednisone over a 4-wk interval. The tiger remained active and without marked discomfort without steroids. The front-end lameness did not ever completely resolve, likely because of permanent conformational damage.

As the cost for one round of treatment at the dosage employed is approximately \$1,800, the nonprofit sanctuary was interested to learn if the treatment interval might be extended. After five injections, the interval between treatments was extended to 5 wk with no adverse effects noted. However, at a treatment interval of 6 wk, animal care staff noted a decrease in the tiger's comfort level and activity. The treatment interval was subsequently revised back to every 5 wk.

After 9 mon of treatment, the tiger began to exhibit increased lameness and hind end paresis. The animal was now over 19 yr old. Treatment interval was again decreased to 4 wk and prednisone therapy was initiated at 100 mg PO q12h. At approximately 10 mon from the onset of treatment, the animal acutely developed marked paresis in the hind legs and pelvic region. Given the animal's age, the facility elected humane euthanasia at this time. The etiology of the hind end failure was attributed to cumulative progression of the suspected DJD in the lumbosacral spine and hind limbs and further age-related deterioration, but without necropsy and histology, that supposition could not be validated.

## Case 2

An 11-yr-old female spayed snow leopard (*Panthera uncia*) at a zoo in Southern California diagnosed with likely congenial mild/moderate unilateral coxofemoral dysplasia had chronically exhibited low-grade signs of discomfort, including muscle tremors in the ipsilateral forelimb, reluctance to descend from higher elevations in enclosure furniture, and some minimal paresis in the affected limb at rest with slight plantigrade stance. The animal was also overconditioned, perhaps due in part to inactivity. A course of gabapentin given at 100 mg PO q12h was abandoned 2 mon prior because of some sedation and abnormal gait noted by care staff. The animal was therefore not on any treatment other than glucosamine supplementation.

The animal was immobilized for a preventative care exam and radiography of the affected limbs.

Radiographs demonstrated the previously noted left coxofemoral abnormalities with periarticular bony production along the acetabular ridge and elongation of the femoral head. The initial injection of frunevetmab was given at 1 mg/kg SC (42 mg) during the recovery from anesthesia for a total of 6 ml for this 42-kg animal. Subsequently the animal was trained to enter a panel barrier chute for feeding and presentation of the flank for injection, thus alleviating the need for anesthesia for injection. No adverse effects were noted after any injections.

Within 2 wk of the first injection, care staff noted a behavioral change wherein the animal was more playful with its conspecific. Additionally, the forelimb muscle tremors and hind leg weakness both improved subjectively, and the animal was able to jump and climb within the enclosure with more fluidity and speed. In fact, the animal sustained two small superficial abrasions from increased activity within the first month after treatment. Some subjective increase in muscle mass had developed and improvement in body condition score was noted (Supplemental Video 2).

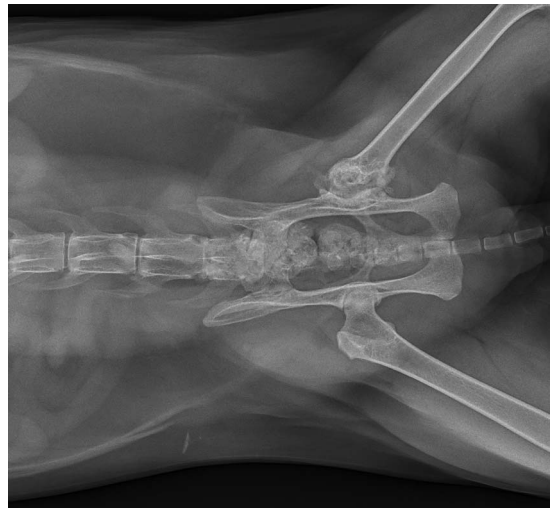
At the time of writing, no other treatment modalities have been implemented for this animal. The dosage schedule remains at 28 d. No adverse effects have been noted since initiation of treatment approximately 10 mon ago.

### Case 3

An 11-yr-old female spayed bobcat (*Lynx rufus*) at a sanctuary in Nevada was diagnosed on radiograph with severe unilateral coxofemoral degeneration secondary to trauma sustained as a juvenile while held as a private pet. The animal was overweight and demonstrated limited activity and decreased mobility over several years at the sanctuary. Radiographs of the left coxofemoral joint demonstrated marked periarticular osteophyte formation and minimal/absent appreciable joint aperture (Fig. 1). Mild DJD was present in the contralateral tarsocrural joint. The animal was treated with gabapentin but refused to consistently consume that or other pain medications. These treatment modalities did not produce much appreciable clinical improvement.

The animal was treated with Solensia at 1 mg/kg subcutaneously. The injection of 1.5 ml (10.5 mg) was administered with the patient awake and netted. No adverse effects were noted. The protocol of video logging at 2-wk intervals and daily logging by animal care staff were followed as described above.

This animal demonstrated a marked clinical improvement in mobility, activity, and general

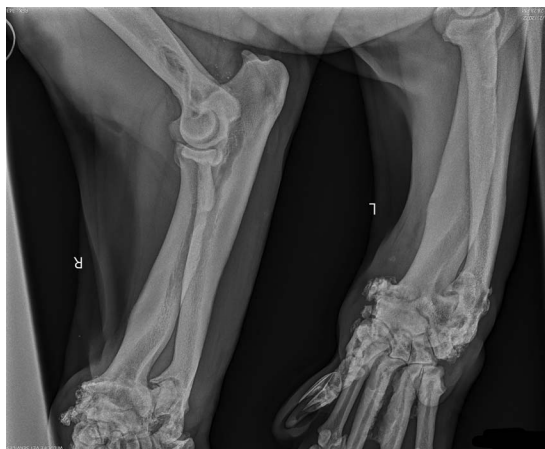


**Figure 1.** Radiograph of a bobcat coxofemoral joint with chronic osteoarthritis secondary to trauma.

demeanor within the 2-wk interval from the first injection. Body condition improved, with body weight decreasing 2 kg over 4 mon. Muscle development was evident on recheck exam 5 mon later when the animal was immobilized for preventative care and dental examination. The animal is on a 4-wk interval dosing with a total of 10 doses at time of writing and no adverse side effects have been noted (Supplemental Video 3).

### Case 4

A 16-yr-old intact male Bengal cross tiger at a sanctuary in Southern California was diagnosed on examination in 2021 with severe polyarthropathy secondary to inbreeding, juvenile malnutrition, and marked conformational deficits, with DJD bilaterally in the carpi with severe periarticular osteophyte formation as well as increased cortical bone density in the radius and ulna with marked congenital angular limb deformity; moderate OA was additionally noted in the hocks and caudal cervical vertebrae (Fig. 2). This older animal demonstrated increased lethargy and inability to jump onto platforms or use the pool or other enclosure furniture, and was very slow to stand. Clinicopathologic data collected the year prior indicated a moderate chronic renal failure with elevations in creatinine and symmetric dimethylarginine. The animal was placed on a treatment regimen including gabapentin, prednisone, famotidine, and mirtazapine (mirtazapine 15-mg tablets, Aurobindo Pharma USA Inc, East Windsor, NJ 08520, USA; 0.18 mg/kg PO q24h), but consistent medication was challenging.



**Figure 2.** Radiograph of front distal extremities of a tiger with severe chronic osteoarthritis secondary to juvenile malnutrition and conformational defects.

The animal's quality of life declined over a 6-mon period, with advanced muscle atrophy and increasing periods of immobility and trouble standing. Prednisone doses were increased to 100 mg PO q12h (0.7 mg/kg) and end-of-life discussions were held with animal care staff. The first dose of frunvetmab was successfully administered using the protocol described above at a dose of 1 mg/kg SC. No adverse effects were noted other than a brief reaction to injection typical for the species (vocalization).

Improvement was noted within the first week. The animal played in its pool for the first time in 13 mon and was observed jumping onto a low platform. Overall activity increased. No significant change was reported after the second dose administered at 4 wk (Supplemental Video 4).

Seven weeks after starting treatment, the animal developed ulcerative cutaneous masses along its dorsum, and a progressive, rapid cachexia was observed with concomitant decrease in energy, demeanor, and appetite. These lesions did not correspond with the location sites of the frunvetmab injections given at the flank and shoulder; rather, they were spaced along the dorsal spinous processes. Additionally, the animal developed abrasive lesions on the ventral aspect of the testes and hips consistent with pressure sores and again not localized to injection sites. The brief respite provided by the frunvetmab did not alleviate the discomfort associated with the comorbidities, presumed to be neoplasia in addition to suspected progressive renal failure. The decision was made to humanely euthanize the animal rather than continue treatment after two doses.

## DISCUSSION

In general, until recently there was a lack of proven treatment options for cats exclusive of nonsteroidal anti-inflammatory drugs, the mechanism of which may create adverse effects because of the high prevalence of renal disease in many cats with DJD.<sup>5</sup> Additionally, reliable daily oral administration of medication is often problematic in both domestic cats and nondomestic felids.<sup>7</sup>

NGF is a novel therapeutic target for DJD/OA-associated pain. NGF plays an essential role in the development of sensory and sympathetic neurons. However, NGF, which is elevated in osteoarthritic joints, also triggers activation of a receptor-mediated signaling cascade in humans and animals with a direct role in the nociception and nervous system plasticity of chronic pain conditions.<sup>1,3</sup>

As a mAb (murine-originated immunoglobulin G [IgG] isotype), frunvetmab binds to feline NGF, preventing its binding to the tropomyosin receptor kinase A (TrkA) and p75NTR receptors, thus disrupting signaling of one of the main stimulus sources that cats experience during OA.<sup>8</sup> Sixty-seven percent of cat owners reported improvement in quality of life after three monthly subcutaneous injections of Solensia (1 mg/kg of body weight for cats).<sup>1,2,9</sup>

Off-label treatment is anecdotally common in zoological medicine; however, the evaluation of protein similarity between cat and several other feline species suffering from OA might predict a positive outcome of such treatment. Conducting immunogenicity, safety, and effectiveness trials in wild animals is extremely difficult and would require multicentric studies bringing together zoos with disparate infrastructure and husbandry practices, resulting in results of low levels of confidence. This case series used the power of sequence analysis to inform and predict positive outcomes of adapting frunvetmab for use in several species of nondomestic felids, specifically tigers as well as snow leopards and bobcats.

Protein alignments of NGF and IgG were performed using sequences from NCBI, accession numbers XP\_004001166.2 (predicted cat NGF, [https://www.ncbi.nlm.nih.gov/protein/XP\\_004001166.2](https://www.ncbi.nlm.nih.gov/protein/XP_004001166.2)), XP\_007076516.2 (predicted tiger NGF, [https://www.ncbi.nlm.nih.gov/protein/XP\\_007076516](https://www.ncbi.nlm.nih.gov/protein/XP_007076516)), XP\_046941768.1 (predicted bobcat NGF, [https://www.ncbi.nlm.nih.gov/protein/XP\\_046941768.1](https://www.ncbi.nlm.nih.gov/protein/XP_046941768.1)), XP\_049472454.1 (predicted snow leopard NGF, [https://www.ncbi.nlm.nih.gov/protein/XP\\_049472454.1](https://www.ncbi.nlm.nih.gov/protein/XP_049472454.1)), ATI97572.1 and ATI97615.1 (cat IgG Fc <https://www.ncbi.nlm.nih.gov/protein/>

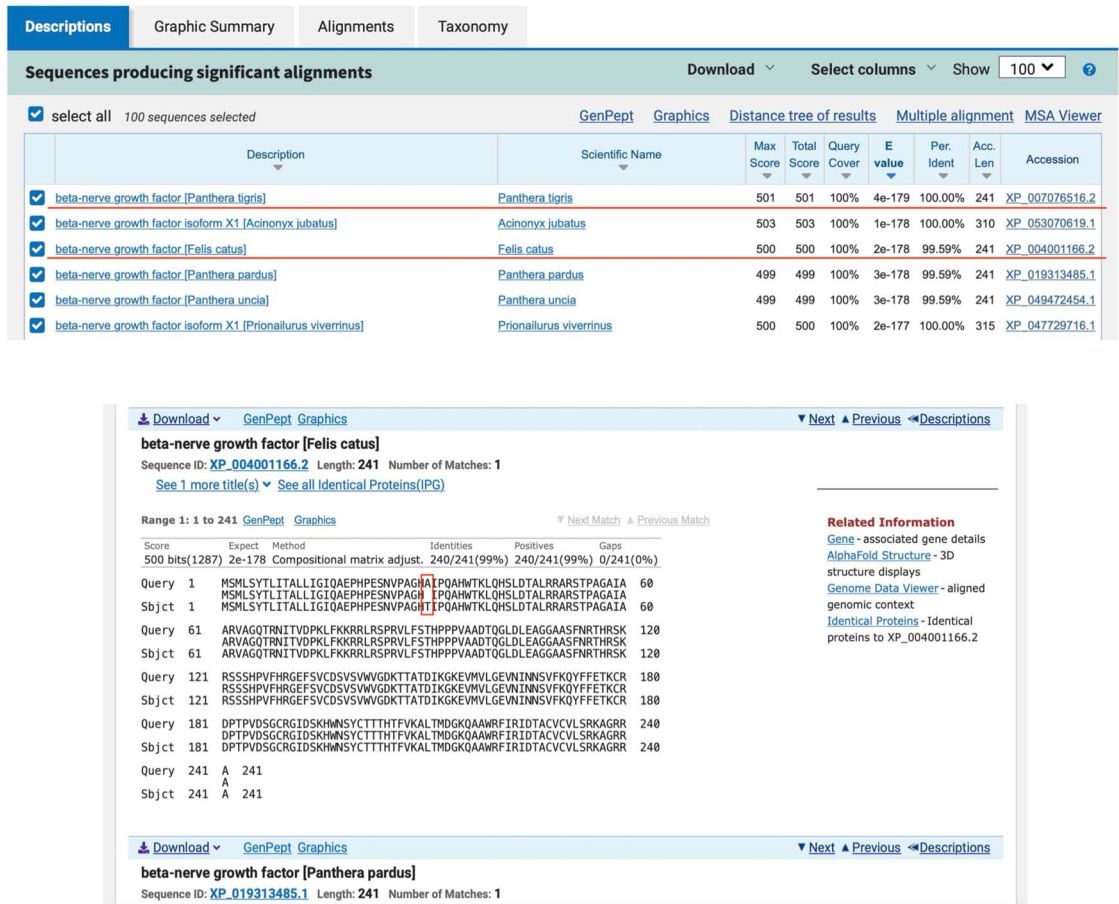


Figure 3. Blast results page showing (A) the description tab and (B) the alignments tab.

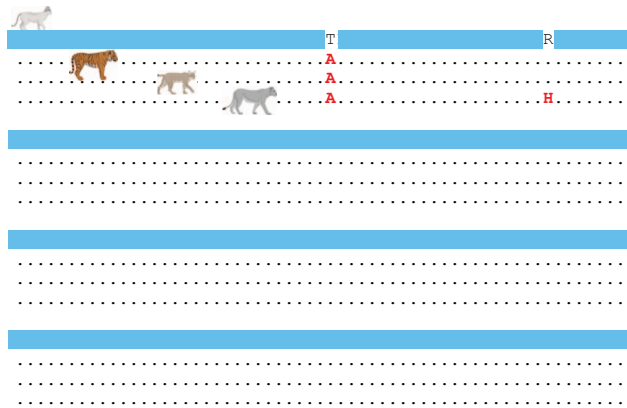
ATI97572.1 and <https://www.ncbi.nlm.nih.gov/protein/ATI97615.1>), and XP\_042845222.1 (tiger IgG Fc, [https://www.ncbi.nlm.nih.gov/protein/XP\\_042845222.1](https://www.ncbi.nlm.nih.gov/protein/XP_042845222.1)). Protein-protein blast (blastp) of each protein was run using default parameters (<https://blast.ncbi.nlm.nih.gov/Blast.cgi>). The results page brings a list of proteins ranked by identity and protein alignment showing the residue substitutions (Fig. 3). Available genome sequences for tiger, bobcat, and snow leopard have coverage of 78× (PacBio technology), 40× (PacBio, Dove-Tail, and Illumina technologies), and 32× (Illumina technology) respectively.

NGF is the target for frunvetmab, and thus, as a starting point, the amino acid sequences of NGF of the domestic cat and the predicted sequences for the tiger, the snow leopard, and the bobcat (Fig. 4) were aligned. It was found that the identity between the cat and the tiger and bobcat sequences was 99.59% (240/241 residues) and between the cat and the snow leopard was 99.17% (239/241 residues;

100% query cover for all sequences). In the tiger and the bobcat, there is only one substitution on position 31: a threonine in the domestic cat is substituted for an alanine in the tiger and bobcat. On the snow leopard there is an additional substitution on position 52: an arginine is replaced by a histidine.

Frunvetmab is a felinized mAb of murine origin and IgG isotype, so it was also important to determine whether the constant region of cat IgG was similar enough to tiger, snow leopard, and bobcat IgG to prevent (or at least delay) appearance of antidrug antibodies (ADA) that can potentially neutralize frunvetmab upon repetitive use. Alignment of constant regions of IgG from these species showed 86%–88% identity between domestic cat and tiger sequences (Fig. 5). There are no predicted sequences for immunoglobulin heavy chains for snow leopards and bobcats to this date.

The in silico analysis suggested that both NGF and IgG constant fraction of domestic cats and



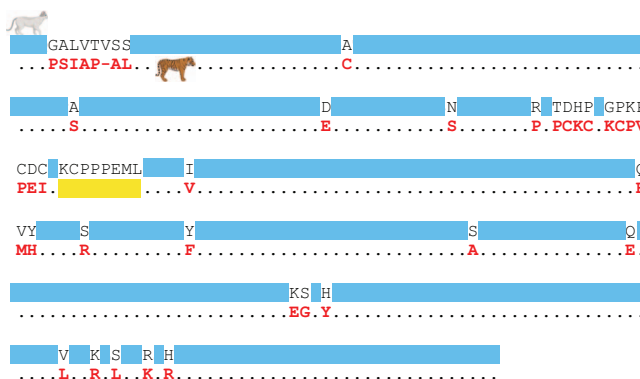
**Figure 4.** Protein alignment of cat and predicted tiger, bobcat, and snow leopard nerve growth factor shows 99% identity. Residue substitutions in red.

tigers present enough identity to warrant therapy with frunevetmab when used in tigers suffering from severe OA. In fact, compassionate off-label usage of frunevetmab in these tigers yielded positive results, considerably improving the quality of life of the treated animals and prolonging their lifespans, even if only briefly for one animal.

Similarities noted in the bobcat and snow leopard in both clinical response and in silico analysis indicate that frunevetmab may be successfully applied in these species as well. Of interest is the younger age and lack of concurrent treatment comorbidities in these two patients. Although both tigers were in end-of-life care, the snow leopard and bobcat may reasonably be expected to live for several more years without the need for daily oral medication to provide comfort and relief from progressive DJD. Therefore, the application of frunevetmab in these individuals has provided not only a possible increase in lifespan but also a measurable improvement in

quality of life, which is a standard by which the welfare of managed animals must be judged.

One study demonstrated that maximum drug levels were observed in domestic cats at 3–7 d after dosing; this is subjectively consistent with the clinical impressions in these represented nondomestic felids.<sup>8</sup> Though NGF is similar in several species, including humans, canines, and felines, as mAb from one species may induce immune reactivity in other species, felinization of the mAb further reduces the risk of immunoreactivity and production of ADA.<sup>1</sup> In a study that analyzed ADA, 4 out of 259 cats that received monthly applications of frunevetmab developed ADA. One of them presented ADA already on Day 0 and further doses of frunevetmab failed at producing noticeable clinical positive effects.<sup>10</sup> In this study, the authors found 86%–88% identity between constant regions of the IgG heavy chain of domestic cats and tigers, suggesting that although it is impossible to affirm that



**Figure 5.** Protein alignment of cat and predicted tiger IgG heavy chain constant region shows 86%–88% identity. Residue substitutions in red, deletions in yellow.

ADA will not happen in tigers, it is unlikely to happen quickly unless the patient already presents antibodies that cross-react with frunevetmab's Fc region.

### Limitations of treatment

The tiger treated in Case 1 did not have previous radiographic findings or clinicopathologic data available. Because of the animal's advanced age and compromised status, facility management did not want to risk general anesthesia prior to treatment. Ideally, as in the other cases, radiographic confirmation of advanced DJD as well as clinicopathologic baseline data would have been collected. Consequently, the appreciable and marked difference in the animal's clinical appearance is based on subjective assessment only. Additionally, neither animal in Case 1 or Case 4 underwent necropsy, and histopathologic data were therefore not available. Furthermore, although animal care staff had observed chronic lameness and changes in gait in Cases 1, 2, and 3, no standardized video monitoring was in place prior to treatment. Additionally, videos were not independently assessed by a trained observer blinded to the time point in treatment when the videos were collected. Such a blinded evaluation, in addition to validated keeper assessment questionnaires or the possible application of physical activity monitors, may improve the objectivity of data collected in any future studies.

The significant cost of the medication may also prove a barrier to regular and ongoing treatment, as was the issue with Case 4. To treat an average adult tiger or lion will cost \$1,600–\$2,000 per injection; this price may prove prohibitive for many facilities, particularly those outside of the American Zoological Association, that rely solely upon donor funding to maintain preventative care and must balance the needs of their entire collection against the high cost of treatment for one individual. Additionally, there is no compounded version of frunevetmab available at this time. The volume of 20–25 ml complicates swift injection, particularly in noncompliant patients or when administered by staff less competent with hand or pole syringe injection techniques. Lastly, the patient must be either anesthetized for injection if noncompliant or be sufficiently and reliably trained to allow injection. The appropriate application of squeeze crates may therefore prevent the loss of thousands of dollars of medication from failed injections. However, staff can be trained in injection technique, and based on the above patients, minimal injection reaction has been observed; distraction techniques may

be employed to improve the likelihood of successful administration.

As with Case 4, treatment with frunevetmab did provide a brief period of comfort and increased mobility. However, to truly improve quality of life, treatment ideally would have been instituted at an earlier date. By the time comorbidities are clinically evident, treatment may not result in significant enough improvement to justify the concomitant expense.

The authors are aware of other large felids treated with frunevetmab who have sustained injury subsequent to treatment, presumably from increased activity in older animals with poor muscling and/or bone density to support the increases in activity level. Additionally, in domestic cats, frunevetmab has been associated with injection site reactions, weight loss, scabbing on the head/neck, worsening of existing renal disease, and increase in lameness, among other side effects.<sup>10</sup> The paresis noted in both tigers as well as the ulcerative dermatological lesions in Case 4 may potentially have been caused or exacerbated by the administration of the medication; the renal failure previously diagnosed in Case 1 may similarly have progressed because of frunevetmab. Therefore, any adverse effects subsequent to administration of frunevetmab, as well as any other novel medication in nondomestic species, should be considered as a potential side effect until more safety data are available.

Long read sequencing of the immunoglobulin loci of different species will greatly improve the ability to analyze and quantify identity of the Fc regions, empowering predictions on the probability of development of ADA when using mAb designed for pets and humans. In this study, the authors were unable to retrieve IgG heavy chain Fc regions for the bobcat and snow leopard, likely because of incomplete assembly of their immunoglobulin loci resulting from short read sequencing that prevents proper assemblage of such complex loci rich in repetitive short sequences.<sup>6</sup>

### CONCLUSION

This case series demonstrates the efficacy of frunevetmab in these particular nondomestic feline species for control of pain associated with DJD/OA and the consequent improvement in quality of life for these animals. The report is a proof of concept that many tentative drug adaptations can be either supported or discarded *in silico*, much sooner than the involvement of real patients, and argues that acquisition of basic skills in sequence analysis is a useful tool for zoological practice.



Pharmacokinetic and pharmacodynamic studies of the medication in nondomestic felids are indicated to determine effective dosing and dose intervals and to evaluate any long-term effects on clinicopathologic parameters and improved understanding of the development of ADA in each species. Further documentation of use of frunevetmab in other nondomestic felid species is called for to validate the efficacy and safety of the drug. Further *in silico* analysis of protein sequences may guide the application of this medication in other, less represented species.

### LITERATURE CITED

1. Enomoto M, Mantyh PW, Murrell J, Innes JF, Lascelles BDX. Anti-nerve growth factor monoclonal antibodies for the control of pain in dogs and cats. *Vet Rec.* 2019;184(1):23.
2. Gruen ME, Myers JAE, Lascelles BDX. Efficacy and safety of an anti-nerve growth factor antibody (frunevetmab) for the treatment of degenerative joint disease-associated chronic pain in cats: a multisite pilot field study. *Front Vet Sci.* 2019. doi:10.3389/fvets.2021.610028.
3. Isola M, Ferrari V, Miolo A, Stabile F, Bernardini D, Carnier P, Busetto R. Nerve growth factor concentrations in the synovial fluid from healthy dogs and dogs with secondary osteoarthritis. *Vet Comp Orthop Traumatol.* 2011;24(4):279–284.
4. Lascelles BD, Henry JB 3rd, Brown J, Robertson I, Thomson Sumrell A, Simpson W, Wheeler S, Hansen B, Zamprogno H, Freire M, Pease A. Cross-sectional study of the prevalence of radiographic degenerative joint disease in domestic cats. *Vet Surg.* 2010;39(5):535–544.
5. Marino CI, Lascelles DB, Vaden SL, Gruen ME, Marks SL. Prevalence and classification of chronic kidney disease in cats randomly selected from four age groups and in cats recruited for degenerative joint disease studies. *J Feline Med Surg.* 2014;16(6):465–472.
6. Rodriguez O, Gibson W, Parks T, Emery M, Powell J, Strahl M, Deikus G, Auckland K, Eichler E, Marasco W, Sebra R, Sharp A, Smith M, Bashir A, Watson C. A novel framework for characterizing genomic haplotype diversity in the human immunoglobulin heavy chain locus. *Front Immunol.* 2020;11:2136.
7. Siven M, Savolaninen S, Rantilä S, Männikkö S, Vainionpää M, Airaksinen S, Raekallio M, Vainio O, Juppo AM. Difficulties in administration of oral medication formulations to pet cats: an e-survey of cat owners. *Vet Rec.* 2017;180(10):250.
8. Walters R, Boucher J, De Toni F. Pharmacokinetics and immunogenicity of frunevetmab in osteoarthritis cats following intravenous and subcutaneous administration. *Front Vet Sci.* 2021;8:687488.
9. Zoetis [Internet]. Zoetis Solensia product support. 2022. <https://www.zoetisus.com/products/cats/solensia>.
10. Zoetis Pharmaceuticals. Solensia (frunevetmab injection) [package insert]. Kalamazoo (MI): Zoetis Pharmaceuticals, Inc; 2021.

*Accepted for publication 16 January 2024*

**Supplemental Video 1.** An 18-yr-old intact male Bengal tiger with right front lameness, paresis, muscle atrophy, and proprioceptive deficits. The subject animal is shown prior to treatment with frunevetmab; at 3 d after initial injection; at 28 d after initial injection; after 2 mon of treatment; after 3 mon of treatment; and approximately 5 mon into treatment. The consistent, marked improvement in lameness, activity, ease of movement, ability to jump, and engagement in play activity is demonstrated.

**Supplemental Video 2.** An 11-yr-old female spayed snow leopard with coxofemoral dysplasia, hind end lameness, abbreviated gait, and poor body condition shown prior to treatment. The same animal is shown approximately 5 mon into treatment. Improvement in body condition, fluidity of movement, and ability to jump is demonstrated.

**Supplemental Video 3.** An 11-yr-old female spayed bobcat with traumatic chronic osteoarthritis of the coxofemoral joint is shown prior to treatment. The animal is overconditioned and demonstrates a short, mincing gait with notable hind end lameness. The same animal is shown 3 mon into treatment. A marked improvement in lameness and ease of movement is evident, as is a significant degree of weight loss.

**Supplemental Video 4.** A 16-yr-old intact male Bengal cross tiger with chronic bilateral front leg lameness, hind end paresis, marked muscle atrophy, lethargy, and proprioceptive deficits is shown prior to treatment. It is difficult for the subject animal to step over a small barrier only a few inches high. The same animal is shown 6 wk into treatment. Improvement in lameness, hind end weakness, and comfort in gait is demonstrated.