

Embryonic Development of the Japanese Mamushi, *Gloydus blomhoffii* (Squamata: Serpentes: Viperidae: Crotalinae)

Authors: Tokita, Masayoshi, and Watanabe, Hiroki

Source: Current Herpetology, 38(1) : 6-13

Published By: The Herpetological Society of Japan

URL: <https://doi.org/10.5358/hsj.38.6>

BioOne Complete (complete.BioOne.org) is a full-text database of 200 subscribed and open-access titles in the biological, ecological, and environmental sciences published by nonprofit societies, associations, museums, institutions, and presses.

Your use of this PDF, the BioOne Complete website, and all posted and associated content indicates your acceptance of BioOne's Terms of Use, available at www.bioone.org/terms-of-use.

Usage of BioOne Complete content is strictly limited to personal, educational, and non - commercial use. Commercial inquiries or rights and permissions requests should be directed to the individual publisher as copyright holder.

BioOne sees sustainable scholarly publishing as an inherently collaborative enterprise connecting authors, nonprofit publishers, academic institutions, research libraries, and research funders in the common goal of maximizing access to critical research.

Embryonic Development of the Japanese Mamushi, *Gloydus blomhoffii* (Squamata: Serpentes: Viperidae: Crotalinae)

MASAYOSHI TOKITA AND HIROKI WATANABE

Department of Biology, Faculty of Science, Toho University, 2–2–1 Miyama, Funabashi, Chiba 274–8510, JAPAN

Abstract: The Japanese mamushi, *Gloydus blomhoffii*, is a medium-sized pit viper found in Japan, Korea, and China and is one of the most familiar snake species to Japanese people due to its nutritional and medicinal value, as well as its venomous nature. Although the reproductive biology (e.g., mating season, breeding cycle, spermatogenesis, follicular growth, and pregnancy period) of the mamushi has been partly investigated, there is no detailed report about how the embryos of the mamushi develop in the mother's oviduct. To provide new information about developmental and reproductive biology of the mamushi and to provide a basis for evolutionary developmental studies aimed at understanding morphological evolution of pit vipers, we described embryonic development of the mamushi covering the middle pharyngula and just before birth, during which pit viper-specific anatomical traits are formed.

Key words: Crotalinae; Development; Embryo; External morphology; Pit vipers

INTRODUCTION

Snakes (Serpentes: Squamata) are one of the most successful and cosmopolitan groups of reptiles, even occurring above the Arctic Circle in Europe and above the timberline in the Himalayas (Pough et al., 2016) and including over 3,700 living species (Uetz et al., 2018). The body plan of snakes is distinct among reptiles, lacking limbs and scleral ossicles (the bony dermal plates present in the eyes of many lizards) and having a suite of anatomical characters such as an elongated body supported by a large number of precloacal vertebrae (ranging from 120 to more than

400), a highly kinetic skull, and venom delivery systems (Lillywhite, 2014; Pough et al., 2016).

How these “snake characters” evolved has been gradually clarified through experimental approaches of evolutionary developmental biology in the last few decades (reviewed by Guerreiro and Duboule, 2014). Describing embryonic development of snake species is an important initial step for evolutionary developmental analyses aimed at understanding the molecular and cellular mechanisms of snake body plan evolution. Normal embryonic development has been described in several snake species including both viviparous (garter snake, *Thamnophis sirtalis* [Zehr, 1962], asp viper, *Vipera aspis* [Hubert and Dufaure, 1968], jararaca pit viper, *Bothropoides jararaca* [Polachowski and Werneburg, 2013]) and oviparous (monocled

* Corresponding author. Tel: +81-47-472-5236;
Fax: +81-47-472-5236;
E-mail address: masayoshi.tokita@sci.toho-u.ac.jp

cobra, *Naja kaouthia* [Jackson, 2002], African rock python, *Python sebae* [Boughner et al., 2007], African house snake, *Boaedon fuliginosus* [Boback et al., 2012], Egyptian cobra, *Naja haje* [Khannoon and Evans, 2014], sand snake, *Psammophis sibilans* [Khannoon and Zahradnicek, 2017], Japanese four-lined snake, *Elaphe quadrivirgata* [Matsubara et al., 2014; Murakami et al., 2017]) species.

In this paper, we describe the embryonic development of a viviparous pit viper, the Japanese mamushi (*Gloydus blomhoffii*), based on the staging system of the garter snake (*Thamnophis sirtalis*) by Zehr (1962). The Japanese mamushi is a medium-sized (total length, 40–65 cm; body mass, 35–150 g) venomous snake living in Japan, Korea, and China (Toriba, 1996; Uetz et al., 2018). The Japanese mamushi becomes sexually mature in 2–3 years and gives birth to 2–9 neonates between August and October, reproducing either biennially or triennially (Yomeishu Seizo Co., Ltd., 1999). In Japan, the mamushi has long been hunted and sometimes artificially propagated for their nutritional and medicinal value (Yomeishu Seizo Co., Ltd., 1999; Sasaki et al., 2009, 2012). Also, approximately 1,000 cases of mamushi bites occur annually in Japan, of which approximately 1% are fatal (Okamoto et al., 2016; Chiba et al., 2018). With such a cultural background, the mamushi is one of the most familiar snake species for Japanese people.

Reproductive biology of the mamushi (e.g., mating season, breeding cycle, spermatogenesis, follicular growth, and pregnancy period) has been partly investigated (Yomeishu Seizo Co., Ltd., 1999; Sasaki et al., 2012). However, there is no detailed report about how the embryos of the mamushi develop in the mother's oviduct. To provide new information on developmental and reproductive biology of the mamushi, we describe their embryonic development from middle pharyngula through immediately before birth, during which pit viper-specific anatomical traits are formed. Our report on development of a snake

species, of which embryos are relatively easily available, would contribute to future evolutionary developmental studies aimed at understanding the morphological evolution of pit vipers as well as snakes in general.

MATERIALS AND METHODS

Gravid females of *G. blomhoffii* were collected from Hiroshima Prefecture, Japan by local snake hunters between late June and early September in 2015, 2016, 2017, and 2018 and were commercially supplied to the authors for study. After decapitation, the abdomen of each snake was opened with a surgical knife and scissors, and embryos were removed from the oviduct (uterus) using forceps and a spoon. To describe external morphology of the embryos that covers the middle to late stages of embryogenesis as fully as possible, the snakes were sacrificed at different times during each year, in order to harvest embryos at different embryonic stages. For example, the embryos at stage 19 were collected in early July, whereas those at stage 37 were collected in middle September. Although we were unable to obtain all later embryonic stages, we obtained 12 of the last 19 stages employed in the staging system of *T. sirtalis* (Zehr, 1962). The embryos were transferred to petri dishes filled with phosphate-buffered saline (PBS) and were excised from the surrounding extraembryonic membranes. All embryos were fixed with Serra's fixative (a mixture of 60% ethanol, 30% formalin, and 10% acetic acid) except those at stage 37, which were fixed with 10% buffered formalin.

To assess external morphology, the fixed embryos were examined under a dissecting microscope (Leica M125). Photographs of earlier embryos (stages 19–27) were taken with a digital camera (Advan Vision, AdvanCam-LP2) mounted on the dissecting microscope. A single-lens reflex digital camera (Olympus, E-5) was used to photograph later embryos (stages 30–37). For stage 28 embryos, morphology of the whole

embryo was recorded using the single-lens reflex camera, whereas the head was photographed through the microscope. A total of 61 embryos was examined for describing the process of embryonic development based on external morphological features that had been used in previous studies (Zehr, 1962; Hubert and Dufaure, 1968; Jackson, 2002; Boughner et al., 2007; Boback et al., 2012; Khannoon and Evans, 2014; Polachowski and Werneburg, 2013; Matsubara et al., 2014; Khannoon and Zahradnicek, 2017; Murakami et al., 2017). The numbering of mamushi embryonic stages was established based upon the staging sequence for *T. sirtalis* (Zehr, 1962), which is the most frequently cited staging sequence in developmental studies of snakes (e.g., Reyes et al., 2010; Tokita et al., 2013). All of the live animal procedures were approved by the Committee on the Ethics of Animal Experiments of Faculty of Science, Toho University (15-51-301, 16-52-301, 17-53-301, 18-54-301).

RESULTS

Stage 19 (n=4; Figs. 1A and 2A)

The epidermis of the head is translucent, so the brain is visible through the skin. The frontonasal process is smooth, creating a rounded shape at the rostrum. Eye pigmentation is not yet developed. The maxillary process is differentiated within the first pharyngeal (maxillo-mandibular) arch and extends anteriorly, approaching the level of the posterior margin of the eye. The mandibular process is distinct from the maxillary process. The otic vesicle is clearly visible at the dorsal side of the second pharyngeal (hyoid) arch. The trunk coils two times.

Stage 23 (n=1; Figs. 1B and 2B)

The nasal pit appears as a deep depression between the frontonasal and lateral nasal processes. The maxillary and lateral nasal processes bulge laterally. An internasal depression appears at the anterior tip of the frontonasal process. Expansion of the mesen-

cephalon is now conspicuous compared to the prosencephalon and metencephalon. The trunk coils three times.

Stage 25 (n=2; Figs. 1C and 2C)

The tip of the maxillary process extends anterior to the eye, whereas the tip of mandibular process does not extend beyond the center of the eye. The retina of the eye is faintly pigmented but the eye is not yet surrounded by a mesenchymal bulge. The trunk coils 3–4 times.

Stage 26 (n=2; Figs. 1D and 2D)

The eye is surrounded by a mesenchymal bulge. The maxillary process expands anteriorly toward the lateral nasal process and these two processes start to fuse. The pharyngeal slits are reduced to shallow grooves. The lateral body walls are still separated medially, so the heart is visible between the walls. The trunk coils 4–5 times.

Stage 27 (n=3; Figs. 1E and 2E)

Medial and lateral nasal processes have fused except for at their most anterior part, and a small pore remains as an external naris. The internasal depression is still present. The maxillary process is completely fused with the lateral nasal process, and the groove between the two processes is no longer visible. The trunk coils 4–5 times.

Stage 28 (n=8; Figs. 1F and 2F)

The eyelid folds begin to form. The lower jaw extends to the level of the anterior margin of the eye. The medial and lateral nasal processes fuse completely to create the external naris. The depression of the pit organ is not visible externally. The tongue is not visible even when the mouth is pried open. The hemipenis is visible at the posterior part of the trunk. The trunk coils 4–5 times.

Stage 30 (n=11; Figs. 1G and 2G)

The lower eyelid reaches the margin of the pupil. Cervical flexure is no longer prominent. Scales are not visible. The facial prominence

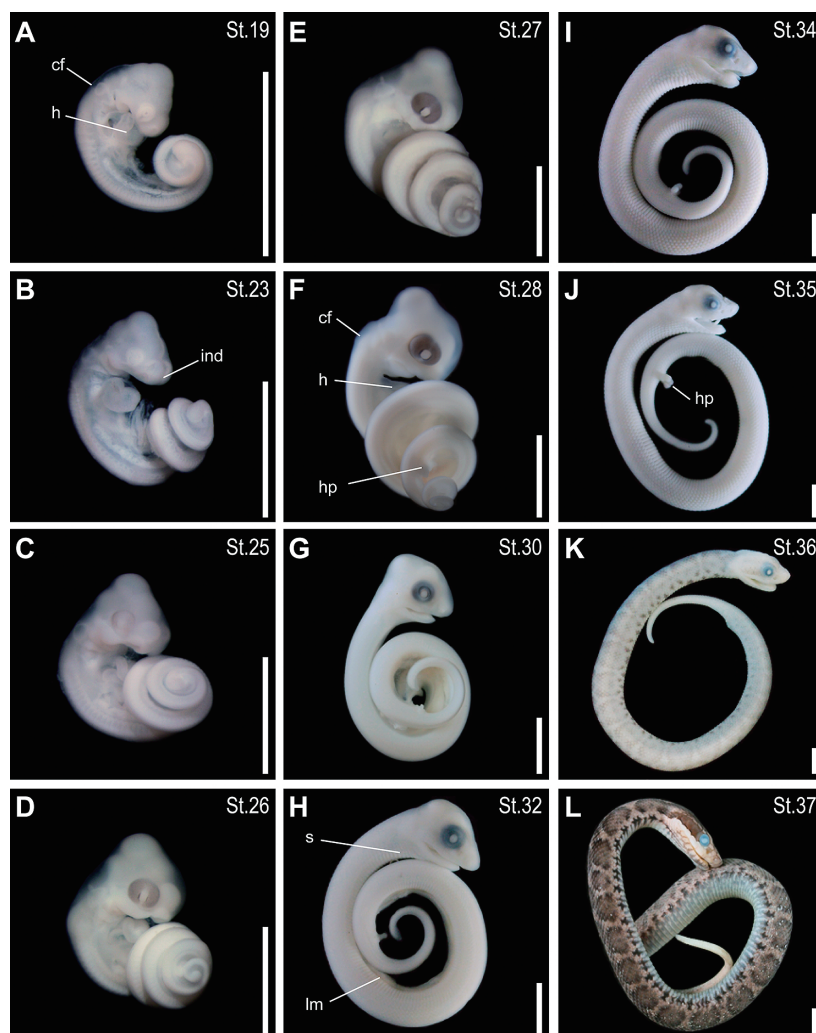


FIG. 1 Embryos of the Japanese mamushi, *Gloydius blomhoffii* (lateral view). The stage of each embryo is given in the upper right of each picture. (A) stage 19; (B) stage 23; (C) stage 25; (D) stage 26; (E) stage 27; (F) stage 28; (G) stage 30; (H) stage 32; (I) stage 34; (J) stage 35; (K) stage 36; (L) stage 37. Scale bars are 5 mm. Abbreviations: cf, cervical flexure; h, heart; hp, hemipenis; ind, internasal depression; lm, lateral trunk muscle; s, primordium of scale.

extends rostrally. The tip of the lower jaw extends anteriorly beyond the anterior border of the eye. The depression of the pit organ is faintly visible between the eye and the external naris. The tongue is visible. The otic vesicle is no longer visible in lateral view.

Stage 32 ($n=5$; Figs. 1H and 2H)

Scales are now visible in the trunk region

but not in the head region. The eyelid folds have fused and cover the eye completely. The tip of the rostrum is more pointed. The lateral trunk muscles begin to extend ventrally, but the heart is still visible in lateral view through the ventral body wall.

Stage 34 ($n=6$; Figs. 1I and 2I)

Scales are visible around the mouth and

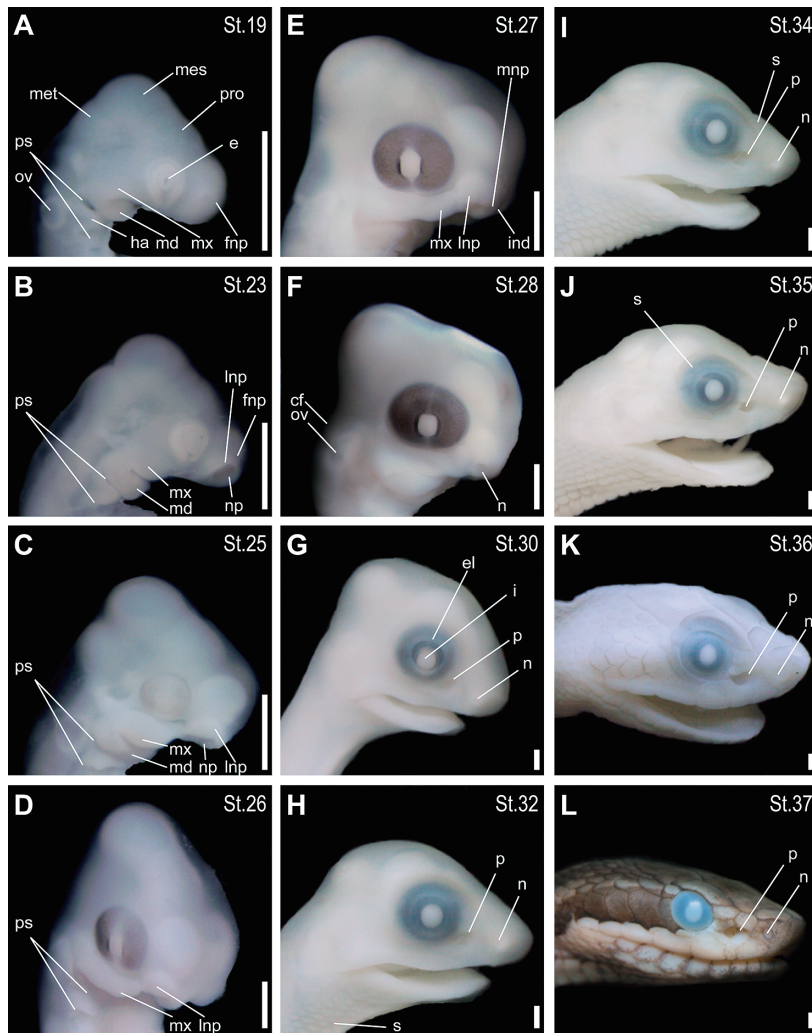


FIG. 2 Heads of mamushi embryos. (A) stage 19; (B) stage 23; (C) stage 25; (D) stage 26; (E) stage 27; (F) stage 28; (G) stage 30; (H) stage 32; (I) stage 34; (J) stage 35; (K) stage 36; (L) stage 37. Photographs B, C, E and F have been flipped horizontally using imaging software. Scale bars are 1 mm. Abbreviations: e, eye; el, eyelid; fnp, frontonasal process; ha, hyoid arch; ind, internasal depression; lnp, lateral nasal process; md, mandibular process; mes, mesencephalon; met, metencephalon; mnp, medial nasal process; mx, maxillary process; n, external naris; np, nasal pit; ov, otic vesicle; p, pit organ; pro, prosencephalon; ps, pharyngeal slits; pu, pupil; s, primordium of scale.

frontal region of the head. The lateral trunk muscles meet along the ventral midline, at least in the region of the heart, so the heart is no longer visible in lateral view. The depression of the pit organ is now clearly visible. Body pigmentation is absent.

Stage 35 ($n=12$; Figs. 1J and 2J)

The fangs on the upper jaw are visible. Scales around the eyes are visible. Except for a small area around the umbilical cord, the left and right trunk muscles have completely fused at the ventral midline. Pigmentation of the head is faintly visible posterior to the eye.

The outline of the brain is faintly evident externally.

Stage 36 (n=5; Figs. 1K and 2K)

Scales cover the entire head. The outline of the brain is no longer visible externally due to the scales covering the parietal region of the head. The mandibular teeth are visible. The shape of the pit organ, externally, is now similar to that of the adult. Black pigmentation is intensified on the entire body. Pigmentation of the scales close to the ventral midline of the trunk is darker than that of the scales on the dorsal side of the trunk. The pattern of pigmentation on the dorsal side of the body (where some large coin-shaped spots are distributed) is distinct from that of the ventral surface (where a number of small black spots are distributed). The hemipenis is no longer visible externally, and is retracted behind the cloaca.

Stage 37 (n=3; Figs. 1L and 2L)

External morphology of the embryos at this stage is almost identical with that of hatchlings. The pigmentation pattern is fully established on the entire body. The scales covering the upper and lower jaws are pale brown, whereas those posterior to the eye are dark brown. On the dorsal side of the body large dark brown spots are aligned longitudinally on the pale brown ground color. The ventral pigmentation pattern is distinct from that of the dorsum, with small black spots dispersed on a light gray ground color.

DISCUSSION

In this paper, we described the middle to late stages of normal embryonic development of *G. blomhoffii*. To our knowledge, *G. blomhoffii* is the third viperid species for which the process of normal embryonic development has been described. The other two species are the asp viper, *Vipera aspis* (Hubert and Dufaure, 1968), and the jararaca, *Bothropoides jararaca* (Polachowski and Werneburg, 2013). All of these three species are vivipar-

ous, and in the present study we confirmed that they share a general embryogenetic pattern.

Cranial morphology unique to vipers, such as a steep upward inflection of the rostrum, becomes apparent after stage 30 of embryonic development (corresponding to stage 37 of Hubert and Dufaure [1968]). Both *G. blomhoffii* and *B. jararaca* are members of the subfamily Crotalinae, which is the sister clade of the subfamily Viperinae (Alencar et al., 2016). One of the most unique characters of crotaline snakes is the pit organ (loreal pit) used for infrared sensing (Goris, 2011). Although Polachowski and Werneburg (2013) described the first sign of the pit organ development as a kind of groove or slit anteroventral to the eye of SES-stage 1 embryos of *B. jararaca* (see Fig. 2 of their paper), we first detected the pit organ in stage 30 embryos of *G. blomhoffii*, as a small depression anteroventral to the eye. To fully understand how the crotaline-specific loreal pit forms, additional studies of histogenesis of the pit organ (Hofstadler-Deiques, 2002), as well as osteogenesis of the bones surrounding the pit (Savitzky, 1992), should be pursued in pit viper species.

The pit organ is also present in some species of the families Boidae and Pythonidae (their pit organ is called “labial pit” on the basis of its position in the head) (Goris, 2011). The pictures of the embryos of African rock python, *Python sebae*, by Boughner et al. (2007) show that the labial pit of this species first appears at stage 7, which corresponds to stage 34 of the mamushi. As we described in this paper, the loreal pit of the mamushi first appears in the embryos at stage 30. Structurally, the loreal pit of crotaline snakes is more complex than the labial pit of pythonid snakes (see Fig. 2 of Goris, 2011). The earlier appearance of the pit organ in the mamushi, perhaps by the heterochronic shift of its formation, may be attributed to such a structural complexity of the loreal pit that generally takes longer time to be completed.

Gloydus blomhoffii could be a good model

species of pit vipers because the embryonic materials are relatively easily available in Japan. We expect that the recently published genome sequence of another pit viper species, the hundred-pace viper, *Deinagkistrodon acutus* (Yin et al., 2016), will also facilitate future evolutionary developmental studies aimed at understanding the morphological evolution of this distinct and highly successful snake lineage.

ACKNOWLEDGMENTS

We thank Hajime Moriguchi for his valuable advice at the early phase of this study, Kazuhiko Kuwada for collection of the materials, and Jason Preble for proofreading the manuscript. We are also indebted to two anonymous reviewers for their suggestions and comments to improve the paper.

LITERATURE CITED

- ALENCAR, L. R. V., QUENTAL, T. B., GRAZZIOTIN, F. G., ALFARO, M. L., MARTINS, M., VENZON, M., AND ZAHER, H. 2016. Diversification in vipers: Phylogenetic relationships, time of divergence and shifts in speciation rates. *Molecular Phylogenetics and Evolution* 105: 50–62.
- BOBACK, S. M., DICHTER, E. K., AND MISTRY, H. L. 2012. A developmental staging series for the African house snake, *Boaedon (Lamprophis) fuliginosus*. *Zoology* 115: 38–46.
- BOUGHNER, J. C., BUCHTOVÁ, M., FU, K., DIEWERT, V., HALLGRÍMSSON, B., AND RICHMAN, J. M. 2007. Embryonic development of *Python sebae*. I. Staging criteria and macroscopic skeletal morphogenesis of the heads and limbs. *Zoology* 110: 212–230.
- CHIBA, T., KOGA, H., KIMURA, N., MURATA, M., JINNAI, S., SUENAGA, A., KOHDA, F., AND FURUE, M. 2018. Clinical condition and management of 114 mamushi (*Gloydius blomhoffii*) bites in a general Hospital in Japan. *Internal Medicine* 57: 1075–1080.
- GORIS, R. C. 2011. Infrared organs of snakes: An integral part of vision. *Journal of Herpetology* 45: 2–14.
- GUERREIRO, I. AND DUBOULE, D. 2014. Snakes: Hatching of a model system for Evo-Devo? *International Journal of Developmental Biology* 58: 727–732.
- HOFSTADLER-DEIQUES, C. 2002. The development of the pit organ of *Bothrops jararaca* and *Crotalus durissus terrificus* (Serpentes, Viperidae): Support for the monophyly of the subfamily Crotalinae. *Acta Zoologica* 83: 175–182.
- HUBERT, J. AND DUFAURE, J. P. 1968. Table de développement de la vipère aspic, *Vipera aspis*. *Bulletin de la Société Zoologique de France* 93: 135–148.
- JACKSON, K. 2002. Post-ovipositional development of the monocled cobra, *Naja kaouthia* (Serpentes: Elapidae). *Zoology* 105: 203–214.
- KHANNOON, E. R. AND EVANS, S. E. 2014. The embryonic development of the Egyptian cobra *Naja h. haje* (Squamata: Serpentes: Elapidae). *Acta Zoologica* 95: 472–483.
- KHANNOON, E. R. AND ZAHRADNICEK, O. 2017. Postovipositional development of the sand snake *Psammodon sibilans* (Serpentes: Lamprophiidae) in comparison with other snake species. *Acta Zoologica* 98: 144–153.
- LILLYWHITE, H. B. 2014. *How Snakes Work*. Oxford University Press, New York.
- MATSUBARA, Y., SAKAI, A., KUROIWA, A., AND SUZUKI, T. 2014. Efficient embryonic culture method for the Japanese striped snake, *Elaphe quadrivirgata*, and its early developmental stages. *Development, Growth & Differentiation* 56: 573–582.
- MURAKAMI, A., HASEGAWA, M., AND KURIYAMA, T. 2017. Developmental mechanisms of longitudinal stripes in the Japanese four-lined snake. *Journal of Morphology* 279: 27–36.
- OKAMOTO, O., NAKASHIMA, R., YAMAMOTO, S., HASHIMOTO, T., TAKASAKI, T., TOKUDA, H., SATO, S., GAMACHI, A., HASHIMOTO, H., AND INAGAKI, N. 2016. A lethal case of mamushi (*Gloydius blomhoffii*) bite: Severe bowel symptoms as a lethal sign. *Acute Medicine & Surgery* 4: 135–139.
- POLACHOWSKI, K. M. AND WERNEBURG, I. 2013. Late embryos and bony skull development in *Bothropoides jararaca* (Serpentes, Viperidae). *Zoology* 116: 36–63.

- POUGH, F. H., ANDREWS, R. M., CRUMP, M. L., SAVITZKY, A. H., WELLS, K. D., AND BRANDLEY, M. C. 2016. *Herpetology. 4th Edition*. Sinauer Associates, Sunderland.
- REYES, M., ZANDBERG, K., DESMAWATI, I., AND DE BELLARD, M. E. 2010. Emergence and migration of trunk neural crest cells in a snake, the California kingsnake (*Lampropeltis getula californiae*). *BMC Developmental Biology* 10: 52.
- SASAKI, K., FOX, S. F., AND DUVAL, D. 2009. Rapid evolution in the wild: Changes in body size, life-history traits, and behavior in hunted populations of the Japanese mamushi snake. *Conservation Biology* 23: 93–102.
- SASAKI, K., FOX, S. F., AND DUVAL, D. 2012. Reproductive ecology and human-caused mortality in the Japanese mamushi snake (*Gloydius blomhoffii*) on the northernmost main island of Japan. *Journal of Herpetology* 46: 689–695.
- SAVITZKY, A. H. 1992. Embryonic development of the maxillary and prefrontal bones of crotaline snakes. p. 119–142. In: J. A. Campbell and E. Jr. D. Brodie (eds.), *Biology of the Pitvipers*. Selva, Tyler.
- TOKITA, M., CHAEYCHOMSRI, W., AND SIRUNTAWINETI, J. 2013. Skeletal gene expression in the temporal region of the reptilian embryos: Implications for the evolution of reptilian skull morphology. *SpringerPlus* 2: 336.
- TORIBA, M. 1996. Mamushi, habu, beni-hebi. p. 101–102. In: S. Sengoku, T. Hikida, M. Matsui, and K. Nakaya (eds.), *The Encyclopaedia of Animals in Japan. Vol. 5: Amphibians, Reptiles, Chondrichthyes*. Heibonsha, Tokyo, Japan.
- UETZ, P., FREED, P., AND HOŠEK, J. (eds.) 2018. *The Reptile Database*. <http://www.reptile-database.org>, (accessed 3 September 2018)
- YIN, W., WANG, Z. J., LI, Q. Y., LIAN, J. M., ZHOU, Y., LU, B. Z., JIN, L. J., QIU, P. X., ZHANG, P., ZHU, W. B., WEN, B., HUANG, Y. J., LIN, Z. L., QIU, B. T., SU, X. W., YANG, H. M., ZHANG, G. J., YAN, G. M., AND ZHOU, Q. 2016. Evolutionary trajectories of snake genes and genomes revealed by comparative analyses of five-pacer viper. *Nature Communications* 7: 13107.
- YOMEISHU SEIZO Co., LTD. 1999. *Ecology and Artificial Propagation of the Mamushi*. Central Research Laboratories, Yomeishu Seizo Co., Ltd., Nagano.
- ZEHR, D. R. 1962. Stages in the normal development of the common garter snake, *Thamnophis sirtalis sirtalis*. *Copeia* 1962: 322–329.

Accepted: 22 November 2018