

TOTAL ALOPECIA IN A GREY SQUIRREL (*Sciurus carolinensis*)

Authors: EMMONS, R. W., MAYNARD, R. P., and TAYLORS, D. O. N.

Source: Journal of Wildlife Diseases, 10(1) : 42-43

Published By: Wildlife Disease Association

URL: <https://doi.org/10.7589/0090-3558-10.1.42>

BioOne Complete (complete.BioOne.org) is a full-text database of 200 subscribed and open-access titles in the biological, ecological, and environmental sciences published by nonprofit societies, associations, museums, institutions, and presses.

Your use of this PDF, the BioOne Complete website, and all posted and associated content indicates your acceptance of BioOne's Terms of Use, available at www.bioone.org/terms-of-use.

Usage of BioOne Complete content is strictly limited to personal, educational, and non - commercial use. Commercial inquiries or rights and permissions requests should be directed to the individual publisher as copyright holder.

BioOne sees sustainable scholarly publishing as an inherently collaborative enterprise connecting authors, nonprofit publishers, academic institutions, research libraries, and research funders in the common goal of maximizing access to critical research.

TOTAL ALOPECIA IN A GREY SQUIRREL (*Sciurus carolinensis*)

R. W. EMMONS,^[1] R. P. MAYNARD^[2] and D. O. N. TAYLOR ^[1]

A report by Sheldon on alopecia of captive flying squirrels⁴ prompts us to report briefly on total alopecia in a *Sciurus carolinensis*. There have apparently been few reports of this condition in wild mammals, and the causes are not well understood.

The animal, an adult male, was found May 13, 1965, terminally ill with paralysis of the hind legs, having fallen out of a tree in Hillsborough, San Mateo County, California. It had been observed in the area previously, with gradually progressing alopecia. It was sacrificed by chloroforming. No ectoparasites were found, and no abnormalities of the skin were noted aside from the complete absence of hair (Fig. 1). Skin sections were carefully examined for mites, with negative results.

No broken bones were found and no significant abnormalities of the internal organs were noted. A special histological study of the brain showed only a focus of glial scarring and mineralization in the internal capsule, and some demyelination along the lateral ventricle adjacent to the hippocampus, but no evidence of acute encephalitis. We suspected that a viral encephalitis might have caused the paralytic illness, and that the alopecia may have offered an unusually attractive target for mosquitoes, which pre-

sumably are the source of fatal infection of squirrels with western equine encephalomyelitis virus.¹ However, tests of serum, blood clot, brain, liver, spleen, submaxillary salivary glands, kidney, and lung, by inoculation of suckling mice, and of brain by inoculation of primary hamster kidney cell cultures using standard methods² yielded no viral agents. Culturing of tissue suspensions in trypticase soy and thioglycollate broth cultures yielded no significant bacterial pathogens, and tests of the brain for rabies were negative.³ No other such specimens have been recovered in California, to our knowledge, although patchy alopecia or hair abnormalities are sometimes seen in squirrels, associated with mite infestation.

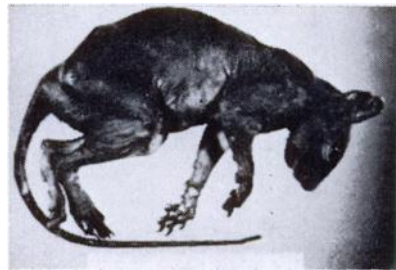


Figure 1

[1] From the Viral and Rickettsial Disease Laboratory, California State Department of Health, Berkeley, California 94704.

[2] Formerly from the Bureau of Vector Control and Solid Waste Management, California State Department of Health, Berkeley, California 94704.

This study was supported in part by Grant AI-01475 from the National Institute of Allergy and Infectious Diseases to the Viral and Rickettsial Disease Laboratory, California State Department of Health.

Acknowledgements

We thank Alan M. Barnes, Ph.D. for examining the specimen for mites, and Keith F. Murray for identifying the squirrel species.

LITERATURE CITED

1. LENNETTE, E. H., M. I. OTA, M. E. DOBBS and A. S. BROWNE. 1956. Isolation of western equine encephalitis virus from naturally-infected squirrels in California. *Amer. J. Hygiene* 64: 276-280.
2. LENNETTE, E. H. and N. J. SCHMIDT (Editors) 1969. *Diagnostic Procedures for Viral and Rickettsial Infections*, Fourth edition. American Public Health Association, Inc., New York.
3. LENNETTE, E. H., J. D. WOODIE, K. NAKAMURA and R. L. MAGOFFIN. 1965. The diagnosis of rabies by fluorescent antibody method (FRA) employing immune hamster serum. *Health Lab. Sci.* 2: 24-34.
4. SHELDON, W. G. 1971. Alopecia of captive flying squirrels. *J. Wildl. Dis.* 7: 111-114.

Received for publication 14 August 1973
