

INVESTIGATIONS ON A Theileria SPECIES FROM AN IMPALA

Authors: GROOTENHUIS, J. G., YOUNG, A. S., KIMBER, C. D., and DREVEMO, S. A.

Source: Journal of Wildlife Diseases, 11(1) : 122-127

Published By: Wildlife Disease Association

URL: <https://doi.org/10.7589/0090-3558-11.1.122>

BioOne Complete (complete.BioOne.org) is a full-text database of 200 subscribed and open-access titles in the biological, ecological, and environmental sciences published by nonprofit societies, associations, museums, institutions, and presses.

Your use of this PDF, the BioOne Complete website, and all posted and associated content indicates your acceptance of BioOne's Terms of Use, available at www.bioone.org/terms-of-use.

Usage of BioOne Complete content is strictly limited to personal, educational, and non - commercial use. Commercial inquiries or rights and permissions requests should be directed to the individual publisher as copyright holder.

BioOne sees sustainable scholarly publishing as an inherently collaborative enterprise connecting authors, nonprofit publishers, academic institutions, research libraries, and research funders in the common goal of maximizing access to critical research.

INVESTIGATIONS ON A *Theileria* SPECIES FROM AN IMPALA

J. G. GROOTENHUIS,^[1] A. S. YOUNG,^[2] C. D. KIMBER

^[2] and S. A. DREVEMO^[1,3]

Wildlife Diseases Research Project,^[1] Veterinary Research Laboratory, P.O. Kabete, Kenya
Immunological Research on Tick-borne Diseases and Tick Control Project,^[2] East African
Veterinary Research Organization, P.O. Box 32, Kikuyu, Kenya

Abstract: An immature impala (*Aepyceros melampus*), captured in the Machakos district of Kenya, had *Theileria*-like parasites in its erythrocytes.

Blood from this animal was inoculated into a *Theileria*-free impala born in captivity and a *Theileria*-free, splenectomized steer. Theilerial piroplasms were detected in the erythrocytes of the recipient impala 10 days after inoculation, and a peak parasitaemia of 2% was reached after 48 days, but no infection was detected in the steer. Anaemia developed in the recipient impala in association with the theilerial infection. The morphology of the theilerial piroplasm is described. Possibly dividing parasites were identified. Attempted tick transmission of the impala *Theileria* to a steer using the ixodid tick, *Rhipicephalus appendiculatus*, was unsuccessful.

With an antigen prepared from the impala blood and the indirect fluorescent antibody test, this parasite was serologically distinct from other theilerial parasites isolated from Bovidae in East Africa.

INTRODUCTION

In East Africa there is a greater diversity of ungulates than in any other comparable area of the world and in the family Bovidae 46 species have been recorded.⁸ Of these 46 species, most of those examined have been shown to harbour parasites of the family Theileriidae⁴ which are well known protozoan pathogens of domestic bovids. Since *Theileria* from wild animals may play an important role not only in wild animal disease,⁸ but also in the epizootiology of cattle theileriosis^{8,12,13} there is considerable interest in determining their inter-relationship.

There have been previous reports of *Theileria* in impala^{4,10,11} but their rela-

tionship to other theilerial parasites is not known.¹⁰ This paper reports preliminary experiments to determine the relationship of *Theileria* species of an impala to other theilerial parasites of East African Bovidae.

MATERIALS AND METHODS

Experimental animals

A juvenile male impala was captured on a farm in the Machakos District of Kenya, where it was confined to a portable pen for 3 weeks. It was then transported to Kabete and housed for one month before experimentation. Theilerial parasites were detected in blood smears.

^[1] and ^[2] Projects supported by the United Nations Development Programme with the Food and Agriculture Organization of the United Nations as the Executing Agency, in co-operation with the Kenya Government and the East African Community respectively.

^[3] Present address: Frithiofsväg 43, 19400-S Upplands Väsby, Sweden.

This animal was chosen as a donor animal for an attempted transmission.

A female impala was also captured on the same farm and after transport to Kabete gave birth to a calf. Blood smears from this calf were examined regularly for theilerial parasites but none were found. At eight months of age this animal was used as a recipient for infected blood in the transmission experiment.

For attempts to infect cattle, a steer of *Bos taurus* type was used. This steer was placed in isolation immediately after birth and splenectomized at three months of age and was approximately one year old at the start of the experiments. Another steer, also of *Bos taurus* type, obtained from a farm where strict acaricidal regimes were practised, was transported to Kabete at nine months of age. All animals at Kabete were kept in tick free conditions.

Ticks

Rhipicephalus appendiculatus from the Kabete colony, maintained according to Bailey,¹ were used for transmission experiments.

Specimen collection

Before examination, the impala were immobilized using a Cap-Chur Gun⁴ with xylazine⁵ as the anaesthetic (0.6-1.5 mg/kg body weight). Experimental cattle were examined every second day and the impala every third day. During experiments, blood, with EDTA as an anticoagulant, was collected from the jugular veins of the animals at regular intervals for blood smears and haematology. Other samples of blood were allowed to clot and serum was collected. Blood smears were stained in Giemsa and examined for the presence of theilerial piroplasms. In some cases lymph node biopsies were taken, smears prepared, stained in Giemsa and examined for the

presence of theilerial schizonts. Haematology was carried out by standard procedures with the use of a Coulter Counter.⁶ Rectal temperatures were taken.

Attempted transmission of impala *Theileria*

When its parasitaemia increased to 2% the donor impala was bled from the jugular vein, using heparin (20 i.u./ml of blood) as an anticoagulant. Twenty ml of blood was inoculated into the recipient impala, half intravenously and half subcutaneously. Concurrently a similar amount of blood was inoculated into the splenectomized steer.

R. appendiculatus larvae were applied in a cotton bag to the ears of the donor impala.¹ As they became engorged the larvae were collected daily and allowed to moult to nymphs. 500 nymphs from this batch were applied to an ear of a steer and allowed to feed to repletion.

Serology

A piroplasm antigen (IPA) was prepared for use in the indirect fluorescent antibody test (IFA) from the blood of the recipient impala according to the methods of Burrige.⁵ The parasitaemia of *Theileria* in the impala blood was 2%, lower than is usually found satisfactory for a slide antigen. This was compensated for by the large number of erythrocytes per microscopic field as impala have very small erythrocytes (3.2-4.8 μ m in diameter).⁹

The IPA was then evaluated against standard control sera of a variety of theilerial parasites^{6,7} using the IFA test with a fluorescein isothiocyanate anti-cattle globulin.⁵ Also, the IPA was used in the IFA test to detect antibodies against impala *Theileria* in the experimental animal. Positive control serum obtained from the donor impala was tested for cross reactions with various theilerial antigens⁷ as shown in Table 1.

⁴ Palmer Chemical and Equipment Co. Inc., Box 867, Douglasville, Georgia, U.S.A. 30134.

⁵ Rompun, Bayer Agrochem Ltd., Eastern Way, Bury St. Edmunds, Suffolk, U.K.

⁶ Coulter Electronic Inc., Hialeah, Florida, U.S.A.

TABLE 1. A comparison of antibody titres of positive sera against antigens of some theilerial parasites of Bovidae in East Africa using the indirect fluorescent antibody (IFA) test.

Reciprocal IFA titres produced against various antigens							
Positive control sera against <i>Theileria</i> parasite	Impala <i>Theileria</i> ¹ piroplasm	Eland ⁴ schizont antigen	<i>Theileria</i> ³ <i>gorgonis</i> piroplasm	<i>Theileria</i> ² <i>lawrencei</i> (Serengeti) schizont	<i>Theileria</i> ³ <i>mutans</i> (Aitong) piroplasm	<i>Theileria</i> ² <i>parva</i> (Muguga) piroplasm	<i>Theileria</i> ² <i>parva</i> (Muguga) schizont
Impala <i>Theileria</i> ¹	2560	<10	<40		<40	<10	<10
Eland <i>Theileria</i> ²		160	<40		40	<40	<10
<i>Theileria gorgonis</i> ³	<10	<40	640	<40	<40	<40	<10
<i>Theileria lawrencei</i> ² (Serengeti)	<10	<40	<40	640	<40	10,240	640
<i>Theileria mutans</i> ³ (Aitong)	<10	<40	<40	<40	10,240	<40	<40
<i>Theileria parva</i> ² (Muguga)	<10	<40	<40	640	<40	10,240	640

Material used derived from: 1, Impala; 2, cattle; 3, wildebeest; 4, eland.

In cattle reciprocal titres of 40 and over are considered significant for schizont antigen and 640 and over for piroplasm antigen.^{5,7}

RESULTS

When blood smears from the donor impala were first examined, theilerial piroplasms were detected in its erythrocytes in low numbers (approximately 0.3% of erythrocytes infected). During 3 weeks of observations these piroplasms increased until 2% of the erythrocytes were infected. Lymph node biopsies were

taken during this period but no theilerial schizonts were detected.

Piroplasms were first detected in the blood of the recipient impala 10 days after inoculation. The parasitaemia gradually increased until it reached a peak of 2% of the erythrocytes infected after 48 days. At this stage the parasitaemia began to decrease. In an attempt to exacerbate the parasitaemia the impala was

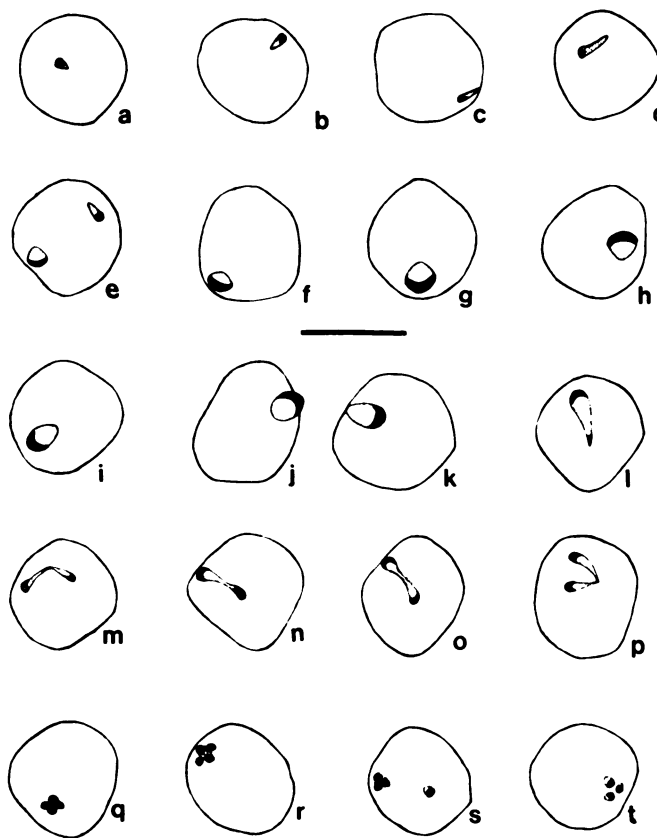


FIGURE 1. Piroplasms in the blood of impala:

a-e forms with solid cytoplasm

e-l vacuolated forms

m-p forms in "binary fission"

q-t forms in "quarternary fission"

Scale equals 4 μ m.

then splenectomized, but it unfortunately died after the operation.

No febrile response was observed during the course of the theilerial infection; however, the animal became anaemic. The erythrocyte count base-line of 35.9×10^6 RBC/mm³ decreased to 15.5×10^6 RBC/mm³ and the packed cell volume decreased from 57% to 36%. Associated with this was a fall in haemoglobin levels from 21.2 to 11.5 g/100 ml. The leucocyte count increased slightly from 3,831 to 5,373/mm³.

No infection developed in the splenectomized steer after the inoculation of impala blood nor in the steer which received the ticks.

The morphology of the impala *Theileria* in the erythrocytes of the donor and recipient impala was studied in some detail. The piroplasms in the donor impala were mostly small vacuolated forms with relatively large nuclei (Fig. 1 e-1). The piroplasms varied in length from 0.7 μ m to 2.5 μ m, the smaller parasites being ring-shaped and the larger parasites oval. A few piroplasms with non-vacuolated cytoplasms were detected. These were usually rod-shaped varying in length from 0.5 μ m to 2.2 μ m (Fig. 1, a-e). Apparently dividing parasites were rare. During the rising parasitaemia small parasites with solid cytoplasm were most abundant (Fig. 1, a-e). In a sample of 1000 piroplasms 65.6% of the parasites had non-vacuolated cytoplasm and 30.1% of the parasites were vacuolated. This was the reverse of the situation in the donor impala. Also in the recipient impala, forms of the parasite thought to be undergoing division were more common: 3.3% were thought to be undergoing binary fission (Fig. 1, m-p) and 1.0% quarternary fission (Fig. 1, q-t).

The IPA antigen prepared from the recipient impala was tested against sera from animals infected with various other *Theileria*, using the IFA test. The results are summarised in Table 1. No cross-reactions were observed with other *Theileria*. However, sera obtained from the donor impala gave a titre against the IPA of up to 1/2560. This serum was

used as an impala *Theileria* positive control serum and no significant titres against antigens of other theilerial parasites were observed (Table 1).

During the investigation the donor impala sera had antibody titres against the impala *Theileria* antigen of 1/640 to 1/2560. The recipient impala had a titre of 0 before inoculation of impala blood and this rose to 1/160 during the resultant infection. The experimental cattle had a titre of 0 against the impala *Theileria* antigen throughout the experiments.

DISCUSSION

It was shown that the impala *Theileria* was blood transmissible within the species. This suggests that these piroplasms divide in erythrocytes similarly to *T. mutans* of cattle.^{2,11} Apparently dividing piroplasms detected in the erythrocytes of impala were thought to represent stages in quarternary and binary fission, which have also been described in *T. mutans* infections.¹¹

The impala *Theileria* was neither transmitted by blood to a splenectomized steer nor by *R. appendiculatus* to a steer. This agrees with the lack of success in tick transmitting *Theileria* from impala to cattle as reported by previous workers,⁴ (A. S. Young, unpublished data).

The serological investigation suggested that the impala *Theileria* was distinct from other theilerial species studied. The impala *Theileria*, however, has been placed in the family Theileriidae because of morphological and behavioural resemblances of its piroplasms to those of *T. mutans* and other theilerial species. In this paper we have demonstrated the usefulness of susceptible wild bovids in the study of *Theileria* and thrown some light on the relationships of impala *Theileria*. Before the exact role of wild Bovidae in the theileriosis of domestic animals can be established, more extensive work on the relationships of wild bovid *Theileria* will have to be undertaken.

Acknowledgements

We would like to thank Mr. N. Peckover for permission to capture impala on his farm. Colleagues on our projects gave us considerable help and advice during this work. This paper is published with the permission of Dr. I. E. Muriithi, Director of Veterinary Services, Kenya, and Dr. G. L. Corry, Director of the East African Veterinary Research Organization, Muguga, Kenya.

LITERATURE CITED

1. BAILEY, K. P. 1960. Notes on the rearing of *Rhipicephalus appendiculatus* and their infection with *Theileria parva*. Bull. epizoot. Dis. Afr. 8: 33-43.
2. BARNETT, S. F. 1968. Theileriasis. In *Infectious Blood Diseases of Man and Animals*, ed. Weinmann, D. and Ristic, M. Academic Press, London.
3. BROCKLESBY, D. W. 1964. Parasites of the family Theileriidae of the African buffalo occurring in East Africa. D.V.M. Thesis, University of Zurich.
4. BROCKLESBY, D. W. and B. O. VIDLER. 1966. Haematozoa found in the wild members of the order Artiodactyla in East Africa. Bull. epizoot. Dis. Afr. 14: 285-299.
5. BURRIDGE, M. J. 1971. Application of the indirect fluorescent antibody test in experimental East Coast fever (*Theileria parva* infection of cattle). Res. vet. Sci. 12: 338-341.
6. BURRIDGE, M. J. and C. D. KIMBER. 1973. Serological studies on *Theileria gorgonis* using the indirect fluorescent antibody test. Z. tropenmed. Parasit. 24: 186-191.
7. BURRIDGE, M. J., A. S. YOUNG, D. A. STAGG, G. K. KANHAI and C. D. KIMBER. 1974. *Theileria lawrencei* infection of cattle and the African buffalo. Evaluation of a buffalo derived cell culture schizont antigen. Res. vet. Sci. (in press).
8. DORST, J. and P. DANDELOT. 1972. *A Field Guide to the Larger Mammals of Africa*. Collins, London.
9. DREVEMO, S., J. G. GROOTENHUIS and L. KARSTAD. 1974. Blood parameters of wild ruminants in Kenya. J. Wildl. Dis. 10: 327-334.
10. IRVIN, A. D., B. SCHIEMANN, P. OMWOYO and R. E. PURNELL. 1973. Blood parasites of the impala (*Aepyceros melampus*) in the Serengeti National Park. Vet. Rec. 93: 200-203.
11. NEITZ, W. O. 1957. Theileriosis, gonderioses and cytauxzoonosis. A review. Onderstepoort J. Vet. Res. 27: 275-430.
12. YOUNG, A. S., D. BRANAGAN, C. G. D. BROWN, M. J. BURRIDGE, M. P. CUNNINGHAM and R. E. PURNELL. 1973. Preliminary observations on a Theilerial species pathogenic to cattle isolated from buffalo (*Syncerus caffer*) in Tanzania. Br. vet. J. 129: 382-389.
13. YOUNG, A. S., M. J. BURRIDGE and R. C. PAYNE (in preparation). The transmission of a *Theileria* species to cattle by the ixodid tick *Amblyomma cohaerens*, Donitz 1909.

Received for publication 15 August 1974