

## TUBERCULOSIS IN LESSER FLAMINGOES IN KENYA

Authors: COOPER, J. E., and KARSTAD, L.

Source: Journal of Wildlife Diseases, 11(1) : 32-36

Published By: Wildlife Disease Association

URL: <https://doi.org/10.7589/0090-3558-11.1.32>

---

The BioOne Digital Library (<https://bioone.org/>) provides worldwide distribution for more than 580 journals and eBooks from BioOne's community of over 150 nonprofit societies, research institutions, and university presses in the biological, ecological, and environmental sciences. The BioOne Digital Library encompasses the flagship aggregation BioOne Complete (<https://bioone.org/subscribe>), the BioOne Complete Archive (<https://bioone.org/archive>), and the BioOne eBooks program offerings ESA eBook Collection (<https://bioone.org/esa-ebooks>) and CSIRO Publishing BioSelect Collection (<https://bioone.org/csiro-ebooks>).

Your use of this PDF, the BioOne Digital Library, and all posted and associated content indicates your acceptance of BioOne's Terms of Use, available at [www.bioone.org/terms-of-use](http://www.bioone.org/terms-of-use).

Usage of BioOne Digital Library content is strictly limited to personal, educational, and non-commercial use. Commercial inquiries or rights and permissions requests should be directed to the individual publisher as copyright holder.

---

BioOne is an innovative nonprofit that sees sustainable scholarly publishing as an inherently collaborative enterprise connecting authors, nonprofit publishers, academic institutions, research libraries, and research funders in the common goal of maximizing access to critical research.

## TUBERCULOSIS IN LESSER FLAMINGOES IN KENYA

J. E. COOPER<sup>1</sup> and L. KARSTAD,<sup>2</sup> Veterinary Research Laboratory, P.O. Kabete, Kenya

E. BOUGHTON, Central Veterinary Laboratory, Weybridge, Surrey, England

**Abstract:** Four cases of tuberculosis are recorded in lesser flamingoes (*Phoeniconaias minor*) from Lake Nakuru, Kenya. The clinical, pathological and microbiological findings are given and the possible significance of the infection in this species is discussed.

### INTRODUCTION

There are two species of flamingo in East Africa, the greater (*Phoenicopterus ruber*) and the lesser (*Phoeniconaias minor*). Both species are spectacular in appearance. Many tourists to East Africa visit the Rift Valley Lakes in order to see these birds and concern has been expressed lest they should suffer a decline in numbers.

Information on diseases of flamingoes is limited mainly to observations on captive birds in European or American zoological collections. The only reports of disease in flamingoes in Africa refer to leg paralysis following capture,<sup>8</sup> foot injuries and infections;<sup>9</sup> and three *post-mortem* reports including one case of "avian tuberculosis infection" diagnosed histologically in a lesser flamingo from Lake Nakuru.<sup>6</sup>

In this paper we describe tuberculosis in four adult lesser flamingoes.

### MATERIALS AND METHODS

The birds, all adults, were collected alive or dead on Lake Nakuru which lies at an altitude of 1,750 m in the Kenya Rift Valley.

Haematological estimations were carried out using standard techniques for avian blood.<sup>4</sup>

A *post-mortem* examination was carried out on all birds but the central nervous system was not examined. Tissues for histological examination were fixed in 10% formalin, embedded in wax and sectioned. They were stained with haematoxylin and eosin and by the Ziehl-Neelsen method for acid-fast organisms. Material for bacteriology was examined initially on stained smears and was then cultured on blood agar, McConkey's agar, Middlebrook 7H10 and Löwenstein-Jensen media at both 37C and 43C. The mycobacteria were typed by thin-layer lipid chromatography and tube agglutination tests, by the methods of Birn *et al.*<sup>1</sup>

### CLINICAL HISTORIES

Birds 1, 2 and 3 were found alive but mired in the mud on 22/9/73 in one small area (less than 0.5 ha) on the north edge of Lake Nakuru while bird 4 was picked up alive, but weak, in the same vicinity on 21/11/73.

Bird 1 was thin and weak and died within 2 min of capture. Bird 2 had a prominent sternum but felt very heavy; it was severely waterlogged and fluid could be palpated under the skin. It was dried and warmed, but died 2½ h after capture. Blood for haematology was taken from the heart immediately after

<sup>1</sup> Present address: Clinical Research Centre, Watford Road, Harrow, Middlesex, England.

<sup>2</sup> FAO Wildlife Disease Project—a project of the Government of Kenya supported by the United Nations Development Program with the Food and Agricultural Organization of the United Nations as the executing agency.

death. Bird 3 was also thin and weak; it too was kept warm but it was found dead 12 h later. Bird 4 was brought to Kabete on 22/11/73. After a blood sample was taken by cardiac puncture for haematology, it was killed by cervical dislocation. Its weight was 1,245 g.

#### POST-MORTEM FINDINGS

All birds were thin and had feather lice (Mallophaga).

##### Bird 1

The left lung was replaced by a light yellow nodular caseous mass. Similar caseous material was present under the sternum, within the interclavicular, left thoracic and abdominal airsacs, on the pericardium, and on the anterior poles of the kidney. The liver was slightly swollen and chocolate brown. The heart was flabby. The ureters were both slightly distended and there were approximately 10 whitish-yellow nodules on the serosal surface of the intestine. The testes were small.

##### Bird 2

Oedematous, straw-coloured fluid was present under the skin and within skeletal muscles and connective tissue throughout the carcass. Internally there was a yellow mass overlying the syrinx and similar material was present in discrete raised yellow nodules in both lungs. There was one small (2-3 mm diameter) yellow lesion on the border of the liver but the organ itself appeared normal in size, colour and consistency. The gall bladder was enlarged and the stomach contained only fine sand. The intestinal contents were green and there were many small petechiae on the intestinal mucosa. There was one small nodular lesion on the serosa of the intestine. The kidney was yellow and friable and the testes were small.

##### Bird 3

Internally there were no respiratory tract lesions but the liver, which was

enlarged, had numerous yellow-white foci of various sizes on its surface and within its substance. The gastro-intestinal tract showed no nodules but there was a pale area in the wall of the pylorus and the stomach contained small quantities of sand. The ovary was apparently inactive but the oviduct was enlarged (approximately 5 mm in diameter) suggestive of previous egg laying.

##### Bird 4

There was a 7-8 mm diameter nodule at the base of the left elbow joint. There was a hard grey 10 cm x 6 cm nodular mass on the left shoulder region, lateral to the vertebral column which extended into the interclavicular airsac (Figure 1). The mass consisted of 1-2 cm nodules with gritty, orange-yellow content. There were similar nodules in the right abdominal airsac, left adrenal, both lungs and mesentery. There were many pale foci (1-3 mm diameter) in the liver, which was friable, and the heart had a raised white lesion, 4 mm in diameter on the left ventricle. The stomach contained algae and on the intestines there were many firm serosal nodules of various sizes. The kidneys were friable. The ovary showed slight activity and the oviduct again was enlarged.

#### LABORATORY RESULTS

##### Haematology:

Results on the two birds examined are shown in Table 1. Examination of smears showed no abnormalities.

##### Histopathology:

The distribution and frequency of lesions in the four cases were somewhat variable but their microscopic appearance did not vary appreciably from case to case.

Three types of lesions were noted: classical tuberculous granulomata; arteritis, involving small and medium sized arteries; and focal collections of histiocytes. The granulomata consisted of

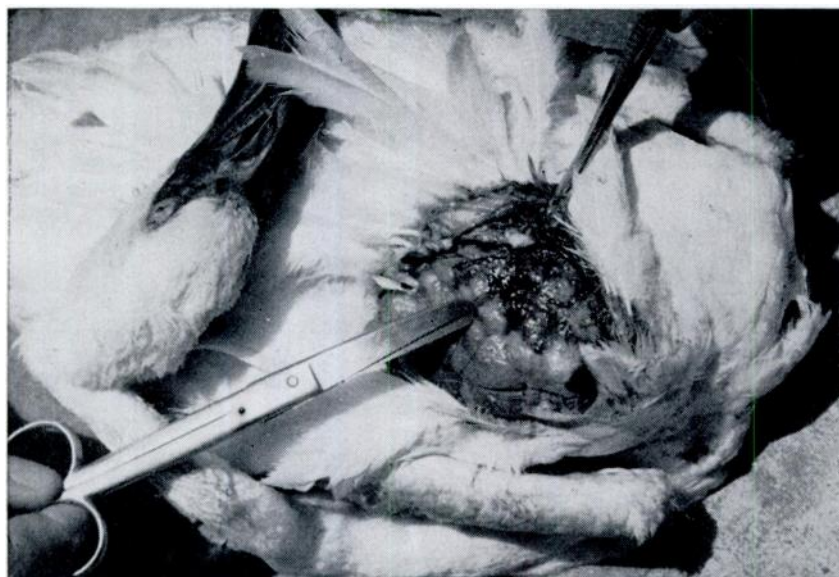

FIGURE 1. Flamingo 4, dorsal view, showing tuberculous lesion on shoulder region.

TABLE 1. Haematological Findings in Two Lesser Flamingoes.

Erythrocytes	Packed Cell Volume	Haemoglobin
Bird 2 — 2,080,000/mm <sup>3</sup>	49%	19.5g/100ml
Bird 4 — 1,940,000/mm <sup>3</sup>	35%	10.0g/100ml

central areas of homogeneous eosinophilic necrotic material surrounded by three concentric narrow zones: first, a zone of multinucleate giant cells together with large histiocytes, then a ring of fibrous connective tissue, and finally an irregular border of infiltrating leucocytes, mainly lymphocytes. Such granulomata were found in all major visceral organs, notably the heart, lung, liver, spleen and kidney. The second type of lesion, arteritis, seemed to affect arteries in close proximity to the tuberculous granulomata. The changes consisted of proliferation of intimal cells, sometimes almost to obliterate the artery lumens, and proliferation of mononuclear leucocytes. The significance and pathogenesis of this lesion could not be determined. The third

mentioned lesion, focal proliferation of histiocytes, was seen in several organs but especially in the liver and kidney. These collections of histiocytes were microscopic, irregularly spherical, and when stained by the Ziehl-Neelsen method the histiocytes were shown to have their cytoplasm packed with masses of acid-fast bacilli (Figure 2). Acid-fast bacilli were seen also in the caseous centres of granulomata, and in the adjacent histiocytes and giant cells.

A number of incidental findings, such as the distended ureters in bird 1 and the pyloric lesion in bird 3, were not investigated histopathologically. Neither was the heart lesion in bird 4 but from its gross appearance this was assumed to be a tubercle.

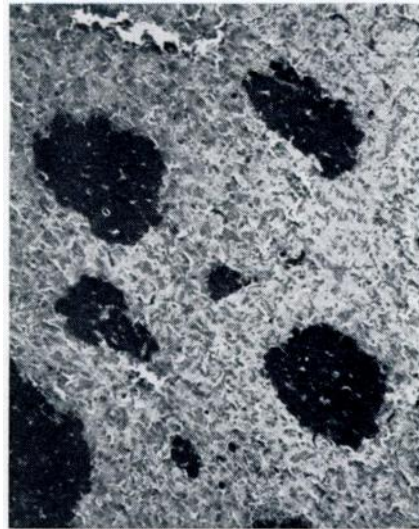


FIGURE 2. Islands of histiocytes in the liver. Cytoplasm of histiocytes is filled with acid-fast bacilli, appearing black in the photograph. Ziehl-Neelsen 200X.

#### Bacteriology:

Acid-fast bacteria were isolated from the lung of bird 1 and liver of bird 2 on both Middlebrook and Löwenstein-Jensen media. Bacterial growth was present after 5 weeks. In addition an *Aeromonas* sp. biochemically resembling *A. shigelloides* was isolated from the kidney of bird 2.

The acid-fast organisms isolated from both birds grew slowly on Löwenstein-Jensen medium as circular, domed, smooth, nonchromogenic colonies; they deaminated nicotinamide and pyrazinamide but not urea, and did not reduce nitrate. These features suggested mycobacteria of the *M. avium-intracellulare* complex, and both strains were typed by thin-layer lipid chromatography and agglutination tests as *M. avium* type 1.

#### DISCUSSION

With the exception of the case reported by Koeman *et al.*,<sup>6</sup> this appears to be the only record of mycobacterial infection in East African flamingoes. Since this report was compiled a further 10 cases have been diagnosed, again all in lesser flamingoes at Lake Nakuru.<sup>3</sup>

One previous case of an acid-fast bacterial infection has been reported from an avian host at Lake Nakuru.<sup>5</sup> This was an African fish eagle (*Haliaeetus vocifer*) in which acid-fast organisms were seen in fixed material on histopathological examination but bacteriological culture was not carried out. The authors considered this to be the first recorded case of avian tuberculosis in a wild bird in Kenya and they discussed its possible source. Despite its name, the fish eagle feeds largely on flamingoes on Lake Nakuru.

It would appear from the present study that avian tuberculosis is present amongst the flamingoes on Lake Nakuru and is probably responsible for deaths. It is impossible to say whether the infection is recent or one that has been present on the lake for some time; cases may have been overlooked in the past.

The avian fauna of Lake Nakuru includes numerous ducks and waders, many of which are migratory. It may therefore be relevant that, although *M. avium* type 1 is the least common of the three types in domestic fowl, and apparently in wild birds in those parts of Europe from which information is available,<sup>2</sup> it was found in a recent study to be by far the most common mycobacterium isolated in enzootic tuberculosis of ducks in a British wildfowl reserve.<sup>7</sup>

The significance of the infection in flamingoes could be considerable. At times there are over one million flamingoes on Lake Nakuru and, as these birds are usually in close proximity to one another, spread of an acid-fast infection would not be difficult. This lake is

<sup>3</sup> Grootenhuis, J. G., J. Hopcraft, L. Karstad and S. Drevemo. 1974. Unpublished data.

alkaline (soda) but the organism is relatively resistant to chemical agents and might withstand such conditions for considerable periods. At a time when there is concern over the future of Lake Nakuru and its bird population, the possible role of tuberculosis should not be overlooked.

#### Acknowledgments

We thank Mr. John Hopcraft, Director of the Baharini Wildlife Sanctuary, for his assistance and collaboration, Dr. N. Myers for Figure 1 and Mr. E. Edwards of the East African Tuberculosis Investigation Centre for initially culturing the organisms. This report is published with the permission of the Director of Veterinary Services, Kenya.

#### LITERATURE CITED

1. BIRN, K. J., W. B. SCHAEFER, P. A. JENKINS, T. SZULGA and J. MARKS. 1967. Classification of *Mycobacterium avium* and related opportunist mycobacteria met in England and Wales. *J. Hyg., Camb.* 65: 575-589.
2. BOUGHTON, E. and S. BERNSTAD. 1974. Screening by thin-layer chromatography of "avium-like" mycobacteria isolated from animals in Sweden. *Zentbl. Vet. Med. Reihe B.* 21: 171-175.
3. COOPER, J. E. 1968. Veterinary examination of exotic animals prior to export. *J. small Anim. Pract.* 9: 237-243.
4. COOPER, J. E. 1973. Some haematological data for birds of prey. *Raptor Research* 6: 133-136.
5. KALINER, G. and J. E. COOPER. 1973. Dual infection of an African fish eagle with acid-fast bacilli and an *Aspergillus* sp. *J. Wildl. Dis.* 9: 51-55.
6. KOEMAN, J. H., J. H. PENNING, J. J. M. DE GOEIJ, P. S. TJIOE, P. M. OLINDO and J. HOPCRAFT. 1972. A preliminary survey of the possible contamination of Lake Nakuru in Kenya with some metals and chlorinated hydrocarbon pesticides. *J. appl. Ecol.* 9: 411-416.
7. SCHAEFER, W. B., J. V. BEER, N. A. WOOD, E. BOUGHTON, P. A. JENKINS and J. MARKS. 1973. A bacteriological study of endemic tuberculosis in birds. *J. Hyg., Camb.* 71: 549-557.
8. YOUNG, E. 1967. Leg paralysis in the greater flamingo and lesser flamingo following capture and transportation. *Internat. Zoo Yearbook* 7: 226-227.

*Received for publication 30 April 1974*